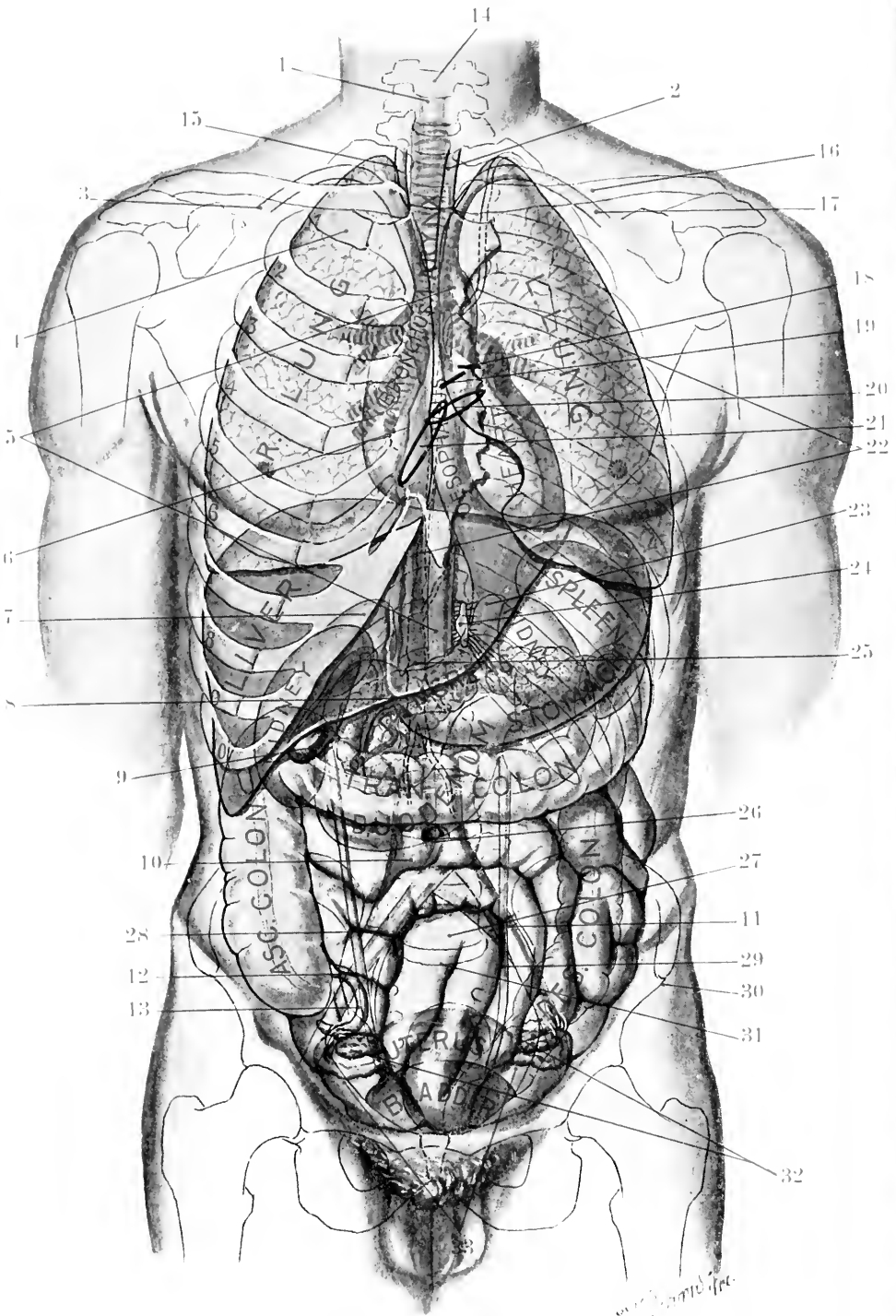






3 1761 04383 1536

PLATE I



Drawing showing the normal situation of the parts of the human trunk, introduced for the purpose of quickly and accurately preparing outline figures to illustrate the situation and extent of lesions found at any postmortem. 1, oesophagus; 2, left common carotid; 3, right subclavian artery; 4, first rib; 5, aorta; 6, sternum, with heart beneath; 7, adrenal; 8, pylorus; 9, gall-bladder; 10, ascending vena cava; 11, left common iliac; 12, ureter; 13, appendix; 14, vertebral column; 15, right common carotid; 16, clavicle; 17, left subclavian artery; 18, pulmonary valves; 19, aortic valves; 20, mitral valve; 21, tricuspid valve; 22, thoracic duct; 23, adrenal; 24, left solar plexus; 25, receptaculum chyli; 26, umbilicus; 27, small intestine; 28, right common iliac; 29, ureter; 30, anterior superior spine of pelvis; 31, fifth lumbar vertebra; 32, ovaries; 33, oviducts.





Digitized by the Internet Archive
in 2007 with funding from
Microsoft Corporation

MP.
C.
P.

POSTMORTEM PATHOLOGY

A MANUAL OF THE TECHNIC OF POST-MORTEM EXAMINATIONS AND THE INTERPRETATIONS TO BE DRAWN THEREFROM

A PRACTICAL TREATISE FOR STUDENTS AND PRACTITIONERS

BY

HENRY W. CATTELL, A.M., M.D.

PRESIDENT OF THE PHILADELPHIA MEDICAL JURISPRUDENCE SOCIETY, 1905-6; SOMETIME PATHOLOGIST TO THE PHILADELPHIA, PRESBYTERIAN, AND PENNSYLVANIA HOSPITALS; AMERICAN EDITOR AND TRANSLATOR OF ZIEGLER'S SPECIAL PATHOLOGY; FELLOW OF THE COLLEGE OF PHYSICIANS OF PHILADELPHIA, ETC.

THIRD EDITION

COPIOUSLY ILLUSTRATED WITH COLORED PLATES AND FIGURES

"Rotto dal mento lnsln dove si trulla.
Tra le gambe pendevan le minugia ;
La corata pareva, e il tristo sacco
Che merda fa di quel che si trangugla."

—DANTE

PHILADELPHIA AND LONDON
J. B. LIPPINCOTT COMPANY

1906

94277
24/12/08

Copyright, 1903, by J. B. LIPPINCOTT COMPANY

Copyright, 1905, by J. B. LIPPINCOTT COMPANY

Copyright, 1906, by J. B. LIPPINCOTT COMPANY

TO THE MEMORY OF
MY FRIENDS

DR. THOMAS G. MORTON

WHOSE SURGICAL SKILL AND GREAT DIAGNOSTIC ACUMEN WAS AT THE
SERVICE OF ALL DURING A LONG AND BUSY LIFE

AND

DR. THOMAS S. KIRKBRIDE, JR.,

WHOSE EARLY DEATH WAS A SAD LOSS TO AMERICAN
PATHOLOGY



PREFACE TO THE THIRD EDITION



THIS book has been out of print during the past school year owing to the unexpectedly rapid exhaustion of the second edition, within six months of its publication in 1905, and to the difficulties incident to seeing the work through the press because of unavoidable labor disturbances now adjusted. This delay, however, has afforded the author opportunity for making the revision more thorough. Two short chapters, one upon "Plant Pathology" and the other upon the "Teaching of Post-Mortem Technic," have been added and also much recent matter bearing upon syphilis, tuberculosis, tropical diseases, and other topics of immediate interest to those making post-mortem examinations. The number of illustrations has been increased by nineteen and several of the old cuts have been replaced by new ones.

The writer is indebted to Dr. W. M. L. Coplin for facilities conceded him for making special dissections for photographs at the Philadelphia Hospital and to Dr. W. Reynolds Wilson and Dr. George M. Boyd for a similar courtesy at the Philadelphia Lying-in Charity Hospital. The author is also under obligations to many kind friends for assistance; especially to Dr. John Guitéras, of Havana, and Dr. Martha Tracy, of New York, for material used in the chapter upon "Diseases due to Parasites;" to Dr. J. Morgan Coffin for information regarding the performance of autopsies in the United States Army, Navy, and Marine-Hospital Service; to Dr. R. V. Lavenson and Dr. G. Ó. Jarvis, both of Philadelphia, for some suggestions introduced into Chapters VI and X; to Mr. John Starr Hewitt for seeing the book through the press; to Miss L. A. Brown for the preparation of the Index; and to the writers of those suggestive reviews of the second edition, appearing in *Science*, May 19, 1905, by Professor Lewellys F. Barker, of Johns Hopkins University, and in the *Münchener medicinische Wochenschrift*, April 4, 1905, by the late Professor Hans Schmaus, of Munich.

As a German edition of this book will soon be issued by J. F. Bergmann, of Wiesbaden, the writer would be indebted for any suggestions and criticisms having especially in view the introduction into its pages of the most approved American and English methods of post-mortem technic and of the latest results of original research in pathology now so actively and successfully carried on in America, Canada, and Great Britain.

HENRY W. CATTELL, M D

3709 SPRUCE STREET, PHILADELPHIA, PA., July 1, 1906.

PREFACE TO THE FIRST EDITION



THIS book has been written for those who ought to make autopsies but do not and for those of whom such investigations are required, as medical students, hospital interns, and Coroner's physicians. While the author has mainly relied upon his personal experiences in the preparation of the subject-matter of this manual, he has freely used classifications and material derived from ORTH'S *Pathologisch-anatomische Diagnostik*, OSLER'S *Practice of Medicine*, NAUWERCK'S *Sectionstechnik*, and other publications mentioned in the foot-notes and in the text. He is, therefore, much indebted to these authorities, as well as to Dr. GEORGE ROBINSON and Mr. LOUIS SCHMIDT for most of the drawings, all of which were prepared under the writer's direction, to his friends and former students Drs. WILLIAM S. WADSWORTH, MARY E. LAPHAM, E. D. BURKHARD, and EDWARD LODHOLZ for suggestions in the preparation of the book, and to that excellent proof-reader Mr. T. GROW TAYLOR for seeing the work through the press.

HENRY W. CATTELL, M.D.

3709 SPRUCE STREET, PHILADELPHIA, PA., March 31, 1903.

CONTENTS



CHAPTER	PAGE
I. GENERAL CONSIDERATIONS	1
II. ORDER OF EXAMINATION AND POST-MORTEM RECORDS.....	14
III. POST-MORTEM INSTRUMENTS AND HOW TO USE THEM.....	34
IV. CARE OF THE HANDS AND TREATMENT OF POST-MORTEM WOUNDS	45
V. EXAMINATION OF THE EXTERIOR OF THE BODY	53
VI. TECHNIC OF OPENING THE ABDOMINAL CAVITY AND TOPOGRAPHIC EXAMINATION OF ITS WALLS AND THE PARTS CONTAINED THEREIN..	89
VII. TECHNIC OF EXPOSING THE THORACIC CAVITY AND THE EXAMINATION OF THE PARTS CONTAINED THEREIN	103
VIII. DISEASES OF THE HEART, BLOOD, BLOOD-VESSELS, AND LYMPH-VESSELS ..	126
IX. DISEASES OF THE RESPIRATORY TRACT AND ACCESSORY PARTS.....	156
X. CRITICAL EXAMINATION OF THE ORGANS OF THE ABDOMINAL CAVITY ..	173
XI. DISEASES OF THE GENITO-URINARY TRACT.....	209
XII. DISEASES OF THE LIVER, PANCREAS, AND THEIR DUCTS	223
XIII. EXAMINATION OF THE SKULL AND BRAIN	235
XIV. SPINAL COLUMN, SPINAL CORD, AND NERVES	253
XV. DISEASES OF THE BRAIN, SPINAL CORD, AND NERVES	257
XVI. EXAMINATION OF NASOPHARYNX, EYES, AND EARS	270
XVII. BONES AND JOINTS	275
XVIII. POST-MORTEM EXAMINATION OF THE NEW-BORN	289
XIX. RESTRICTED POST-MORTEM EXAMINATIONS	295
XX. RESTORATION AND PRESERVATION OF THE BODY	298
XXI. DISEASES DUE TO PARASITES	306
XXII. PRESERVATION OF TISSUES FOR MICROSCOPIC AND MACROSCOPIC PURPOSES	368
XXIII. BACTERIOLOGIC INVESTIGATIONS	382
XXIV. WEIGHTS AND MEASUREMENTS	394
XXV. POST-MORTEM EXAMINATIONS OF THE LOWER ANIMALS	407
XXVI. PLANT PATHOLOGY	432
XXVII. TEACHING OF POST-MORTEM TECHNIC AND THE INTERPRETATIONS TO BE DRAWN FROM THE MATERIAL SO OBTAINED	434
XXVIII. MEDICOLEGAL SUGGESTIONS	436
XXIX. PRUSSIAN REGULATIONS FOR THE PERFORMANCE OF AUTOPSIES IN MEDI- COLEGAL CASES	479
XXX. USUAL CAUSES OF DEATH: THEIR NOMENCLATURE, COMPLICATIONS, AND SYNONYMS ..	491
XXXI. REFERENCES	508

LIST OF ILLUSTRATIONS



PLATE	PAGE
I. Outline Chart of Human Body	<i>Second page of cover</i>
II. Normal Size of Familiar Objects	27
III. Post-Mortem Hæmoglobin Scale. Moisture Scale	<i>Third page of cover</i>
IV. Chart of Tumors	148
V. Bacteriologic Chart	385
VI. Powder Markings	449

FIG.	PAGE
1. Portable post-mortem table	10
2. Body in coffin prepared for post-mortem examination	10-11
3. Post-mortem table for babe, constructed of chairs and drawing-board..	10-11
4. Post-mortem room of Ayer Clinical Laboratory, Pennsylvania Hos- pital	10-11
5. Refrigerator box for preservation of bodies	11
6-8. Working plans for preparing refrigerator box for storage of bodies ...	12
9. Adjustable and movable table for transporting bodies	12
10, 11. Plans for post-mortem table	12-13
12, 13. Combination electric, gas, and water fixtures for post-mortem table ..	13
14. Section- or cartilage-knife	34
15. Cartilage-knife with projection on back	34
16. Post-mortem knife with a faulty point and improper belly	34
17. Coplin's brain-knife	34
18. Bread-knife for incising large organs	34
19. Valentine's knife	34
20. Pick's myelotome	34
21. Forceps; saw; needles; hammer; steel tape measure; hone and strop; and scalpel	34-35
22. Saw for post-mortem work	34-35
23. Butcher's saw for post-mortem work	34-35
24. Hey's saw	34-35
25. Metacarpal saw	34-35
26. Luer's double rhachiotome	34-35

FIG.	PAGE
27. Masland's electric saw and stand	35
28-30. Various forms of scissors	35
31, 32. Proper and improper forms of enterotome	35
33. Proper form of costotome	36
34. Improper form of costotome	36
35. Steel hammer	36
36-38. Various forms of chisels	36-37
39, 40. Various forms of forceps	36-37
41. Straight grooved director	36-37
42-44. Various forms of Satterthwaite's calvarium clamp	36-37
45. Folding head-rest	37
46. Cornell folding clamp	38
47. Measuring stick	38
48. Raspatory	38
49. Pocket-case of instruments	38
50. Cones for measuring orifices	38-39
51. Glass balls for measuring orifices	38-39
52. Linen twine wrapped of proper length ready for use	38-39
53. Formad's pocket-case for post-mortem instruments	38-39
54. Method of holding cartilage-knife	39
55-57. Lines showing methods for opening thoracic and abdominal cavities ..	89
58, 59. Method of making initial incision over sternum	89
60, 61. Method of removing skin over sternum and ribs	89-90
62. Method of opening abdominal cavity	89-90
63. Method of incising ribs	89-90
64, 65. Method of separating sternoclavicular attachment	90
66. Incising first rib and sternoclavicular articulation with costotome	104
67. Severance of diaphragm	104
68, 69. Removal of bony parts covering thoracic cavity	104-105
70. Breastplate after its removal from body	104-105
71. Methods of enlarging abdominal cavity and of protecting operator's hands from injury	104-105
72. Organs of the mediastinum	105
73. Method of opening pericardium	110
74. Cardiac plexus and ganglion of Wrisberg	110
75. Pericardium opened	111
76-78. Lines for opening heart	114
79. Method of opening right auricle	116
80. Situation of pulmonary veins	116
81. Method of opening left ventricle	116-117
82. Method of removing heart from body	116-117
83. Method of opening pulmonary artery	116-117

LIST OF ILLUSTRATIONS

xi

FIG.

PAGE

84.	Interior of left auricle and ventricle fully exposed	117
85.	Reconstruction of heart after its examination	117
86-89.	Method of opening lung and examining pulmonary vessels	122-123
90.	Method of removing tongue, œsophagus, trachea, etc., in a single piece ..	124
91.	Examination of organs of neck	124-125
92.	Method of opening trachea posteriorly	124-125
93.	Examination of trachea and vocal cords	124-125
94.	"Grand swipe" of thoracic organs	125
95.	Finger method of tying intestine	179
96.	Method of tying intestines preparatory to their removal	180
97.	Bucket method of opening and cleansing intestines	180
98.	Method of removing small intestines	180-181
99.	Opening of small intestines after their removal from the body.....	180-181
100.	Method of incising kidney with its ureter still attached	180-181
101, 102.	Method of opening kidney.....	180-181
103.	Method of removing capsule of kidney (without gloves)	181
104.	Method of removing capsule of kidney (with gloves)	181
105.	Relations of pancreas, kidney, ureter, adrenal, and solar plexus	192
106.	Position for body in examination of rectovaginal region	194
107-114.	Post-mortem extirpation of bladder, uterus, and adnexa through vagina, and subsequent restoration of parts	194-195
115.	Method of opening uterus	194
116.	Uterus and adnexa after being opened	195
117-119.	Author's method of examining testicles, epididymis, spermatic cord, etc., without disfigurement	194-195
120.	Method of opening seminal vesicles	195
121.	Relation of gall-ducts and pancreas to the duodenum.....	195
122.	Examination of bile ducts	198
123.	Method of examining stomach	199
124.	Removal of liver from body	199
125.	Method of incising liver	205
126.	Starting-point of incision in removal of brain	236
127.	Parting of hair so as not to injure it in removal of brain	236
128.	Toilet of hair preparatory to removal of brain in the female	236-237
129.	Method of sawing skullcap	236-237
130.	Angular method of removing brain	236-237
131.	Method of breaking up inner table with an old knife after sawing	237
132.	Method of drawing off skullcap with a retractor	237
133.	Appearance of dura mater after removal of calvarium	238
134.	French method of opening skull	238
135.	French method of opening dura	239
136.	Appearance of brain after removal of dura.....	238-239

FIG.	PAGE
137. Method of removing brain from skull	238-239
138. Sawing of brain	239
139. Removal of pituitary body	244
140. Nerves and foramina	244-245
141-144. Virchow's method of dissecting brain	244-245
145-147. Virchow's method of dissecting brain (continued)	246-247
148. Nauwerck's method of dissecting brain	246-247
149. Basal ganglia, with cerebellum, pons Varolii, and medulla oblongata attached, in Meynert's method of dissecting brain	246-247
150. Flechsig's, Brissaud's, and Dejerine's transverse sectioning of brain	247
151. Dejerine's incisions for brain previous to hardening	247
152. Lines for removing spinal cord and brain, the latter through a small triangular occipital incision	252
153-158. Removal of spinal cord	252-253
159. Opening spinal cord	253
160. Method of examining nasopharynx, eyes, and ears.....	270
161, 162. Harke's method of examining nasopharynx	270
163. Use of wire-saw in examining auditory apparatus	273
164. Postmortem on child	290
165. Johan van Neck's painting of Frederik Ruysch, the anatomist.....	290-291
166. Relative size of spleen, kidney, and appendix in a new-born child	290
167. Examination of ductus arteriosus	290-291
168. Examination of umbilical vessels	290-291
169. Removal of spinal cord in a child	291
170, 171. Method of examining the femur for syphilitic osteochondritis	292
172. Method of exposing BécIard's centre.....	293
173, 174. Method of examining nasal cavities, antrum of Highmore, etc.	298
175, 176. Method of sewing up the body.....	298-299
177. Slee's method of fixing skullcap	299
178. Author's method of holding skullcap in place	300
179. Method of withdrawing blood from a body previous to injection of embalming fluid	298-299
180. Injection of body with embalming fluid	298-299
181, 182. Refrigerating room for preservation of bodies, University of Pennsylvania	299
183. Method of determining rectal temperature in a guinea-pig	390
184. Animal holder	390
185. Method of performing peritoneal injection in a rabbit	390-391
186. Ear method of inoculating rabbit	390-391
187. Post-mortem examination of guinea-pig	390-391
188. Post-mortem examination of rabbit	391
189-191. Post-mortem examination of horse	411, 412, 414

LIST OF ILLUSTRATIONS

xiii

FIG.	PAGE
192. Lines for opening cephalic cavities of horse	420
193. Lines for opening cranial cavity of horse	421
194. Lines for exposing cranial and nasal cavities in ruminants	424
195. Appearance of cranial cavity in a cow	424
196, 197. Second method for removal of the brain in ruminants.....	425
198. Post-mortem examination of sheep	426
199. Post-mortem examination of dog	427
200. Exposure of oral and pharyngeal cavities in a dog.....	428
201. Virchow, 1892, Jubilee Medal	479
202. Jars prepared for medicolegal work.....	487

POST-MORTEM EXAMINATIONS



CHAPTER I

GENERAL CONSIDERATIONS

HISTORICAL.—No mention is made in literature before the time of Herophilus (320–250 B.C.) of opening the dead body for legal or scientific purposes, although ancient writings abound in references to violent death and the shedding of blood. Long before this, however, the Jewish priests are known to have examined the carcasses of animals killed for food to detect impurities, and the knowledge of anatomy displayed by the ancient Egyptians in embalming could only have been acquired by dissection.

The old and important office of Coroner¹ dates from the reign of King Athelstan (925 A.D.). Its duties were clearly defined soon after the Norman conquest, and from England the institution was brought to America by the colonists. (Becker.) Massachusetts in 1877 abolished the office of Coroner, substituting therefor medical examiners, and in 1904 the New York Legislature passed a bill with the same object in view for New York City, which was, however, returned to the Governor with the Mayor's veto. In 1905 a similar bill failed to pass the Legislature. In Pennsylvania the office of Coroner is a constitutional one.

The first post-mortem examination in the Western Hemisphere appears to have been made in 1535 at Montreal during the prevalence of an unknown epidemic disease. On this occasion the body of one Philip Rougemont² was "ripped to see if by any meanes possible we might know what it [the disease] was, and to seeke meanes to save and preserve the rest of the company." The heart, liver, lungs, spleen, and thigh were examined. Among other early autopsies in America may be mentioned one in which death was due to a fracture

¹ WELLINGTON'S *King's Coroner* (1905) and SMITH'S *Manual for Coroners* (1904) give some useful information upon this subject, especially concerning the English Coroner's Act of 1887.

² RICHARD HAKLUYT'S *Voiages*, 1589, vol. iii, p. 226; 1904, vol. viii, p. 247.

of the skull (1639) and another in which a man died from a bullet wound (1643).¹

DEFINITION.—A postmortem, autopsy, or necropsy is the systematic exposure and critical examination of the cadaver or carcass with the object of determining the cause of death or of studying morbid conditions in any of their various aspects. Other synonyms employed are necroscopy, mortopsy, section, *sectio cadaveris*, *sectio anatomica*, and *post* (colloquial). The German word *Obduction* means properly a medicolegal postmortem, which differs from an ordinary postmortem only in that the information thereby obtained is applied to furthering the ends of justice. The word "autopsy" was first used in the sense now generally accepted by v. Rühl, Crighton, and Bluhm, in their account of the examination of the body of the Empress Maria Feodorowna, of Russia.²

PURPOSE.—As the object of a post-mortem examination is the acquisition of exact data, the procedure should be carried out in a scientific and systematic manner. This is especially important in medicolegal cases, which frequently involve not only the reputation and liberty, but even the life of a human being. If the examination be performed in a perfunctory or desultory manner, some detail of the greatest importance may be overlooked, and the information obtained may be so insufficient as to be practically valueless for statistic or demonstrative purposes. In no other department of medical science are greater demands made upon the faculties of observation and discrimination, and in none other are sound knowledge and accurate work so indispensable. As the science of medicine advances, new discoveries necessitate a constant revision of the statistics of even the most common diseases. While it would seem to be quite needless to urge upon a physician the importance of performing post-mortem examinations, it is a fact that extremely few are made outside of hospitals, and even there necropsies are too frequently conducted without the supervision of a trained pathologist. It cannot be questioned, however, that the practitioner of medicine who improves his opportunities for pathologic study on the cadaver

¹ HOADLEY, *Proceedings Conn. Med. Soc.*, 1892, pp. 207-17, quoted by STEINER, *Johns Hopkins Bull.*, August, 1903. See also PACKARD, *Proceedings Phil. Path. Soc.*, January 1, 1900, p. 45; EDITORIAL, *Jr. Amer. Med. Assoc.*, October 28, 1893, p. 661.

² *Salzb. med.-chir. Ztg.*, 1829, vol. i, p. 107; FOSTER'S *Encyclopedic Med. Dict.*, vol. i, p. 516, quoting from KRAUS'S *Kritisch-etymologisches medicinisches Lexikon*.

will be a better diagnostician and safer therapist, will have a more enduring reputation, and will receive a greater pecuniary return than he who neglects such means of investigating morbid processes.

Opportunities for the study of physiologic structures offered by postmortems upon presumably healthy individuals killed by accident should not be neglected, as thorough familiarity with the normal appearance of the various organs and tissues is necessary to a recognition of morbid changes or slight variations from health. Such subjects also often afford favorable opportunities for the study of the earliest manifestations of disease, particularly of tumors and the infective granulomata. New anomalies also may be found, and these, as in the case of polydactylism, may be studied in order to support or disprove Mendel's and Galton's¹ laws of inheritance, etc.

Autopsies present exceptional opportunities for reviewing the study of anatomy or for investigating such subjects as anastomoses after amputation. They may also be employed for acquiring dexterity in surgical manipulations. To this end, it is permissible in suitable cases to practise surgical operations that entail no visible disfigurement of the body. Some of the more recently introduced procedures, such as decapsulation of the kidney, mechanical irritation of the hepatic peritoneum, transplantation of ovarian tissue, Lorenz's operation for congenital dislocation of the hip, Gersuny's injection of paraffin for the correction of deformities, Quincke's lumbar puncture, suturing a wound of the heart, total enucleation of the prostate, etc., will at once suggest themselves in this connection.

PERMISSION.—When a postmortem is desired, the first step in every instance is to secure the legal right to make it, either by order from a regularly-appointed officer of the law, or by consent (preferably written) from the next of kin to the deceased, or, in the absence of relatives, from the person in charge of the funeral. The feelings of relatives and friends must be fully respected; scientific zeal is no excuse for wounding them. In a suit for damages brought a few years ago against a Philadelphia hospital which had allowed a post-mortem to be made without the consent of the nearest relative, the Judge severely censured the institution for holding the autopsy, but held that no damages could be recovered, as the hospital was a charitable institution.

¹ *Natural Inheritance*, 1889.

The method to be pursued in gaining permission for the performance of an autopsy will depend largely upon circumstances, but tact will nearly always overcome sentimental objections and secure consent except when refused on account of religious scruples.¹ Thus, one resident in a hospital will obtain the opportunity for making a post-mortem examination upon almost every patient dying in the wards during his term of service, while another interne of the same institution will, for one reason or another, meet refusal in the great majority of his cases. Permission may often be obtained by arousing the curiosity of the relatives and friends, or by the humane plea that no harm will be done to the dead while possibly much good to the living may result. The author recalls a case in which those interested expressed great satisfaction on learning that death was not due to consumption, which had been diagnosed during life. An invitation to a member of the family to be present at the postmortem or a promise to make a death-mask (see page 305) will often secure the desired permission. The laity should be encouraged to ask for an autopsy. A carefully performed postmortem often secures ready consent to, or even a voluntary request for, others in the vicinity in which the physician resides. The blank forms which accompany insurance papers often contain the query, "Was an autopsy made?" and an affirmative answer greatly strengthens the holder's claim. Indeed, insurance companies should encourage the making of autopsies, as it is to their own pecuniary advantage so to do. Our Boards of Health, with their enormous power for good or evil, in some States have the legal right to compel the performance of postmortems, a prerogative that has already been advocated more warmly by the lay press than by the profession at large. Among the indigent foreigners who are so numerous in our large cities, the offer of a small sum of money will often secure permission to make a necropsy, but a threat to refer the case to the Coroner unless permission is voluntarily granted should never be employed. Undertakers who oppose the making of autopsies should not be recommended.

The pecuniary value that dead bodies may have sometimes gives rise to legal contests. The Supreme Court of California has decided that one cannot dispose of his own corpse by will. A man bequeathed

¹ See *Lancet*, January 13, 1906, p. 109, in regard to the attitude of the public towards post-mortem examinations.

his body to the managers of a medical college, in the hospital of which he had been treated, to be used for scientific purposes. The man's relatives claimed the cadaver, and applied to the courts for an injunction restraining the medical college from using it. The kinsfolk won, the Court holding that the custody of the corpse and the right of burial belong to the next of kin.¹ There are in America and in France several societies the members of which sign cards granting permission for the performance of postmortems on their bodies; in view of the above decision the card should be endorsed by the legal heirs, except in such States as New York, where Section 305 of the Penal Code provides that a person may dispose by will of his corpse as he may direct. Even when permission has been given circumstances may prevent an autopsy, as in the case of Phillips Brooks, who was a member of the American Anthropometric Society. The Prosecutor of the Society, on reaching Boston from Philadelphia, could not perform the postmortem, as death had been caused by diphtheria and the body had already been placed in an hermetically sealed coffin, in order that a public funeral might be held.

In the case of *Loesch vs. the Union Casualty and Surety Company*,² the Supreme Court of Missouri held that the making of the autopsy without previous notice to the Company was no bar to recovery. The physician making the examination and the mother of the deceased, who tacitly assented to its performance, were in ignorance of the clause in the policy providing that if a postmortem were held without due notice to the Company in time to have its medical adviser present, all claims under the policy should be forfeited. As soon as the error was discovered, which was in time for a re-examination, the Company was notified.

There should be a law permitting post-mortem examinations of the bodies of all persons dying in charitable institutions. Such a rule exists in the hospitals in Germany, and this custom prevailed for some time in the Philadelphia Hospital with practically no opposition, until lawsuits, arising out of this custom, caused it to be discontinued. In cadavers allotted to the Anatomical Board, care should be taken not to destroy the arteries commonly used for injection. If in the course of an autopsy conditions are found which indicate foul play,

¹ *Amer. Med.*, April 6, 1901, p. 37.

² *Jr. Amer. Med. Assoc.*, September 26, 1903, p. 805.

as serious traumatic injuries or the signs of a poison in toxic doses, the examination should be immediately suspended, and steps at once taken to have the Coroner or other legal officer take charge of the case; but if properly authorized by the Coroner or his legal representative, the examination may proceed in the manner prescribed for conducting medicolegal postmortems.

When portions of the body are desired for future study or for preservation, permission to remove them should be obtained from some one connected with the household, though not necessarily from the nearest relative; it is, of course, unnecessary to tell how much is to be taken away! Should the person authorizing the autopsy forbid the removal of any portion of the body from the house, no specimens should be taken. Consent can nearly always be obtained for the removal of small pieces of tissue for microscopic purposes, even when permission to take away larger specimens is refused.¹ In the necropsy on the body of President McKinley, the bullet which produced the fatal wound was not found, because a member of the family objected, though without legal right, to the search, and it was only with the greatest difficulty that consent was obtained to remove portions of the body for microscopic study. In France the law forbids the extraction in legal cases of teeth *post mortem* without special administrative authorization. (Letulle.) The careless handling of specimens removed at autopsies, especially those containing pathogenic organisms, as well as the culture of the more virulent bacteria in our laboratories, are sources of danger to the public that will no doubt evoke legislative restrictions in the near future. For the protection of their patients, residents on duty in the surgical and gynæcological wards of our hospitals should be forbidden to make or even to be present at autopsies.

THOSE PRESENT.—To one who makes many autopsies, a capable assistant and a trained attendant are invaluable. Knowing their duties, they anticipate what is required of them. In order to familiarize an assistant with a proper method of procedure, it is a good plan, except in important cases, for the experienced pathologist to play at times the part of an assistant by permitting the learner to perform the autopsy. Professional friends, especially those who saw

¹ In the case of *Winkler vs. Hawkes* the Supreme Court of Iowa held that consent for an autopsy being given, permission is implied for removal of the organs for microscopic study, if such be necessary to effect the purpose of the postmortem.

the patient during life, should be invited to be present at the autopsy; the scrutiny of critical eyes undoubtedly ensures more careful work. Besides, in medicolegal cases the responsibility of making an autopsy in which the evidence obtained may be sufficient to convict a person of the gravest of crimes is often too great to be borne alone. Before work is begun, the relatives and friends should be tactfully requested to withdraw from the sight, smells, and sounds of the postmortem. The nurse should be within calling distance, and the undertaker or his assistant should remain, as he can often render valuable aid. While those present are prone to give advice that is useless, the suggestions made by them are frequently of great value. Courtesy demands that a guest should not be too forward in offering advice, but should always be ready to render such assistance as the operator may need or request, for the one making the autopsy is in command and is alone responsible for the success or failure of the work entrusted to him. The desire of those present to handle the specimens is natural, though this should not be done until the notes have been dictated and portions removed for microscopic study. While witnessing the performance of a score or more of postmortems in Vienna during the summer of 1905, the writer was greatly impressed with the difficulty of securing a proper interpretation of the morbid lesions present without handling the specimens himself. Letulle lays great stress upon the prohibition of smoking during the performance of the postmortem.

TIME.—The time allowed to elapse after death before making an autopsy depends upon the circumstances of the case, and may vary from a few minutes to several days or even months. The examination should never be deferred longer than is absolutely necessary, as the entire cadaver is soon invaded by bacteria, and nuclear figures and cellular elements quickly lose much of their value for microscopic study. But the feeling of warmth imparted to the hands of the operator while making a necropsy soon after death, especially where there is much elevation of the temperature of the cadaver, as in fatal cases of heat-exhaustion or atropine poisoning, is so repugnant to one's sensibilities that sufficient time should always be allowed for the temperature of the corpse to fall to a point inconsistent with suspended animation. In New York State a postmortem must immediately follow a legal electrocution; it is popularly believed that in at least one case the criminal was not killed by the electric current. The suit brought in the case of Bishop, the so-called mind-reader and cataleptic,

where the necropsy was made immediately after death, will also be recalled. The law in Germany is that at least twenty-four hours should elapse between death and the autopsy.

The time required for the completion of a postmortem depends, of course, upon the conditions under which it is performed, upon the nature of the case, and upon the skill of the operator. Under favorable circumstances the author has removed the brain in less than three minutes from the time of making the preliminary incision, and has made an entire post-mortem examination, including the removal of the cord, in less than nineteen minutes. On the other hand, eight hours of uninterrupted work have been consumed by him in the performance of one autopsy. In a hospital the time usually allowed for a necropsy is about an hour and a half. Virchow considered that three hours' work was ordinarily sufficient to complete a medicolegal postmortem according to the Prussian regulations given in Chapter XXIX, and that in certain cases this time might be reduced by one-third. It is stated that Rokitansky¹ performed over thirty thousand autopsies, which would average scarcely an hour each. Kolisko, of Vienna, sometimes made five or six postmortems in a morning, and the author himself has more than once performed ten within twenty-four hours. Owing to lack of time, the surgeon or clinician may wish the necropsy to be made with more celerity than is consistent with thoroughness. As he often merely desires to ascertain a certain fact or to observe a single organ, he can generally be immediately accommodated, and the examination may be afterwards completed in the routine manner. The performance of the autopsy may take but a short time in comparison with that required for the proper preparation and study of the tissues. Indeed, the collection and preservation of material for future investigation by the microscopist, chemist, experimentalist, and bacteriologist are often the most important parts of the process, for an error made at the postmortem may be irremediable later on. As Virchow aptly said, "A postmortem does not admit of repetition, whereas in a clinical examination at the bedside any omission may ordinarily be rectified at a subsequent visit."

PLACE.—The place at which a post-mortem examination is to be made is rarely a matter of choice, especially in private practice, but

¹ Preface to the Sydenham Society's translation of CARL FREIHERR VON ROKITANSKY'S *Pathologische Anatomie*.

it should always be where the best light is obtainable. Daylight from the north, such as is sought by artists, should be preferred. If the autopsy must be made after dark, a combination of the electric and Welsbach lights is the most satisfactory artificial illuminant. Orth states that a good substitute for daylight may be obtained by allowing the artificial light to pass through a glass flask containing water slightly colored with methylen blue. Such a flask may be used also as a condenser to concentrate the rays of light upon the surface under examination. In Manchester, England, where the days are so often dark, textile workers adopt various expedients to get true color values; one of these consists in having the artificial light pass through specially colored glass. That one should accustom himself to the changes of color produced by different kinds of artificial light was well shown in one of the author's autopsies made by gaslight on a subject of poisoning by battery-fluid: the tissues stained with potassium bichromate presented an entirely different appearance when examined by daylight the next morning.

Time and labor will, of course, be spared by making the autopsy before the body is dressed for interment, and the undertaker should be directed to defer embalming it until after the completion of the examination. The fact that the appearance of the exposed parts is improved by the loss of blood and by its gravitation into the larger cavities of the body as a consequence of the section may be indeed mentioned to him as an argument in favor of the procedure. Fortunately, the formalin injecting-fluid now generally employed for embalming purposes does not interfere with the microscopic study of tissues as did the arsenical preparation formerly used. Indeed, one of the special methods for hardening the brain is based on its previous injection with formalin by means of a cannula introduced through the orbit or nasal cavities.

The amount of preparation necessary for an autopsy will depend somewhat on whether the examination is to be made (I) in a private house or at an undertaker's establishment, or (II) in a hospital or morgue.

I. In the former case a table on which to lay the cadaver is rarely available, and a substitute must be provided. There are in the market several portable operating-tables¹ which may be used for this purpose.

¹ SHERMAN, *Amer. Med.*, October 26, 1901, p. 644. Illustration from *Internat. Clinics*, 1902, vol. 1, Twelfth series.

as the one shown in Fig. 1. The postmortem may be performed while the body lies in the coffin, on the coffin-lid, or, still better, on the bottom of the inverted coffin, on the wooden slab usually found in the box, or on a door taken from its hinges and placed upon two kitchen chairs. The undertaker may have prepared the corpse for the autopsy, as seen in Fig. 2. For the body of a child the marble top of a bureau or wash-stand placed on the backs of chairs may be used. (Fig. 3.)

To facilitate the necessary manipulations, the cadaver must lie at a proper height. If placed too low, fatiguing work in the stooping position is necessitated. A piece of oil-cloth, mackintosh, or old carpet should be placed under the table or its substitute, to prevent soiling the floor. In addition to the articles brought by the operator (see page 42), two buckets half filled with lukewarm water, an empty basin, and several newspapers should be provided.

Scrupulous cleanliness in the performance of an autopsy is of the greatest importance. The reasons for this are apparent. We owe it to our fellow-men to leave no malignant organisms in the place where the postmortem was performed. Besides, the pathologist can see better and his sense of touch is finer if the organs, fingers, and rubber gloves are not besmeared.

If the operator be careful not to soil his own person, the surrounding objects will be more likely to escape contamination. For this reason, he may accustom himself in private work to make necropsies in non-contagious cases with but little protection to his clothing. In France the usual dress consists of a hospital blouse, overalls of homespun, an apron reaching to the feet, and a pair of sabots or wooden shoes. In our hospitals the regulation duck trousers, shirt-sleeves, bare arms, rubber gloves, and an apron are most frequently seen. There should be a bountiful supply of water, a basin for the hands, and a board on which to arrange the instruments. The parts under examination should be cleansed as occasion requires by a stream of water squeezed from a sponge, the sponge itself not being permitted to touch the tissues. Mucous and serous surfaces should always be carefully inspected before washing.

In private work the laity are likely to estimate the skill of the pathologist by the neatness displayed in sewing up the body and the appearance of the room after the autopsy is completed. The greatest care should be exercised that no blood-stains be left behind.




FIG. 1.—Portable post-mortem table. 1, closed; 2, open; 3, packed in bag; 4, elevated position for removal of brain. Before use the coffin-lid may be laid on the table, and the body placed thereon. With but slight increase in weight, the top of the table may be made solid. An English portable operating table is described in the *Lancet*, April 29, 1905; cost, about \$8.00. The floor should be protected by rubber sheeting, an old piece of carpet, or other suitable means.



FIG. 2.—Body in a coffin prepared for a post-mortem examination. In this case the board supporting the body is elevated by means of a soap-box, there being no ratchets or pins to support the body as are so often found in modern ice-boxes.




FIG. 3.—Post-mortem table for a babe, constructed of chairs and a drawing-board; the marble slab from a wash-stand or bureau may be used for the same purpose.




FIG. 4.—Post-mortem room of the Ayer Clinical Laboratory of the Pennsylvania Hospital of Philadelphia.



FIG. 5.—Refrigerator box for the preservation of nine bodies, with scales so arranged as to weigh the corpse while it is in the refrigerator, if placed in the lower compartment next to the scales.

Incense or cascarilla may be burned or ground coffee strewn on red-hot coals to remove the odor from the apartment, which should then be thoroughly aired.

II. In a hospital or morgue the facilities for making postmortems are much more complete. The room set apart for this purpose should be clean, well lighted, and secure against intrusion. The author remembers once having seen, much to his annoyance, a number of convalescents in the grounds of a hospital watching the performance of an autopsy through an open window. If practicable, the dead-house should communicate by an underground passage with all the wards of the hospital, and a covered or screened court for the undertaker's wagon should also be provided. A well-appointed mortuary room, like the one at the Ayer Clinical Laboratory of the Pennsylvania Hospital (Fig. 4), should have a refrigerator box with scales so arranged that bodies can be weighed within it. At the author's suggestion, the Fairbanks Scale Company fitted one of their scales to a Ridgeway refrigerator for this laboratory (Fig. 5), in such a way that the cadaver could be weighed while in the ice-chest and the result noted without opening the doors. (For structural plans see Figs. 6, 7, and 8.) The corpse should be weighed as soon as it is brought into the dead-house, as it will usually be found to lose weight after a time. Each box should have two doors, one opening into the post-mortem room, and the other into a waiting-room on the opposite side, through which the body may be viewed by friends and removed by the undertaker. This arrangement also prevents the transmission of noises and odors. In case there are several tiers, the ingenious device in use in the Massachusetts General Hospital may be employed (Fig. 9). The waiting-room ought also to be so arranged that religious services may be held in it, if desired.

The operating-table should be strongly built, about seven feet long, two feet nine inches high, and three feet six inches wide. The top may be of slate, soapstone, zinc, or copper; its surface should slope gently towards a central perforated depression connected with a drain and a ventilating shaft operated by an electric fan, and should be provided with sunken grooves converging towards the centre. (Figs. 10 and 11.) The drains of the post-mortem room should not connect with those of the hospital, but empty directly into the main sewer. An ideal though expensive plan would be to sterilize all the waste water. A scale of feet, inches, and fractional parts of an inch (or of centi-

metres) should be laid off on the top of the table, or, if this be of slate, upon a metal rule sunk into it in such a way that no edges are exposed. For class instruction, a revolving table is required, preferably one upon which by an ingenious fulcrum and lever attachment the body can be weighed. An extra iron table like those used in the dissecting-room may be provided, in case it is desired to conduct two autopsies at once. The making of several necropsies simultaneously was discontinued in one Philadelphia hospital owing to the fact that

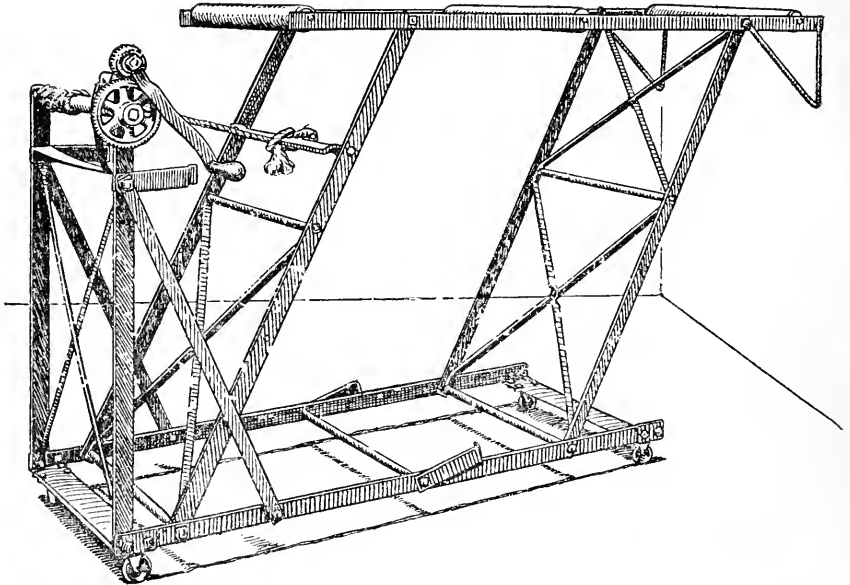


FIG. 9.—Movable table for transporting bodies, in use at the morgue of the Clinico-pathological Laboratory of the Massachusetts General Hospital. The top may be elevated or depressed to a level of the upper or lower tiers of the ice-chest or the table upon which the post-mortem examination is to be made. Designed by Mr. Francis Blake; Drawn from a photograph by L. S. Brown; Illustration secured through the kindness of Drs. Mallory and Wright.

three livers were found in a body subsequently exhumed on account of suspected poisoning. Additional tables, upon which to place instruments, scales, plates, and other requisites, should also be at hand.

Ample illumination should be provided by a northern skylight, if possible, by day, and by a combination gaslight and electric-light fixture directly over the table (Figs. 12 and 13) by night. A good modification of the greenish blue Peter Cooper Hewitt light was shown during December, 1905, at the New York Electrical Exhibition in Madison Square Garden. In strength it is said to exceed the

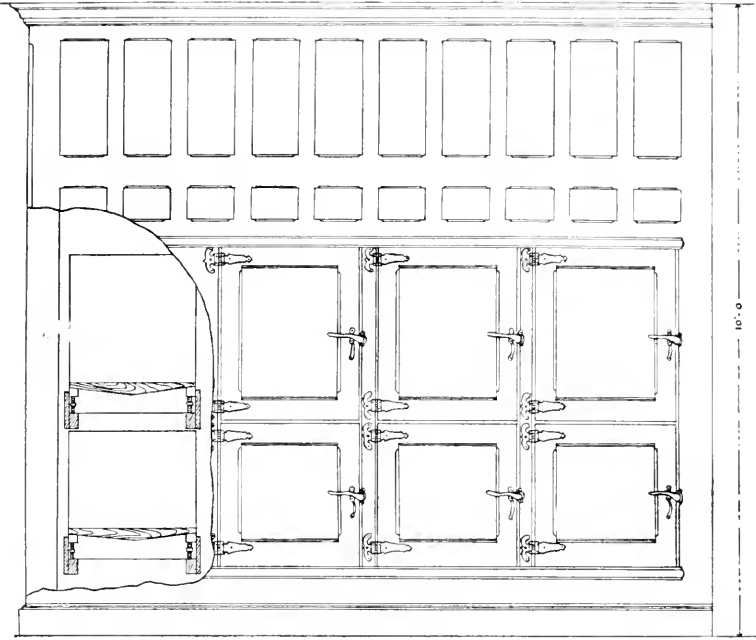


FIG. 6.—Working plans for preparing refrigerator with eight compartments for the storage of bodies preparatory to their removal for burial. Front view.

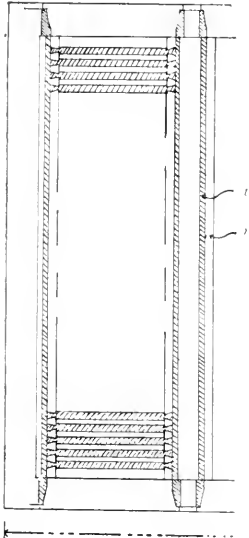


FIG. 7.—Ground plan for a truck.
a, guide; b, track.

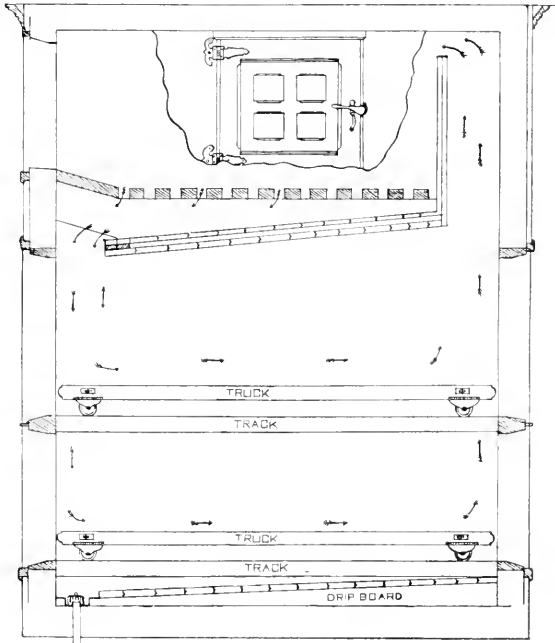


FIG. 8.—Cross-section.

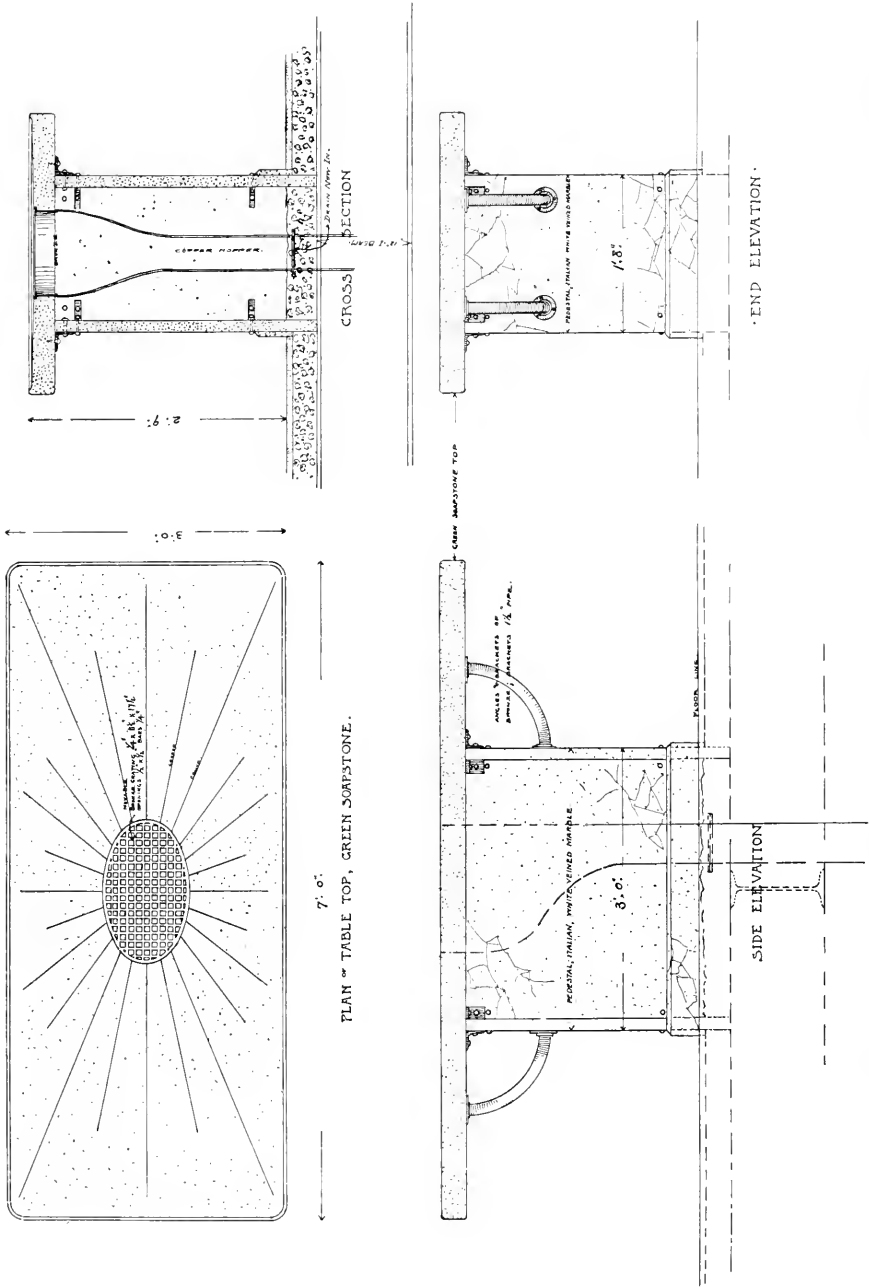


FIG. 10.—Plans prepared for the writer by Mr. Addison Hutton for a post-mortem table at the Ayer Clinical Laboratory. (See also Fig. 11.)

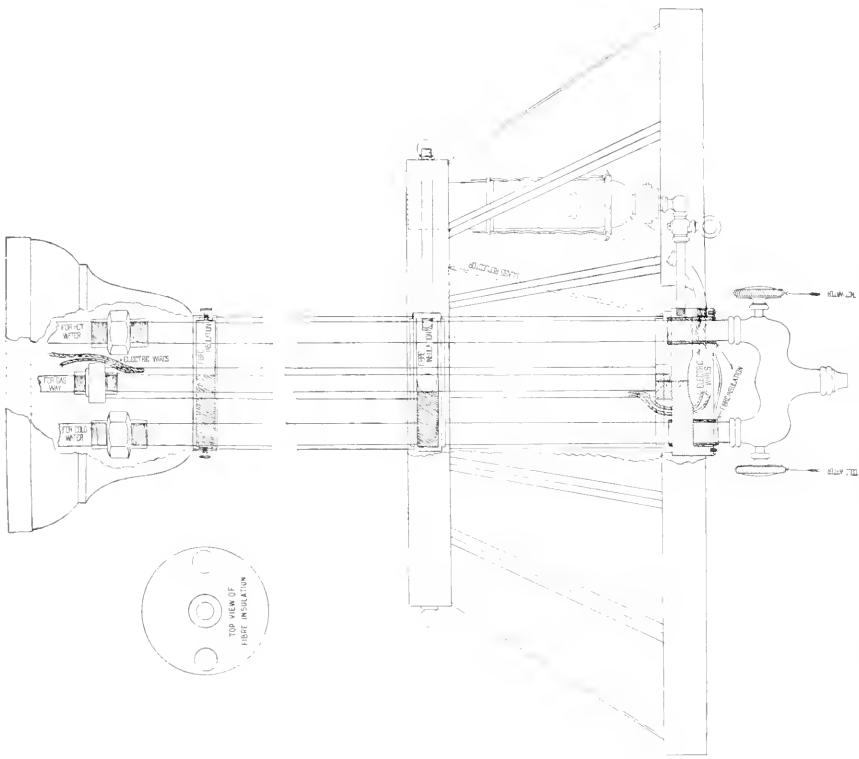


FIG. 12.—Working plan for combination electric, gas, and water fixture above post-mortem table, prepared for the Ayer Clinical Laboratory.

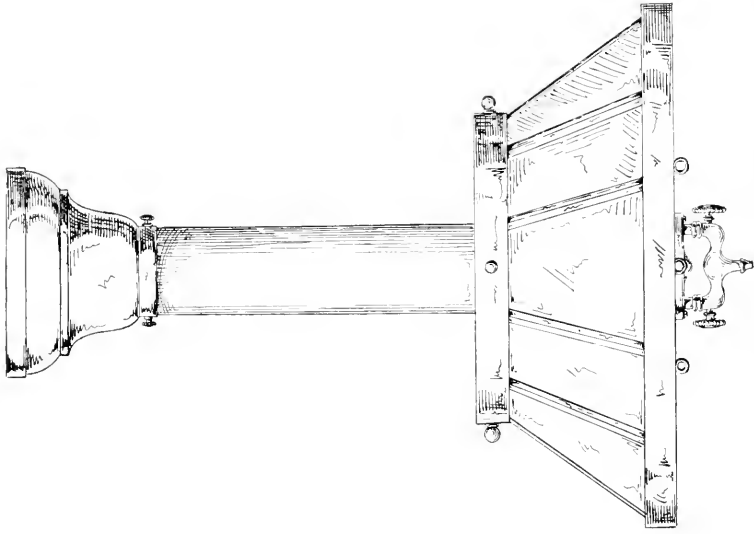


FIG. 13.—Combination electric, gas, and water fixture to be placed above post-mortem table.

ordinary electric light twenty-five fold and not to cause any discomfort to the eyes. Krönig and Siedentopf¹ recommend a shaft of reflected light from a lantern outside of the room projected through an opening in the wall so that it strikes a mirror in the ceiling above and is reflected down upon the table. By this device specimens may be photographed *in situ*. Plenty of water, hot and cold, should be supplied by means of an overhead spigot with rubber tubing attached, so that by the use of a mixer a steady stream of water at any required temperature may at once be had wherever directed.

To support the head there should be a solid block or rest similar to those used by undertakers. This block should be about forty centimetres long, twenty centimetres high, ten centimetres broad, and hollowed out on top to receive the nape of the neck. For children smaller sizes are employed. (See Figs. 58, 126, 127, and 128.)

A board upon which the viscera may be placed after their removal, for convenience in making sections, etc., should also be at hand, as the table top becomes slippery from exuded fluid and the organs are held with difficulty while being incised. It is the custom abroad to set a stool upon which instruments are arranged over the upper end of the thighs within easy reach of the operator. To avoid the spattering of dripping fluids when opening the cranium, a piece of previously moistened horse-blanket or a mop may be placed on the floor beneath the head. The operator, if subject to rheumatism, should stand on a piece of dry board rather than on the cement or tile floor usually found in mortuaries. The latticed wood flooring found on ships is well adapted to this purpose. The lavatories should preferably be the surgical kind operated by the feet or the elbows. All linen, towels, etc., used in the dead-house ought to bear some distinguishing mark, and should be put at once into a proper disinfectant, or sterilized apart from the other wash of the hospital.

A desk for the post-mortem book, a revolving chair, a slop-sink, a wash-stand, several cabinets, a work-table supplied with ordinary chemicals, a bacteriologic outfit, preservative fluids, and apparatus for preparing frozen sections complete the furniture of a well-equipped mortuary. Frozen sections add greatly to the interest and value of an autopsy by enabling the operator to compare the microscopic and macroscopic appearances of a part while it is still in a fresh state. A library and a museum should be attached to the dead-house.

¹ *Arch. f. klin. Chir.*, 1904, vol. lxxiv, no. 2, p. 373.

CHAPTER II

ORDER OF EXAMINATION AND POST-MORTEM RECORDS

As precision, supplemented by a simple, cleanly technic, is the keynote for a successful autopsy, the following rules should govern the removal and opening of organs at every post-mortem examination when it is possible so to do.

I. *Never disturb any part or organ until its position relative to adjacent tissues and organs has been accurately determined.*

II. *Never unnecessarily remove a part or organ if the proper inspection of remaining parts or organs will thereby be rendered difficult or impossible.*

III. *When an organ is to be opened in order to examine its cavities, walls, or component parts, the requisite incisions should be made in such a way as to permit, as far as possible, of the reconstruction of the organ in its original shape and condition.*

In the fulfilment of these conditions it is, therefore, best to begin by making a topographic examination of the contents of the cavity about to be explored. In the case of the trunk, the organs of the abdominal cavity are inspected first, those of the thorax next, and those of the pericardium last, whereas the removal of the organs and their minute description should be made in the reverse order. The abdomen should be examined before the thorax is opened, in order that the position of the diaphragm and the relative situations of the various abdominal organs can be determined before the entrance of air into the relaxed thoracic walls has altered the normal relationship, before the heart has been emptied of its blood by cutting the abdominal veins, and before the escape of blood and other liquids has obscured the appearances of the parts under consideration.

In order that nothing of importance shall be overlooked, the pathologist should have a definite plan of survey that he follows at every autopsy. The following order of examination is recommended:¹

1. Inspection of the exterior of the body: (a) Signs of death; (b) Body heat; (c) Hypostatic congestion; (d) Rigor mortis; (e) Build and nutrition;

¹Virchow's routine method of performing a postmortem is given in Chapter XXIX.

(*f*) Anomalies; (*g*) Deformities, including scars; (*h*) Signs of trauma, including surgical wounds; (*i*) Signs of disease; (*j*) Skin; (*k*) Hair; (*l*) Eyes; (*m*) Nose; (*n*) Ears; (*o*) Mouth, including teeth; (*p*) Nails; (*q*) Breasts; (*r*) Umbilicus; (*s*) External genitalia, including the vagina in the female; (*t*) Anus; (*u*) Buttocks; (*v*) Other portions of the body.

2. Topographic exploration of the abdominal cavity,¹ especial attention being directed to the situation of the organs contained therein, to the height of the diaphragm, to the peritoneum, to hernia, etc., and to the consideration of any modification to be made later on in the usual plan of procedure due to the presence of pathologic lesions or of anomalies.

3. Examination of the breasts (from behind); Mediastinum; Thymus; Thyroid; Parathyroids; Carotid glands; Cervical and salivary glands; Entrance of the thoracic duct into the subclavian vein.

4. Topographic exploration of the pleural cavities.²

5. Pericardium and subserous adipose tissue; Pneumogastrics; Arch of the aorta; Vena cava; Cardiac plexuses.

6. Heart (external and internal examination of each cavity in the direction of the blood-currents): (*a*) Papillary muscle; (*b*) Chordæ tendineæ; (*c*) Trabeculæ; (*d*) Endocardium; (*e*) Valves; (*f*) Blood-vessels; (*g*) Lymphatics. Coronary arteries.

7. Lungs:³ (*a*) Pleura; (*b*) Lymph-glands; (*c*) Lobes; (*d*) Lobules; (*e*) Alveoli; (*f*) Bronchi; (*g*) Blood-vessels. Pulmonary vessels. Trachea. Larynx.

8. Mouth and Pharynx: Tongue; Palate; Tonsils, etc.; Epiglottis; External examination of the œsophagus.

9. Omentum; mesentery; and other portions of the peritoneum, especial attention being paid to enlarged glands.

10. Spleen: (*a*) Capsule; (*b*) Follicles; (*c*) Pulp; (*d*) Trabeculæ; (*e*) Blood-vessels.

11. Intestines (except the duodenum); Appendix vermiformis; Rectum.

12. Adrenal body: (*a*) Cortical substance; (*b*) Intermediary substances; (*c*) Medulla; (*d*) Vessels; (*e*) Nerves. Splanchnics. Semilunar ganglion. Kidney: (*a*) Capsule; (*b*) Cortex; (*c*) Medulla; (*d*) Pyramids; (*e*) Papilla; (*f*) Pelvis; (*g*) Blood-vessels.

13. Ureters and bladder.

14. In the male: Penis; Urethra; Scrotum; Testicles; Epididymis; Prostate; Spermatic cord; Seminal vesicles, etc. In the female: Uterus; Tubes; Ovaries; Broad ligaments; Vessels; Urethra, etc.

15. Duodenum; Common duct, with its branches going to the liver and the pancreas.

¹The organs are not incised at this time nor are their relations markedly disturbed. In the Rokitsansky or Vienna technic the organs are incised as they are brought to the surface.

²While the heart is being examined time may be saved by having an assistant open the skull, as, theoretically, the heart should be exposed before the head is opened and the brain inspected before the heart is incised.

³The pleural cavities, already superficially examined, are now to be more carefully inspected after the removal of each lung.

16. Stomach: (*a*) Mucosa; (*b*) Submucosa; (*c*) Muscularis; (*d*) Serosa. Esophagus.
17. Liver: (*a*) Capsule; (*b*) Acini; (*c*) Blood-vessels; (*d*) Bile-ducts. Gall-bladder. Portal vessels.
18. Pancreas: (*a*) Acini; (*b*) Blood-vessels; (*c*) Smaller ramifications of the pancreatic duct; (*d*) Adjacent fat. Mesentery.
19. Retroperitoneal glands; Diaphragm; Psoas muscle; Thoracic duct; Thoracic and abdominal aortæ; Inferior vena cava; Abdominal sympathetics; Abdominal portion of the spermatic duct, etc.
20. Head: (1) Scalp; periosteum; and calvarium. (2) Meninges: (*a*) Dura; Longitudinal sinus; (*b*) Arachnoid; (*c*) Pia; Pacchionian granulations; Basal sinuses; Vessels and Nerves; Cerebrum—(*a*) White and gray matter, (*b*) Blood-vessels; Ventricles; Pineal gland; Cerebral ganglia; Peduncles; Cerebellum; Pons; Medulla. (3) Pituitary body. (4) Eye. (5) Ear. (6) Nasopharyngeal cavities. (7) Salivary glands. (8) Region of face and neck.
21. Vertebral column; Spinal cord and its membranes:¹ (*a*) White and gray matter; (*b*) Central canal; (*c*) Nerves; (*d*) Blood-vessels.
22. Bones; Marrow; Joints: (*a*) Fluid, (*b*) Blood-vessels. Peripheral nerves, Sympathetics, Lymph-nodes, Arterial trunks of the extremities, Muscles, Tendons, etc.
23. Portions preserved.
24. Bacteriologic, photographic, microscopic, chemic, and physiologic examinations.²

As a general rule, the order above suggested will be found convenient and practical. It must, of necessity, be subject to more or less variation, depending on the circumstances of the case. For example, in a medicolegal necropsy it is often advantageous to examine the seat of the suspected fatal lesion at once, and afterwards resume the order given above as nearly as possible. Thus, after death by poison the abdominal cavity is immediately inspected, while in a case of gunshot wound of the head the cephalic cavity is first investigated. The finding of anomalies, malformations, adhesions, etc., or the necessity of undertaking special lines of investigation may also cause a departure from the ordinary procedure. Thus, in autopsies on the remains of those who have died from nervous diseases it is often best to remove the brain and cord before opening the body.

The same order of examination as that given above may be followed out with advantage in the case of postmortems upon the lower animals. In Chapter XXV, devoted to the discussion of this subject, the order of procedure recommended by Kitt will be found.

¹ For sake of cleanliness the spinal cord may often best be removed first at an autopsy.

² Should the case subsequently be published, due reference to this fact should be made upon the notes.

Letulle advises, as a routine practice, that the thoracic and abdominal organs be removed *en masse* from the body, and first examined from their posterior aspect, as follows: ¹

(1) Large, or right, and small, or left lower, azygos veins. (2) Thoracic duct (dissection). (3) Suprarenal glands (dissection and removal). (4) Ureters (dissection). (5) Kidneys and their pelves (dissection and removal). (6) Thoraco-abdominal aorta (opened). (7) Inferior vena cava (opened). (8) Main portion of the portal vein and its branches of origin. (9) Common bile duct and its two canals of origin. (10) Pancreas (dissection of posterior surface, tail, and borders). (11) Removal of the thoraco-abdominal aorta. (12) Dissection of the œsophagus to its point of entrance into the stomach. (13) Organs of mouth and pharynx: (a) incision of the pharynx; (b) dissection of the velum palati; (c) tonsils; (d) tongue; (e) sublingual glands. (14) Incision of the œsophagus at its point of origin. (15) Epiglottis and larynx (examination and opening). (16) Trachea and primitive bronchi. (17) Pulmonary roots (examination). (18) Lymphatic glands of the posterior region of the body (deep cervical, posterior mediastinal, diaphragmatic, prelumbar, retrorectal). (19) Cervicothoracic portion of the pneumogastric nerves.

After the posterior examination is completed, the parts are turned so that their anterior aspect comes into view. In doing this care is to be taken that the attachments are not twisted on their axes. The following examination from the anterior surface is then made:

(1) Thymus gland (examination and removal). (2) Thyroid gland (dissection and removal). (3) Opening of the superior vena cava and its branches of origin. (4) Study of the termination of the thoracic duct and the great lymphatic vein. (5) Pericardium (inspection and opening of). (6) Examination of the cardiac plexus. (7) Dissection of arch of the aorta and the thoracic aorta down to the seventh costal artery. (8) Pulmonary artery and its extrapulmonary branches (separation and opening of). (9) Pulmonary veins, extrapulmonary portion (separation and opening of). (10) Hilum of the lung (examination). (11) Examination of the exterior of the heart. (12) Removal of the heart. (13) Removal of the lungs. (14) Diaphragm (examination). (15) Liver and extrahepatic biliary ducts (examination and removal). (16) External examination and separation of spleen, stomach, pancreas, and duodenum. (17) Removal of œsophagus, stomach, pancreas, and duodenum. (18) Exterior examination, dissection, and removal of intestinal canal, with the exception of the rectum: (a) small intestine, (b) cæcum, (c) vermiform appendix, (d) colon, (e) rectum, (f) anus. (19) Examination of the peritoneum: (a) mesentery, (b) omentum, and (c) parietal peritoneum; (d) pelvic cavity. (20) Urinary apparatus (separation and examination of): (a) kidneys; (b) ureters; (c) bladder; (d) urethra. (21) Genital organs: (a) prostate, vesiculæ seminales, vasa deferentia, and testicles; (b) oviducts, broad ligaments, ovaries, vulva, vagina, and uterus.

¹This mode of procedure presents greater advantages in a child than in an adult, as in finding the ductus Botalli and in tracing a diphtheritic exudate in the air-passages.

PENNSYLVANIA HOSPITAL.

POST-MORTEM RECORDS OF THE AYER CLINICAL LABORATORY.

Autopsy number,									
Hospital number,									
Name,									
Occupation,									
Died,									
Weather,									
Permission given by									

PATHOLOGICAL DIAGNOSES.

REMARKS.

¹ This should always be entered before the beginning of the autopsy, and if there is any doubt as to the clinical diagnosis of the cause of death, such doubt should be stated, and the most likely cause written first.

In post-mortem books prepared for hospital records it is advantageous to have some data printed at the top of each page if the book be a large one or at the top of the left-hand page alone if the book be less than ten by fifteen inches, so as to afford ample room for notes. In my service at the Pennsylvania Hospital I used the form given on the opposite page.

The routine order of examination to be employed in the making of the autopsy, as given on page 14, may then follow, or a card showing this order may be displayed in such a manner as readily to be seen by the one making the autopsy and the person to whom the notes are being dictated. Figures corresponding to the numbers of the divisions in the list may then be placed just before the notes describing the lesions to be sought for in the parts under examination.

Many writers advise the use of more or less elaborate printed descriptions of the various anatomic regions and organs, with blank spaces to be filled in at the time of making the autopsy. Printed books and forms for this purpose are to be found on the market,¹ especially in England. This method of keeping notes has not in my hands yielded as satisfactory results as the one just described. I give, however, the following example of a post-mortem record, which was prepared in 1890 by Dr. Formad and myself and was in use for a number of years at the Philadelphia Hospital. The opposite (right-hand) page contained no printed matter, and could be used for more extensive descriptions or for the dictated record of the entire autopsy.

¹The best one in America is WARTHIN'S *Blank-Book for Autopsy-Protocols*, published by George Wahr, Ann Arbor, Mich. It contains room for the recording of ten autopsies.

BLOCKLEY ALMHOUSE,
PHILADELPHIA HOSPITAL—POST-MORTEM RECORD.

No. of Autopsy, _____
 Name, _____
 Ward, _____
 Admitted _____, Died _____, 190 _____
 History of { Alcoholism, Syphilis, Consumption, Injury. }
 Date of Autopsy, _____
 Sex, _____
 Age, _____
 Nationality, _____
 Occupation, _____
 Color, _____
 Address, _____
 { Married, Single. }
 hours after death. _____
 Weather, { Cold, Hot, }
 Attending Physician, _____
 Resident Physician, _____
 Performed by _____

Cause of Death, _____
 Weight of Body, _____ lbs., _____
 Height, { Wounds, Bruises, }
I. EXTERNAL APPEARANCES.—Condition of Nutrition, _____
 Eruptions, _____
 Appearance of Skin, _____
 Deformities, _____
 Rigor Mortis, _____
 Decomposition, _____
 P. M. Lividity, _____
 Color, { Quantity, Soft and thin, Hard and thick, }
II. HEAD.—Scalp, _____
 Skull—size, _____
 Fluid in Cranium, amount, _____
 Dura Mater.— _____
 Sinuses, quantity of blood, _____
Pia Mater.— _____
 Surface of Hemispheres, _____
Brain.—Weight, _____
 Ventricles,—Size, _____
 Softening, _____
 Base of Skull after removing Dura, _____
III. SPINE.—Deformities of Spinal Column, _____
IV. THORAX and Neck.— _____
 Tongue, _____
 Larynx, _____
Lungs.— _____
 Left Lung, _____
 Right Lung, _____
 Lesion, _____

Other Peculiarities, _____
 Injuries, _____
 Injuries, _____
 Character, _____
 Color, _____
 Thrombi, _____
 Vascularity, _____
 Condition of Convulsions, { Flattened, Asymmetrical, }
 Color, _____
 Contents, _____
 Lateral Vs., _____
 Blood-Clots, _____
 Consistency of Substance, _____
 Fluid, _____
 Ounces ; _____
 Consistency of Substance, _____
 Lateral Vs., _____
 Blood-Clots, _____
 Cord, { Examined, Not examined, }
 Pharynx, _____
 Trachea, _____
 Glands, _____
 Upper Lobe, _____
 Lower Lobe, _____
 Upper Lobe, _____
 Middle Lobe, _____
 Lower Lobe, _____
 Pleural Cavities.— _____
 Left, Adhesions, _____
 Effusion, _____
 Right, Adhesions, _____
 Effusion, _____
 { Mediastinal Glands, Bronchial }
 Tonsils, _____
 Membranes, _____
 Thyroid, _____
 Areas of Degeneration, _____
 Tumors, _____
 Other Lesions, _____
 Color, _____
 Thymsus, _____
 { Clear, Purulent, }
 Blood, _____
 Adherent to Calvarium, _____

Heart. —Size, Pericardium—Adhesions, Heart opened <i>in Situ</i> shows Blood, { Fluid, } Ounces, Shape, { Globular, } Hypertrophy of Cardiac Walls, Atrophy of Cardiac Walls, Valves and Orifices, { Chronic, } Valvulitis, { Acute, } Calcification,	Position, Clots, { Red, } Effusions, Quantity, Left Sided, Dilatation, Aortic, Atheroma,	Character, Left, Right Side, Right Sided, Tricuspid Valve, Coronary Vessels, Aneurism, Position of Diaphragm,
V. GENITO-URINARY TRACT. — Kidneys.—Weight—Left, Lesion, Suprarenal Bodies, Bladder, Uterus,	Right, Ounces, { Color, } Thickness of Wall, Ovaries, Peritoneum, Color, Cut Surface, Gall-Stones,	{ Cysts, } { Capsule, } { Surface, } Ureters, Prostate, Testicles, Adhesions, Surface, Color of Bile,
VI. ABDOMEN. —Position of the Organs, Liver.—Weight, Edges, Gall-Bladder and Ducts, Lesion, Pancreas.— Spleen.— Stomach.—Size, Congestion, Lesion, Small Intestines.— Vermiform Appendix, { Empty, } Hernia, Large Intestines and Rectum.— Constrictions, Other Organs.—	Ounces, Size, Ounces, Mucous Membrane, Ulcers, Catarrhal Condition, Parasites, Intussusception, Dysentery, Hemorrhoids,	Peritoneal Lymph Glands, Esophagus, Duodenal Ulcer, Contents, Obstruction, Volvulus, Contents, Thickness, Cancer,

Specimens Preserved in Museum.—No.

PROTOCOLS OF AUTOPSIES IN THE UNITED STATES ARMY, NAVY, AND PUBLIC HEALTH AND MARINE-HOSPITAL SERVICE.—In investigating the methods which obtain in the three public services in regard to the performance of autopsies one is forcibly impressed with the fact that there is no uniform method of making post-mortem examinations and of recording the pathologic conditions observed.¹ With authority thoroughly to investigate the cause of death in practically all cases which die in service, it will be readily seen what a vast wealth of material is rendered practically valueless for comparative study through their lack of coördination. It must be thoroughly understood, however, that the author appreciates the fact that the amount of work in these services is exceedingly large, and that he does not desire to suggest anything which will still further complicate matters. If some regular form, as that suggested on page 14, could be officially adopted the advantages accruing to the medical profession at large become apparent, especially when one realizes the large amount of tropical work the public services are performing at the present time. In the Army an endeavor is made on the part of medical officers to conform to the outline given in the first edition of this book. This is not compulsory, however. The officer in charge of the autopsy may follow any technic which he personally prefers, and the same is true in regard to the records maintained and the further bacteriologic and microscopic investigations of any given case, these all depending upon the individual interest in the pathologic side of medicine. Every Army post hospital is equipped for the performance of autopsies with the list given on page 43.

In the Navy practically the same conditions obtain as in the Army. Autopsies are performed when practicable, particularly in those cases in which, *ante mortem*, interesting conditions are noted. No definite instructions are given the officer in charge. It may be well to note another point in this connection, and that is that, in practically all

¹One only has to refer to the postmortems performed by Harrison Allen (*Proc. Path. Soc. of Phila.*, 1864, vol. ii, p. 160) at the Lincoln General Hospital in Washington to see what good work has been accomplished in many instances. That the question of a uniform method of making autopsies has been under consideration, is seen by the scheme for performing an autopsy prepared by Bowditch (United States War Department, Surgeon-General's Office, Form of Record of Autopsy, being an extract from a report of Dr. Bowditch to the Mass. Med.-Leg. Soc., Feb. 1, 1882, published for medical officers of the Army, Washington, 1882).

severe cases of disease or injury, the patients are transferred whenever practicable to a shore hospital, and thus the actual necessity for the performance of an autopsy on board a man-of-war is rare.

The Marine-Hospital Service has, on the other hand, a definite routine, as is shown by the following abstracts from the "Regulations for the Government of the Public Health and Marine-Hospital Service" of the United States: approved August 12, 1903, par. 696: "A separate report will be made of each necropsy to be typewritten on legal cap paper, and on one side only of the sheet, and otherwise prepared with care for publication. Each report shall include the diagnosis, initials, age, nationality, date of admission (with name of station), and date of death of the seaman. Each report will be accompanied by a complete clinical history and forwarded to the Bureau as soon as completed." Further instructions relative to necropsies to be found in the Appendix are: "Examinations shall be made in accordance with methods prescribed in Virchow's Post-Mortem Examinations and shall include the following: (A) The calvarium is to be removed, and the condition of the skullcap, the brain-case, the sinuses and vessels, and the brain and its membranes noted. (B) In the thorax the examination will include the anterior mediastinum, the heart and pericardium, the lungs and pleura, the great vessels and nerve trunks, and the diaphragm. (C) In the abdomen the examination will include the omentum, spleen, kidneys and suprarenal capsules, urinary bladder, organs of generation (prostate, seminal vesicles, testicles, penis, and urethra), rectum, duodenum, stomach, gall-ducts, liver, pancreas, solar plexus, mesentery, small intestines, large intestines, and the great vessels. (D) In cases involving disease of or injury to the spinal cord the examination will include the cord and its membranes. (E) Microscopic examinations shall be made of pathologic processes and suspected organs. When it is not practicable to make these examinations at the station, specimens should be sent to the Bureau. For this purpose nervous tissue should be placed in Müller's fluid, lung tissue in a solution of 5 per cent. formaldehyd, and other organs in alcohol, 50 per cent. The specimens should be from one to two centimetres square, and carefully labeled."

NOTE TAKING.—Relying upon one's memory for records is a treacherous practice, and appearances which seem to be of no importance while the organ is before you are often of value to others who for various reasons may be called upon to read the protocol of the

autopsy but who have not had the opportunity of examining the parts in which they are interested. It is important, especially in medicolegal cases, to write "examined" or "normal"¹ after the number referring to the part under study, where no lesion exists, as this shows that an actual examination of this portion of the body has been made.

The notes should always be dictated in a distinct tone of voice and in easily understood language while the autopsy is in progress, and should consist exclusively of descriptions of the conditions then and there observed. Numbers and doubtful words should be at once repeated by the scribe, as an additional safeguard against error. Like the anæsthetist at an operation, the amanuensis should pay strict attention to the work assigned him. Names of diseases should be omitted in the notes themselves, but are to be inserted under the heading of "Pathologic Diagnosis" at the head of the report. The record of morbid changes present ought to be full, clear, and exact, so that from it alone the pathologic lesions can be inferred by another pathologist as well as by the one who performed the necropsy. If the post-mortem record is rewritten, any descriptions given during the superficial examination may be combined with the detailed account of the parts removed from the cavity examined, thus permitting of the omission of any possible repetitions. One well-worded description of an autopsy dictated to a reliable amanuensis during the progress of the work is of much more value than scores written from memory after their completion. Drawings, photographs, skiagraphs, kromskopic pictures, casts, microscopic slides, properly mounted museum specimens, and cultures of micro-organisms make valuable additions to a well-written account of a postmortem.

The liability to mistake, of which every day furnishes examples, is nowhere more forcibly exemplified than in the performance of post-mortems and the description of the appearances of the parts examined. What serious errors may result from poor writing or through misunderstanding, as in conversations over the telephone, is shown by

¹ Objection to the use of the word "normal" may properly be raised, for what one person may consider normal another would class as abnormal, while its use by an inexperienced person might lead to the omission of certain data which might be of importance in the future. It is, therefore, well to describe the part in detail. This will not only impress upon the obducent the normal appearances, but also lead him to make a more critical examination than he otherwise would be likely to do. The comparison of one organ with its fellow or of one part of the organ with another is often of value in this connection.

the following illustrations. A pathologist communicated by telephone to the secretary of a surgeon the diagnosis of adenocarcinoma. The report received by the surgeon was to the effect that the patient "had no" carcinoma.¹ Often the word "atypical" is understood in the sense of "a typical." There is also an amusing side to this subject. In abstracting an article by Banti for the *International Medical Magazine* in 1895, the author wrote of the bacillus there described as being 4 μ long by 1 μ broad. The style of the office where the magazine was printed was to spell out numbers, and, as the compositor mistook the writing of the Greek letter μ for ft., it appeared in the galley proof that "The bacilli are four feet long by one foot broad"!

Post-mortem records may be kept in a book specially prepared for that purpose, or on sheets to be filed away with the clinical history of the case under consideration. To every autopsy performed by myself I give a specific number, and lately have preserved my records on sheets kept in a flat-opening note cover-book, until they are ready to be filed away and indexed in properly made manila covers. The interchangeable sheets in the note-book measure seven by eight and one-half inches. By means of an ingenious clasp opening in the centre, one end being fixed and the other movable, the leaves are held in place by passing the clasp through two small circular openings on the left-hand side of the page. When the clasps are closed, the leaves can be turned like a book; when open, one or more sheets may readily be removed or others inserted. This method I find superior to the practice of keeping the records in special books or on the large index cards which are used by many physicians in preserving their private case records.²

The following characteristics of each organ are to be noted, particular attention being given to those structures which are most vitally connected with the functional activity of the part.

1. Situation and relation to other parts.
2. Size and weight.
3. Shape, contour, borders, and coverings (capsule, serosa, mucosa, etc.).
4. Color.
5. Consistency.
6. Anomalies and malformations (congenital and acquired).
7. Fractures, dislocations, and lacerations.
8. Cut surfaces and liquid exuded.

¹ *Amer. Med.*, December 5, 1903.

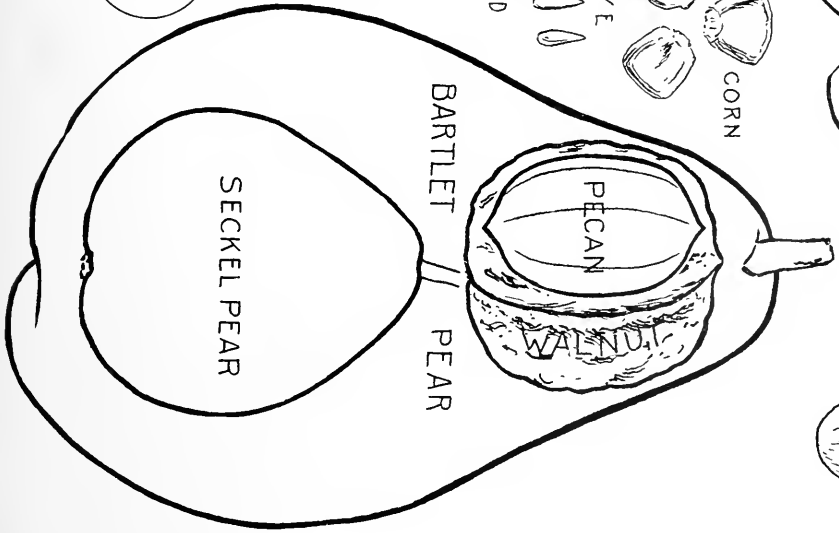
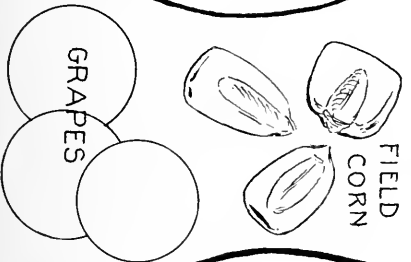
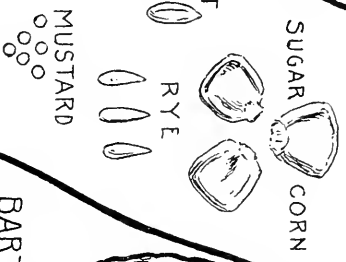
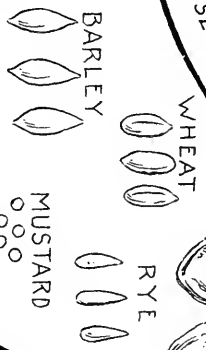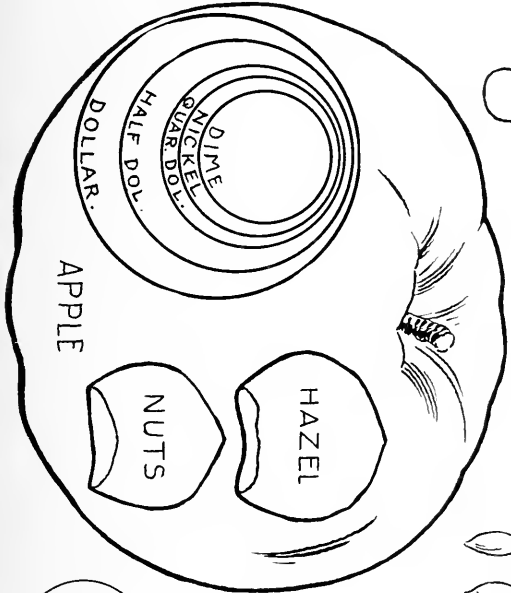
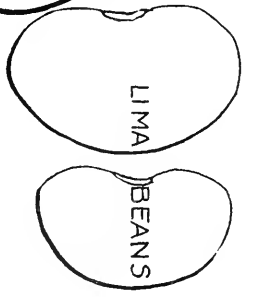
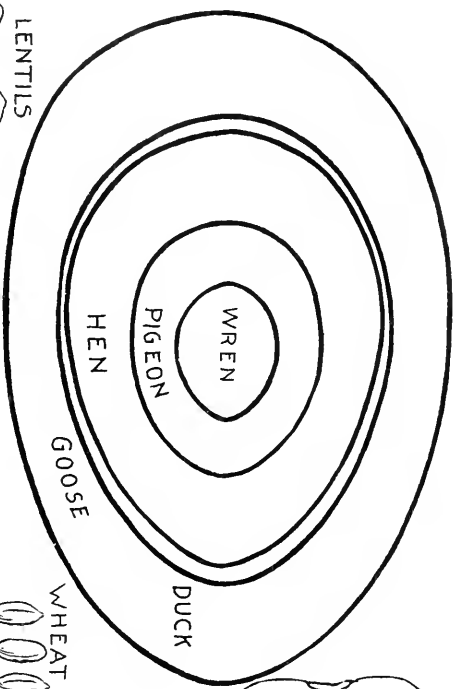
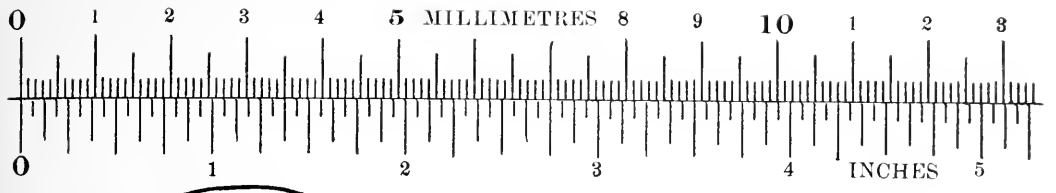
² *International Clinics*, 1902, vol. iv, Eleventh series.

9. Cavities, special attention being paid to their contents and to the linings of their walls.
10. Odor.
11. New growths.
12. Other pathologic conditions, taking into account the condition of the vessels to and from as well as in the part under consideration.


1. *Situation and Relation to other Parts.*—This takes into account any departure from the normal position or attachments of the organ. There are a number of regional landmarks frequently used; thus, in the case of the diaphragm we speak of its height in relation to the ribs or the intercostal spaces; of the stomach, as extending so many inches above or below the umbilicus; of the heart, in its relation to the nipples and the xiphoid cartilage; and of the cord, as to the vertebræ. While it may usually be easy to distinguish from which side an organ has been taken when there are no marked changes in its shape, the author has found that much time is saved and confusion avoided by marking each of the double organs as it is removed from the body,—one nick for the left- and two nicks for the right-sided organs.

Plate I, which will be found upon the inside of the front cover, is based upon Cunningham's Anatomy, and will be helpful in the preparation of outline charts of the body for recording the situation and extent of lesions discovered at postmortems. The drawing shows the normal relations of all the important thoracic and abdominal viscera. Those who are unable to draw can place a sheet of thin paper over the figure and prepare an outline, which, after being filled in according to the exigencies of the case, may be pasted in the notes for future reference. One may purchase English-made gummed outline charts in sheets of the brain and other parts of the body, upon which may be sketched in black ink the lesions which it is desired to record. Such drawings without further change may then be sent at once to the engraver for reproduction in order to illustrate matter intended for publication.

2. *Size and Weight.*—For tables of weights and measures of the body, see Chapter XXIV. Whenever possible, it is advisable to give dimensions in centimetres and weight in grammes; if, however, measures and weights are to be used when giving testimony in a court of justice, it is well to convert them into inches and pounds, ounces, and grains avoirdupois, before going on the witness stand. The size of an organ naturally depends much on the size and weight of the body.



Representation of certain familiar objects, with millimetres and inches, useful for comparison in describing the size and form of lesions found at the postmortem.



It should be remembered that a large organ is not necessarily a heavy one. Atrophy and hypertrophy may be present in the same part, as seen in cases of hypertrophic cirrhosis of the liver in which acute yellow atrophy has supervened. As nearly as possible similar conditions should be employed in the preparation of the organs for weighing. Thus, about one inch of the large blood-vessels is usually left attached to the heart previous to weighing and the renal pelvis of the kidney and a portion of the ureter is weighed with the kidney.

For determining bulk various means are employed besides actual measurement. A number of familiar objects at once suggest themselves, which may be used for comparison in describing the size of a lesion or part. And the importance of thoroughly familiarizing one's self with the dimensions of objects seen daily is illustrated by the fact that most persons have only vague and more or less erroneous notions concerning the dimensions of many common things, such as the head of a horse (usually underestimated) or the height from the ground of a stationary wash-stand (generally overestimated). A lesion may appear larger or smaller by being elevated or depressed and of a color like or unlike that of the surrounding parts. Virchow had, in the old Charité dead-house before its destruction by fire on January 16, 1901, a cabinet containing specimens of various familiar objects, such as beans, peas, lentils, barley, etc., with which pathologic lesions could be compared. (Plate II.) Later on, recognizing the relation of specific gravity to size and weight, he estimated the size by noting the quantity of water displaced by the organ when placed in a large vessel of known capacity.

3. *Shape, Contour, Borders, and Coverings (Capsule, Serosa, etc.)*.—All deviations from the normal in these particulars should be noted, as valuable information may be gained thereby. Thus, the shape of the uterus may point to a probable previous pregnancy. The symmetry of the organs should be looked for, and comparisons made of one part with another. The form of an organ is often markedly changed by its removal from the body. Freezing the bodies and injecting them with formalin are the best methods used of determining the real shape of the parts. That marked changes occur in life under normal conditions is seen on comparing the lung during an operation upon the chest in a condition of expiration with that of inspiration. An organ may retain its normal size and to a large extent its shape, and yet the parenchymatous tissue be markedly decreased,

as when the pelvis of a kidney is filled with fat. It is often advisable to use the name of some well-known object in describing the configuration of a part,—*c.g.*, cauliflower growth, mushroom-shaped, hobnail, hour-glass contracture, beaver-tailed, horseshoe, sago, bread-and-butter, pig-backed, etc. As to the external appearance of a solid organ, its surface may be smooth, granular, nodular, shrivelled, or puckered. Here also we describe the capsules of organs, the serous coverings of the various parts,—as of the liver, brain, etc.,—the mucous membrane,—as of the stomach, vermiform appendix, etc.,—being considered after the opening of the part. The borders of organs that have undergone infiltration are usually rounded and filled out; in degenerations they are generally flatter, thinner, and sharper than normal. Thus, in fatty infiltration the edges of the liver are rounded, while in cirrhosis its margins, often so largely composed of connective tissue as to contain practically no liver-cells, are sharply defined. The general contour of the blood-vessels may be markedly changed, as in aneurisms.

4. *Color*.—It is most difficult to describe colors or to reproduce them satisfactorily. In the reproduction of color "three-color" printing does not give, as yet, such good results as lithography. The best color-values are obtained by the kromskop,¹ which has a wide field of usefulness not sufficiently recognized. Color differs when viewed from a long or short distance. For purposes of comparison colored chalks or oculists' colored worsteds can be used. The primary colors yellow and red are chiefly met with, as also various shades of brown, which is a mixture of these two with some black added. Other colors found are slate, shades of gray and of yellow, blue, and green. The numerous shades and gradations of red are the most common tints found in the body. There is no such thing as pure white, even the conjunctivæ being a pearl-grayish pink. In pathology the word "pale" means relative deficiency of color. The color of adjacent parts may bring out or hide pathologic lesions. Color may point to a post-mortem change, as the red color of the aorta seen in imbibition, or to a lesion, as the appearance of blood-vessels in the valves of the heart. One may not be able to distinguish an artery from a vein at the postmortem by color alone. The color of an organ or part is to be noted as soon as possible after exposure, as air, light, and water tend to alter it con-

¹ CATTELL, *International Clinics*, 1900, vol. ii, Tenth series.

siderably, though naturally more or less change has already been brought about by death. Thus, the pericardium, which during life is transparent, is at autopsy only translucent. An organ should not be washed before its color is described, as water removes part of the coloring matter present, acts on the proteids, and modifies the original consistence of the organ; these changes may readily be demonstrated by placing the thymus gland, with the surrounding areolar tissue, in running water for five minutes. The natural juices of the body may cause alterations in color; thus, the gastric juice turns blood to a brownish tinge. Air oxidizes the blood, so that a bluish stain may in a short time change to bright red. In the case of a congested lung it is well to note its appearance both before and after the blood has become oxidized. Certain abdominal organs are frequently discolored by a greenish slate tint supposed by some to be due to the deposition of the iron from the hæmoglobin by the hydrogen sulphid arising from decomposition. It would add materially to our knowledge if surgeons were to inform pathologists under what circumstances this condition is seen during life. In a case of ammonium hydrate poisoning observed by the author, although the body was well preserved, the characteristic discoloration had penetrated the substance of the liver to a depth of three-quarters of an inch. In this instance a rod dipped in hydrochloric acid and held in the cranial cavity after the removal of the brain gave off fumes of ammonium chlorid. Poisons often change the color of the blood markedly, and degenerations and infiltrations alter the color of the various parts affected. For a further description of the blood the reader is referred to page 126.

5. *Consistency*.—This is learned only by experience, and is determined by pinching the organ between the thumb and the index-finger and by noticing its behavior when held in the hand. According to Oestreich,¹ the best method of determining the consistency of an organ is, with closed eyes, gently to raise the part from beneath with a lateral pressure by means of the moistened fingers exclusive of the thumb. Hollow organs should be tested both before and after opening. It should be remembered that consistency is affected by the season of the year, by the temperature of the cadaver and of its surroundings, by the length of the interval between dissolution and the autopsy, by the manner of death, by the means used for the preservation of the body,

¹ *Allgemeine pathologisch-anatomische Diagnostik*, 1905, p. 13.

and by various other influences. The name applied to the pathologic condition often shows the consistency, as malacia (soft), in osteomalacia, and the hepatization of croupous pneumonia (hard). Elasticity is seen, as in the aorta, which in health may be stretched several centimetres. Parts when once pressed may not return to their previous condition, as in fatty liver or œdema of the lungs. Organs are hardened by an increase in connective tissue, as in cirrhosis of the liver; by deposits of lime, as in calcareous infiltration of the coronary arteries, etc. Consistency differs before and after death, and is much modified by rigor mortis (increased) and by decomposition (diminished).

6. *Anomalies and Malformations (Congenital and Acquired).*—Each part or organ is subject to its own peculiar anomalies and malformations, which depend on the embryonal stage at which they occur. An entire chapter might readily be written upon the various altered conditions, congenital and acquired, revealed by autopsies. Thus, the author has seen perforation of a typhoid ulcer in a Meckel's diverticulum; free calcified bodies in the abdominal cavity; peculiar curvatures of the iliac arteries; the left kidney shaped like the spleen; the tip of the vermiform appendix resting near the pyloric end of the stomach; an artificial anus made by the rupture of a typhoid ulcer; the vermiform appendix in a *left* femoral hernia and the sigmoid flexure in a *right* inguinal hernia; a fish-bone in the omentum, etc.

7. *Fractures, Dislocations, and Lacerations.*—Every degree of injury may be represented. It should be remembered that from the external appearances alone it is not possible to state definitely the extent of the internal lesions. A heavy wagon may run over a child without rupturing the skin, though the internal organs may be lacerated and torn to a remarkable extent. The writer had an instructive case where a man struck a lamp-post with a push-cart, the handle of which struck his hepatic region; the external injury was not larger than a silver dollar, but hemorrhage from laceration of the liver finally caused death. Injuries are especially apt to be overlooked in those parts which are covered with hair. Artificial fractures of the organs afford abundant opportunity for study. This is best accomplished by making a small incision in the organ and then tearing it apart by force. Compare the difference under these conditions between an amyloid and a fatty liver, or a heart affected with fragmentary myocarditis and the normal heart.

8. *Cut Surfaces and Liquid exuded.*—When an organ is incised, describe first that which is most striking, as, for example, the presence of a hydatid cyst that is exposed on section of the spleen. Note the color of the exposed surface; whether it is smooth or granular; dry, as in dry gangrene, or moist, as in liquefaction necrosis; the amount, character, and chemic reaction of the fluid that is spontaneously exuded or is obtained by scraping with a knife (the material thus obtained is at once examined with the microscope); and the condition of the blood-vessels, especially as to atheroma and thrombosis. Numerous incisions may lead to the discovery of new lesions or afford an opportunity of studying the morbid process in its various stages. Under the term “liquid exuded” are included not only blood, transudates, and exudates that follow incision of the part, but also any fluid that may be contained in the cavity of a hollow organ or in a cyst present and the juice that appears on scraping and squeezing. Œdema of an organ may be detected by squeezing it. In the lungs a frothy œdematous material shows the absence of a pneumonic infiltration.

9. *Cavities.*—In opening any cavity look for blood, mucus, pus, transudates, exudates, specific secretions and excretions, and stones. In describing cavities pay especial attention to the lining membranes, noting their color, lustre, smoothness or roughness, and the presence of any adhesions; also the quantity, color, consistence, odor, and reaction of their contents and any sediments found therein. Normal cavities may be increased or diminished in size and singular or multi-form new cavities may be formed. The gaseous contents of cavities is a most interesting and unexplored field of original investigation.

10. *Odor.*—It is safe to predict that more and more attention will be given to the significance of odor. The organ of smell is imperfectly developed, and varies greatly in different individuals and in the same individual at different times. The peculiar odor that accompanies the growth of certain bacteria, such as the *Bacterium coli commune*, is well known. Smallpox, measles, cancerous ulcerations, and gangrene of the lung have their peculiar stenches. We may also mention the odor of acetone in diabetes, the pus-like odor in leucocythæmia, the butyric-acid-like or alcoholic odor from the brains of those who have drunk heavily before death, the uræmic odor, the odor in cases of carbolic or hydrocyanic acid poisoning, etc. The following poisons may also be recognized by their odor: ammonia (see p. 29), amyl nitrite, aromatic oils, bromin, bromoform, camphor, chloral, chlorin,

chloroform, creosote, ether, ethereal oils, formalin, hydrochloric acid, indol, iodine, iodoform, methylic alcohol, nicotine, nitrobenzol, opium, osmic acid, paraldehyd, phosphorus, skatol, sulphuretted hydrogen, sulphuric acid, tellurium salts, and turpentine. Fischer and Penzoldt¹ state that the one five-millionth part of a gramme of chlorphenol or of mercaptan may be recognized by the sense of smell. For another illustration, see the action of the *Penicillium brevicaulis* on arsenical preparations, Chapter XXVIII. We should not, however, err in the other direction, for too often a case of apoplexy is taken to a police-station and the diagnosis is there recorded as one of alcoholism, simply because the odor of alcohol is found on the person arrested.

11. *New Growths and Parasites*.—It is important to determine at once the presence of tumors, cysts, worms, etc., in a part, as subsequent manipulations may have to be markedly altered by their discovery.

12. *Pathologic Conditions*.—Every death may be attributed to one or more of the three following ultimate causes: I. Interference with respiration, called asphyxia or apnoea; II. Interference with the heart's action, called syncope; and III. Interference with the nervous system, called coma or shock. The number of distinct diseases capable of producing death is limited, as will be seen by reference to the Bertillon classification of the causes of death given in Chapter XXX, the list not being nearly so large as one might expect without due consideration of this subject. There is also a distinct repetition of morbid processes in the different diseases and in the different parts. It is also well to remember that the histologic structure of an organ often at once gives information as to the lesions which will possibly be present in an affected part. In making a postmortem the diseases from which a person is liable to die and the lesions which may be found in any individual part or organ should always be carefully considered. Bearing this point in mind, considerable care has been taken in the preparation of the index in order to aid the reader in reaching a proper diagnosis by refreshing his memory as to the possible diseases or disturbances that may take place in the part or organ under study. By exclusion, the character of a lesion under observation may often at once be reduced to two or three possibilities, the final diagnosis being reached, in many cases, only by microscopic study. The index will

¹*Jr. Amer. Med. Assoc.*, April 23, 1904.

also be found of use as suggestive in the preparation for an examination in pathology before a State Board or elsewhere.

Every pathologist is familiar with cases in which it was impossible to state positively the cause of death, even on the completion of an elaborate autopsy and subsequent thorough examinations by the chemist, bacteriologist, and microscopist. In such instances, as in all others, the accuracy of the conclusions drawn will depend upon the care exercised in the observation of details. Fortunately for those having to do with cases coming under the notice of the Coroner, sudden death is nearly always attended by well-marked pathologic lesions. When no such cause of death is found, chemic or early microbic poisoning should be suspected. Any epidemic disease, such as smallpox, which is now (1906) so widely distributed throughout America, should always be thought of during the time of its prevalence, as death therefrom may occur before the characteristic rash or symptoms have appeared.

A lesion found in one portion of the body may indicate the existence of pathologic conditions in another perhaps remote part. For example, multiple melanotic sarcomata of the liver are frequently secondary to a primary growth in the eye; embolism in the brain often arises from malignant endocarditis; hæmatomata of the ears will suggest chronic meningo-encephalitis, with thickening of the cranial meninges; a stricture of the urethra may cause hypertrophy of the bladder; and the presence of miliary tuberculosis should lead to an examination of the pulmonary arteries for tuberculous thrombi arising from caseous tuberculous glands. Again, particles of coal-dust embedded in the hands demand a careful inspection of the lungs for anthracosis, while bronzing of the skin will suggest scrutiny of the adrenals and of the sympathetic ganglia (Addison's disease).

Bond's interesting experiments¹ have shown that the ascending currents to be found in mucous canals and the ducts of glands are prolific sources of infection not hitherto sufficiently recognized. Sterilized pigments were placed in various apertures of the body before operation and the neighboring organs were examined after removal in order to discover if they had been reached by these substances. Thus, when the colored matter was placed in the vagina, the particles would pass into the oviducts and thence to the peritoneum covering the broad ligaments.

¹ *Med. Notes and Queries*, September-October, 1905, p. 130.

CHAPTER III

POST-MORTEM INSTRUMENTS AND HOW TO USE THEM

VARIOUS combinations of post-mortem instruments are found in the sets catalogued by dealers, but these, except for the systematic work possible only in hospitals and morgues, are more luxurious than necessary. The former wooden box with its plush lining is an abomination, owing to the impossibility of keeping it in a cleanly condition. The metal box is satisfactory, and one should be employed which can occasionally be sterilized by heat in its entirety. The ends of the box should be rounded so as to prevent any sharp edges from injuring the hands of the operator. If a box be used, all instruments should be thoroughly disinfected and returned to their proper places after each postmortem. It is annoying to take such a box to the place where the postmortem is to be held and then to discover the very instrument wanted to be missing. The instruments that are really indispensable for the proper performance of an autopsy are very few in number, as a complete examination may be performed in case of an emergency with a penknife and an ordinary wood-saw. Of course, in this field, as in surgery, ample opportunity has been offered for the exercise of mechanical ingenuity, and many instruments have been devised for facilitating post-mortem work that save much time and render greater neatness and exactitude possible.

The following list contains the instruments, apparatus, and chemicals most commonly used in the performance of an autopsy.

KNIVES.—*Section- or Cartilage-Knives.*—These should be made very strong, with a broad back; blunt, rounded ends; and a bulge or belly at the outer third (Fig. 14), becoming narrower at the attachment of the blade to the handle. For general purposes the length of the entire knife should be from seven to seven and a half inches (about eighteen centimetres), the handle measuring about four inches. The Germans use knives even as long as eleven inches (twenty-eight centimetres, with a blade of sixteen centimetres). The rounded expansion for the index-finger found on the back of some section-knives is unnecessary (Fig. 15). The sharp-pointed knife should in all instances be rejected (Fig. 16). When the knives are sent to be

sharpened, the instrument-maker should be cautioned not to grind them to a point. *Scalpels*, such as are used in dissecting. Those made of a single piece of metal—*i.e.*, without wooden, bone, or ivory handles—are to be preferred. The *brain-knife* (Fig. 101) should have a thin blade about ten inches (twenty-five centimetres) long, one and a half inches (four centimetres) broad, and be blunt at the end like a table-knife. This instrument may also be used for incising the large organs and in opening the cavities of the heart. The brain-knife is sometimes sharpened on both edges or it may be marked in the form of a rule and thus serve a double purpose (Fig. 17). An *amputation-knife* may be employed in place of a brain-knife, or in removing the brain through a trephine opening made in the skull. A *Waring bread-knife* (Fig. 18), which also does good work, may be used for incising the larger organs. A *Valentine knife* (Fig. 19), which has two parallel blades adjustable by screws to keep them the desired distance apart in order to cut at will thick or thin sections, is now rarely seen, but was much employed before the freezing microtome came into common use. Pick's *myelotome* (Fig. 20) is an instrument with a short blade bent nearly at right angles to the shaft, for cutting the spinal cord rectangularly to its axis instead of in an oblique direction. A *curved, probed-pointed bistoury* is also used in cutting the dura mater, spinal cord, etc. A *razor* was formerly included in all lists of post-mortem instruments, but is now discarded.

SAWS.—The *saw* should possess a strong blade solidly attached to the handle, as the two-piece jointed ones, kept in place by a screw, are very liable to become loosened. (Figs. 21, 2 and 5, and 22.) A butcher's meat-saw, which is arranged like a scroll-saw (Fig. 23) with its teeth pointing towards the front, its cutting surface measuring from ten to fourteen inches (twenty-five to thirty centimetres) for an adult and six inches (fifteen centimetres) for a babe, or a large cross-cut carpenter's saw, does the quickest work in removing the calvarium. *Hey's saw* (Fig. 24) is useful in sawing the angles when opening the skull. A *metacarpal saw* (Fig. 25) is often of service, especially in examining the femur of a babe for the detection of syphilitic osteochondritis. A *wire saw* is seen in use in Fig. 163. Schalle (*Virchow's Archiv*, vol. lxxi, p. 206) gives a good account of how to use it. Van Walsem has prepared a special saw, which he calls *cranioprion*, for opening the skull without injury to the dura. *Lucr's double rhachiotome* (Fig. 26), employed for opening the spinal



FIG. 14.—Section- or cartilage-knife, with rounded end. (One-half natural size.)



FIG. 15.—Cartilage-knife with projection on back upon which the index-finger rests when making incisions. (Two-thirds natural size.)



FIG. 16.—Post-mortem knife with faulty point and without proper belly. (Two-thirds natural size.)

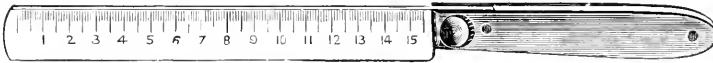

FIG. 17.—Coplin's brain-knife marked in centimetres on one side and in inches on the other. (Reduced.)




FIG. 18.—Bread-knife, useful in incising large organs, as the brain, the liver, etc. It comes in two forms,—with both sides meeting at the cutting edge like an ordinary knife, or with one side perpendicular and the other slanting for about three-eighths of an inch above the sharp edge, as shown near the handle in the illustration. (One-third natural size.)

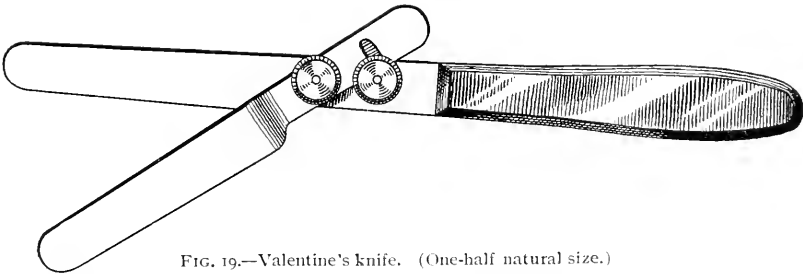


FIG. 19.—Valentine's knife. (One-half natural size.)



FIG. 20.—Pick's myelotome. This little instrument is useful for severing the spinal cord in the removal of the brain. (One-half natural size.)




FIG. 21.—1, desirable form of forceps with spring; 2, saw with rounded end; 3 and 4, proper shapes of needles; 5, small saw with rounded end; 6, spring forceps; 7, box-jointed tenaculum forceps; 8, solid-headed hammer; 9, steel tape measure; 10, combined hone and strop (a strip of aluminium may be used for this purpose); 11, scalpel with rounded hard-wood handle. (Reduced about one-half.)




FIG. 22.—A very desirable saw for post-mortem work; it is solidly constructed, and the teeth on the curved end are useful for sawing out the angles in the removal of the skullcap by the angular method. (Slightly less than one-half natural size.)

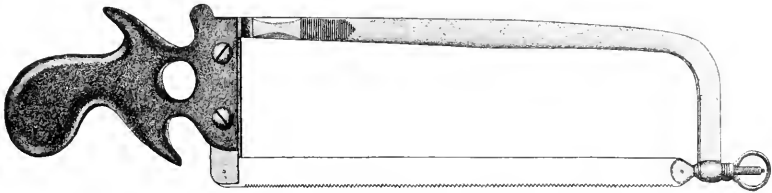


FIG. 23.—Butcher's saw, with teeth facing forward, very useful for quick work in opening the calvarium. (One-quarter natural size.)

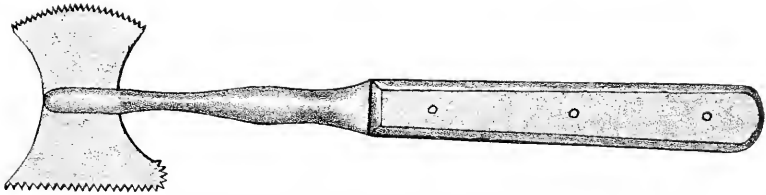


FIG. 24.—Hey's (Paré's) saw. (Two-thirds natural size.)



FIG. 25.—Metacarpal saw. (Slightly less than two-thirds natural size.)

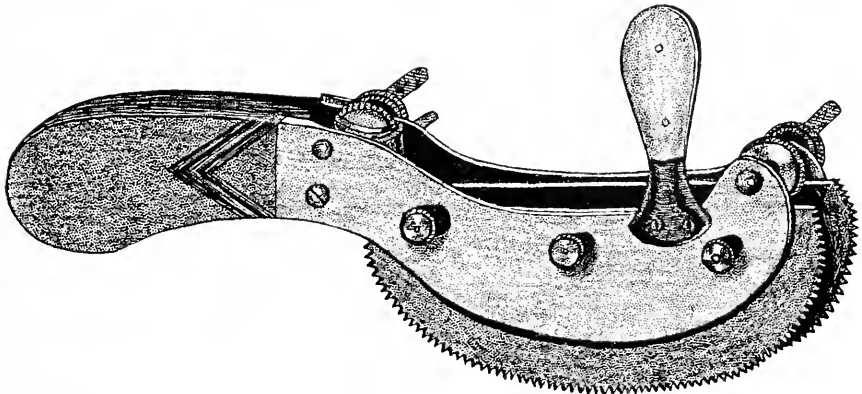


FIG. 26.—Luer's double rhachiotome. This instrument is worked with the right hand and steadied with the left by means of the handle attached to the fixed blade, the other blade being movable by clamps, so that the distance between the parallel blades may be varied at the will of the operator. The sawing is done towards the hip, except for the upper cervical bones, where it can best be done towards the occipital bone. This instrument should not be used in marked deformities of the vertebral column.

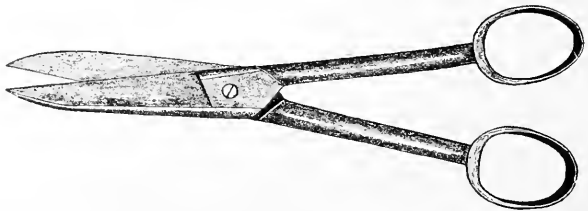


FIG. 28.—Strong scissors with short blades. (One-half natural size.)

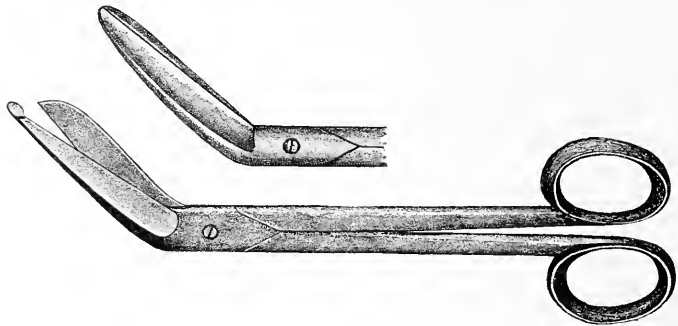


FIG. 29.—Scissors with one rounded blade and with bent blade. (One-half natural size.)

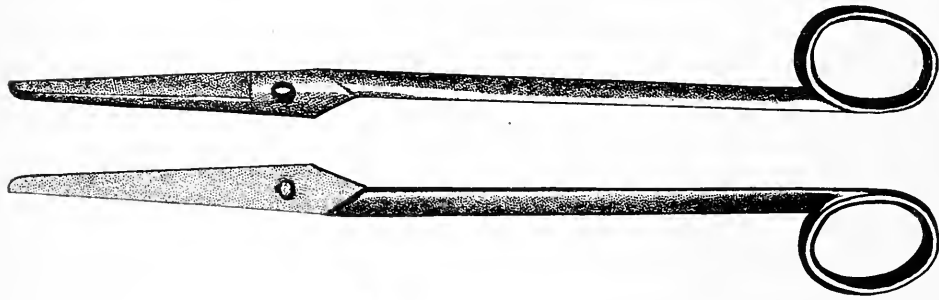


FIG. 30.—Separate-bladed scissors, easily disinfected. The female blade is to the right; the male to the left.

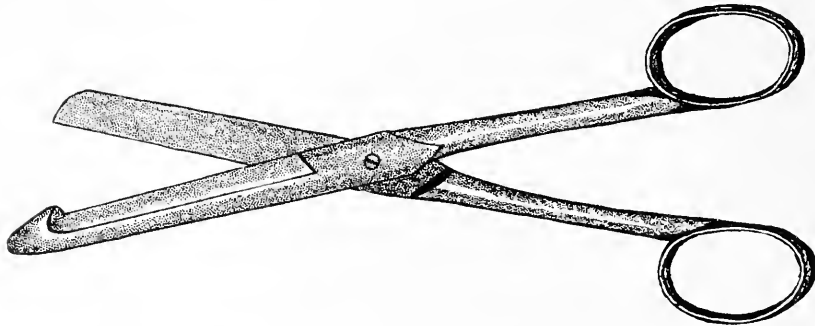


FIG. 31.—Proper form of enterotome. (One-half natural size.)

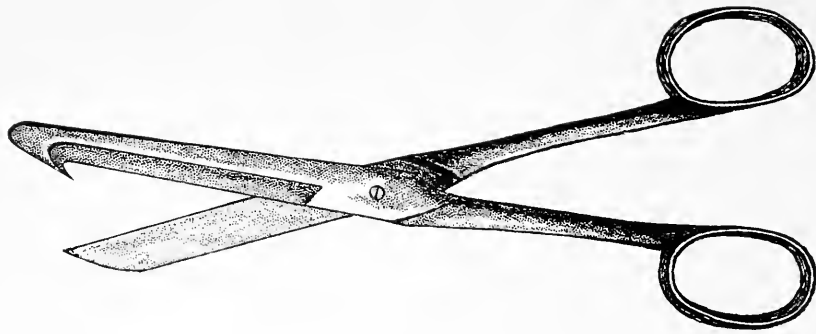


FIG. 32.—Improper left-handed form of enterotome, with pointed ends. (One-half natural size.)

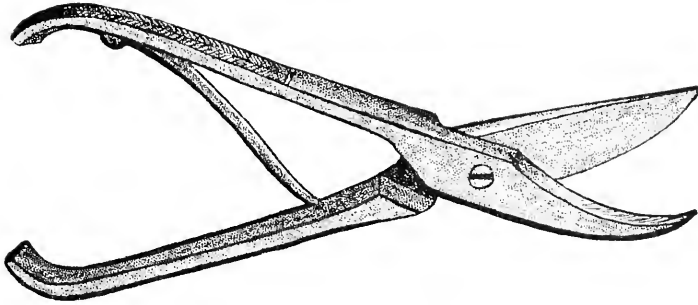


FIG. 33.—Proper form of costotome; the handles do not meet by one-quarter of an inch and the ends are not pointed, but rounded. (One-half natural size.)

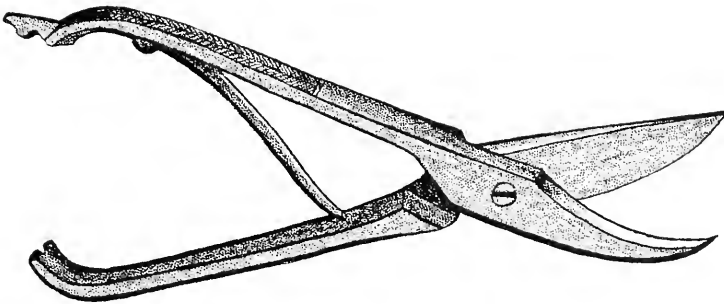


FIG. 34.—Improper form of costotome, with pointed blades and a catch, the handles meeting when the instrument is closed. (One-half natural size.)




FIG. 35.—Steel hammer with proper handle. (One-half natural size.)



FIG. 36.—Solid steel side chisel for breaking through any unsawed portions of bone in removing the calvarium. The pointed end is used as a pry and retractor for pulling out the sawed-off portion of the skull. (One-half natural size.)

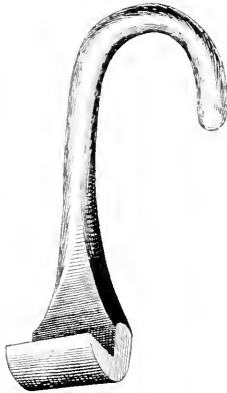

FIG. 37.—Curved chisel, used for the same purposes as Fig. 36. (One-half natural size.)

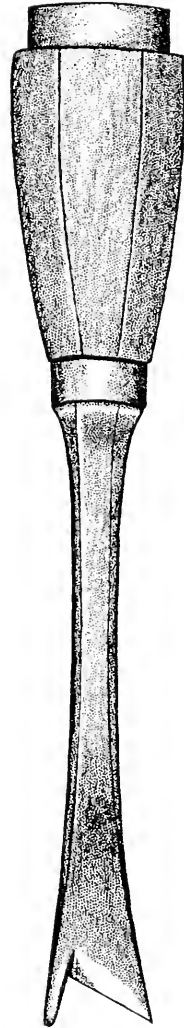


FIG. 38.—Brunetti's left curved spinal chisel, of use in opening the vertebræ. (One-half natural size.)

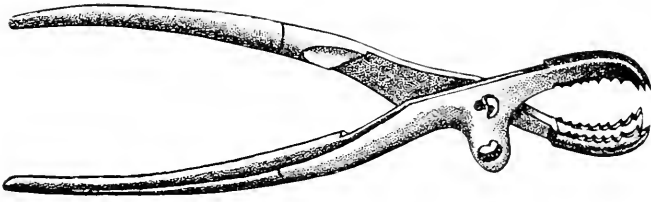


Fig. 39.—Dura tongs.

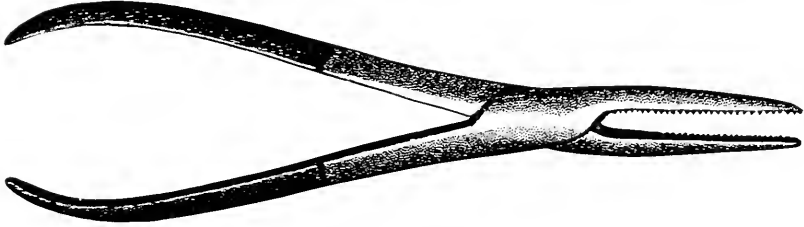


FIG. 40.—Forceps.



FIG. 41.—Straight grooved director. (One-half natural size.)

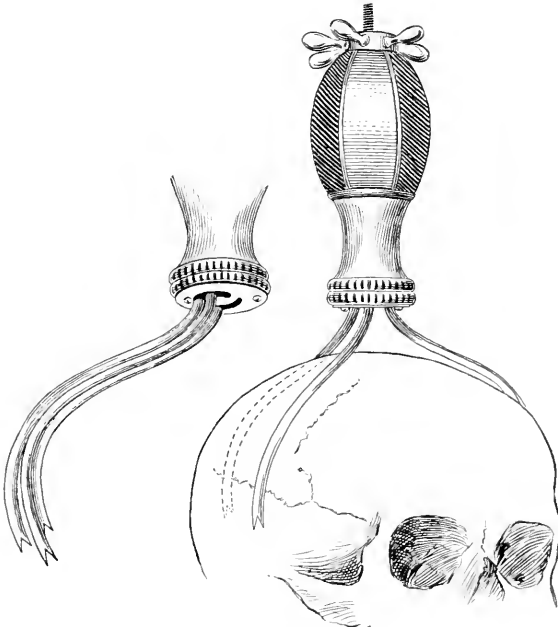


FIG. 42.—Satterthwaite's calvarium clamp, closed and in use.

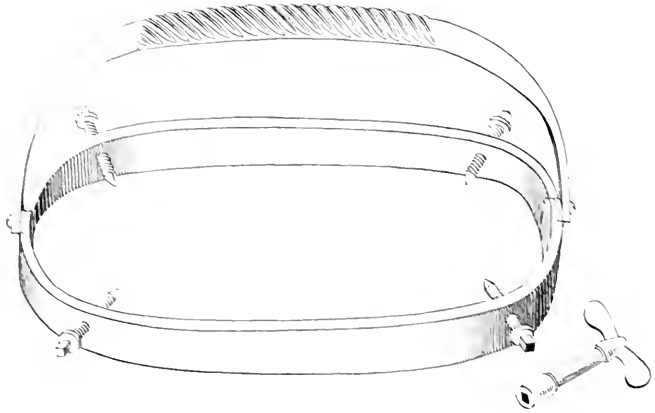


FIG. 43.—Iron clamp to be applied to the skull before the removal of the brain: especially used in dissecting-rooms.

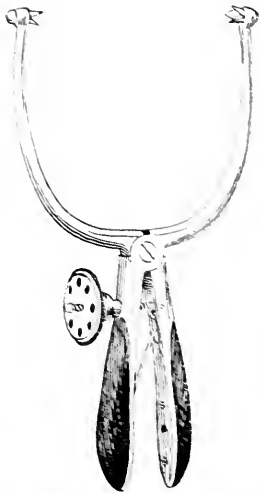

FIG. 44.—Bigelow clamp for holding the head in the removal of the brain.

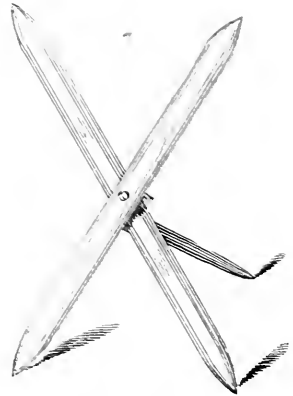


FIG. 45.—Folding iron head-rest.

tioned those of Cryer,¹ de Vilbiss, Wright, Sykes (English), Masland (Fig. 27),² etc. These instruments are high priced (\$100 to \$300), on account of the infrequent demand for them. Hand-driven instruments may be purchased for twenty-five dollars and upward.

SCISSORS.—One pair of scissors should be large and strong, with long handles and short, stout blades (Fig. 28); the other pair should have rounded ends with handles at an angle of forty-five degrees (Fig. 29). A pair with separable blades is frequently useful (Fig. 30). The *enterotome* is a scissors with one short and one long blade (Fig. 31), the latter being blunt and curved on itself at the end. Be sure that there is no sharp-pointed end, as this is the form usually supplied (Fig. 32). The *costotome* (Fig. 33) is an expensive instrument, with short, thick blades, the under one being curved and having a strong spring between the handles. Dangerous blood-blisters are sometimes produced by pinching the operator's skin with the ends of the handles, which usually meet and fasten with a catch (Fig. 34). *The ends should not meet and there is no necessity for the catch.* *Bone-forceps*, large and strong and with rough handles, are desirable. One blade is blunt, so that it can be shoved against soft tissues without injuring them, as in cutting the ribs.

HAMMERS.—The most useful hammer is made of solid steel (Figs. 21, 8, and 35). One end of the head or striking portion is cuneiform, and there may be a hook on the end of the handle which is of service in springing off the calvarium. Lead filling in a hammer muffles the sound of its impact and prevents rebounding. A wooden or rawhide mallet is preferred by some pathologists for a similar reason.

CHISELS.—There are chisels of various patterns devised for opening different regions. The *straight chisel* is the most serviceable, as it can be used in any region. The T-shaped chisel is also generally useful; it has one arm placed perpendicular to the other, and the arm which serves as a handle has one sharp and one blunt end so that it can be hammered upon. The chief use of the T-shaped chisel is in springing off the calvarium and in elevating the periosteum from it. Guarded, hatchet-shaped chisels (Figs. 36 and 37) and Brunetti's spinal chisels (Fig. 38) are useful in opening the spinal canal, and a chisel with a guard about half an inch, or 1.25 centimetres, from the edge

¹ *Medical News*, January 30, 1897.

² *Proc. Phila. Count. Med. Soc.*, February 28, 1905.

will not injure the brain while springing off the calvarium from the dura mater. The *raspatory of Chiari* has a broad, spoon-shaped end, four centimetres wide, with which the periosteum from a large surface can easily be removed; the other end is of the shape of a lance, one inch (2.5 centimetres) long, and is used for deep separation. Chavigny¹ has devised a special lever of ingenious construction for the purpose of removing the spinous processes and laminae of the vertebral column in taking out the spinal cord.

FORCEPS.—Dissecting forceps are indispensable when it is necessary to trace small structures; pointed, straight and curved forceps are the forms in use. (Fig. 21, 1 and 6.) *Lion-forceps* of special type may be used when removing the bodies of the vertebræ. *Dura-tongs* (Fig. 39), for pulling the dura mater away from the calvarium when it is adherent, may prevent the fingers from being injured by the bone. Various forms of tongs and forceps are recommended for those who use gloves. (Simmonds.) Another form of strong forceps is seen in Fig. 40. For *bone-forceps* and *costotome*, see under Scissors.

Grooved (Fig. 41) and curved DIRECTORS are frequently of use.

CHAIN HOOKS and a TENACULUM may be employed, but they are dangerous instruments. HOOKED RETRACTORS are more desirable than a tenaculum or chain hooks.

VARIOUS INSTRUMENTS.—A metal *catheter* and several flexible catheters, all of size number 8, may be needed for withdrawing urine. A *blow-pipe* with a stop or valve, a *trocár* and *cannula*, *probes*, some of which have eyes, and some form of *injecting syringe* are also useful. A *vise* is serviceable in firmly holding bone preparations in course of dissection, and in fixing a saw that is being sharpened. A *skull clamp* is considered by some to be of use in removing the calvarium (Figs. 42, 43, and 44). *Iron tripods* and other special devices for holding the head are shown in Figs. 45 and 46.

Weights and *measures* of various kinds are frequently found to be indispensable. These should include scales, a steel tape measure (Fig. 21, 9), graduated calipers, graduated glass cones, glass balls, and graduated measuring vessels of glass. The *scales* should have a capacity of twenty pounds, or ten kilogrammes, and be supplied with weights from a gramme upward. They are needed in weighing organs. The *steel tape measure* and the *two-foot rule* are marked both in centimetres

¹ *Presse méd.*, July 20, 1904, p. 460.




FIG. 46.—Cornell folding clamp for the secure holding of the head in the removal of the calvarium. (See article by B. B. Stroud in the *Proc. Assoc. Amer. Anat.*, May, 1900, p. 10, and the *Med. News*, December 9, 1905. In the later communication, an iron form of head-rest is described. Specifications for the making will be sent upon application to the author.)




FIG. 49.—Metal pocket-case of instruments for finer dissection; very easily sterilized. (About one-half reduction.)




FIG. 50.—Cones for measuring orifices. (Actual size.)




FIG. 51.—Glass balls to which handles are attached, for measuring orifices. (Actual size.)




FIG. 52.—Various ways of wrapping linen twine, cut of proper length and ready for use.




FIG. 53.—Formad's leather pocket-case for holding the instruments usually employed in making a postmortem. (One-half natural size.)

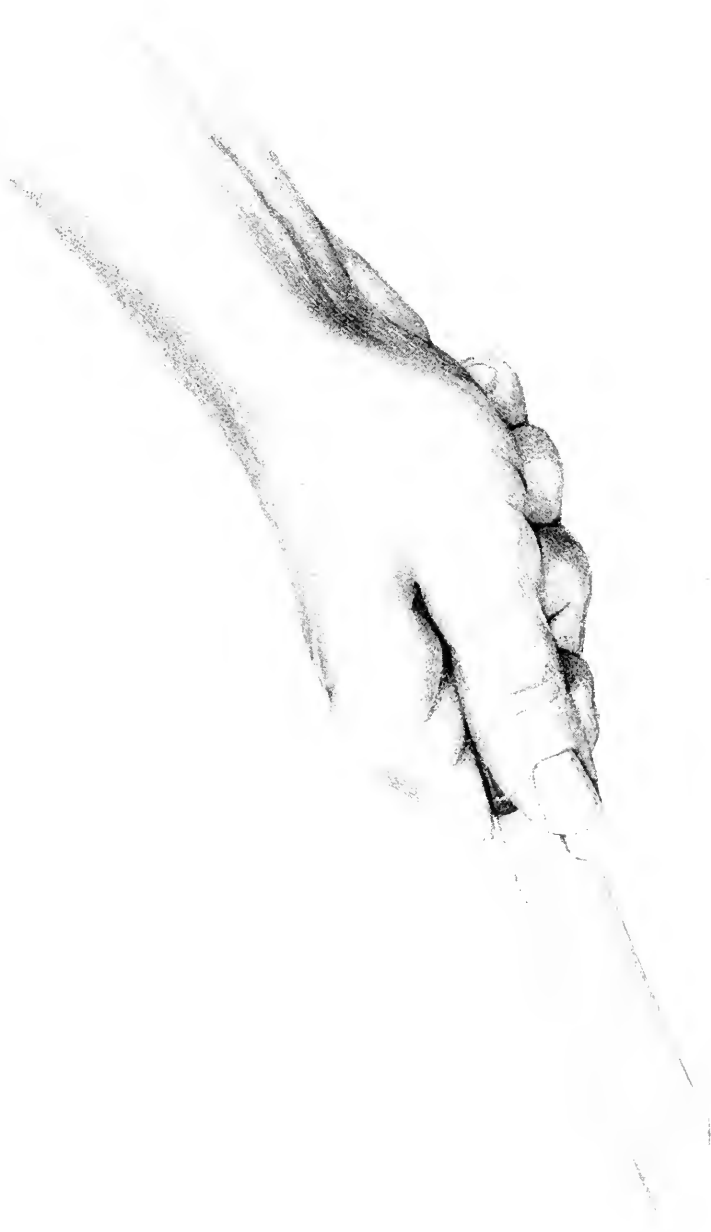

FIG. 54.—Method of holding cartilage-knife. The hand firmly grasps the knife, and the cutting is done with the belly of the blade.

and in inches. *Graduated calipers* or a measuring stick (Fig. 47) may be used in determining diameters. Fig. 48 represents an instrument known as a *raspatory*. A metal *pocket-case* for instruments is shown in Fig. 49, and a leather one in Fig. 53. *Graduated wooden cones*

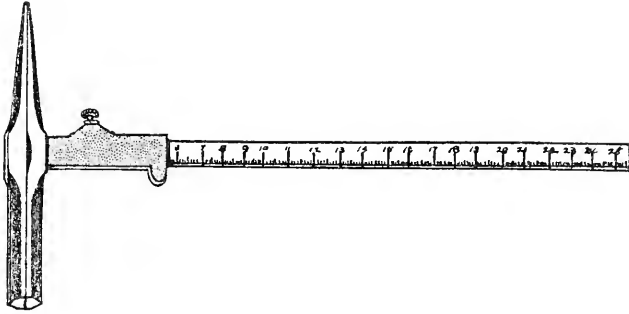


FIG. 47.—Steel measuring stick marked in centimetres. (Reduced.)

(Fig. 50) and *glass balls* (Fig. 51) are serviceable for measuring orifices and canals. *Graduated measuring vessels* of glass are useful. The larger vessels should be marked at every hundred cubic centimetres up to one or two litres, and the smaller for every two cubic centimetres up to a hundred. A *stomach-pump* is especially useful in withdrawing fluids from cavities. A *urinometer* is often of use. *Ladles* with a lip or spout, made of enamelled or agate ware, and with a

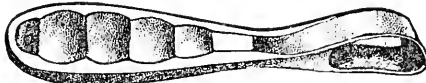


FIG. 48.—Raspatory. (Reduced.)

capacity of half a pint, or two hundred and fifty cubic centimetres, are needed in dipping fluid from cavities. A *wetstone* is useful, especially the form with a handle and a leather strop on the back of the stone. (Fig. 21, 10.) A *magnifying-glass* that enlarges at least ten diameters should be in the hands of every one making postmortems.

OTHER SUPPLIES.—*Enamelled trays* or *basins* are useful for receiving removed organs, and the basins are also required in cleansing

the hands and instruments. *Blocks of wood* are needed to support the body. Metal supports are unwieldy and scratch the table. The blocks should be made of very hard wood, as of ebony, were it not for the cost, it being most difficult to secure boxwood of the proper size. Some of these should be prismatic in form, others excavated to fit under the neck during removal of the brain. All wooden utensils should be finished with oil so as to be non-absorbent. *Earthenware plates* or *wooden boards* are useful during the dissection of organs. *Needles* (Fig. 21, 3 and 4) and *coarse flax thread* or *fine twine* are needed in closing incisions made through the skin. The thread is also required in ligating the intestines before removing them. *Sponges* are a necessity which are readily procured, and should always be moist when in use. Nauwerck keeps them in a creolin solution, but carbolic acid is better (two per cent.). F. W. Andrews¹ prepares a disinfecting solution by dissolving 37 grammes of ammonium persulphate, $(\text{NH}_4)_2\text{S}_2\text{O}_8$, in 950 cubic centimetres of distilled water, and then adding 11 cubic centimetres of strong hydrochloric acid. The mixture when first made up has no extraordinary germicidal powers and must be allowed to stand for several days before using, when it will then appear as a perfectly clear solution and remain efficient for many weeks. The sponges are first thoroughly cleansed and become sterilized within an hour after being placed in the mixture. Moreover, discolored sponges are bleached and renovated, a sojourn of two or three days in the mixture being requisite for this purpose. *Pins* are useful in fixing small structures in course of dissection. Special *tables* of zinc-covered wood, slate, iron, or glass are desirable in a pathologic department. Rotating tables are convenient, but weighing tables are expensive. The table should be constructed so as to carry off all fluids into a receptacle provided for them. (See p. 11.)

Rubber gloves that reach well up the wrist and *finger-cots* afford protection to the pathologist, particularly in cases where the danger of infection is great. The gloves are more readily put on and are preserved by dusting them freely with *ground soapstone* kept in a dusting bottle. (See p. 46.) *Museum jars* of various sizes or clean glass bottles with glass stoppers are useful for preserving gross specimens, and two-ounce, *wide-mouth bottles*, for microscopic specimens. *Sealing-wax* is needed to close the jar with after it has received the

¹*Lancet*, October 14, 1905.

contents of the stomach in a case of poisoning in order to prevent its contents being tampered with. *Bromin* in a strong bottle with a ground-glass stopper that fits well serves a good purpose in disinfecting fresh wounds. Formaldehyd and distilled water should always be at hand.

Pails are needed as containers for water and to receive fluid removed from the body. *Cotton-wool, sawdust, or tow* placed in the large cavities of the body before they are closed prevents the escape of fluid from them. An amusing story is told of a professor of pathology in Philadelphia whose assistant used a self-raising buckwheat flour for this purpose; the formation of gas was so great that an explosion took place in the night. *Plaster of Paris* and *sand* serve similar purposes in the cranial cavity. *Disinfectants* and *deodorants* should not be forgotten, as it is desirable to destroy or neutralize odors emanating from the body, and to disinfect and deodorize the hands of the pathologist after the examination has been completed. *Bellows* are occasionally useful in inflating viscera, as the lungs or stomach. A *hand-bag* which may be properly cleansed is often required for the carrying of the requisites to a postmortem.

The *chemic, bacteriologic, and microscopic* supplies required in the work of the pathologist at the postmortem are red and blue litmus paper, turmeric paper, Lugol's solution, solution of sulphid of ammonium for detection of free iron derived from bile pigment (as in pernicious anæmia), Gabbett's solution, carbol-fuchsin, Löffler's alkaline methylen blue, absolute and commercial alcohol, ethyl chlorid or methyl chlorid; culture tubes containing blood-serum, agar, and gelatin (bouillon is troublesome to carry); an alcohol-lamp, glass slides and covers for microscopic specimens, filter-papers three or four inches in diameter, an old scalpel which can be heated, a platinum wire three inches (eight centimetres) long, set in a solid glass rod six inches (fifteen centimetres) long, for making cultures (called an öse),¹ a microscope, a freezing microtome, and easy access to an incubator. A Paquelin thermocautery or one of the simpler forms now so commonly used for wood burning is very useful for bacteriologic purposes.

In my own experience it has been found desirable or convenient to discard one instrument after another until now my satchel for

¹ Wetherill has recently suggested the use of an electric öse, the platinum wire being connected to a hand-battery of sufficient strength to cause the metal to glow when the current is turned on.

private work weighs with its contents but ten pounds, and contains the following articles: two section-knives *in good condition*; a scalpel; a pair of medium-sized, strong scissors; a pair of bone-forceps; a dissecting forceps; a saw; an enterotome; a hammer with a hook on its handle; a pelvimeter; a new rubber catheter; gummed labels; various kinds of litmus paper; sealing-wax; a dissecting-apron and sleeves; a pair of rubber gloves, with plenty of ground soapstone in an iodoform-dusting bottle; finger-stalls; a piece of thin rubber sheeting 30 by 45 inches; a square yard of oiled silk, or a rubber bag (10 by 16 inches) from which fluid will not escape; two medium-sized bath-sponges; a quart museum jar graduated into ounces or cubic centimetres, into which some of the smaller articles are placed and which can be used for the removal of gross specimens later, if desired; a large needle and flax twine, cut and wrapped (Fig. 52) into three lengths, for sewing the body with single thread (forty-five inches), for sewing the head (twenty-five inches), and for tying the intestines (ten inches); some bromin in a strong bottle with a well-fitting ground-glass stopper; two per cent. iodoform celloidin solution; a small roll of cotton; four two-ounce, wide-mouth bottles for microscopic specimens, one of which should be filled with seventy per cent. alcohol, one with ten per cent. formalin, one with Müller's fluid, and the fourth with a saturated solution of mercuric bichlorid; two ounces of creolin; a cake of one per cent. bichlorid of mercury soap; an öse; an alcohol-lamp; several culture-tubes properly packed; incense powders; matches; pins, safety and ordinary; a steel tape measure marked in inches and centimetres; a hand lens magnifying not less than ten diameters; spring scales weighing up to fifteen pounds; whetstone; an electric pocket lamp; and last, but not least, a note-book and several pencils, one of which will write on glass. To this list may be added other articles as the necessities of the case may demand or the individual ingenuity of the operator may suggest.

For the private use of the general practitioner, a large section-knife, a scalpel, an enterotome, a saw, a chisel, a mallet, a pair of scissors, and a large needle may be purchased for about five dollars. These should be kept rolled up in a piece of chamois-skin, preferably made with pockets into which the instruments fit, and if the latter be put away clean after use they are always ready for service; or a leather case (Fig. 53) may be employed.

In the U. S. Army the following post-mortem instruments are furnished in a mahogany box :

Blowpipe	No. 1	Knife, amputating, small	No. 1
Chains and hooks.....	No. 1	Knife, cartilage	No. 1
Chisel	No. 1	Needles and thread	No. 2
Costotome chisel	No. 1	Saw	No. 1
Enterotome	No. 1	Scalpels, assorted	No. 3
Forceps, dissecting	No. 1	Scissors, straight	No. 1
Hammer, steel	No. 1	Tenaculum	No. 1
Knife, amputating, large.....	No. 1		

In addition at the large hospitals, to which a pathologist is detailed, such other instruments are furnished as may be thought necessary, all stations, of course, being provided with sponges, basins, trays, etc. The medical department of the Navy supplies the same instruments as the Army with the exception that the large and small amputating knives are omitted and a director, a double-edge brain-knife, and a large aneurism needle are added.

The proper handling of post-mortem instruments is not acquired in a day, and the beginner will find that experience teaches many lessons which are not likely to be forgotten. A well-ground, keen-edged knife is a great desideratum, the advantage of a dull knife being simply that it is less likely to injure a beginner or careless operator and to disfigure the exposed portions of the body.¹

In opening the body free incisions should be made by an easy, untrammelled movement, executed by the muscles of the shoulder rather than by those of the arm or hand. It is essential that the knife be grasped firmly (Fig. 54), and not held like a pen, as is a scalpel in the act of dissecting the finer structures of the body. Virchow says that the knife should be held in the whole hand, so that when the arm is stretched out the blade extends with it. The fingers and hands are fixed, if not absolutely, at least relatively, and the motion is executed with the whole arm, so that the movement is principally in the shoulder-joint and secondarily in the elbow-joint. Thus the whole strength of the arm and shoulder muscles is brought into play and long, smooth incisions, so essential to proper inspection, are made. In cutting, pressure should be uniform, and the greater the pressure the quicker the knife should pass through the tissues. A clean cut made in the wrong

¹The various methods of holding and using the instruments will be seen illustrated by reference to the pages treating of the examination of the various organs.

place does less harm than a ragged one in the right place (Virchow). The portion of the blade near the handle should be used for work which dulls a knife, as cutting the ribs. This also applies to scissors, the part near the pivot being employed in all cases in which considerable force is required. When the knife is held as shown in Fig. 59 or 61, but preferably as in Fig. 61, the operator is sure to have a firm grasp of the knife-handle, so that there will be little likelihood of a dangerous slip. The actual cutting is properly and mainly done with the belly of the knife about one inch from its end, for which reason this part of the blade is always the thickest. The direction of the incision should invariably be *from* the operator, especial care being taken not to wound the left hand, and *from* those portions of the subject in which disfigurement would be most likely to be noticed. Care must also be taken not to injure the assistants or those standing near. When the resistance of a tissue is unexpectedly overcome, the knife will sometimes travel a considerable distance before it can be stopped by an effort of the will.

The blade of the knife must be kept free from blood by frequent washing. This is especially necessary when incising organs, as the brain, in which incisions are made with much more satisfaction if the knife-blade be previously moistened. A pointed knife may be used for the removal of the tongue and the larynx, and a scalpel for fine dissection, as in tracing the spermatic or thoracic duct and the fourth cranial nerve.

CHAPTER IV

THE CARE OF THE HANDS AND THE TREATMENT OF POST-MORTEM WOUNDS

BEFORE beginning the autopsy, especially in a purulent case, the pathologist should carefully examine his hands; if these be not in good condition, the notes may be dictated by him while some one else is doing the actual cutting. All rings should be removed and the finger-nails cut close, except possibly those of the thumb and index-finger of one hand, which may be left slightly protruding in order to grasp certain parts, as the capsule of the kidney, to facilitate its removal,—a feat often difficult of accomplishment without the use of an instrument, such as a knife, when rubber gloves are used.

Abrasions of the skin of the hands and forearms may be detected by the application of a ten per cent. solution of glacial acetic acid, which will at once reveal the location of such lesions by the smarting sensation that ensues. Slight wounds on the hands may be protected before beginning the necropsy by placing a small piece of absorbent cotton upon them and then applying the ordinary thick celloidin used in bacteriologic work, or the two per cent. iodoform celloidin already referred to. Varnish such as is used to coat pictures, liquid gutta-percha, or liquid court-plaster may also be employed for this purpose.

It was once the custom for pathologists before making an autopsy to anoint their hands and forearms with some antiseptic salve, such as vaselin containing boric acid, ten grains to the ounce, a ten per cent. carbolic acid ointment, or an alcoholic solution of balsam of Peru. If these be used, they should be renewed several times during the postmortem. It is, however, doubtful whether the advantages gained by their employment are not more than offset by the fact that the hold upon the instruments is thereby rendered less secure. This can to a certain extent be avoided by fully anointing only the left hand (the one which handles the tissues) and the back of the right (the hand that holds the instruments), thus limiting the application of the protective to those parts through which infection usually takes place when no mechanical injury to the hands is inflicted. Frequent washing of the hands in clean water is regarded by many as decidedly

better. Of course, when digital investigations are necessary, as in exploring fistulous tracts, examining the vagina and os uteri, and in certain kinds of peritonitis, antiseptic unguents are desirable; in such cases it is necessary to anoint only that hand or portion of the hand which comes in contact with the tissues under investigation. It is also an advantage sometimes to introduce carbolized vaselin into the crevices around the finger-nails.

An equally efficient and in many respects a much better safeguard against infection is the use of rubber gloves. Those should be selected which are neither too thick nor too thin, and not the old-fashioned thick black, red, or white gloves. They should be provided with long sleeves, and should be purchased from a reliable dealer who has not had them too long in stock, as they markedly deteriorate by age. They fit snugly, and are especially useful when opening the stomach and intestines, as it is most frequently the intestinal contents which impart the odor that adheres so persistently to the hands. They do not prevent, though they to a certain extent hinder, the production of post-mortem wounds. After use they should be washed both inside and out with water to which a little washing soda has been added and scrubbed with a nail-brush until clean, rubbed lightly with a towel or absorbent lint until thoroughly dried, and then carefully dusted with powdered soapstone or with talcum powder. Either the weight of the water or pressure of the air may be used to force the everted fingers straight. With care rubber gloves may be sterilized in the autoclave. *They should never be put away moist or dirty.* Small openings may be patched in the same manner as a bicycle or automobile tire. Should the postmortem be upon a metallic poison case, a new pair of gloves should be used, and another pair from the same lot reserved unused for possible future examination by the chemist. Those of us who have made many hundreds of autopsies with our naked hands feel that we lose that delicacy of touch so desirable in post-mortem work when gloves are employed. Letulle,¹ in his recent work, enters into a tirade against their use. The coming generation will, however, undoubtedly wear them, or employ some such substitute as that recommended by Murphy,² of Chicago, who has recently suggested a method of dispensing with gloves in surgical opera-

¹ *La pratique des autopsies*, 1903.

² *Jr. Amer. Med. Assoc.*, September 17, 1904.

tions. This consists in the application to the hands of a four to eight per cent. solution of gutta-percha in benzin or acetone, the former giving the better satisfaction in routine practice, as it is more lasting. The coating may have to be renewed during the operation, and when removed, by washing in benzin, leaves the hands soft and smooth. Rubber finger-stalls, especially the variety known as the seamless rolled finger-cot, which unrolls as it is placed on the finger, are useful if the operator have any hangnails or other abrasions of the fingers. They often break, however, during the performance of the autopsy. Blood, pus, or other fluid should not be allowed to dry upon the hands, upon the gloves, or upon the instruments used. Upon the hands they not only impair the delicacy of touch so desirable in this work, but may also cause unsightly stains upon the skin, which are difficult to remove, especially when certain preservatives have been employed in embalming the body. Simmonds¹ uses a thin rubber coat, the sleeves of which overlap the rubber gloves, the point of contact being made watertight by an elastic band.

The hands may usually be freed from odor by applying to them, while still wet, either a few drops of turpentine, formic aldehyd (from one to two per cent.), aromatic spirit of ammonia, *liquor antisepticus*, U. S. Pharm., 1900, paregoric, or mustard, and then washing them thoroughly with a good glycerin soap. The use of equal parts of hypobromite solution (used in the quantitative estimation of urea) and of water, while severe, is also very effective for this purpose. A five per cent. chloral hydrate solution may also be employed.

For disinfection of the hands after the postmortem one may use a creolin solution, made by placing about an ounce of creolin in a basin of tepid water;² a mixture of two teaspoonfuls of acetic acid, twice this amount of calx chlorinata, and a quart of water; bichlorid solution 1 to 1000; ninety per cent. alcohol; or a concentrated solution of potassium permanganate. The brownish discoloration of the hands may be removed by applying to them while still moist either oxalic acid or a concentrated aqueous solution of the bisulphite of sodium to which has been added a small amount of chlorin; or an antiseptic soap may be employed. Of the latter, I prefer the one per cent. bichlorid of mercury soap, or a ten per cent. lysol

¹ *Centralbl. f. allg. Path. u. path. Anat.*, 1906, vol. xvii, no. 1.

² Or, more exactly, a two per cent. creolin solution.

solution made with the tincture of green soap. Of course, any of the surgical methods in vogue for disinfection of the hands may be employed. Hand brushes may be kept in five per cent. formalin solution, as this keeps the bristles stiff and clean. At the end a sodium bicarbonate wash and the application of a little lemon juice leave the hands in good condition. A brisk walk in the open air is also to be advised after the completion of the autopsy.

A post-mortem wound, as usually referred to, means not only a break in the continuity of the skin by an accidental incision, puncture, or other injury received at an autopsy, but also the inoculation therein of pathogenic bacteria from the cadaver, and their subsequent multiplication in the system, with the production of toxic symptoms. Wounds presenting similar characteristics may, of course, be derived from many sources, as from surgical operations or from other post-mortem wounds. The intact skin of the hand is a perfect protective against the invasion of bacteria. In order that the organisms may infect the body, there must be both a point of entrance and a predisposition or lack of immunity in the individual affected. While any of the infectious diseases may be contracted in making a post-mortem, those most to be feared are tuberculous warts, syphilis,¹ gonorrhoeal ophthalmia, tetanus, anthrax, glanders, plague, actinomycosis, typhus fever, yellow fever, cholera, and smallpox. I have seen septicæmia, general tuberculosis, ulcerative endocarditis, purulent meningitis, boils, whitlows, etc., follow post-mortem wounds. Several years ago one of my patients suffered from a tuberculous wart which he had evidently contracted from a cow, thus adding another case to the list of those affected with bovine tuberculosis.

The results of a post-mortem wound depend very much upon the general health of the one affected, and experience seems to show that severer symptoms and slower convalescence may be expected in those who are habituated to the use of alcohol. Inoculations from serous surfaces are especially to be guarded against, as from some of the varieties of peritonitis due to criminal abortion, and other forms of

¹ J. DE LISLE (*Amer. Med.*, Sept. 19, 1903) writes, "Medical records furnish no instance of a specific contamination resulting from a wound received during the autopsy of a syphilitic cadaver." BLASCHKO (*Berl. klin. Wchschr.*, 1904, vol. xli, no. 52) reports a case of syphilitic infection, unmistakably derived from the dissection of a syphilitic cadaver twenty-four hours after death. The *Microspironema pallidum* has also been found at autopsy.

septic peritonitis, meningitis, or pleurisy. Among other virulent kinds of post-mortem wounds may be mentioned those derived from cases of pyæmia, of septicæmia, of puerperal fever, of malignant œdema and diffuse cellulitis, of erysipelas, and of gangrene. Infection by the *Bacterium pyocyaneum* may cause long-continued high temperature with little local manifestation, as in my own case when I became inoculated with this organism from a case of cancer of the gall-bladder with secondary infection by this bacillus.

It is often asked why post-mortem wounds and injuries received in the performance of similar operations are more dangerous than those which are otherwise inflicted, though containing the same organism. Their greater virulence may in part be due to the fact that they are usually punctured wounds, in which the organisms are implanted deeply in the tissues, especially in cases of tetanus, which is due to an anaërobic bacillus. Again, it is well known that many organisms become more virulent by passing through successive animals, and, therefore, an organism which has overcome the resistance of the tissues and killed them is naturally more destructive than one which has not had such favorable opportunities for growth. It has been shown experimentally that bone-marrow possesses marked bactericidal properties. It is a well-established clinical fact that wounds produced by sharp spicules of bone are unusually severe. The reason assigned is that bacteria which have already overcome the increased resistance of the bone-marrow have now been introduced into the body.

Post-mortem wounds are generally caused in one of four ways: first, by the operator injuring himself with instruments used in the making of the autopsy, especially sharp-pointed knives and the saw; second, by scratches or punctures from ragged bones or calcified tissues, as the ribs or atheromatous patches of the aorta which have undergone calcareous infiltration; third, by inoculation of pre-existing wounds, abrasions, small eruptions, especially at the roots of the hair-follicles, hangnails, blisters, fissures in chapped hands, by infection from unsterilized instruments, by subsequent injuries received upon unsterilized hands, etc.; and, fourth, by cuts and scratches accidentally inflicted by the operator on his assistant, as in opening the head. Indeed, so frequently does the latter occur that a helper to steady the head should be dispensed with unless his hands be thoroughly protected by some covering, such as a towel. Some of the usual ways of producing wounds which are especially worthy of men-

tion are by the operator cutting towards instead of away from himself or his assistant; by leaving a knife in one of the cavities and forgetting its presence; by placing his instruments in a dangerous position on the body, the table, or the ice-box; by the use of sharp-pointed knives; by punctures from the needle made during the sewing up of the body; and by the too rapid passage of thread through the hands, producing a sort of brush-burn. Ragged wounds, such as those caused by the saw or by bones, are especially to be dreaded, for, being both punctured and lacerated, they easily become infected.

The micro-organisms present at a postmortem made several days after death are apt to be less virulent than those encountered soon after dissolution, the saprophytes having now gained the mastery. Other things being equal, the more quickly the patient died after infection, the more dangerous will be the post-mortem wound; but the character of this lesion and the nature of the organism must always be considered. Undoubtedly, persons making many postmortems become immune to inoculation by the ordinary *Staphylococci* and *Streptococci*. When toxins are introduced along with the bacteria, the constitutional symptoms are apt to be more severe, as the toxins overcome a certain amount of vital force at the point of infection of the tissues which would otherwise aid in combating the micro-organisms.

As is well known, the bleeding of a wound is a considerable protection thereto; hence its immediate closure by the application of caustics or of celloidin is worse than useless. If the finger be wounded, it should be wrapped with a miniature Esmarch band and allowed to bleed freely under running water for at least five minutes, or the part may be washed in distilled water made alkaline by the addition of sodium bicarbonate, cleansed with equal parts of alcohol and ether, and then washed with an antiseptic solution. Sucking of the wound after cleansing has been practised. If a caustic be used, there is probably nothing better than glacial acetic acid, carbolic acid, or pure bromin. The employment of the actual cautery is advisable in some cases, but it must be so thoroughly applied that no pathogenic organisms are left behind, as otherwise the necrosed tissue affords a favorable medium for their growth. A fifty per cent. alcoholic dressing, moist mercuric bichlorid gauze, or dry sterile gauze is now applied, which should be renewed twice daily. On the slightest indication of pus or a deadish-gray appearance of the edges of the wound, it should be freely incised, thoroughly curetted, cleansed

with a sterile salt solution, dusted with iodoform, and protected with a wet bichlorid dressing; or a solution of silver nitrate may be applied with benefit. I have seen no good effect from the local use of the unguentum Credé (ointment of fifteen per cent. soluble metallic silver). The frequent application of hot flaxseed poultices containing a teaspoonful of Labarraque's solution is most grateful when the wound is discharging. Several inches above the wound a ring of iodine should be plentifully painted. Intravenous injections of antitoxic sera, collargol, formalin, and silver nitrate have been practised by some with alleged benefit in septic affections. Hume injects intravenously five hundred cubic centimetres of water containing one-half cubic centimetre of a ten per cent. solution of the nitrate of silver at a temperature of from 110° F. to 115° F.

Involvement of the lymphatics, as manifested by red lines running up the arm, usually on the inner surface, and tenderness in the axilla, indicates danger, and shows that the infection is no longer a local one. Inflammation of the lymphatics of the axilla may cause the glands in this region to become tender and enlarged, so that an incision is necessary; and in cases of axillary cellulitis, even though the wound of inoculation be small, early opening should be employed. Quinine is useful in these cases, and phosphoric acid and iron may be prescribed later. The affected arm should be carried in a sling, tonic treatment with changes of air instituted, and a surgeon consulted, who will treat the case according to the character of the wound, the nature of the infection, and the constitution of the patient. When healing has begun, massage has made many a serviceable finger or hand out of what would otherwise have been a stiff and useless one.

The anatomic wart is a local tuberculous lesion, often multiple, and is usually situated on the back of the hand or at the inner joints of the fingers. There is a warty thickening of the papillæ of the skin, accompanied by a discharge of thin serous pus, but with no true ulceration. The sensation produced is similar to that caused by a splinter, which, however, subsides for several days after the removal of the fluid contents. The lesion sometimes heals spontaneously, but may give rise, as in the case of one of my helpers in the post-mortem room at Blockley, to general tuberculosis. Wet dressings, combined with an application of equal parts of glycerin and extract of belladonna, may be employed, or the following mixture applied: Salicylic acid, 10 parts; extract of cannabis indica, cocaine hydrochlorate, of each 1

part; oil of turpentine, 5 parts; glacial acetic acid, 2 parts; and collodion, 100 parts. It would be interesting to try the hypodermic injection of tuberculin, or some of the newer forms of treatment of lupus of the face, as that of the concentrated rays of light recommended by Finsen. In one of my cases treated by the X-rays in 1896 I thought that an anatomic wart was rendered worse by their use. When tuberculous warts have lasted several months, surgical treatment should be instituted, care being taken to remove them in their entirety without cutting into the diseased area. Guinea-pigs injected with such material, which contain but few bacilli, usually linger a long time; in one of my cases over six months elapsed before the animal died from general tuberculosis of a fibroid nature.

Suppuration of the matrix of the nails can often be cured only by the removal of the nail, though frequent soaking of the finger in a hot saturated solution of boric acid or a strong solution of lead subacetate may be tried. Or the nail may be soaked in a solution of silver nitrate—twenty grains or more to the ounce—and then wrapped in a moist bichlorid of mercury dressing. Dropping upon the wound a saturated solution of iodoform in ether has also been tried. Diffuse cellulitis should be treated by early and free incision and by the application of compresses. When the hand itself is involved in spreading gangrene, amputation should usually be practised. If tetanus is feared, the wound should be laid open and the area of contagion, if possible, removed, powdered antitoxin applied to the part, and the general health of the patient sustained. The subdural use of the antitoxin and, better still, direct injection into the spinal canal have recently been employed.

If the knives used in post-mortem work were thoroughly sterilized after each necropsy, there would be fewer infected wounds. For this purpose they should be boiled for five minutes after use in a one per cent. soda solution, the edge of the knife being protected, as by wrapping in cloth, so as not to dull it. Entres recommends one-half per cent. formalin or the use of tablets of mercury oxycyanide 1 to 1000. The making of autopsies is undoubtedly dangerous, and therefore those who perform them frequently should insure themselves in one or other of the accident companies which contain a clause giving a claim for benefits in case of wound-infection. As these companies generally show a marked disposition to dispute claims, every injury, no matter how slight, should be reported to them as soon as possible after its occurrence, so that any subsequent damages may be easily proved.

CHAPTER V

EXAMINATION OF THE EXTERIOR OF THE BODY

SIGNS OF DEATH.—The signs of death are of two kinds,—those which manifest themselves immediately upon the extinction of life and those which appear only after the lapse of a shorter or longer period of time, and vary at the time of dissolution according to the age, muscular state of the body, disease, presence of certain poisons, etc., and the external conditions surrounding the body. The later signs are the more positive, but the earlier ones are of more importance from a utilitarian point of view. Taken individually, each sign may be inconclusive, but when considered collectively they give a scientific authority to the generally only too apparent fact that death has taken place. Cases of trance and the Indian fakirs afford the best illustrations of suspended animation. Authentic instances of persons having been buried alive during suspended animation are almost unknown,¹ investigation of the newspaper accounts of such premature interments in almost every instance showing their falsity. In Munich the popular belief in such occurrences is so great that the bodies of those dying in the higher walks of life are kept for several days previous to burial in a specially prepared room, a bell being placed in the hands of the corpse for the purpose of summoning an attendant in case of resuscitation. Such notions usually originate from careless handling of the coffin, from the expulsion of a fœtus by the formation of gases in the body of a pregnant woman, from real or apparent growth of hair, from conversion of bodies into adipocere, etc. In a judicial hanging the murderer is ordered to be hung by the neck until he is dead. The responsibility of fixing this time naturally devolves upon the physician. It was recently brought out at an inquest held in England that a child nine days old was pronounced dead by a physician after twenty minutes of observation; the child was later on discovered to be living and remained so for over eighteen hours.

It is not possible to draw a sharp line between physiologic and pathologic death. Even when what we call "death" has taken place, the function of all organs has not ceased, the most important organs,

¹ See ICARD, *Presse méd.*, no. 66, 1904.

heart, lungs, and nervous system, sometimes continuing their activity. Functionating of the intestinal tract, liver, and kidneys may cease and yet the patient live several days before death ensue. The senses may be lost without ending life.

The earlier or negative indications of death are, first of all, insensibility and inability to move, often preceded by the so-called death-rattle. There are loss of sensitiveness to stimuli, loss of reflexes, failure to respond to inflammation, and the cessation of all bodily vitality, though in cases of sudden death spermatozoa may be found in movement twenty-four hours after decease and atropine will dilate and physostigmine will contract the pupils as long as molecular life exists in the ocular tissues. Loss of nervous and muscular irritability is determined by application of light to the eye, of snuff to the nose, or of cold, heat, force, electricity, or other irritants to the skin. Rosenthal considers the existence of electric contractility in a dead body to be an indication that death has taken place within two or three hours. After the head is severed by the guillotine the eyes may open and close and in amputated limbs muscular twitchings may often be seen even for hours after their complete removal from the body. Associated with the change in muscular tonicity is the facial expression. During the period of relaxation the visage is pale and flaccid, except in very rare cases, where the face even immediately before death has a red color and there is a drawn, contracted, painful expression, the so-called *facies Hippocratica*.

Much more positive signs are the entire and continuous cessation of the respiration and circulation. As a rule, respiration stops a moment or so before the heart-throbs and ceases sooner in infants than in adults. The absence of breathing may be determined by auscultation and by the lack of motion of a down feather or small flame or by the absence of the deposition of moisture on a cold mirror held before the lips. A glass of water or of mercury placed upon the epigastrium will show a ripple on its surface if there be the slightest movement of respiration (Winslow's test). The X-rays have also been used to detect any activity of the heart and lungs.

Most of the minor signs of death depend upon the absence of circulation. This is determined first by observation. The skin of a dead person acquires almost immediately a leaden pallor or lividity and loses its translucency. The mucous membranes become pale and exsanguinated. The hands if viewed by strong transmitted light show no pink tinge where the fingers come in contact (diaphanous test).

The palms and soles of the feet become more or less yellow in color. By palpation and auscultation the absence of pulse and heart-beat can be determined. A small artery, as the temporal, may be incised and examined; after death it will be found empty and its lining will be of a pale-yellow color. The mercury in the manometer records zero. Scarification or cupping on a dead subject causes no flow of blood, while ammonia injected subcutaneously produces no congestion. In Icard's test¹ fluorescin (resorcin-phthalein) is injected subcutaneously; if life be present, greenish discoloration of the skin, mucous membranes, and eyes soon appears and the staining material may be chemically detected in blood abstracted at a distance from the point of injection. A tight ligature around a finger, a limb, or the lobe of an ear will give rise to no reddening (Magnus's test). Pressure applied to a finger-nail will drive the blood away, leaving a white area, which will again be filled with blood if there is any circulation. If a flame or heat of any kind, as from melted sealing-wax, is applied to the skin, and a vesicle is formed, the blister on the dead skin will contain a non-albuminous fluid and the underlying cutis vera will remain dry and glazed, while in the living the contents will be rich in albumin and the cutis vera will be reddened. Caustics applied to dead skin will form no eschar, but may make the skin yellow and transparent. A steel needle plunged into a muscle after death has occurred will not be oxidized, even though it remain in place for many hours, but would tarnish in ten seconds if life were present (Glaister). Brissemoret and Ambard² assert that the viscera, especially the liver and spleen, rapidly lose their normal alkaline reaction and become acid after death, even within a quarter of an hour after dissolution. The blood of the part should be removed, as far as possible, before testing.

Besides these tests, there are changes in the eyes which are very important signs, and are in a great measure due to the loss of circulation, and later on to the evaporation of fluids, especially if the eyes be not closed. The fundus oculi is of a pale-yellowish white and its vessels are empty or the column of blood in them is beaded by the presence of bubbles of gas. There is a marked loss of elasticity in the eyelids and in the globe. The eye collapses, sinks back in the socket, and appears flat and wrinkled, due to the loss of the vitreous and aqueous humors; it loses its lustre and presents a glazed appearance. In

¹ *Le danger de la mort apparente sur les champs de bataille*, Paris, 1903.

² *Virchow's Archiv*, vol. clxxviii, no. 1.

some cases it is soft and flabby and may be covered with viscid mucus; more rarely, as in apoplexy or hydrocyanic acid and carbonic acid poisoning, it remains bright, full, and prominent for a considerable time. The conjunctiva quickly becomes cloudy and gray. The cornea may become opaque immediately after death or during the last hours of life; in other cases it does not change until the lapse of several hours. The cornea, iris, and conjunctiva lose their sensitiveness. In the last agony or shortly after death the pupils dilate, and again in about an hour they contract, as a rule unequally; this contraction lasts for three or four days. The loss of elasticity in the eye is very marked; the pupil can be made oval and will remain oval by synchronously compressing the globe (Ripault's test). This may, however, occur before death. In most cases death occurs with the eyes and mouth open. This rule holds good especially in asphyxiation and sudden death, while in coma the eyes may remain closed. Owing to the unclosed eyelids, the sclerotic is exposed to the air and permits the water to evaporate, thus forming a dark oval stain on the temporal side of each globe (Larcher's sign).

Another sign is loss of vital warmth (*algor mortis*). This occurs more rapidly at first than on nearing the temperature of the surrounding atmosphere. Clothing, fat, etc., cause the lowering to take place more slowly. Wilks and Taylor show that at an average temperature a nude dead body cools at the rate of about one degree Fahrenheit per hour. A body placed in water will cool more rapidly than in air of a similar temperature, and refrigerants naturally reduce the temperature quickly. Nysten finds¹ that the bodies of those killed by lightning or by suffocation retain their heat longer than when death is due to other causes. Post-mortem cooling requires under normal conditions, as a rule, twenty-three hours for its completion. Brouardel says that the rectal temperature ordinarily is the same as that of the room in about forty hours. In the bodies of those who have died from some of the zymotic diseases, as cholera, tetanus, variola, etc., from injuries to the nervous system, or from certain abdominal disorders, the temperature may rise soon after death, and an elevation has also been noted during the period of muscular rigidity. Where decease is due to some chronic affection chilling is slow, while after fatal hemorrhage it is very rapid.

¹ *Arch. gén. de méd.*, June, 1862.

DECOMPOSITION.—The most positive sign of death is putrefaction, which appears as rigidity passes off after a longer or shorter time, and manifests itself first by a foul odor and a prominence of the superficial veins and by a greenish color in the iliac fossæ and the centre of the abdomen, later on in the genitalia and thighs. Finally the whole body is involved. It becomes purplish red in color, due to the posthumous circulation, which is a displacement of the blood from the heart and large vessels by the pressure of the gases of putrefaction formed in the abdomen. The tissues soften and are more easily torn. Putrefaction succeeds death by snake poisoning at once, because it fixes itself to one of the factors (complement) which render the fluids of the body non-bacteriolytic. (Flexner.) Mummification and adipocere show that death took place some time ago. The bodies of infants decompose more quickly than those of adults. The process begins earlier in plethoric and fat adult bodies than in thin, aged persons. It is more rapid after muscular activity and in those dead of acute diseases, fevers, jaundice, heat-stroke, sepsis, suffocation by gases, etc., while it is longer delayed in cases where the system is exhausted and muscular irritability retarded, and in the bodies of those fatally poisoned by hydrocyanic acid, carbonic acid, sulphuric acid, etc. Arsenic may or may not prevent decomposition. At the same temperature a body which has been for one week in the air, one which has been two weeks in water, and one which has been eight weeks buried will show similar degrees of decomposition. (Brown-Séguard.) In the cases of Hickman and Holland the kidneys of certain exhumed bodies had resisted the agents of disintegration to a greater extent than had the uterus.¹

Hofmann recommends, in cases where decomposition is much advanced, the removal of the brain in the ordinary manner, the making of some openings in the skin, the washing of the entire body in running water for twelve hours, and the further bathing of the corpse in a concentrated alcoholic sublimate solution or chlorid of zinc for an equal period. The green coloration due to decomposition disappears to a marked degree under this treatment.

POST-MORTEM OR CADAVERIC LIVIDITY; HYPOSTASIS OR HYPOSTATIC CONGESTION (*Livores mortis*).—Unless drained of its blood by previous hemorrhage, a corpse usually shows a bluish-red to purplish-

¹ *Lancet*, December 26, 1903, p. 1797.

red discoloration on its most dependent parts, due to the cessation of the circulation and to the gravitation of the blood to those organs. The discoloration does not, however, appear upon those portions of the body upon which it directly rests. It will at once be seen that this fact may afford a basis upon which to form an opinion as to the position in which a body has lain after death. Cyanotic changes, as in the fingers and toes, may remain after death. Post-mortem lividity rarely comes on before five hours; though it may start even before death, as in cholera. It reaches its maximum in the second day and shows itself not only on the exterior of the body, but also on the dependent parts of such internal organs as the posterior wall of the stomach and the temporal lobes of the brain. Cadaveric lividity may resemble a bruise made during life, with all its various forms and shades of color. The distinguishing features are: (1) The discoloration in post-mortem lividity disappears on pressure, while that due to a bruise does not. (2) A patch of post-mortem lividity will bleed freely when incised, because the vessels in the dependent parts are engorged with blood, while from a bruise there is little or no oozing, as the original hemorrhage is circumscribed and the discoloration is due to extravasated staining of the tissues and not to the actual presence of blood. The epidermis prevents the drying of the skin; when this is removed, leathery patches are seen. An incision into the affected area should therefore be made in all suspected cases, especially in those of a medicolegal character. If the part be washed with running water, blood will appear again and again in hypostatic congestion. The two conditions are more closely simulated in those rare cases of hypostasis where we find a post-mortem cedematous infiltration and enlargement of the adjacent tissue. Should such exist or should the two conditions be combined, it is well to free the suspected area from the hypostatic congestion by turning the body on the opposite side for several hours before describing the bruise. As a rule, the more fluid the blood, as in cases of death from suffocation, the acute infectious fevers, poisoning by hydrocyanic acid, etc., the more marked will be the post-mortem lividity. In the latter case, as well as in poisoning by illuminating gas, the lividity may be of a characteristic rose-red color. In potassium chlorate poisoning it is chocolate colored. In the negro the effects of cadaveric lividity are naturally more difficult of determination than in the white race.

POST-MORTEM RIGIDITY OR DEATH-STIFFENING.—The involuntary muscles first show contraction,—eyelids and heart¹ primarily,—and it is doubtless this action which sometimes causes the expulsion of a fœtus after death. Post-mortem rigidity commences externally in the muscles of the lower jaw and neck and spreads downward, disappearing in the same order, though Lacher, from an examination of six hundred bodies, found the condition to occur last in the arms. In ordinary cases it begins about two hours after death, is complete in from seven to eighteen hours, and ends as the stage of putrefaction comes on, in three or four days. Brown-Séguard mentions a case of typhoid fever where rigidity came on in less than four minutes, disappeared in a quarter of an hour, and putrefaction commenced in one hour after death. The stronger the individual and the shorter the duration of the fatal disease, the more prompt and marked usually will be the rigidity. The bodies of soldiers killed by being shot in battle after forced marches sometimes retain the position they occupied when they were hit, in certain cases even remaining erect when killed standing. The case of Captain Nolan at Balaklava is often cited in this connection, where it is alleged that he held a sword and with extended arm rode on horseback in the charge after death had ensued. The position of the hands produced by this muscular rigidity is also an important sign. The thumbs are usually flexed across the palms and the fingers flexed over the thumbs. Instantaneous rigor of the hand of a suicide may occur, a weapon being grasped tightly in the hand. This condition cannot be reproduced artificially, and shows high mental tension, nerve excitement, suicide, and not murder. Rigidity is marked, especially in the abdominal muscles, after death from cholera. De la Camp² has shown by X-ray studies that the heart contracts in all directions and that the auriculoventricular openings may be closed thereby, but not before sufficient time has elapsed for blood to pass from the ventricles to the auricles. Rigidity is also seen at the pylorus and in an hypertrophied bladder. The body of one who has died from tetanus, strychnine, or other spinal poison, as *veratrum viride*, may lie supported only by the head and heels, or when placed upright may stand erect with little or no support. In one

¹ FUCHS, *Ztschr. f. Heilk. Abthl. path. Anat.*, 1900, p. 1.

² *Ztschr. f. klin. Med.*, 1903, vol. xlix, p. 411.

of my cases of strychnine poisoning rigor mortis was present on disinterment twenty-four days after death. Suffocation causes long-continued post-mortem rigidity. Chronic alcoholism delays and prolongs it. The more muscular the individual, the slower is it in coming on and the longer in going off. Rigidity disappears more quickly in cachectic subjects, and is sometimes almost entirely absent after heat-stroke. The process does not depend upon the nervous system, but upon changes taking place in the sheaths of the individual muscular fibres. Section of the ischiatic nerves will delay, but not prevent, rigidity of the legs.¹ Laceration of muscles retards or may even prevent it. The reaction of the muscles is at first acid, due to sarcolactic and other acids (sarcomere).² As the rigor mortis passes off the parts become alkaline, a condition natural to a decomposing body. It should be remembered that in the preparation of the body by the undertaker the rigidity may have been overcome by force; this is especially true of the elbows. On the other hand, be not deceived by a previously existing ankylosis. Rigidity may be overcome by the use of hot applications, but when it has once disappeared it seldom returns and is never again so pronounced as at first. Rapid cooling delays rigidity, which, however, passes off the more quickly when the body is once more made warm. This condition must be differentiated from freezing, where on reduction there is a crackling sound. Rigidity is not found in the *immature* fœtus. Evidence of the limbs and body existing in a state of cadaveric rigidity in the shape in which the child is moulded *in utero* is strong proof of still-birth.³

Bodies which have been kept for a long time (or a shorter time under unfavorable conditions) after death, especially during cold weather, present another form of cadaveric lividity which is characterized by a uniform reddish tint. This is caused by the diffusion of hæmoglobin from the blood-vessels into the surrounding tissues (imbibition). This form of lividity is most conspicuous along the course of the superficial veins and is not affected by pressure. Hæmolysis (disintegration of the blood) starts earliest in the portal vein (Revenstorff), aërated blood showing it last of all. In drowning this order is reversed. It is important to distinguish between post-mortem lividity

¹ BIERFREUND, *Arch. f. d. ges. Phys.*, 1888.

² Bruecke, Kuhne; quoted from ZIEGLER'S *Gen. Path.*, xi ed., p. 179.

³ *Brit. Med. Jour.*; *N. Y. State Jr.*, June, 1905, p. 216.

and the greenish discoloration of commencing decomposition, usually first seen over the abdomen. According to some authorities, the greenish color is due to the precipitation of the iron of the hæmoglobin by the hydrogen sulphid arising from the decomposition of the tissues under the influence of bacteria, while others teach that it is due to chromogenic organisms themselves or a pigment elaborated by them of iron, potassium, and cyanogen. In one of my cases such discoloration was mistaken for the effects of personal violence, and serious allegations based upon this error were made against the husband of the deceased.

The length of time which has elapsed since death has to be determined by the circumstances peculiar to each case. So many considerations may apply that in many instances it is dangerous to be too dogmatic.

EXTERNAL EXAMINATION OF THE BODY.—It is of great importance that we should not confine ourselves solely to the examination of the corpse, but should, in addition, carefully scrutinize the clinical history, weigh the evidence derived from a personal survey of the surroundings, consider the circumstances under which death occurred, and question the persons who came in contact with the subject just before and after death. Data derived from such sources are of especial value in medicolegal cases or when a postmortem is to be performed upon an unidentified body; but the knowledge acquired by inspecting the surroundings and the exterior of the cadaver must in no way bias the operator before the internal examination is made, as the unexpected may happen here as well as elsewhere. The naked body is then to be minutely inspected, first as a whole for symmetry and then both anteriorly and posteriorly as to its component parts, proceeding in a definite and orderly manner. It would indeed be to our advantage in acquiring pathologic knowledge if the living body in the nude state were more frequently made the subject of careful study, for the information thus obtained is often of the greatest value to the clinician and surgeon.

IDENTIFICATION OF THE BODY.—Before a postmortem is begun, the remains should, if practicable, be positively identified to the obducent by one or more persons who knew the individual during life. If this be impossible, the one who found the cadaver or those who saw it in its original situation after death and those that removed it from one place to another may act as identifiers. Persons who have gone under several names should be recorded under their legally

correct names, any aliases which had been used being also recorded. Certain details, such as articles of clothing, jewelry, and even pawn tickets, sex, age, height, weight, birth-marks, angioma, moles, tattoo markings, condition of the teeth, anomalies of the ear and eye, deformities, wounds, scars, or even the evidence of certain diseases, are of great importance and may often be the sole means of identifying the body. Should personal identification be impossible, a cast of the face, a photograph, and an accurate description of the body, with a full and clear statement of any peculiarities, should be made. In some cases a wax cast of the interior of the mouth, made afterwards in plaster, may be helpful. A set of false teeth or glasses should be preserved. As the person whose body is being examined may have been a criminal and thus during life have had the Bertillon system applied for purposes of future identification, these measurements and finger-impressions should be secured in important cases.¹ Skiagraphs of old osseous lesions, as well as a record of the teeth of the decedent and of their peculiarities, might also lead to identification. Clothing alone is not sufficient for purposes of identification, as bodies have been substituted and clothed in the wearing apparel of the alleged deceased, such substitutions being made in order to defraud life-insurance companies or change succession to titles and estates. The body of Admiral Paul Jones was identified in Paris one hundred and thirteen years after his death. A bust executed from life and a knowledge of his age and physical condition were the means of identification, coupled with a fair presumption of his place of burial. The corpse was that of a man forty-five years old with brown hair slightly turned gray. The body was well preserved in spirits in a leaden coffin. Chronic bronchial pneumonia and advanced interstitial nephritis were found. Admiral Jones was known to have had serious pulmonary symptoms and œdema of the lower extremities. Lortet recently examined microscopically the heart of Rameses II, who died 1273 B.C.

CARE OF CLOTHING AND A STUDY OF THE SURROUNDINGS.—The clothes may greatly assist the legal authorities in the prosecution of a case, as in showing the entrance but not the exit of a bullet. In such

¹ A recent case in England showed that the right thumb of one of the prisoners agreed with the marks left behind at the time of the robbery, there being twelve characteristics in common. Collins, of Scotland Yard, stated in the trial that only in two or three out of 80,000 cases had he found three characteristics to agree.

cases, where the clothing has not been already removed by responsible persons before the arrival of the physician, as is done in certain places (though this is scarcely justifiable), the examiner should observe the condition of the articles and their position, whether torn or soiled, displaced or reversed. If any irregularity is observed, he must determine, if possible, what significance may be attached thereto. For example, singeing about a recent small bullet-hole, with the powder markings pointing upward, would indicate that the powder used was black and not smokeless, that the weapon was discharged at close range, and that the trigger was held in the opposite direction,—*i.e.*, down.¹ (Plate VI, p. 449.) Again, seminal stains with marked disarrangement or tearing of the clothing of a female would strongly suggest—at least an attempt to commit—rape. The clothing in all such cases should, therefore, be preserved. Before securely wrapping and labelling, such perishable articles as one has decided to preserve should be disinfected and gum camphor or tar camphor added, in order to prevent their destruction by moths, as it is disappointing at or just before the trial to find the material so badly moth-eaten as to be useless for demonstrative purposes. Spots to be remembered, such as those made by blood or seminal stains, should be designated with thread or ink and a careful note made as to their exact location. In handing over to the proper legal officers articles for future use, it is well to place upon them in the presence of a reliable witness some mark of identification and to get a receipt for every article so delivered. The desire of the police to be on friendly terms with the reporters often renders the proper study of the surroundings impossible or misleading. In one of my cases—a brutal murder by violence—the scene had been visited by scores of persons and the body removed to an undertaker's before the writer was summoned to perform the autopsy. The importance of ascertaining the nature of the substance upon which the body rested when found was shown in another postmortem by my finding in the rectum of a four-year-old boy “needles” from a Christmas-tree and a similar “needle” upon the hat of the murderer and sodomist many blocks from the place where the crime was committed.

That the place where an unidentified body is found should be carefully stated is shown by one of my cases. A colored woman confessed the placing of the corpse of a new-born male bastard wrapped in a

¹ BRINTON, *International Clinics*, October, 1902.

shawl in an ash-barrel on the corner of A—— Street, Philadelphia, Pennsylvania, in which State the concealment of the death of an illegitimate child is a penal offence. The body identified at the post-mortem was that of a new-born colored babe wrapped in a shawl, but found in an ash-barrel situated at the corner of B—— Street, some two blocks away. On the plea of the lawyer for the defence that there was no *corpus delicti*, as the body found at B—— Street was not shown definitely to be the body left at A—— Street, the Judge decided that the trial should not proceed and ordered the jury to acquit. This was at once done, and, though new evidence might later be secured, it could not be used, as the woman could not have her life put in jeopardy a second time, though, as in the Mollineux trial, a man might once be condemned but on a new trial be acquitted.

SEX.—The sex is easily determined, except in hermaphrodites, where it is sometimes necessary to complete the autopsy and even then wait for microscopic sections before deciding as to whether or not the question can be definitely settled. An interesting legal question is whether an hermaphrodite should be allowed to choose to which sex he or she should belong or whether this should be settled by law.

RACE.—As the world becomes more cosmopolitan the racial question must receive more and more attention. It is of especial importance to designate mixed races; thus, in a colored person it is well to estimate as closely as practicable the amount of negro blood in the body under examination, as mulatto, quadroon, or octoroon.

AGE.—The apparent age should then be carefully considered. By apparent age is meant the age of the body as it appears to the judgment of the observer at the time of making the postmortem. A person may look older or younger than his or her *real* age, disease, mental depression, or dissipation often making the body seem many years older than it really is. *Per contra*, the signs of suffering may pass away, the features becoming relaxed and presenting a better appearance than they had done for many months before death. If the years cannot be estimated with any certainty, one may be able at least to designate the time of life as represented by the seven ages of Shakespeare.

HEIGHT.—The height is determined by measuring in a straight line from the vertex of the head to the centre of the external arch of the instep, the foot being flexed at a right angle to its plane of support. If a scale is not marked on the table and no other means of measuring is at hand, a piece of inelastic string or tape may be

employed for this purpose and measured later. The writer suggests the use of a measuring apparatus modelled on the style of a shoe-measure. A simple form can readily be made by taking two one-foot rulers, or other sticks of about the same size, and attaching, one inch from one end, a seventy-eight inch tape measure, which is made to run through a transverse slit one inch from the top of the other ruler. If a tape measure of this length is not at hand, forty-two inches of inelastic tape may be sewed together and this attached to a measure of ordinary length. The first ruler is held close to the foot, which is placed in a vertical position, and the other stick is held parallel to the first stick by an assistant standing at the head of the corpse, and the tape is drawn until it is taut. When not in use the tape measure is wound around the sticks. Next measure the circumference of the head and shoulders. Should there be shortening of a limb, or atrophy, as in fracture and in infantile paralysis, full measurements of both limbs are to be made.

Certain abnormalities of stature are occasionally seen, such as: (1) Dwarfism, a condition which may be congenital or acquired. If acquired it may be either cretinoid or rhachitic, and is often associated with sterility, impotence, bone deformities, or atrophy of the thyroid. (2) Giantism appears in two types, infantile and acromegalic, which are intimately related. From the literature on this subject, it would seem that acromegaly frequently follows giant growth or even the period of excessive growth. This condition is often accompanied by an abnormal development of the genitalia and changes in the vascular glands, especially the pituitary and the thyroid. (See also p. 257.)

If only part of a body is present, as in the case of Wakefield Gaines, where the trunk alone was found, the length may be approximated from various data. If the head and upper extremities remain, twice the length of the arm from the midsternal line to the tip of the middle finger, measured along the flexor surface with the arm in abduction, or the distance between the tips of the middle fingers along the flexor surface, with the arms extended at right angles to the main axis, will about equal the height of the individual. If but one extremity is present, twice the length measured from the glenoid cavity plus one-half the distance between the glenoids measured between perpendicular lines, or nineteen times the length of the middle finger, equals the approximate height. Other means of computing the height are: (1)

The distance from the tip of the olecranon to the tip of the middle finger is five-nineteenths of the height. (2) The upper border of the symphysis pubis in an adult is the midpoint of the adult's height, but this is not trustworthy in women or persons with deformities. (3) From the head of the femur to the plantar surface of the heel is one-half the height, while the length of the femur is one-quarter the height. (4) Orfila has shown, however, that from one of the long bones alone the exact determination of the length of the body is impossible. Manouvrier in cases of extremely short or long bones multiplies by coefficients to secure the height, as follows: ¹

MEN.

FEMUR.	TIBIA.	FIBULA.	HUMERUS.	RADIUS.	ULNA.
Less than 392 mm.	less than 319	less than 318	less than 295	less than 213	less than 227
COEFFICIENT.					
x 3.92	x 4.80	x 4.82	x 5.25	x 7.11	x 6.66
More than 519 mm.	more than 420	more than 413	more than 368	more than 273	more than 293
COEFFICIENT.					
x 3.53	x 4.32	x 4.37	x 4.93	x 6.70	x 6.26

WOMEN.

Less than 363 mm.	less than 284	less than 283	less than 263	less than 193	less than 203
COEFFICIENT.					
x 3.87	x 4.85	x 4.88	x 5.41	x 7.44	x 7.00
More than 478 mm.	more than 388	more than 376	more than 344	more than 250	more than 264
COEFFICIENT.					
x 3.68	x 4.42	x 4.52	x 4.98	x 7.00	x 6.49

(5) The length of the skeleton from the vertex to the calcaneum plus from four to six centimetres about equals the height of the individual,

¹ Rollet has prepared similar tables, which will be found in VIBERT'S work, 6th ed., pp. 561, 562.

these figures being added to compensate for the loss of the interarticular cartilages, the intervertebral disks, and the coverings of the head and heel.

In many cases where homicide has been committed and the murderer has attempted to destroy the evidence of his guilt, or in destructive accidents, the *corpus delicti* has been proved by the finding of a part or member of the body or a portion of the clothing, as a piece of charred bone, a tooth,—as in the Parkman case,¹—a ring, or a button. On the other hand, instances are on record where deluded individuals made confessions of murder which were proved to have been unfounded by the subsequent appearance in life of the persons said to have been killed. So important is this point that time and time again juries have failed to convict where the moral evidence was well-nigh conclusive. It is only upon irrefutable evidence that the fundamental principle concerning the *corpus delicti* is disregarded.

Where only a part of the body is available for examination, considerable difficulty is apt to arise as to the best method of procedure. The examiner will then need to possess a wide knowledge of comparative and pathologic anatomy and to exercise great ingenuity in order satisfactorily to demonstrate the identity of the parts submitted. Should the only proof of the *corpus delicti* be a skeleton or a portion of one, the expert may be asked to determine the age, race, and sex of the person, and the probable date at which death took place,—whether the bones are old or recent. With limitations, the age would be known by the condition of the epiphyses, whether united or not; by the cranial sutures, whether closed or not; and by the state of dentition. Race would be indicated by the different racial characteristics and peculiarities: thus, the negro by his splay-foot, projecting heel, and prognathous jaw; the Caucasian by his higher forehead, wider facial angle, and larger cranial capacity. Evidence of this character is not by any means conclusive. The determining of sex, after the age of puberty, presents less difficulty. In man the size of the cranium is greater and all the bony points are heavier and more prominent, the angle of the neck of the femur with the shaft is greater, and the lower jaw is heavier; in woman the bones are lighter and more compressed, the patella is smaller, and the articular surface of the femur and tibia is narrower. The characteristic differences are, however, found

¹ *Report of Trial of Prof. Webster*, Boston, 1850, p. 50.

in the broad female pelvis, the diameters of which are all greater with the exception of the vertical; the sacrum and coccyx are more curved, and there is greater spread of the arches of the pubes.

The probable age of the bones would be indicated by their condition and appearance. The presence of the marrow and the periosteum is the most conclusive evidence of a recent state. The soft parts are usually destroyed within two years. Under ordinary conditions the body skeletonizes in about ten years, although this period is subject to wide variations, depending upon the cause of death, the chemical properties of the soil in which the body was found, and whether or not preservatives were used.

WEIGHT AND NUTRITION.—Next weigh the body, if this has not already been done, or at least estimate its weight. Particularly observe the state of somatic nutrition. If emaciation be present, note whether it is due to a deficiency of fat (*panniculus adiposus*), to muscular atrophy, or to a combination of both. This can readily be determined by picking up a fold of skin over a muscle and rolling it between the thumb and fingers. One may study upon his own person the differences existing in various parts of the body, noting especially the varying thickness of the integument in the front, the back, and the sides of the neck. The greatest emaciation occurs in phthisis, atrophic cirrhosis, muscular atrophy, and cancer of the upper digestive tract. The fat may be the corpulency of a high liver, of a gouty person, or of one suffering from cardiac affections. Women have a tendency to become obese as they reach the change of life.

An excessive deposit of fat may be due to *adiposis dolorosa*, in which condition there is a great increase of adipose tissue, not uniformly distributed, but occurring in lumps, the forearms, hands, legs, and feet often being without any or with but slight deposits of fat. In some cases there is also a thickening of the synovial membranes, with a tendency towards the formation of joint fungi and rice bodies,—probably a fatty infiltration. In one case reported by Dercum, in a man four feet eight inches in height, the patient weighed two hundred and six pounds.

SKIN.—Some of the bodies coming to autopsy are so filthy that no true estimate of the condition of the skin can be made until they have been cleansed. In vagabondism and alcoholism a distinct cutaneous discoloration often occurs due to the habits of the subject. Lice upon the body or head may be quickly and effectually disposed of by

saturating a towel with chloroform or kerosene and placing it upon the part affected for a few moments preparatory to its opening. Formalin may be used for this purpose if it can be applied several hours previous to the postmortem, so as to allow time for the evaporation of its fumes, which are so irritating as to forbid its application when the autopsy is to be made immediately afterwards.

The color of the skin is of great importance. It varies much in health and still more in disease and after the appearance of hypostatic congestion. Native Africans vary from yellowish brown to jet black. The children of negroes are usually creamy yellow when born, while it has been stated that the offspring of a mulatto mother and a full-blooded negro father is very dark at birth. The integument of a cadaver rarely possesses the rosy hue of health, but is rather of a grayish white, which shade is most conspicuous in cases of fatal poisoning by chlorate of potassium. The skin on those parts which have been exposed to the sun is generally more or less tanned, while in jaundice the color varies from the faintest tinge of yellow to a dark yellowish brown. Yellow color is also noted in chlorosis (yellowish green) and in pernicious anæmia (lemon-yellow). In the latter brown spots are also frequently found, usually situated on the abdomen, groin, buttocks, and thighs. Pallor is due to a primary anæmia or loss of blood, and is often so marked as to suggest the possibility of internal hemorrhage, as from the rupture of an aneurism or of the sac in extra-uterine pregnancy. The cachexiæ of cancer, argyria, etc., are at times peculiarly conspicuous in the dead body. The patches of bronzed skin, alternating with unaffected areas, seen in Addison's disease, may be scattered over the entire body, but are especially well marked on the abdomen; they are also sometimes found upon the mucous membrane of the mouth. This bronzing may occur when the suprarenal bodies are still apparently normal. Brown lines and a brown areola around the navel are observed during pregnancy; patches on the face may also appear. A white skin is found in albinism, vitiligo (where it occurs in patches), and in leprosy. Moles, tattoo marks, and certain cutaneous diseases, as leucoderma, cause characteristic discolorations of the integument. Redness of the skin is important. It may be simply a discoloration from some red clothing, or an erythematous inflammation, which, as a rule, however, disappears *post mortem*. In cases of asystolic cardiac disease a bluish-red cyanosis is often seen, but general reddening of the body is more likely to be a post-mortem lividity,

though it may be due to congenital or other forms of heart disease.

The breasts should be carefully examined in all cases, and the shape and size of the gland noted. The presence of any fluid in the breast should be detected by making pressure upon the gland, and its character described after being studied under the microscope, especially in cases of abortion. Certain inflammatory conditions are found in the breast, the infection usually entering through a wound, abrasion, or fissure of the nipple. The infection may remain localized to the nipple, causing a simple ulcer or abscess, or produce a general affection. The abscess may be due to infection by the organisms of typhoid fever, tuberculosis, etc., the latter being miliary or diffuse. Several cases have been reported where the nipple became infected accidentally from vaccination. Atrophy of the gland is observed in the old, and hypertrophy is sometimes seen in the young. Supernumerary breasts and nipples occur; a well-formed breast with a nipple has been reported in the axilla and one in the groin. Tumors are very common in the female breast, but rare in the male. They are at times discovered by palpation, at other times are visible to the naked eye, and may, as in cancer, become great ulcerous patches. The most common tumor is cancer, which is most often found in the upper outer quadrant of the gland. Paget's disease is an inflammatory dermatitis of the areola and nipple, and is often a precancerous lesion. The glands of the neck, axilla, and supraclavicular region should be palpated and will often be found enlarged. Adenocarcinoma, adenocystoma (also known as chronic cystic mastitis), adenosarcoma, adenofibroma, adenocystic sarcoma, chondroma, myoma, myxoma, round- or spindle-celled sarcoma, adenoma, lipoma, and fibroma have been found in these glands.

In the general survey of the body, relaxed abdominal walls, with the striæ (*linæ albicantes*) of the multipara or of the patient who has had ascites, are to be described, also the enlargement of the superficial veins so often found in chronic heart, lung, and liver disease (especially in atrophic cirrhosis), tumors, aneurisms, thromboses of portal vein, etc. Atheroma of the temporal arteries may be present, causing them to stand out like rods. Gastroptosis and enteroptosis are often discernible on inspection. Œdema, general or local, is investigated, especially as to its extent and the character of the pitting on pressure.

Now examine the skin for any abnormal marks, such as eruptions, scars, wounds, bruises, blood, dirt, discolorations, etc. The amount

of cutaneous injury does not always afford a true index of the lesions found internally. Thus, it is possible for a wagon or even a street-car to pass over a child without leaving any external trace other than a brush-burn, though upon opening the body the pelvis may be found crushed and the abdomen full of blood. As a rule, all eruptions and inflammations of the integument are pale and have a tendency to disappear at the postmortem. This is especially true of those on the mucous membranes and after the administration of certain drugs, as the purpuric rash from the use of quinine. The erythema produced by potassium iodid and mercury entirely disappears, though mercury may cause papules, vesicles, pustules, or even an exfoliative dermatitis,—lesions which remain and can be studied.

Even an extreme eruption of measles may disappear *post mortem*, and in these cases, if a study of the lesion be desired, it is a wise precaution before death to mark the place to be examined with a dermographic or anilin pencil or by the use of silver nitrate. In other diseases, as chicken-pox, smallpox, etc., the eruption is permanent. Chicken-pox, which may be coincident with smallpox, starts with vesicles that come out in crops. The eruption is very superficial, rarely umbilicated, and has no areola; it may become pustular, and often leaves scars. The lesions are most profuse on the trunk, especially the back, and as they dry up leave a black crust. Smallpox, on the contrary, begins as maculo-papules, which pass into vesicles, and lastly form pustules, all three conditions being often found at the same time in different parts of the body. The papules are deeply seated, indurated, and feel like shot when rolled between the fingers. The vesicles are multilocular and difficult to rupture. Smallpox may be associated with a pre-eruptive general purpuric rash. Malaria may be accompanied by urticaria, angioneurotic œdema, erythema multiforme, bullæ, herpes zoster, eczematoid eruption, and gangrene.

The number and variety of skin eruptions are legion, but eczema, acne, syphilis, alopecia, and psoriasis form 75 per cent. of all cases met with. In skin diseases certain definite lesions are found. Macules occur in syphilis, erythema multiforme, pityriasis rosea, pediculosis, measles, purpura, scurvy, rheumatism, peliosis rheumatica, extreme anæmia, typhus fever, and poisoning from snakes, mercury, antipyrin, etc. Brown macules include freckles, chloasma, moles, and nævus pigmentosus. White and pale yellow macules are seen in vitiligo, leprosy, morphea, and facial hemiatrophy. Vesicles are found in herpes,

especially around the eyes and the lips, in dermatitis venenata (ivy or oak poisoning), impetigo, eczema, miliaria, and scabies. Blebs are seen principally in impetigo, where they are flat and umbilicated; pemphigus, having no areola; dermatitis herpetiformis, and as clusters in syphilis. Pustules occur in eczema, acne, dermatitis herpetiformis, impetigo, varicella, ecthyma, smallpox, syphilis, scabies, and furunculosis. Papules occur in lichen, scrofulosis, prurigo, erythema multiforme; after the use of bromids, iodids, copaiba, cubebes, and tar; in eczema, miliaria, acne, scabies, syphilis, smallpox, measles, lichen ruber and planus. Ulcers are associated with syphilis, epithelioma, lupus, trauma, locomotor ataxia, bed-sores, etc. Large tubercles on the skin are associated with erythema nodosum, erythema multiforme, lupus vulgaris, syphilis, tinea sycosis, and leprosy. Crusting is found with eczema, seborrhœa, psoriasis, ichthyosis (where there is abnormal cornification of the sweat glands and hair follicles), syphilis, pityriasis, ring-worm, and scarlet fever.

Besides these common forms there are other interesting lesions which should be looked for, as chimney-sweepers' dermatitis, Röntgen ray dermatitis and burns, ulcerating lesions of syphilis, actinomycosis and anthrax, scurvy and purpura; circumscribed keratosis, as in cutaneous horns; arsenical poisoning; seborrhœa, especially the senile variety of the French authors, which occurs in pinhead to dime-sized spots, more or less elevated, friable and slightly greasy or dry and hard, with yellow, brown, or black crusts which are firmly adherent to the skin and found especially on the exposed parts of the body.¹ These lesions, as well as nævi, may become epitheliomatous later on. In blastomycosis (oïdiomycosis, Gilchrist's disease) of the skin the lesions are principally found on the hands, arms, face, and lower extremities. Internal lesions may occur therefrom secondarily. Tuberculosis of the skin is rare in this country. It appears in several forms, lupus vulgaris being the most common. The anatomic wart has been considered in Chapter IV.

Dermatomyositis sometimes occurs and may be described with the skin lesions. It consists of a swelling of the muscles, associated with an erythematous and pustular eruption and emaciation. The œdematous swelling may be followed by desquamation.

Certain occupations induce special affections, as the inflammations

¹ HARTZELL, *Jr. of Cutaneous Dis.*, September, 1903.

peculiar to those working in tar and paraffin, the necrosis of the jaw in match-makers, etc. Atrophy of the skin may follow injury to or inflammation of nerve-filaments. It at times accompanies pernicious anæmia. Induration of skin is seen in scleroderma, myxœdema, congenital ichthyosis, and keloid. It accompanies œdema of subcutaneous tissues and scurvy, especially in the legs. Trophic affections of the skin, especially of the extremities, may be found in puerperal fever, gangrenous lymphangitis, diabetes, uræmia, ergotism, locomotor ataxia, etc., and is usually present in cases of angioneurotic œdema.

The yellowish deposits of xanthoma are among the striking and peculiar affections of the skin. They are found especially on the eyes and in the palmar creases. As one variety may occur associated with diabetes, this disease should be always borne in mind. MacFarland considers this condition to arise from some disturbance of the connective tissue which causes multiplication of the cells followed by fatty infiltration.

Skin eruptions are frequently found with Bright's disease. (1) Those of the early stage are pruritus, urticaria, and eczema. (2) Those of the final stage are universal erythema and bullous or desquamative eruptions. (3) Purpura or hemorrhagic eruptions may occur at any time during the disease, and affections due to marked œdema are also present in certain cases.

The tumors found in the skin are the wen or steatoma, lipoma, verruca or wart, nævus pigmentosus and nævus vasculosus, morphea or keloid, molluscum fibrosum (which may cover the entire body), xanthoma, epithelioma (seen usually on the face), angiomas, which may undergo malignant change, adenoma, cancer, and sarcoma. Cutaneous horns should not be overlooked.

An entire chapter might easily be written on the significance and value of scars produced in various ways. Those made by the surgeon are often from their location self-explanatory, as the cicatrix after tracheotomy, trephining of the skull, or the mastoid operation.¹ It would, however, certainly facilitate matters, in this age of numerous hospitals and frequent operations, if the absence of organs removed

¹ The writer once desired to secure for a friend some fresh testicular tissue, and hurried to a recent suicide for the purpose of obtaining the testes. Finding scars on the scrotum, but no testicles, it was learned on investigation that these organs had been removed several years previously, and the young man, being in love, had hung himself because he felt that, being thus mutilated, he ought not to marry.

by operation were indicated by some method which would be generally understood. Thus, the first letter of the Latin name of the part excised followed by the sign minus might be tattooed on the skin near the initial incision: *e.g.*, A— would show that the appendix had been removed, R— that nephrectomy had been performed, etc. The presence of scars may lead the obducent to think of herpes zoster, cupping, smallpox, chicken-pox, various skin diseases, as acne and syphilis, explosions, setons, certain occupations, previous application of croton oil, leeches, etc.

Scars made by the hypodermic needle in persons addicted to the use of morphine are usually found on the arms and thighs,—*i.e.*, in those situations which are hidden by the clothes and yet are easily accessible to the individual. Small, multiple abscesses are often to be found in these cases. Hypodermic injections by physicians shortly before death are usually made over the deltoid muscles or the breast, this region being selected owing to the quickness with which the drug is here absorbed into the general circulation. The puncture may be surrounded by an elevated white or reddish area similar to that produced by the application of cups. Recent saline injections (dermo-clysis) also leave marks upon the skin. Exploratory punctures made by physicians at times end disastrously, as three of the several cases seen by me demonstrated. In one the trocar had penetrated the lung and given rise to abscesses which resulted in death. In another case the exploratory needle used in searching for right-sided pleural fluid penetrated the liver and caused fatal hemorrhage. In the third case, one of suspected pericarditis, the needle had passed through the lung and penetrated the right ventricle. There was no pericarditis present at autopsy, but a markedly hypertrophied heart.

Much discussion has arisen in regard to the means at our command for distinguishing a wound inflicted before and one made after death, and as to which is the fatal injury where there is more than one wound. On these and similar questions I have heard experts testify in court in a manner utterly unsupported by the facts of the case, and in a manner they would not do if talking before their county medical society. Great caution should, therefore, be used in the expression of dogmatic statements concerning such findings. Any blood found on the body should be accounted for and all bruises, injuries, etc., accurately located and described so as to be intelligible to the lay mind. In cases of death by electricity the points of entrance and exit of the

current ought to be carefully sought for, and the shoes should be examined for the burns in the leather which are usually seen near the nails in the heels. In one of my eight cases of death from electricity a man carrying an umbrella with a steel handle, while looking into a shop, made connection with the arc light above the window and died instantly from the current thus transmitted.

Parchment-like spots are often seen on the body where the epidermis has been robbed of its protecting epithelium. Such areas are due to the drying of the part, and if produced during life there will usually be some ecchymotic spots around them. When seen about the mouth, they may have been caused by such agents as strong acids (especially carbolic) and alkalies.

The drawn-up and wrinkled appearance of the skin known as "goose-flesh," or *cutis anserina*,—due to the post-mortem contraction of the involuntary muscles of the skin,—excoriation of fingers, mud, sand, water plants, etc., under the nails and in the hands, mouth, nostrils, and ears are especially conspicuous after drowning.

Note the presence of bed-sores and blisters, remembering that scalds found on dead bodies are sometimes due to carelessness in the use of hot-water bags or bottles during the final illness.

The region of the neck should be carefully inspected for finger markings, scratches, rope markings, etc. The neck should be rotated to ascertain if a fracture or a dislocation exists. Tumors are not infrequent in the neck. Madelung¹ describes a special multiple form of lipoma in this region. In infants a sucking gland is found in each cheek. Cysts may be due to occlusion of the salivary glands.

Enlarged glands can be seen or palpated; they become conspicuous in cases of tuberculosis, leukæmia, cancer, etc. An enlarged thyroid should be measured and examined. A slight enlargement of this gland is often seen in pregnant women and women at term, the hypertrophy disappearing during the puerperium. Percussion may reveal a pleurisy, extensive infiltration of a new growth in the mediastinum, an ileocecal abscess, ascites, enlarged organs, as a spleen or liver, etc. The presence of gall-stones or of an hydatid cyst may at times be elicited by manipulation.

Ascites can sometimes be detected by an elevation of the umbilicus, the finger being used to depress the part. Echinococcus cysts, encap-

¹*Von Langenbeck's Arch.*, 1888, xxxvii.

sulated peritonitic exudates, ovarian cysts, primary carcinoma, and allantoic cysts of the urachus may all be found at the navel.

DEFORMITIES.—The body should now be carefully examined from head to foot and from left to right, and any variations from the normal, either bony or muscular, minutely described. Deformities may be congenital or acquired, single or multiple, symmetrical or asymmetrical. Babès¹ believes that there is a special centre, situated in the anterior base of the skull in the upper part of the face, which presides over the development of the limbs, and that disease of this region produces a tendency to the formation of symmetrical deformities.

Congenital Deformities.—These may be due to embryologic defects or to traumatic or pathologic intra-uterine causes. Injury during delivery is responsible for quite a number of these cases, Allis recently advocating that congenital dislocations of the hip are produced at the time of birth. Those interested in the pathology of congenital dislocation of the hip will find an excellent illustrated article on this subject by Carl Ludloff in *Klinisches Jahrbuch*, 1902, vol. x, no. 1.

According to Hirst and Piersol, the most common monsters are:

I. SINGLE MONSTERS: (1) Autositic Monsters.—*Ectromelus*, aborted or imperfectly formed limbs; *symelus*, a union of two limbs and imperfectly developed pelvis; *celosomia*, body cleft with some eventration, and with anomalies of limbs and genito-urinary apparatus; *exencephalus*, a fœtus with malformed brain, part at least without cranium; *pseudencephalus*, bones of vault absent or very rudimentary and brain rudimentary; mouth a mere opening; *anencephalus*, a fœtus without a cranium or brain; *cyclocephalus*, a union of the eyes, generally with an absence of the nose; *otocephalus*, lower jaw wanting; ears approach each other. (2) Omphalositic Monsters.—*Paracephalus*, imperfect extremities; imperfect head and face; lungs absent or rudimentary; heart often absent; one member of a unioval twin, sex feminine; *acephalus*, complete absence of head and upper extremities, rudimentary or absent heart, lungs, etc.; *asomata*, trunkless head, which is not well formed; no cord; *anideus*, shapeless mass covered with skin.

II. DOUBLE MONSTERS: Double Autositic Monsters.—(1) Terata Katadidyma: *Metapagus*, two fœtuses united by their cephalic extremities; *pygopagus*, two fœtuses united in the region of the buttock;

¹ *Berliner klin. Wchnschr.*, 1904, vol. xli, no. 18.

ischiopagus, two fœtuses united by the pelves, coccyges, and sacra, with a common umbilicus; *dicephalus*, with two distinct heads, usually separate necks; *diprosopus*, having a double face, body single. (2) Terata Anadidyma: *Dipygus*, double pelvis, lower extremities, and genitalia; *syncephalus*, division up to navel and imperfectly formed up to head; *craniopagus*, bodies joined at homologous parts of the cranium. Laloo was an illustration of a *Dipygus parasiticus*. (3) Terata Anakatadidyma: *Prosopothoracopagus*, twins united by the thorax, abdomen, and face; *omphalopagus*, united at the umbilicus; *rhackipagus*, united at the vertebral column. The Siamese Twins were examples of monsters of the *xiphopagus* variety, where the individuals are united from the umbilicus to the xiphoid cartilage.

III. TRIPLE MONSTERS. In composite monsters there is a complete or partial union of two or more fœtuses.

IV. DOUBLE PARASITES: *Heterotyphus*, a parasitic fœtus hanging from the anterior abdominal wall of the principal; *heteralius*, a parasite inserted at a distance from the umbilicus of its host and having no direct connection with the latter's cord; *polygnathus*, ill-developed fetal parts joined to jaw of autosite; *polymelus*, duplication of lower extremities; *endocyma*, the greater part of the parasite within the body of the autosite.

Spina bifida is a defect in the union of the laminae of one or more vertebrae, with more or less malformation of the spinal cord or its membranes. While *spina bifida* usually shows itself posteriorly, it may do so entirely alone or in combination with an anterior opening, and, at times, with increase of size due to the presence of a lipomatous mass. *Encephalocele* is a hernia of the brain, and *meningocele* a hernial protrusion of the meninges.

Various other defects and lesions may be found: as, *e.g.*, complete or partial absence of the *nose*; imperforate *ala nasi*; deviation of the septum; various abnormal shapes, as saddle-back in hereditary syphilis. *Palate*, cleft. *Cheeks*, fissures and fistulae. *Ears*, absence of the helix; hæmatoma. *Mouth*, imperforate, abnormally large (*macrostoma*), abnormally small (*microstoma*). *Atresia oris*, besides being congenital, may be due to cicatrization from burns. *Tongue*, absent; cleft; atrophied (*microglossia*); hypertrophied (*macroglossia*); or it may be adherent to the palate. The *frænum* may be too short or too long. The hairy tongue is due to cornification of its mucous membrane. *Alveolar process*, absent; cleft; atrophied; hypertrophied.

Lips, cleft (harelip); cysts. *Neck*, tracheal fistula; cysts on visceral clefts. *Fingers and toes*, absent; atrophied; hypertrophied; supernumerary; webbed; or clubbed. *Sternum*, absent, malformed, or fissured. *Ribs*, cervical ribs and various defects in their development. *Umbilicus*, skin insertion of the cord; abnormalities of the vessels; hernia. *Urachus*, persists and remains patent. *Bladder*, extroversion. *Penis*, the glans may be atrophied, hypertrophied, or phimosis or atresia may be present; often imperfectly formed in cretins. The entire penis may be absent, but this condition may be due to amputation, traumatic or pathologic, in which case the scar will be present. Scars on glans or prepuce are usually syphilitic. An elongated or fissured penis is often associated with calculi. Epispadias or hypospadias may exist. The penis may be found erected after death by hanging, injury to spinal cord, or drowning. It may be affected with gangrene or cancer, and the arteries may show arteriosclerosis, the latter condition being rare. *Testicles*, one or both may be absent from the scrotum or from the body altogether; they may not have descended, or may be found in some abnormal position not in their line of descension. There may also be found atrophy; hypoplasia, a condition often present in imbeciles; hypertrophy, congenital or acquired, or compensatory in one testis, as after the removal or destruction of its fellow; duplication or malformation. Abdominal, crural, cruroscrotal, or ilio-abdominal ectopia may occur. These organs are usually retracted in cases of drowning. *Scrotum*, absent, atrophied, or hypertrophied; gangrenous lymphangitis is seen sometimes in children. The hypertrophied condition may be acquired, as in elephantiasis. *Filarie* are possibly introduced by the bite of a mosquito, the *Culex pipiens*. Other conditions may be cleft scrotum, hydrocele, hæmatocele, varicocele, and hernia. It may be contracted in cases of drowning. *Vulva*, absent; imperforate; atrophied; hypertrophied. The Bartholinian glands may become enlarged, forming retention cysts; abscesses; tumors, as fibroma, chondroma, lipoma, sarcoma, carcinoma, and myoma. Aphthæ occur as white spots on the mucous membrane; elephantiasis; herpes progenitalis; diphtheritic ulcers; acne; eczema, especially on the skin of the labia, the vulva, or the nymphæ, sometimes giving rise to atresia or stenosis; lupus; syphilis, as the chancre, mucous patch, or gumma; gonorrhœa, as a purulent vulvitis; chancroid; and venereal warts are found. Injuries are common after parturition and rape. Hæmatoma, rupture of varicose

veins, lacerations, œdema, etc., are seen. *Clitoris*, absent; atrophied; hypertrophied, in which case it may simulate hermaphroditism; carcinoma. *Anus*, absent or imperforate, or may end in a blind sac. Fissures, indurated and irregular. Small polypoid growths may fringe the borders. All lesions around the anus are at times altered by the distortion of the part with the cotton introduced by those who have had the body in charge. *Rectum*, prolapsed. This condition is common in children. The rectum may be imperforate or contain congenital polypi, internal or external hemorrhoids, carcinoma, sarcoma, and various other tumors. *Fistulæ*, internal or external, complete or incomplete, may follow abscesses. *Hymen*, absent; imperforate; fimbriated. Its absence may be due to traumatic causes or rupture during menstruation. An *ovary* may lie in the canal of Nuck. *Urethra*, absent or occluded; atresia or partial plimosis. It may have abnormal openings, as on the penis, scrotum, perineum, clitoris, or rectum, in the last case forming a urethrorectal fistula. It may be cleft, presenting a condition of epispadias or hypospadias. It may be inflamed (urethritis), with or without *Gonococci*, and showing a bloody, mucopurulent, purulent, or altered spermatic discharge. Chronic urethritis occurs with thickening of the tube. It may be torn by the passage of a stone or foreign body. Stricture may occur, in the male, as a rule, four to six inches from the meatus. Tuberculosis is extremely rare. Tumors, as fibroma, angioma, sarcoma, epithelioma, are seen. Condyloma or caruncle may be found.

Congenital hypertrophies may be confined to the big toe, and are, as a rule, associated with disturbances of the genitalia or a persisting thymus gland. In rare instances the enlargement is general, as in gigantism, a condition not uncommonly acquired, when it is apt to be irregular and partial, affecting usually the bones of the face and skull (leontiasis ossea). Although appearing soon after birth, it more often arises at puberty and is due to an abnormal proliferation of the cartilages in the process of endochondral ossification. Acromegaly, a condition due to some lesion of the pituitary body, is often a cause of giant growth, the enlargement affecting the face bones and the distal ends of the long bones. Local hypertrophies due to inflammation and rhachitis are not at all uncommon. Rokitsansky describes deposits of phosphates and salts of lime in the cranial and pelvic bones of pregnant women; these are the analogues of the "plaques choriales" of sheep, which probably contribute to the development of the fetal skeleton.

The opposite condition, atrophy, is much more common. The general congenital form is the microsomic dwarf (normal proportion), a rare condition, the stunting more often affecting only one part, and being due to ischæmia or inflammation *in utero*. It may affect a limb (agenesis), skull (microcephalus), pelvis, etc. Acquired microsomia (cretinism, etc.) is the result of absence or disease of the thyroid gland, which produces an arrest of development in the longitudinal growth of the cartilaginous bones and in the lateral growth of the membranous bones. Rhachitis and synostoses are other causes of stunted development. Partial atrophy, if congenital, is often confined to the head, tibia, fibula, or radius, and is, as a rule, associated with other deformity. There may be an entire absence of bones or parts, as in apodia, or the lack of a clavicle, scapula, or radius.

Signs of Degeneration.—Closely connected with malformations are the signs of degeneration, as misshaped ears and nose, asymmetrical face, deformed fingers, and some anomalies of the penis, vulva, and anus, which should be noted for their statistical value.

Fractures.—Deformities due to fractures are very common. Their character depends upon the location, the bones broken, and the age of the fracture. A recent fracture will exhibit crepitus, swelling, increased mobility, and deformity due to contracture of the muscles; this contracture, however, may disappear *post mortem*. If the fracture is old there may be non-union, false union, union with deformity, false joint, or a non-absorbed callus. Deformity due to fracture of the shaft of a bone can be more easily found by making comparisons between the same bones on both sides of the body, as the femora, humeri, and tibiæ. Likewise comparisons should be made between similar joints, especially the shoulder, elbow, hip, knee, and finger joints, to determine whether the deformity be a fracture or a dislocation. Fractures and dislocations of the neck are frequently overlooked, owing to lack of careful examination of these parts.

Dislocations.—Dislocations are also common sources of deformity. They may be: (1) Congenital, as illustrated in club-foot. (2) Traumatic, resulting from direct or indirect violence or muscular action. These two forms are the ones commonly met with. (3) Pathologic dislocations, due to degenerative changes in the joint, as occurs in tabes and Charcot's joint. Recent dislocations rarely show inflammatory changes, whereas older ones present evidences that such changes have occurred. Contractures are caused by nervous diseases, cicatrices

with loss of skin and subjacent tissue, burns, and other accidents. These contractures are occasionally due to spontaneous dislocations. In old traumatic cases ankylosis is sometimes present. Ankylosis also occurs in pathologic conditions.

It may be important to examine the hyoid bone and laryngeal cartilages for fracture, dislocation, or laceration. In a case recently tried in the New York courts a patient was supposed to have received harsh treatment from an attendant in one of the hospitals there. The case hinged on determining whether a fracture of the hyoid bone had or had not been produced during life.

Pathologic Deformities.—Such distortions are due to diseases which may produce certain changes in the bone structure. The most common of these disorders are rickets, tuberculosis, syphilis, osteomalacia, acromegaly, and osteitis deformans. Rhachitis is a general cause of many varieties of deformity. In this disease the bones lose their tenacity and hardness, change in consistency (usually being thickened and spongy), and become distorted by the action of the muscles. These processes produce certain deformities: (1) Of the extremities, bow-leg (*genu varum* or *extrorsum*), knock-knee (*genu valgum*). (2) Of the sternum and ribs, pigeon-breast (*pectus carinatum*), funnel-breast, Harrison's groove, beaded ribs. (3) Of the cranium, the square-box rhachitic skull, in the bones of which may be found spots of craniotabes. (4) The subject may be more or less dwarfed. These are the most common malformations.

Tuberculosis is often associated with a long, narrow chest, and is a source of common deformities, seen in coxalgia, Pott's disease, knee-joint disease (*hydrops articuli*), and the various grades of spinal curvature. Syphilis in its secondary and tertiary periods may produce nodes or cause great destruction of bone-tissue. This process is present whether the malady be of the inherited or acquired variety. Osteomalacia causes bone softening, which may be followed by various deformities, especially fracture. This disease usually occurs in women after pregnancy. Osteitis deformans also produces changes in bones, usually those of the extremities. Certain chronic lung conditions result in contraction of one side of the chest and often a corresponding scoliosis; emphysema of the lungs is accompanied by a barrel-shaped chest; nervous diseases lead to more or less disfigurement of the body, as facial paralysis and spastic paraplegia; pernicious anæmia may either cause or be associated with spinal deformities; pleurisy

may give rise to unilateral enlargement of the chest; aneurism may cause protrusion of the sternum. (For a further discussion of the changes found in bones and joints, see Chapter XVII.)

Tumors and other abnormal growths are also a common source of marked deformity. While deformities of the bones are the most frequent and conspicuous, yet there are other acquired deformities which are quite important. Congenital fissures of the neck which are tubular and go to the thyroid cartilage, and the tuberculous perianal fissures, should be followed out by careful dissection to their point of origin.

Muscular Deformities.—These are most generally due to muscular weakness. They may coexist with bone deformities and even cause or be caused by them; as deviation of the spine due to bone deformity destroys the harmony between the dimensions of the bones and the muscles, some muscles becoming elongated and others shortened.

Acquired Deformities.—Nature itself may produce deformities, as those arising from age, habits, and occupations. Notwithstanding that persons assume particular positions most constantly in certain occupations, they do not often acquire deformities.

Tophi.—These deposits occur in gouty persons, and are generally found in and about joint-cavities, ligaments, tendon-sheaths, arytenoids, epiglottis, vocal cords, skin of the penis, helix of the ear, tarsal cartilages, and margins of the eyelids. They contain a urate and a biurate, both of which dissolve in either acetic or nitric acid and give the murexid test for uric acid. If large and advanced they leave a white chalk-line when rubbed. Superficial tophi are movable and the skin over them is non-adherent, but as the process advances the mass adheres and may finally protrude. They are easily differentiated from sebaceous cysts.

HERNIA.—Hernia being of common occurrence and a frequent cause of death, the various situations where this defect may occur must be thoroughly inspected. The abdomen, inguinal canals, femoral openings, and umbilical region should be carefully palpated. The scrotum should be examined to determine the absence of one or both testicles, and when these are not found search for them should be made in the canal and elsewhere.

EYES.¹—Inquire whether the eyes and mouth were open or closed when death occurred, and whether the expression was peaceful or the

¹ Much interesting material on this subject will be found in PARSONS'S *Pathology of the Eye*, vol. i, 1904; vol. ii, 1905.

countenance distorted. While in life expression is manifested principally by the eyes and the action of the facial muscles, in death the eyes lose their lustre and fail largely to influence the expression.

Abnormalities.—The eyes should be carefully examined in every postmortem, as abnormalities are quite common. The eyelids may be wholly or completely absent. They may not be divided, or a fissure may exist involving one or both lids. There may be eversion or inversion. Ptosis, either acquired or congenital, may be present; if acquired, it may be due to specific causes. One or both eyes may have been replaced by artificial ones. The eye sometimes appears intact where sight had been absent for years before death, in which case there is always evidence that blindness existed. Abnormal prominence is usually caused by cavernous aneurism or exophthalmic goitre; the former may be associated with arteriosclerosis, the latter with enlargement of the thyroid gland. The presence of puffiness about the eyelids should be noted, as it occurs in Bright's disease, cardiac affections, arsenic poisoning, and traumatism. Do not make the error, as was done in the Harris case, of describing signs or symptoms as existing in the ocular apparatus when there is a glass eye!

Position.—Instead of presenting parallel visual axes, one or both eyes may be deviated inward, outward, downward, or upward, constituting one of the various types of strabismus, a condition which may aid in the diagnosis of toxic, cerebral, or nervous disorders. Conjugate deviation of the eyes occurs in apoplexy.

Color.—The color of the eyes is due to a blending of factors, varying in value in every case, depending largely upon the quantity of pigment present. The several races have, as a rule, characteristic colored eyes: the negroes and the Mongolians, black; the Australians and southern European races, dark; the Slavs, the Teutons, and the Scandinavians, blue. These peculiarities are worthy of note, as they may be of importance for purposes of identification. Color-blindness should be investigated by most careful microscopic study. By Daltonism is understood dyschromatopsia (congenital partial color-blindness) and achromatopsia (congenital total color-blindness).

Conjunctiva.—Whitish patches, which may be congenital or acquired, are occasionally seen on the conjunctiva. If congenital they may be associated with moles on the face. The conjunctiva may be the seat of inflammatory conditions, which may be local or associated with some systemic disease. Note the variety of conjunctivitis present,

and if any of the severe forms should be suspected an effort should be made to ascertain whether or not it is specific. Ecchymosis of the mucous membrane may occur in cases of injury to various parts of the eye, traumatic conditions affecting the skull, dura, or brain, and even systemic disease itself. The conjunctiva is one of the seats of jaundice, and it is the place where jaundice shows itself most plainly in the negro. Trachoma may have existed.

Pupils.—Accommodation, convergence, and exposure to light, which during life produce alterations in the size of the pupils, after death do not affect it. In life, age, the color of the iris, and the character of the refraction also influence it. Under ordinary circumstances the pupils should be equal, but variations may occur, depending upon the conditions and cause of death, a few of which will be here mentioned. In fatalities due to chloroform the pupils may remain enlarged; in opium poisoning they often expand shortly before or after death; and in cerebral hemorrhage they are generally irregular, depending upon the location of the clot. The pupil can be measured approximately by holding in front of it a rule marked in millimetres and noting the number of spaces its width occupies. This method is somewhat faulty and only approximately measures the width of the eye, but an accurate measurement can be made with the pupillometer.

Cornea.—Note should be taken of the condition, curvature, and transparency of the cornea. Keratitis, ulcerations, and abscesses are common diseases of this locality. In old persons the arcus senilis is usually present. Besides its liability to disease, the cornea may be lacerated, torn, or injured, with or without the lodgment of foreign bodies.

Sclera.—Examine its surface as to continuity and describe any lacerations or injury which it may have received.

Iris.—The iris should be inspected for color, condition, and quantity of pigment. As this is a common seat of disease and operations, it should be especially examined for the presence of a coloboma, one of its most common malformations, which may be either congenital or acquired. The congenital form is due to the failure of the ocular fissure to unite; it may be distinguished by the presence of the sphincter, which in the acquired form has been excised along the margin of the coloboma, as after an iridectomy. The fissure is usually situated in the lower part of the iris, and is often associated with coloboma of the choroid. The iris should also be examined for the scars of opera-

tions, for the information thus obtained is of value. Albinism is due to a lack of pigment in the choroid.

Crystalline Lens.—Luxation or subluxation of the lens should be looked for. If present it may be either congenital or acquired. Coloboma of the lens is accompanied by a similar condition of the choroid or iris.

Optic Nerve.—This portion of the eye, together with the retina, can best be examined with the ophthalmoscope.

Growths.—The most common growths of the eye, and the parts generally affected are: Iris: angioma; metastatic sarcoma, usually from the ciliary body; granuloma; and cysts. Choroid: sarcoma, most common of all tumors; metastatic carcinoma, occasionally found; nævus, rare; cysts, rare. Ciliary body: sarcoma, common; adenoma, occasional; carcinoma, occasional; nævus; cysts. Retina: glioma and cysts.

Meningocele and herniæ of the brain containing cerebrospinal fluid may be found protruding from the sinuses into the orbit. Dermoids of the orbit are frequently discovered, especially near the eyebrows; those of the eye occur at the corneoscleral junction. The so-called carcinoma originating from the lachrymal gland is usually an adenocarcinoma. Lipoma of the eye, which may be either congenital or acquired, occurs in the fatty tissue. Tumors originating from the bone are generally sarcomas or exostoses.

Orbital Injuries.—As injuries are frequently received in and about the orbit, careful examination of this region should be made. Fractures through the orbit may cause, besides serious damage to the eye itself, grave cerebral complications.

Orbital Diseases.—Diseases of the orbit are quite common and may be important, for they often cause meningitis. Caries, necrosis, and cellulitis are generally preceded by periostitis.

After thorough examination of the eyes the lids should be carefully closed.

HAIR.—Examination of the hair may prove, especially in medico-legal practice, to be of importance. Not only the hair on the cadaver but also any hair found in the immediate vicinity of the body should be examined. Hair not belonging to the corpse demands inquiry as to whose it was and whence it came. In this way observations of value have been made and aided greatly in unravelling some of the world's deepest mysteries. The hair varies in color, length, quality,

and quantity in different individuals, and also according to situation on the same person. The head of the new-born infant is covered with fine, downy hair, a growth of the last two or three months of intra-uterine life. Shortly after birth it is shed and replaced by the true hair. The hair is one of the last tissues to yield to decay. The question of the growth of hair after death is a disputed one. Such apparent growth is most frequently caused by the retraction of the fat. In the new-born there is no medullary canal in the hair. (Vibert.) Human hair can be positively identified as such.

Color.—The color of the hair should be noted and described; also observe whether or not the color is uniform. As it depends principally upon pigment, the color will vary in proportion to the quantity and variety of that pigment. Gray hair in adults is attributed to a diminution in pigment, and may be due to age, care, worriment, sudden fright, as after the San Francisco earthquake, burns, local inflammations, systemic diseases, nervous disturbances, hardships, or exposure to cold, as seen in Arctic explorers. Gray hair in the infant is congenital. Abnormal whiteness of the hair is a condition found in albinos. It may be complete or partial and is associated with loss of pigment in other organs. The examiner should not be misled by dyes.

Length.—The length of the hair should be observed and approximately measured. Long or short hair is characteristic of sex and of certain races. The longest hair is seen in the Indian, Chinese, and Malay; short hair in the Negro.

Quality.—Various races have hair of characteristic texture. The Negro and the Bushman have crisp, woolly hair; among the Anglo-Saxon, Germanic, and kindred races the hair is smooth; Australians have soft, smooth, wavy hair; the American Indian has coarse hair.

Quantity and Distribution.—Hairs normally may be present on all exterior parts of the human body, except the palms of the hands, soles of the feet, glans penis, mucous membranes, and the ball of the eye. Some races are prone to excessive hair growth, as the "hairy men" of the island of Yesso. Loss of hair, complete or partial, may be due to depilatories, pregnancy, disease, friction of clothing, or pressure. Baldness or moth-eaten appearance of the head, eyebrows, and mustache is seen in lues and myxœdema. Epileptic, idiotic, and insane persons generally have large growths of hair. Abnormalities of distribution have been recorded, and the examiner may often find either

absence or overgrowth in certain localities. Under these conditions hair may be found in the interior of organs and neoplasms, especially ovarian dermoid cysts.

Diseases.—The hair of the body is subject to various diseases, and therefore its condition should be carefully noted. Various forms of alopecia, tinea, and fungi may attack the hair. These conditions may be due to local or constitutional disorders.

Injuries and Tumors.—Located under the hair tumors and various injuries may be present. Therefore pass the fingers through the hair of the scalp, and if it be at all thick part it, which aids in the discovery of wounds, hæmatomata, and tumors which may be concealed. Should any be discovered, cut or shave the hair so as to examine them more carefully. If the head has been injured, it will usually be found that the hair has already been removed by the surgeon. The hair may be lost in X-ray workers.

NAILS.—When examining the nails attention should be paid to the material found under them, as it quite frequently is of medico-legal importance. The growth of the nails is regarded as one of the diagnostic signs of fetal maturity. They may be affected with favus (onychomycosis favosa).

Anomalies.—The nails may be absent, atrophied, hypertrophied, brittle, discolored, cracked, etc. Congenital absence of one or more nails is usually associated with other malformations. Acquired anonychia may be due to trauma, nervous diseases, pyogenic infections, scar-leaving affections, as syphilis, and blood-stasis, as in cyanotic conditions. Another anomaly often met with is imperfect nail formation, resulting from dystrophia, in which the nail is usually opaque, discolored, brittle, and fissured. Certain diseases are sometimes noticed about the nails, as abscess, eczema, psoriasis, paronychia, syphilis, and professional dermatitis with paronychia. Traumatism confined to the nail or surrounding tissues is frequently met with and its nature and extent should be noted.

TEETH.—The teeth should be examined as to anomalies, condition, and disease.

Anomalies.—One or more teeth may be permanently absent, or supernumerary teeth may be present to such an extent that there are two dental arches in either one or both jaws. The teeth may be irregularly placed, often beyond the alveolar process. In examining the teeth notice should be taken of the condition of the palatal arch.

Condition.—Much can be learned from the condition of the teeth, as to care, neglect, habits, and disease. The teeth should be examined to see whether they are artificial. It is a noticeable fact that people from certain countries have particularly fine teeth regardless of the care taken of them. Caries of the teeth and the extent to which it involves the bone should be noted and, if possible, the cause determined. Among other conditions phosphorus poisoning produces necrosis of the teeth and maxilla. Hutchinson's teeth are frequently seen and the condition is one of considerable importance. It consists in a single deep notch of the permanent upper central incisors, but the deformity is sometimes present in the molars when it is absent in the incisors. Dental tumors, such as epulis, sarcoma, osteoma, odontoma, or dentigerous cysts, are occasionally found.

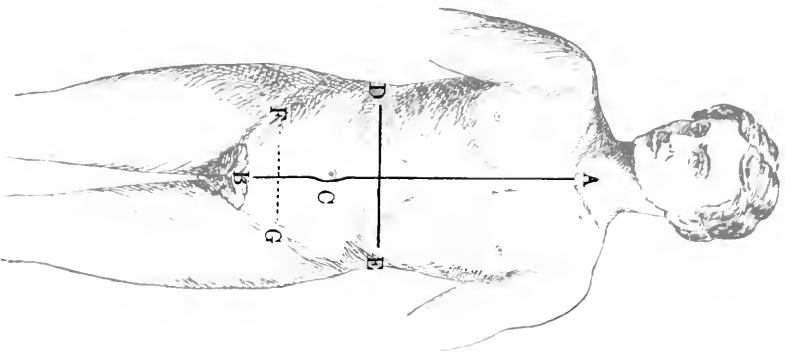


FIG. 55.—Scheme to show the lines for incising the trunk and exposing more fully the abdominal cavity. The primary incision, *A B*, from the interclavicular notch to the symphysis pubis, goes to the left of the umbilicus at *C*, or it may pass in a straight line to the left of the navel. The transverse incision, *D E*, and the cutting of the rectus muscles at *F* and *G*, are for the purpose of enlarging the abdominal opening.

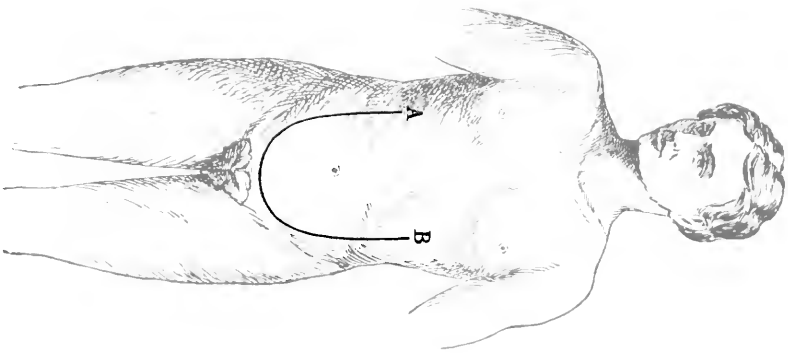


FIG. 56.—Elliptical incision for examination of the abdominal cavity; sometimes useful after abdominal operations and in infants who died from inflammatory conditions of the umbilical vessels.

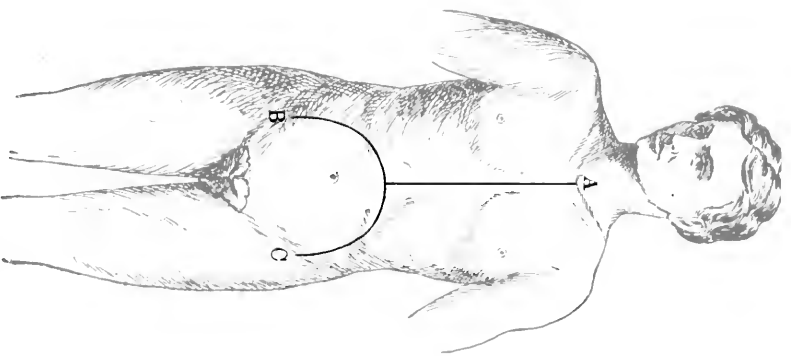


FIG. 57.—Incision sometimes useful after death following operation in the abdominal region.





FIG. 58.—Method of making the initial incision over the sternum, as seen from above.

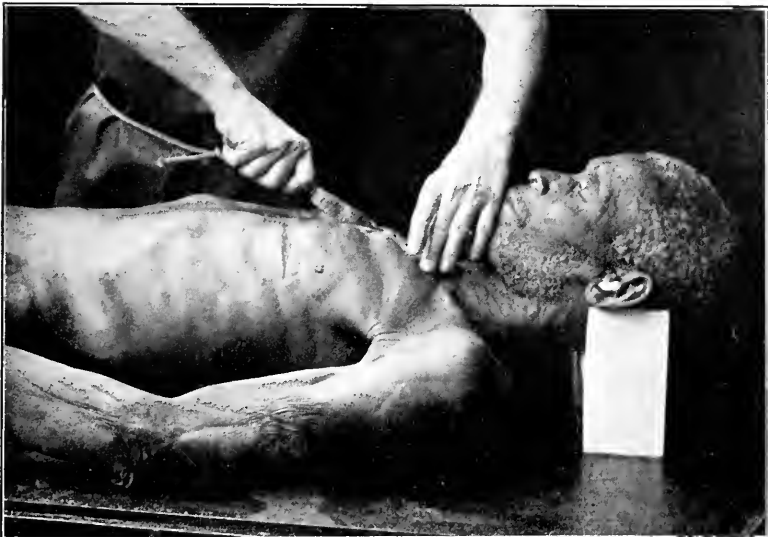

FIG. 59.—The same incision as in Fig. 58 somewhat extended, as seen from the side.

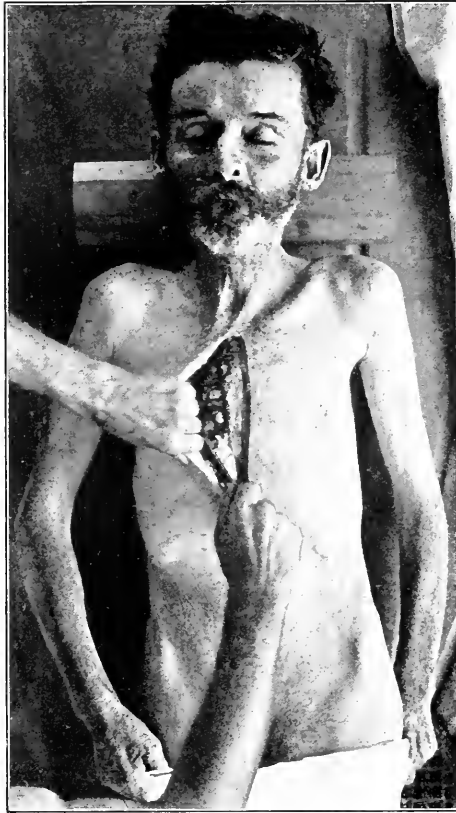

FIG. 60.—Method of raising flap on right side so as to expose sternum and ribs, as seen from above.

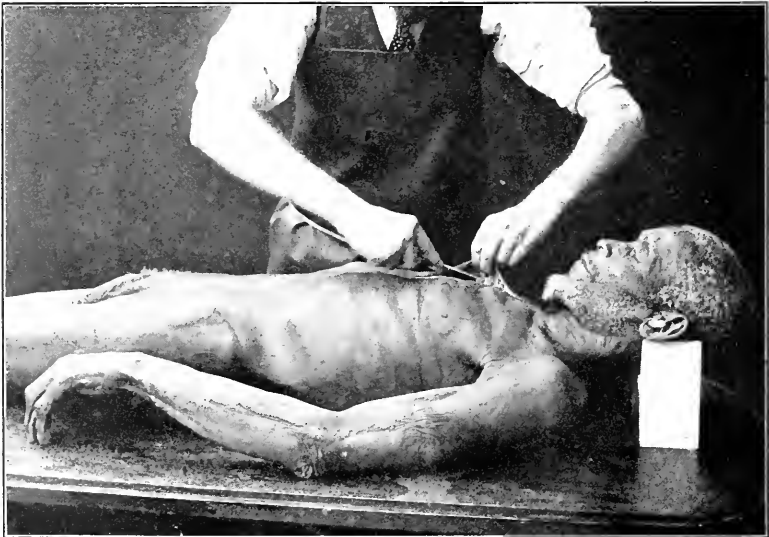


FIG. 61.—Same incision as in Fig. 60, seen from the side.

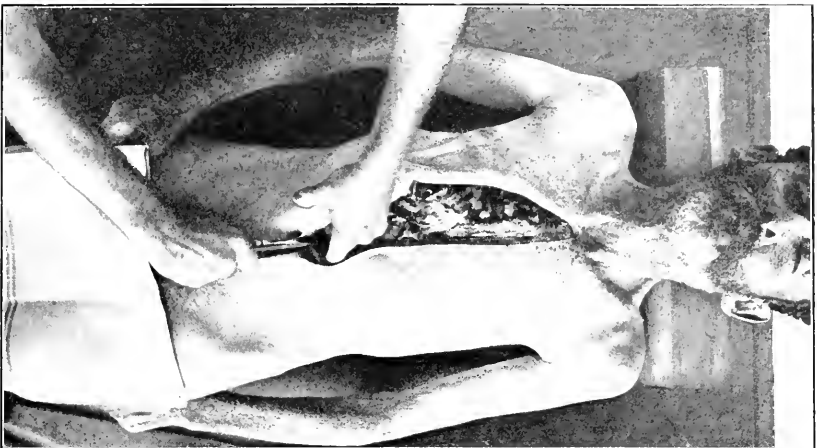


FIG. 62.—Method of opening the abdominal cavity. The index and middle fingers being stretched apart, the abdominal wall is lifted off the viscera so that the cutting may safely be done from above downward.

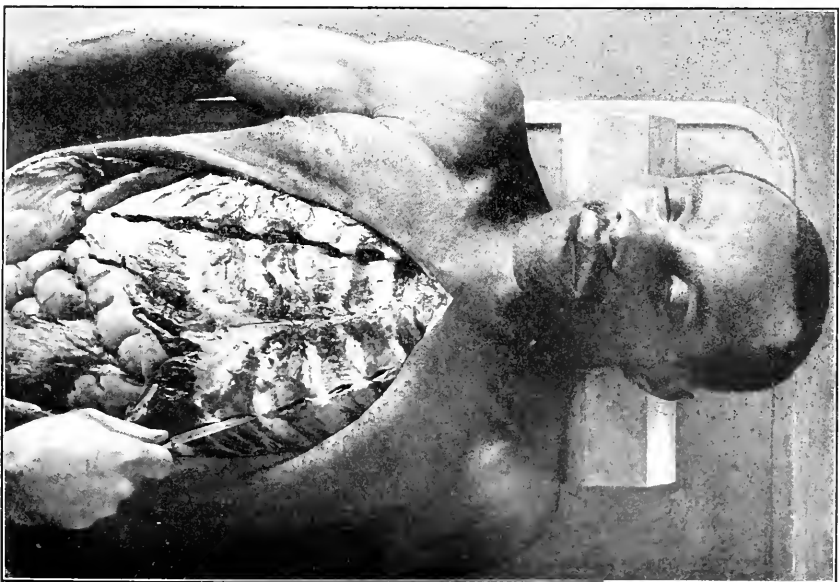

FIG. 63.—On the right side the cartilages have been cut through near their junction with the osseous portions of the ribs. On the left side the fifth rib is about to be cut through, the knife being introduced below it and the cutting done upward, using the sixth rib as a fulcrum.

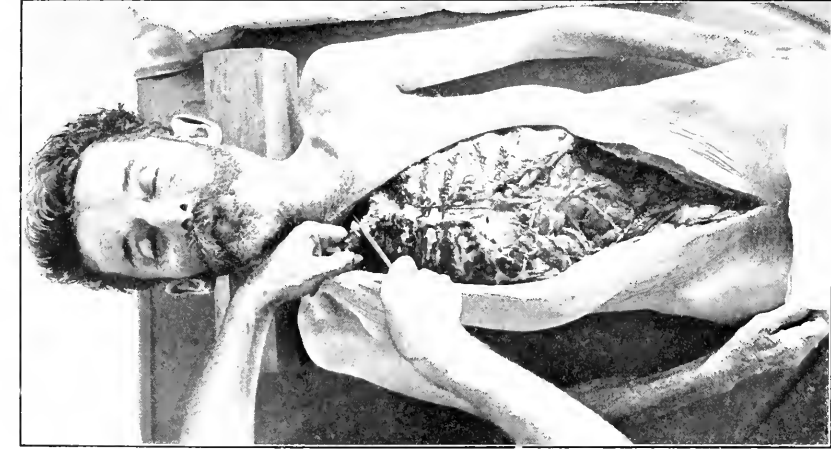


FIG. 64.—Method of separating the sternoclavicular attachment. The articulation is discovered by steadying the sternum with the right hand and moving the clavicle in various directions with the left hand. Unless marked ankylosis exists, incision with the knife is easy after the discovery of the articulation.

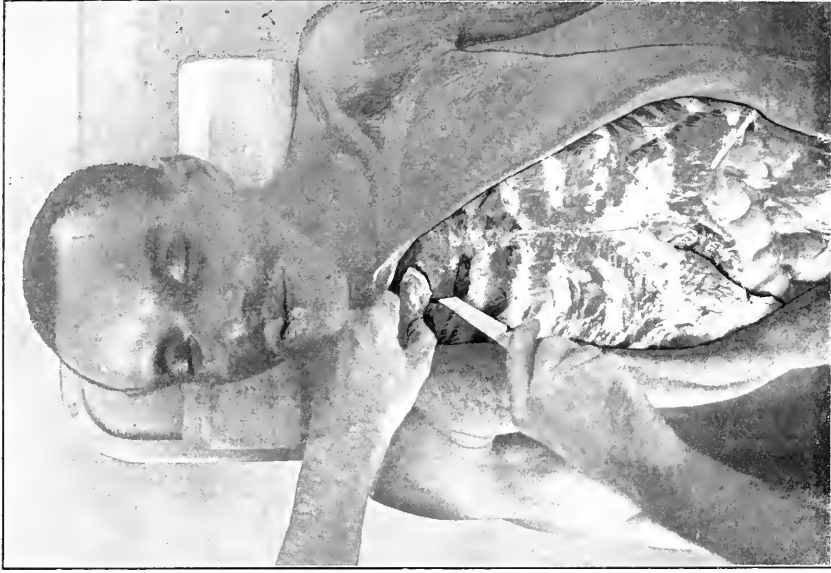

FIG. 65.—The incision through the first rib is here shown. The previous incision seen in Fig. 64 has been carried almost to where the thumb is located, the clavicle elevated, and the incision made through the first rib.

CHAPTER VI

TECHNIC OF OPENING THE ABDOMINAL CAVITY AND THE TOPOGRAPHIC EXAMINATION OF ITS WALLS AND THE PARTS CONTAINED THEREIN

HAVING completed the external examination of the body, all necessary instruments are placed in order and within reach upon a board or tray,¹ and the operative part of the autopsy is begun.

The operator should stand so that when facing the body the incisions from above downward can be made with the greatest ease. This condition is best fulfilled by right-handed operators standing on the right side of the supine object, and left-handed operators on the left side. The body should be drawn well to the side of the table nearest the operator, the head resting on the top of the table and, if preferred, the shoulders supported by a block.

With the knife held in as nearly a horizontal manner as possible (see page 43), clean, quick incisions (Fig. 55) should be made by a sweeping motion of the arm from the interclavicular notch (*A*) to the symphysis pubis (*B*), passing to the left of the umbilicus (*C*) in order to avoid any vessels going to or from the navel, the suspensory ligament, and a possible hernia or omphalomesenteric duct. Care should be taken at this time not to penetrate the abdominal cavity and thus injure the contained viscera, or to extend the incision to the external genitalia so as to disfigure them (Figs. 58 and 59). On the chest this primary incision goes down to the sternum, whereas on the abdomen it penetrates only to the peritoneum. In Europe the initial incision is usually started at the middle of the chin (symphysis menti) and continues down to the symphysis pubis; for there, as a rule, only the poor who die in hospitals reach the post-mortem table, autopsies being seldom performed on the bodies of persons belonging to the

¹ A towel may be laid over the external genital organs and the upper part of the thighs, upon which the instruments to be employed in the performance of the autopsy are placed in the order of their use, with their handles towards the obducent. An ordinary stool is frequently used abroad for this purpose. All instruments after use should be washed and returned to their proper places, so that no time may be lost in putting one's hand upon the one desired. This procedure also prevents possible mechanical injury to the operator, and loss of an instrument by being sewed up in the body.

upper classes. In this country the longer incision should be used only when great haste is necessary, as in cases of contagious diseases, such as diphtheria, or when the body is not to be seen again by relatives or friends. If the mentopubic incision be employed, it should not injure the thyroid gland, or other important structures of this region. A special Y-shaped incision is sometimes made here in order to avoid this, the incisions starting at the external ramus of the jaw and joining in the middle line about one inch above the interclavicular notch. The knife now follows underneath the skin, fat, and fascia over the lower border of the inferior maxillary bone, until the digastric muscle and the submaxillary glands are seen. The gland is then incised, the muscles being left *in situ*. The common carotid artery, internal jugular vein, and pneumogastric nerve are now readily exposed. Care should be taken to avoid wounding the vein, as the resulting hemorrhage hinders subsequent manipulations; such injury is especially to be guarded against on the left side in those cases where search is to be made for the entrance of the thoracic duct into the subclavian vein.

The initial incision over the thorax is now carried down to the sternum in any place where this has not already been done, and the layers of skin, fascia, and muscles of the right side are quickly dissected away close to the ribs, freely exposing the costochondral articulation and some three inches of the sternal end of the clavicle. To do this the attachments of the soft tissues are made tense by drawing them away from the median line with the left hand (Figs. 60 and 61), while long sweeping incisions are being made downward and laterally with the large section-knife. The left side may next be similarly treated, though in practice this is more frequently done after the central abdominal incision has been completed. Some necroscopists permit an assistant to prepare the left side while the operator is uncovering the right, but the time saved by this procedure is small and the danger of injury to those taking part is great.

Should a pneumothorax have been diagnosed during life, the thoracic pocket made by elevating the skin-flap on the side of the pneumothorax is filled with water, and a puncture is made at the bottom through the costal pleura at the intercostal space between the sixth and seventh ribs at the axillary line. If a pneumothorax be present, bubbles of air will escape through the water, the visible supply of which will rapidly diminish. If the head be lowered and enough

water be used, this will finally escape from the mouth. It should be remembered, however, that a cavity in the lung opened accidentally by the knife would give the same result as that arising from a pneumothorax. Stanton finds the normal lowering of the column of mercury in the thoracic cavity to be three millimetres. In a case of a *right-sided pulsating pyopneumothorax* at Blockley in 1905 we found it was from twelve to fifteen millimetres.

A note is now made as to the situation and character of any blood which may escape. The condition of the fat (*panniculus adiposus*) is considered, and its thickness noted at the nipple-line, beneath the xiphoid, and again three inches below the umbilicus. In atrophy the color of the fat becomes darker, changing to orange or reddish yellow. As a rule, the older the individual the darker in color is the fat, varying from straw-color in children to the dark yellow seen later on in life. Different species of animals have different colored fat, depending upon the difference in its chemic composition. The tissues here are often œdematous, as in general dropsy or erysipelas.

The mammary glands may now be examined from behind, and, if desired, the glands of the axillæ may be exposed by continuing the dissection of the pectoral muscles from beneath, as in Halsted's operation for the removal of a cancerous breast. After the reflection of tissue over the ribs, the mammary gland on each side may be opened by four or five parallel perpendicular incisions, followed by several transverse ones, if deemed necessary. When the female gland is quiescent, it will be found to consist of dense, whitish, fibroid tissue, in which are a few pin-point, grayish-red spots (breast-grains). During lactation it is larger, and the secreting tissue grayish red in color and granular, looking like a salivary gland. (Orth.) Fibrous tissue is found principally near the nipple. Pressure may cause an outflow of a yellowish, creamy liquid (which is not altogether unlike pus in its appearance); this should be at once examined under a low power of the microscope. The milk from the cow may be pink,—the so-called "bloody milk,"—due to infection with the *Bacillus prodigiosus*.¹ The following conditions of the gland should be thought of:

1. Deformities: (a) depressed nipple; (b) *mamma infantilis* (hypoplasia); (c) supernumerary glands or nipples. 2. Congestions and anæmias. 3. Burns. 4. Inflammations: (a) inflammation of

¹*Amer. Med.*, August 26, 1905.

nipple; (*b*) fissures; (*c*) mastitis, acute; (*d*) abscess of connective tissue: (*a*) between skin and mamma; (*β*) between muscle and mamma; (*γ*) acini and ducts. (*c*) Fistula: (*a*) soft edge may mean milk fistula; (*β*) indurated edge may mean mammary abscess; (*γ*) if broken and caseous, it is more likely tuberculous. (5) Granulomata, gunmata, tuberculosis, and caries of ribs. (6) Changes of nutrition. Remember in this connection that tumors of the genitalia or pseudopregnancy may cause an hypertrophy of the gland with a true secretion of milk, and that a similar result may occur in rare cases in the male, apparently from certain psychic influences. (7) Tumors, fibroma, carcinoma, echinococcus cysts, etc.

The muscles now to be examined are those of the neck, chest, and abdomen. The external examination notes any marked changes in bulk. Both transverse and longitudinal sections are necessary to a complete study of the muscles, whose general characters should now be observed. The muscles may be atrophied or hypertrophied. Trophic change induced by affections of the anterior horns of the spinal cord may show itself in muscular atrophy and may be either inflammatory or degenerative, as in infantile paralysis, progressive muscular atrophy, and amyotrophic lateral sclerosis. The lesions may chiefly affect the peripheral and intermuscular nerves, as in lead paralysis with atrophy and in certain atrophies following diphtheria and other exanthemata; or the muscles may be affected primarily, as in the juvenile form of Erb's paralysis and pseudohypertrophic paralysis, or reflexly, as in the Charcot joint affections. (Dreschfeld.) Hypertrophy due to exercise increases the number of muscle-cells; when due to an increased blood-supply, the individual fibres are increased in size. Muscle is a highly organized tissue and does not reproduce itself with ease after injury.

As the color of muscle is largely due to hæmoglobin or some modification of it, it naturally varies according to the condition of the blood. Normally muscle is a bright red, but in anæmia it becomes paler, at times a grayish red. In general it may be said that the color and consistence of the muscles bear a distinct relation to each other: pale muscles are usually soft, while the darker muscles are more firm. The muscles are dry when much fluid has been carried off by the alimentary canal, as in typhus fever and cholera, and moist after the occurrence of disturbances of the circulation. Zenker in 1864 described a form of colloid degeneration resembling the flesh of

fish in the flat muscles of the abdominal walls, occurring especially in enteric fever, though found in tetanus, scarlet fever, smallpox, and when near sarcomatous tissue. In diseases where the muscles have long been inactive a similar grayish, translucent appearance is at times observed. The dark meat of the fowl seems to undergo decomposition sooner than the white, perhaps owing to its proximity to the intestines. The flesh of different animals possesses characteristic odors. Embalming fluids containing zinc bleach the muscles, while arsenic and strychnine preserve their natural color. Formalin hardens them.

The general characteristics having been observed, the pathologic conditions to which these muscles are subject are not liable to escape detection. The more important morbid lesions are:

(1) *Hemorrhages*.—These may result from trauma, wet cups, hypodermic injections, etc. The outflow from the cut veins often gives a good idea as to the color, fluidity, and odor of the blood. A special form of bleeding into the rectus may occur in typhoid fever, the so-called “hæmatoma recti abdominis.”

(2) *Inflammations*.—Among these are included: (a) *Acute Myositis*.—This is often suppurative, and may be primary, from trauma, or more usually secondary (as in the muscles of the chest) to pleural affections or (in the muscles of the abdomen) to pelvic suppuration. This inflammation does not, as a rule, produce true abscesses, but infiltrations in the muscle and separation of its fibres, which undergo a fatty or hyaline degeneration. Hæmatogenous inflammation is by no means uncommon, perfect examples of miliary tubercles often being found if searched for in suitable cases. (b) *Chronic Myositis*.—The interstitial connective tissue is increased so that at times it is visible to the naked eye, the muscle-fibres are atrophied, the color becomes a grayish red, and the muscles feel solid. This condition is generally associated with diseased states of the neighboring parts,—e.g., affections of the ribs, pleuræ, cervical glands, etc. There is a syphilitic form of fibroid myositis. Glanders and actinomycosis may affect the muscles. (c) *Parenchymatous Myositis*.—The muscle is paler than normal. All the various forms of degeneration—as cloudy swelling, hyaline, or fatty—affect muscle, and microscopic examination, as in acute primary polymyositis, is necessary in order to determine their presence. (d) Bony formations are sometimes found, as the “drill” bones in the shoulder muscles and the “rider’s” bones in

the adductors of the thigh. (Ziegler.) Progressive ossifying myositis is a rare disease, running a chronic course, which especially attacks young people; those thus affected are sometimes exhibited in dime museums as "petrifying" persons.

(3) *Parasites*.—The most important parasite is the *Trichina spiralis*, which is found most frequently in the muscles of the neck and in the intercostals near to the attachment of the diaphragm; in old cases the calcified capsules may be easily recognized as small, white, oval bodies, which when present in large numbers look and feel like grains of sand. In the muscle itself the site of election is close to the spot where the tendon unites with the muscle proper. In order to see the parasite the capsule should be dissolved with hydrochloric acid. In its early stages this mass is not readily discovered, and its detection is made easier by pressing a teased portion of muscle between two glass slides and observing it by transmitted light with a hand lens. In all doubtful cases the aid of the microscope should be invoked. Measles (cysticerci) and hydatids may also be found in the muscles.

(4) *Tumors*.—Primary tumors are rare; they usually originate from the connective-tissue septa.

The abdominal cut is now deepened between the umbilicus and the xiphoid cartilage until a small portion of the peritoneum is exposed.¹ This membrane should then be carefully opened, and if it be desired to determine the presence and character of any gas present in the abdominal cavity the incision is carried down to the peritoneum, either two inches above or the same distance below the umbilicus, and the abdominal walls are elevated with the fingers or a tenaculum so as to form a pouch, into which water is poured. A test-tube is then filled with water and inverted over the pouch, and a small incision is made through the peritoneum under the mouth of the test-tube so as to allow any escaping gas to enter it. The test-tube is tightly closed before all the liquid has run out of it by pressing a thumb or finger up against its mouth, and placed in a shallow dish containing sufficient water or mercury to seal the open end of the tube. It is then transmitted to the chemist for examination. If a lighted match be held close to the point where a knife is pushed into the chest, any escaping gas deflects the flame. It should be remembered that certain gas-forming organisms may be the cause of the gaseous collection in

¹ For the technic of a bacteriologic examination see Chapter XXIII.

serous cavities. The recent discovery of hitherto unknown elements in the air makes the study of aggregation of gases here an extremely interesting one. If the gas has an acid odor, an opening in the stomach is to be suspected.

If fluid be present, the abdomen usually protrudes, the sides are flattened, and the superficial veins much dilated, a caput Medusæ forming about the umbilicus. Percussion will often reveal its presence, and when found a mental note should be made carefully to examine the œsophageal veins, as a fatal hemorrhage may occur from their rupture, a fact which I have more than once personally substantiated at autopsies. In ascites just enough of the fluid should be removed to facilitate the determination of the height and location of the diaphragm, which may be done by introducing the hand, palm upward, or a steel sound, into the abdominal cavity and following the under surface of this muscle as far as possible. When the tips of the fingers or the end of the sound reach the point of least resistance, this spot should be sought for with the other hand from without. The vault of the diaphragm extends to the upper border of the fifth rib on the left side and to the fourth rib or fourth interspace on the right. Both sides are measured in the line of junction of the ribs with the costal cartilages. The greater height on the right is due to the liver, which forces the diaphragm upward, and in excessive hepatic hypertrophy or in a large subdiaphragmatic abscess the diaphragm may reach even as high as the level of the second rib. Increase in the abdominal contents, as by tumors, pregnancy, hypertrophy of the spleen, etc., elevates the diaphragm, while augmentation of the thoracic contents naturally pushes it downward. Along with the depression is a sense of fluctuation in cases of hydro- or pyothorax. The position of the diaphragm in a new-born child helps to determine whether or not it has breathed. Before respiration has occurred, the summit is found on a level with the fourth rib on the right side and on a level with the fifth rib or the fourth intercostal space on the left. After full expansion of the lungs has taken place, the summit is found at the fifth or sixth rib on the right and at the sixth rib on the left (Orth).

The opening may now be somewhat enlarged and additional fluid removed with a syringe, cup, or large pipette, measured, and its character noted. The remaining portion may be collected from the various folds and pouches in the peritoneum with a sponge or small cup. Normally, there is little or no fluid present in the abdominal cavity;

its color may be lemon-yellow, red, or brown; icteroid or milky; watery, thick, gruel-like, or even semisolid. The removal of liquid at this stage of the operation prevents its admixture with blood, as from an accidental incision into the liver while cutting the costal cartilages, or with other fluids of the body, such as those from the pericardium, the pleura, the bladder, or various portions of the intestinal tract. Ascites is especially associated with Bright's disease, chronic heart disease, chronic lung disease, anæmia, portal obstruction due to cirrhosis of the liver, chronic passive congestion of the liver, inflammatory adhesions, etc., tumors, displaced or hypertrophied viscera, as the enlarged spleen of malaria or leukæmia, and peritonitis, especially when tuberculous. The serous membrane is apt to be lustreless, whitened, and thickened, especially the capsules of the spleen and liver, if the disease has lasted any length of time. The intestines are frequently matted together by fibrous adhesions, and the uterus and adnexa often show a similar condition, especially when the peritonitis is of a tuberculous nature.

In cases of increased amount of fluid it is of importance to distinguish between a serous transudate and an inflammatory exudate. When large amounts of pus and fibrin are present, the differentiation of these two conditions is quite easy. Difficulty arises when a clear, watery fluid is found in which minute flocculi are seen, as these may be either small flakes of fibrin and pus-cells or collections of washed-off endothelial cells.¹ Much fibrin is an evidence of inflammatory changes, and there is a greater tendency to coagulation. The differential points may be summarized as follows:

TRANSUDATE.

1. Fluid clear and watery, though it may form a spontaneous clot; no odor.
2. Usually alkaline reaction.
3. Specific gravity usually below 1.016.
4. Albumin usually below two per cent.
5. No bacteria or their products present.
6. Urea² and cryoscopic index low.
7. Flocculi are thin, veil-like, transparent, and of a gray color.

EXUDATE.

1. Fluid serous, thick, ropy, and at times foul smelling.
2. Often acid reaction.
3. Specific gravity generally over 1.016.
4. Albumin may exceed three per cent.
5. Contains organisms, toxins, globulicides, etc.
6. Urea and cryoscopic index high.
7. Flocculi are thick, opaque, and of a grayish-white color.

¹ MILLER, *Amer. Med.*, November 12, 1904, shows the difficulties of differentiation from a study of seventy-five cases.

² ULRICH, *Centrabl. f. innere Med.*, no. 16, 1903.

TRANSUDATE.

8. In a transudate the globules present are in too small an amount to react thus.¹
9. Under the microscope (cytologic examination) the flocculi are seen to be made up of flat cells with large nuclei (endothelial cells) and lymphocytes, the latter condition appearing to denote especially primary tuberculosis.

EXUDATE.

8. A drop of an exudate coming in contact with glacial acetic acid causes a turbidity.
9. Microscope shows the flocculi to consist of fine threads and polynuclear leucocytes, the nuclei of which appear more distinctly on the addition of acetic acid.

Milky exudates are of two kinds, fatty and chylous. The former variety has been found in connection with peritoneal and mesenteric cancer, and is recognized by the fat-globules seen on microscopic examination. Slight amounts may be due to the fact that the patient was on a milk diet or was suffering from lipæmia, a dyscrasia also found in diabetes (Osler). A chylous exudate results from the perforation of the thoracic duct or the receptaculum chyli.

Suppurative exudates, due to perforation of the intestine, are thick, yellowish, and contain much fibrin, which is deposited on the peritoneum and bowel in layers. The odor, which is peculiarly nauseating, may be due to the *Bacterium coli commune*; the process is usually acute.

A hemorrhagic exudate or fluid may be non-inflammatory, as that arising from trauma (rupture of the liver or spleen or extra-uterine pregnancy), from cirrhosis of the liver, from cancerous and tuberculous peritonitis, etc., or it may be inflammatory. Pure bile, most frequently mixed with blood, may be found in the abdominal cavity after injury to the gall-bladder or the bile ducts.

One finger is now introduced into the opening previously made in the abdominal cavity, the flap of the skin is elevated, and the incision is somewhat lengthened. Next the index- and middle fingers, pointing downward, of the left hand, held V-shaped (Fig. 62), palm upward, are thrust under the abdominal wall in order to raise it above the intestines so as to prevent injury to them while the cut is continued to the pubes, the fingers thus acting as a director. Then a similar incision is made up towards the xiphoid cartilage. If there be much meteorism, the index-finger of the left hand can be introduced and held against the parietal peritoneum. If scissors be used, the lower

¹ RIVALTA, *Il Policlinico*, no. 6, 1904.

blade may be guarded by the fingers of the left hand when the cut is made. Another method is to make the incision by strong traction upward on the right abdominal flap while the part is well elevated above the intestine. The cutting should preferably be done from within outward, great care being taken not to puncture or injure any of the abdominal viscera, especially the stomach and bladder. After noting the location and distribution of adhesions as pointing to previous inflammatory conditions, it is well to break up such adhesions with the fingers. Should the intestine be accidentally opened, it is best to stop at once and tie both above and below the opening in order to prevent the escape of the contents of the bowel into the peritoneal cavity.

If it be desirable to enlarge the opening in the abdominal wall (Fig. 55), a second incision (*D E*) may be made, at right angles to the first one and about three inches above the umbilicus, or the rectus muscle on one or both sides of the body may be divided subcutaneously a little above Poupart's ligament (*F* and *G*). Should there be a penetrating wound of the abdomen, as from a dagger or a previous cœliotomy, the abdominal incision may be changed at will (Figs. 56 and 57).

When the contents of the stomach are found in the peritoneal cavity, care must be taken to determine whether their escape was due (*a*) to post-mortem digestion, or autopepsia, (*b*) to trauma, (*c*) to perforation from a gastric ulcer or from chemic erosion of the coats of the stomach by poisons, etc., (*d*) to the presence of (*b*) and (*c*), with the factor (*a*) as the real cause. In the first case the ingesta are usually widely distributed throughout the abdominal cavity, though most plentifully in the immediate neighborhood of the perforation, the rent is large and irregular, and the walls are soft and slimy; while in disease the opening is apt to be small and circular and surrounded by evidences of hemorrhage and peritonitis. Undigested food enters the peritoneal cavity through a breach in the gastric wall; when digested food or fæces are present the seat of injury is the duodenum, or bowel, and, if the latter, the material is usually stained with bile. Autodigestion is especially frequent in cachectic children. Intestinal worms may escape into the peritoneal cavity through perforations in the bowel. From the fact that the autopsy is usually performed some time after death, the appearances presented by a gastric ulcer are different from those seen at an operation during life, for, *inter alia*, the serous wall of the ulcer may have undergone post-mortem digestion. Ten to twenty ounces of a five per cent. formaldehyd solution may be

introduced within five hours after death to prevent this condition, when the postmortem in gastric cases, as of ulcer, must be delayed.

The suspensory ligament of the liver may be studied at this time. Should there be an omphalomesenteric duct it must be carefully followed out to its diverticulum in the ileum.

Foreign bodies, which may be calcified, are sometimes found free in the abdominal cavity; they may be derived from torn-off appendices epiploicæ or polypoid tumors. Surgical instruments and appliances, such as sponges, artery-forceps, scissors, and gauze compresses, have been discovered in the abdomen after the performance of operations, v. Neugebauer¹ citing 195 such instances. In Europe severe punishment has been meted out to surgeons for their forgetfulness in this respect.

The abdominal cavity being thoroughly exposed, the most striking abnormalities therein are to be noted. Transposition of the viscera would at once be observed. The most marked displacements of abdominal organs seen by the writer have been in cases of Pott's disease and diaphragmatic herniæ.

The omentum ordinarily comes first under observation. Normally the omentum is non-adherent to the intestines except at its point of attachment; in purulent peritonitis it may be markedly adherent to the peritoneum covering the intestinal tract, creamy or plastic lymph appearing in streaks throughout its structure. The omentum may form a part of every variety of abdominal hernia; it may be present alone in the hernial sac, or the intestines may become strangulated by passing through an opening in it. Trauma or atrophy of the connective tissue may produce such openings, some of which may be of large size. The amount of fat deposited between the layers of the omentum varies considerably, being in some cases practically absent and in others measuring as much as half an inch in thickness. During health the omentum is rich in fat, which disappears early and rapidly in emaciation. Normally the layers are readily separable, and when spread out form a beautifully thin, transparent membrane, with irregular deposits of fat, and showing the blood-vessels partly filled with blood. It is a common seat of fat necrosis, tuberculosis, and generalized cancer; in the last two conditions it may be so contracted upon the transverse colon or the greater curvature of the stomach

¹ *Centralbl. f. Gynäk.*, 1903, vol. xxvii, no. 8.

as to be hardly visible, and separable therefrom only with the greatest difficulty. Enlarged glands, encysted parasites, infarcts, pins, supernumerary spleens, etc., may be found.

The serous covering of the stomach and intestines should be minutely inspected, as the play of colors is very varied and the information gained from this examination is often of great importance. In thrombosis of the mesenteric vessels the gut may be gangrenous for ten feet or more. Miliary tubercles are found opposite tuberculous ulcers and extend along the lymphatics; they are also seen on all the other portions of the peritoneum, often being wide-spread in tuberculous peritonitis. Small, yellowish, creamy collections of lymph, with dilated lymphatics, are seen if death occurred several hours after eating; these are physiologic and not pathologic products, but I have known them to be mistaken for miliary tubercles and even for carcinomatous growths. The presence of typhoid ulcers may be recognized by a congested area along the length of the intestine. The location of the vermiform appendix should always be noted, and Virchow's dictum (first published in 1875, though practised long previously) should be remembered: "At least in every case of inflammation of the peritoneum the appendix is to be carefully examined." In the female an inspection should be made of the uterus and its adnexa. The mesenteric glands, especially those near the ileocæcal valves, are to be carefully looked at; they are greatly enlarged in typhoid fever, in which they sometimes undergo suppuration, and in children dying from inanition, where they appear as red nodes, often running together into conglomerate masses.

The transverse colon may assume odd shapes and positions; thus, it may be bent like the letter U and extend as low as the bladder; it may or may not drag down the stomach. In some cases it forms peculiar S-shaped curves; in others the hepatic and splenic flexures may be markedly deficient. These malpositions are supposed by some to be especially common in the insane. In an infantile form there may be no descending colon. Cotton which has been inserted in the rectum or vagina by the nurse or undertaker to prevent the escape of fecal or other matter may be mistaken for a foreign body and may possibly have caused displacement of neighboring parts.

The stomach is subject to marked changes in size and situation, as from hour-glass contracture, tumors, ulcerations, etc. In the babe its situation is nearly vertical. This viscus is often filled with gas

formed after death; a peculiar sound may sometimes be heard when the gas is expelled by pressure from without. One does not realize the extent to which the stomach may be distended by food and drink until he has made post-mortem examinations of the viscera of inebriates and persons accidentally killed soon after they had eaten hearty meals. The capacity of the stomach may be estimated by filling it with water and measuring the amount; but the method is not accurate and may destroy the appearance later on of a gastric ulcer.

All the openings through which herniæ are apt to occur are next to be examined, the most common varieties of hernia being inguinal hernia in the male and femoral and umbilical herniæ in the female. Other forms of rupture are those into the canal of Nuck, the obturator foramen, or the sciatic notch; into the various fossæ about the cæcum or the fossa jejunalis; into new fossæ formed by bands of adhesions, as from extra-uterine pregnancy; from solutions of continuity in the mesentery; retroperitoneal (foramen of Winslow); crural; diaphragmatic, which is often congenital, but may be due to traumatism; between the rectus abdominis muscles and through Petit's triangle; after operations, especially those on the appendix, etc.

Volvulus and invagination are not infrequently seen. True invagination is to be distinguished from a form which often occurs in children just previous to death; in the latter cases multiple lesions (sometimes as many as fifteen or twenty), produced during the agonal period, are found. There is a peculiar form of invagination in which the ileocæcal valve draws the ileum down into the caput coli; this condition when extreme may even cause the ileocæcal valve to appear at the anus. Philipowicz¹ finds that volvulus of the sigmoid occurred in one-third of all such cases reported.

Note if the gall-bladder is distended or contracted; see if it extends below the liver, and, if so, to what extent. Feel it gently and note if any gall-stones are contained therein. Insert a probe into the gall-ducts to determine whether or not they are patent. Should a bacteriologic examination of this part be wanted, it is now to be made. Follow with the hand the upper surface of the liver, first of the right lobe and then of the left, in order to determine their extent, noting the height and the distance to which they extend below the ribs. The tips of the right and left lobes of a large liver almost meet at the vertebral

¹ *Arch. f. klin. Chir.*, 1903, vol. lxx, nos. 3 and 4.

column. The left lobe may extend downward like a beaver's tail, and as a result of tight lacing the whole organ may be divided into an upper and a lower portion by bands of connective tissue containing the biliary vessels and a few liver-cells. The right lobe may be constricted and a portion become a floating lobe. Accessory lobes are very common; some of them even take the form of supernumerary livers. This condition may be congenital, but it is more frequently due to syphilis. In one of my syphilitic cases the liver was made up of more than thirty lobes, in shape resembling a bunch of flattened and distorted hydatid cysts. The liver should next be slightly raised, the pylorus examined, and the tips of the fingers used to determine the presence of calculi in the bile ducts and gall-bladder.

When no extensive pathologic lesions exist, the situation of the pancreas may readily be determined by remembering the close connection of its head with the concavity of the duodenum. One of the striking pictures seen in opening the abdomen is the so-called "Zucker-guss" or "porcelain" liver and spleen. This condition is seen in ascites and is associated with accumulations of fluid in other parts, as in the pericardium and pleura.

During this superficial examination of the abdominal cavity any needful departure from the ordinary routine may be planned. Thus, in a case of cancer of the head of the pancreas it may be advisable later on to remove this organ along with the stomach, the duodenum, or even the liver. Again, in the case of a child or when there is not time for a careful dissection, all the organs of the abdominal cavity may be removed *en masse*. One must always be on the lookout for supernumerary organs, for they occur in the most unexpected places, as pulmonary tissue below the diaphragm, adrenal tissue in the liver, and pancreatic tissue on the wall of the stomach.

To repeat, the relative positions of all the abdominal tissues should be observed, any departure from the normal noted, and a careful search made for foreign growths, attachments, anomalies, etc., none of the organs being at this time removed or their relations so disturbed as to prevent further examination, should such be required in the future manipulation of the body.

CHAPTER VII

TECHNIC OF EXPOSING THE THORACIC CAVITY AND THE CRITICAL EXAMINATION OF THE PARTS CONTAINED THEREIN

METHOD OF OPENING THE THORAX.—After the superficial examination of the parts contained in the abdomen is completed, the organs of the thoracic cavity may be exposed to view in the following manner: The second to the tenth costal cartilages on the left side are cut through, one by one, from above downward, at a point close to the attachments of the osseous portions of the ribs. For this purpose a heavy cartilage-knife is employed, which should be held as nearly parallel to the chest surface as possible, so that as the blade cuts through one cartilage it strikes the next one, thus preventing injury to the organs beneath. In order that the most useful portion of the knife for future cutting may not be dulled by this procedure, the incising may be done by the part of the blade near the handle. Or the knife may be introduced into the intercostal space beneath the rib that is about to be cut, using the next lower rib as a fulcrum and cutting from within outward (Fig. 63). As the incision proceeds downward the ribs are severed more and more towards the axillary line, thus making the opening in the chest larger and larger. In cases where the cartilages are calcified it may be best to use a costotome or a saw for their division, in which event the ribs might as well be cut in their osseous portions in order to allow more room for subsequent manipulations. Care must be taken, however, not to injure one's self later on by the jagged edges left behind, if this mode of procedure be adopted. The second to the tenth ribs on the right side are now severed in a similar manner.

The right clavicle is next separated from the sternum. As its head articulates with the latter bone and the cartilage of the first rib, the collar-bone is grasped with the left hand and its inner end is moved to and fro, or an assistant may produce the same result by moving the whole arm. In this way the line of articulation is easily made out, and permits the part to be disarticulated by cutting downward and slightly outward until the first rib is reached (Fig. 64), the incision being continued outward in the direction of the shoulder

along the under border of the clavicle and the upper part of the first rib for at least two inches. The first rib, which is generally calcified, is now cut through with a knife from below outward or from above inward (Fig. 65). Or the costotome may be employed for this purpose (Fig. 66).

The next procedure is to grasp the breastplate from below and to make traction upon it upward and towards the right. Beginning on the left side at the lowermost incision in the ribs and keeping close to the lower border of the sternum, cut through the underlying tissues—chiefly diaphragm—separating the thoracic from the abdominal cavity, with short transverse strokes of the knife (Fig. 67), elevating the sternum more and more as the tissues are separated. All the lower attachments having been cut with care so as not to open the pericardium, the breastplate is now elevated and pulled towards the left. Any uncut sternocostoclavicular attachments on the right side are thereby made tense, and being easily discovered are severed, the knife passing next along and beneath the upper part of the sternum (Fig. 68). The tissues being made more and more tense by raising and rotating the sternum, its under surface now appears uppermost and is turned away from the operator. The right first rib is now cut through and the left clavicle is disarticulated either from below (Fig. 69) or from above as seems easiest to the operator. Owing to the increased room and the greater leverage afforded by torsion of the sternum upon the left sternocostoclavicular attachment, this procedure usually requires very little use of the knife and is much easier of accomplishment than on the opposite side, the force applied by the rotation being sometimes sufficient for the sternum's removal. The appearance of the breastplate, after its separation from the body, is shown in Fig. 70. If an aneurism or tumor be found adherent to the ribs or sternum, its point of attachment is preserved by sawing through the bone at some distance therefrom.

In removing the sternum great care is necessary in order to avoid cutting the innominate or internal mammary veins which lie beneath its upper end and the clavicle. In Bavaria and Württemberg, in order that these vessels may not be injured and the part bathed with blood, the regulations for the performance of medicolegal autopsies direct that the lower end of the sternum, when freed, shall be strongly elevated, and the sternoclavicular connection and the first rib cut from the under side, or the breast-bone may be sawed through below the

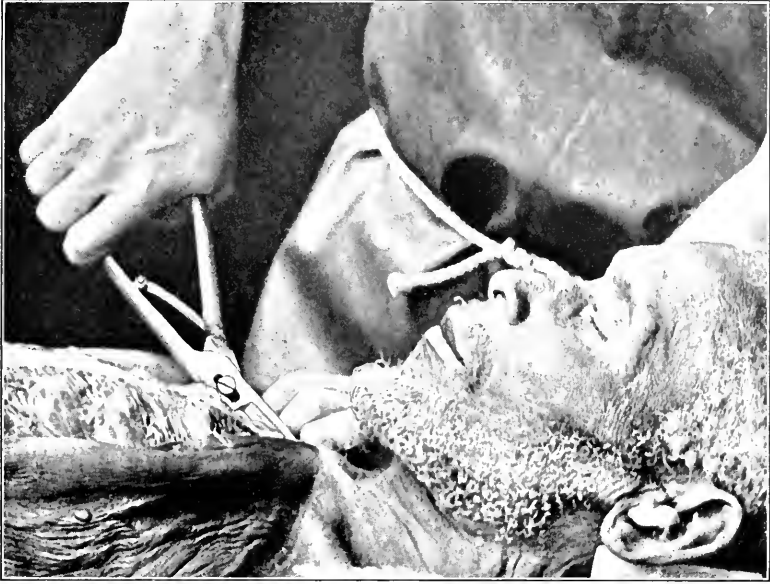

FIG. 66.—Method of incising the first rib and the sternoclavicular articulation with the costotome.

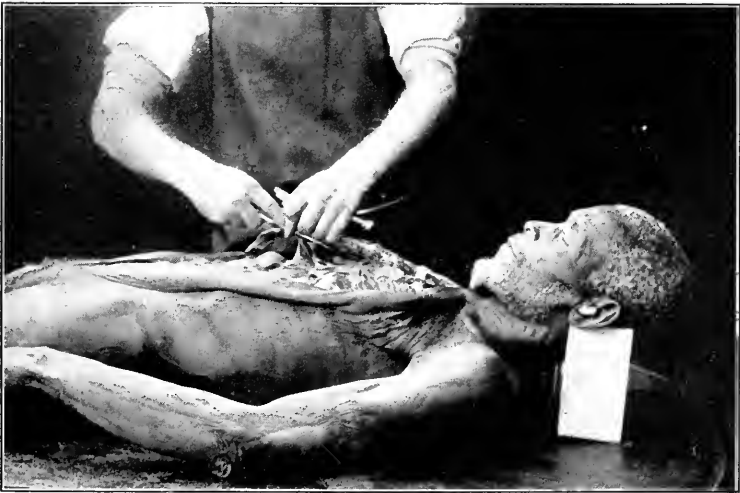

FIG. 67.—All the ribs of the right side have been severed, the sternoclavicular attachment to the first rib remaining intact on the left side. The lower portion of the sternum is elevated and traction made on the diaphragm, which is cut as close as possible to the lower border of the sternum.

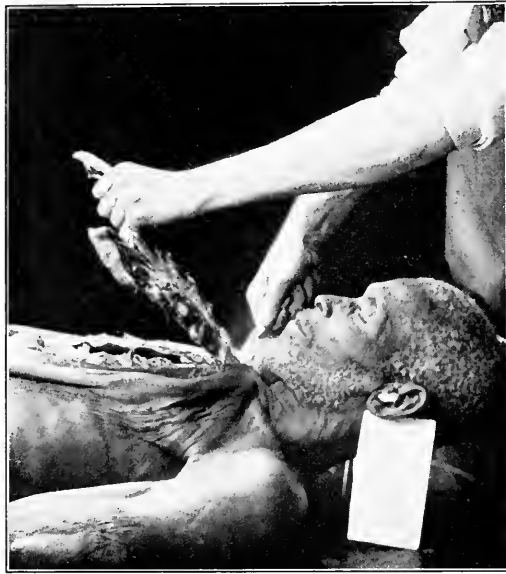


FIG. 68.—The lower border of the sternum having been freed, the breastplate is elevated and pulled upward and towards the left. The left sternoclavicular attachment is thus easily discovered, and is cut through. The first rib is then detached. Care is especially taken on this side not to injure the subclavian vein, not only on account of the blood escaping upon adjacent parts, but also owing to the difficulty after disturbance of the parts in finding the entrance of the thoracic duct into the vein.

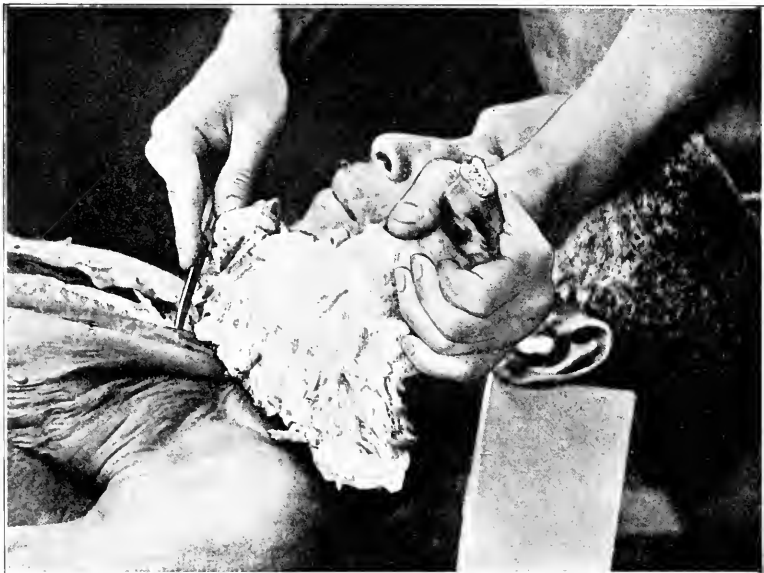

FIG. 69.—The sternum is here practically ready to be removed from the body. The knife is cutting any attachments which may not previously have been severed in the neighborhood of the left sternoclavicular articulation.

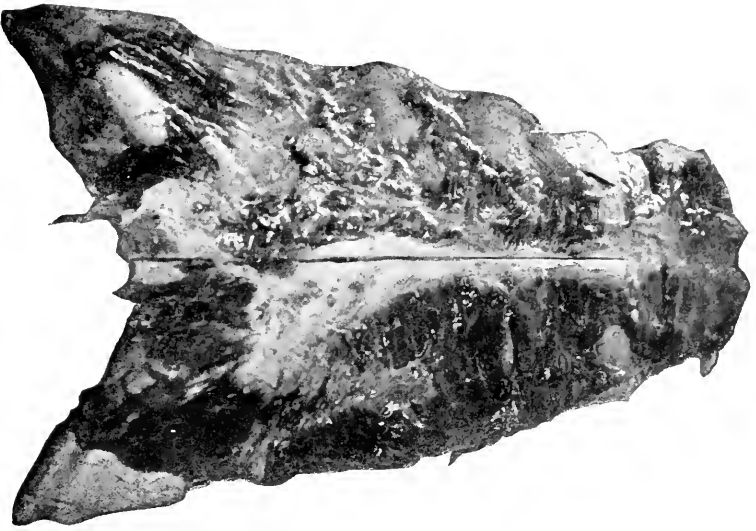


FIG. 70.—Breastplate after its removal from the body. This is what is known in France as the chondrosternal plastron. Should the ribs have been cut through, it would be called the sternocostal plastron. The two internal mammary arteries will be found on the under surface. The retrosternal glands are also to be examined. For an elaborate description of the sternum see *The Human Sternum*, by A. McVillie Paterson, 1904.

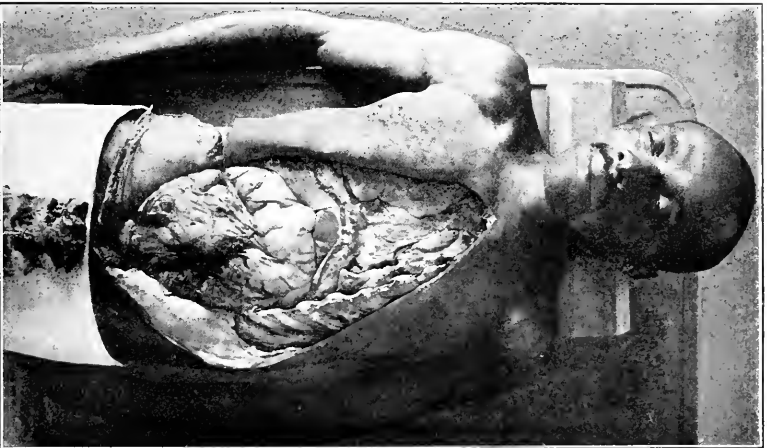


FIG. 71.—The skin flap is placed over the projecting margins of the right clavicle and ribs in order to protect the operator's hands from injury. On the left side this has not been done. On the right side a transverse incision, Fig. 55, *D*, has been made, while on the left side the rectus muscle has been incised as in *G* of the same figure.

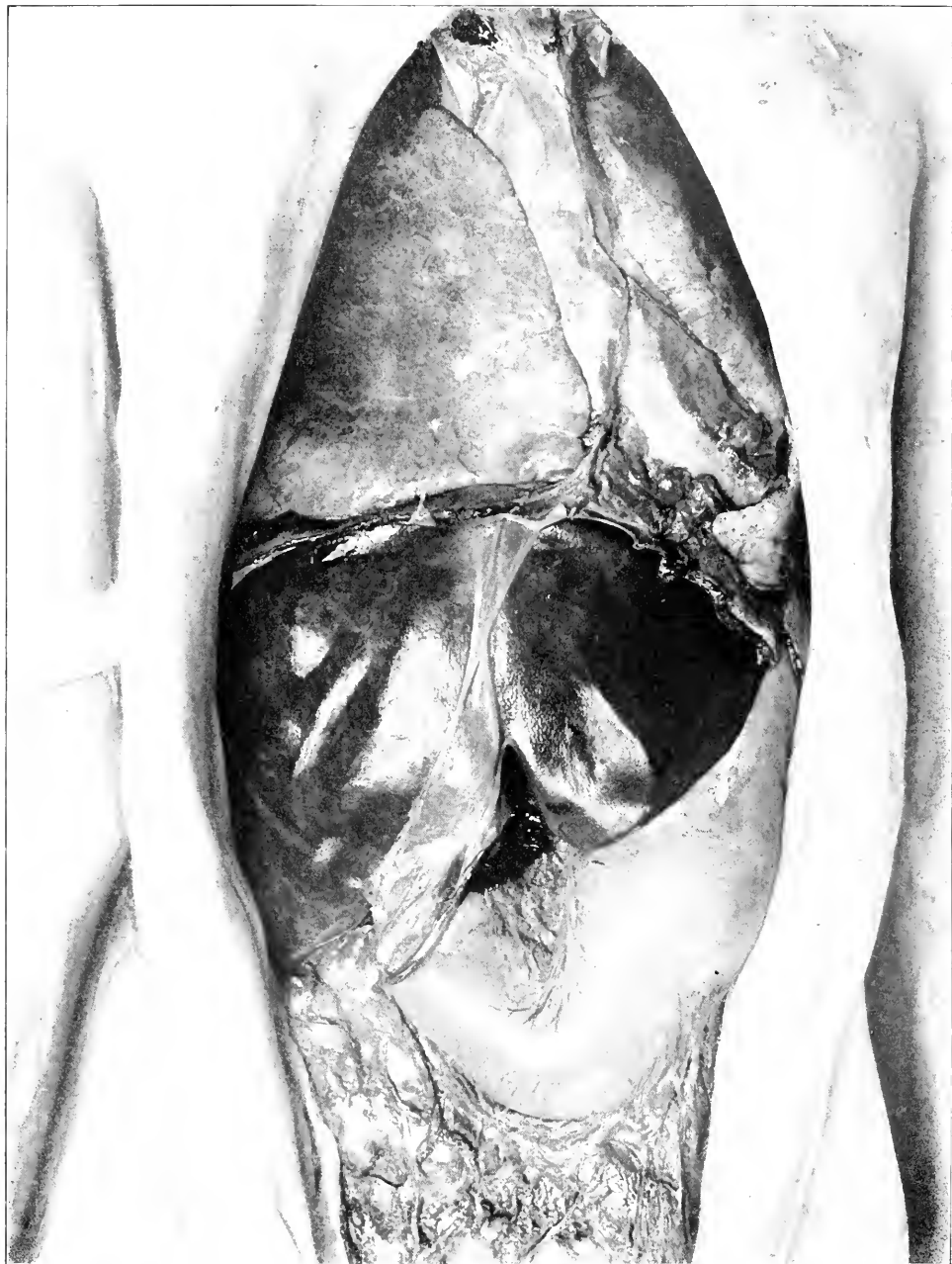


FIG. 72.—Appearance of chest and upper part of abdomen after the opening of the body.

attachment of the first rib, leaving it and the sternoclavicular articulation intact. The writer does not approve of the method often used, after cutting the ribs, of breaking the sternum by turning it backward just below the clavicular attachment. Though it avoids the escape of blood from the veins, it leaves a serrated edge likely to injure the operator's hands in future manipulation and gives less room for the subsequent examination of the thoracic cavity and the neck. Some careless operators do not even remove the bone, but while still attached turn it back over the face. Do not forget to return the sternum to its proper place in the restoration of the thorax, an error often made and not discovered until the body is sewed up.

In order to protect the hands of the operator from injury, the skin flaps are now wound around and beneath the exposed clavicles and ribs (Fig. 71), or these may be covered with a strip of adhesive plaster or of antiseptic gauze held in place by a stitch around an upper and lower rib. Cotton should not be used for this purpose, as portions become detached and adhere to the tissues of the body, thus interfering with later manipulations.

STERNUM AND RIBS.—The examination of the sternum and ribs may now be undertaken. Their shape is often altered, as in Pott's disease, pigeon-breast, emphysema, perforated sternum, rickets, occupation deformities (such as pressure atrophy in shoemakers, caused by holding the shoe against the breast), etc. The ribs may be deficient in number, and supernumerary ribs (*e.g.*, cervical ribs, which may cause brachial neuralgia) or malposed ribs, may be found. The tenth rib is sometimes markedly movable in neurasthenics. Tuberculous caries of the sternum, often secondary to caseation of the mediastinal lymph-glands, or metastatic tumors may be present, or an aneurism may cause pressure atrophy (erosion) or even perforation of this bone. It is this form of saccular aneurism which is sometimes treated by wiring and by electrolysis. Fracture is not common, but may be found, as between the second and third costal cartilages.—*i.e.*, near the junction of the manubrium with the gladiolus. The ensiform appendix of the sternum is sometimes curled upward and outward like a hook in cases of hepatic hypertrophy or tumor. When this condition is present with atrophic cirrhosis of the liver, it indicates a previous enlargement of that organ (Suchard). The marrow of the sternum (best exposed by a longitudinal opening), which is normally of a slightly reddish, lymphoid appearance, may present the changes characteristic

of leukaemia, anaemia, tuberculosis, etc. In the last stages of carcinoma the sternum and ribs are at times so infiltrated with cancerous deposits, especially when the breast is affected, as to break readily. The ribs may show evidence of rhachitis by the presence of the rhachitic rosary, in which case a section of the rounded enlargements, especially where the cartilage joins the bones, will show the changes peculiar to rickets. In old persons the entire cartilage may be calcified or even ossified. The central substance of the ribs sometimes undergoes atrophy and absorption, leaving a large canal filled with blood. The cartilage may contain cystic cavities. Coplin has recently shown that the intercostal muscles are apt to show dissociation of fibres, leucocytosis, infiltration, granulation, etc., in disorders affecting the lungs and pleurae.

CLAVICLES.—Each clavicle may now be freed almost to its acromial attachment, the arm extended at a right angle to the body, and the region of the subclavian vessels and brachial plexus readily exposed and studied, especially for anomalies. In one of my cases—a stab-wound of the shoulder—I found that the brachial plexus had been ligated by a competent surgeon in mistake for the artery. Should it be desired to remove these vessels, the vein may be tied and the whole mass incised beyond this point preparatory to their removal *in toto*. The ending of the thoracic duct on the left side may now be studied, or this may be done after the removal of the heart and lungs.

MEDIASTINUM.—The condition of the mediastinum is to be noted, especially as to emphysema in the areolar tissue, tumors (usually secondary), the ductus arteriosus, the thymus, and the peribronchial and other lymphatic glands. Except in the young, the latter are pigmented, and for this reason have more than once been mistaken for melanotic sarcoma. They are often tuberculous, and may be infiltrated with cancerous or sarcomatous matter. In this situation emphysema is quite often produced after death by the removal of the sternum during the autopsy or by decomposition. When the lung is lacerated, the emphysema is more extensive and may even involve the neck. Hemorrhage into the mediastinum may be due to trauma, rupture of an aneurism, or bleeding from the oesophageal veins, to phosphorus poisoning, or to acute yellow atrophy of the liver. An abscess or chronic mediastinitis, marked by fibrous thickening and density of the connective tissue, may be found. The latter usually occurs in conjunction with a fibrous pericarditis (mediastinopericarditis), and

is of importance on account of its influence upon the heart action (Orth).

THYMUS GLAND.—This weighs about 13.75 grammes at birth, and increases in size until the end of the second year, when it weighs about 26.2 grammes. It then gradually diminishes, and after puberty is normally absent, though the gland should always be sought, as it may, at times, be found in the normal adult. Aberrant glands are sometimes found, as in the neck or just above the diaphragm. In certain pathogenic conditions, as acromegaly, myxœdema, and exophthalmic goitre, the thymus may be present, and then it is more of a yellow color than the normal grayish red. Even when the thymic tissue itself has disappeared, its former situation may usually be located by an increased formation of fibro-adipose tissue. Hemorrhagic areas are often found in the thymus glands of stillborn babes. Pus may sometimes be present, having developed *in situ* or having found its way into the mediastinum along the plane of the cervical fascia. Abscesses are seen at times in syphilitic children, but great care is necessary in making the diagnosis of suppuration, as the altered appearance of the normal juice of the thymus gland after it has undergone post-mortem change may simulate this condition. Sudden death in infants may be due to pressure symptoms from an unduly enlarged thymus. Sarcoma, endothelioma, angioma, and dermoids are also found here.

THYROID AND PARATHYROID GLANDS.¹—Both lobes and the isthmus of the thyroid may at this time be examined *in situ*. If preferred, the gland, together with the tongue, velum palati, epiglottis, œsophagus, trachea, parathyroids, carotids, intercarotid bodies, etc., may be removed in a single piece (see page 122) and studied subsequently detached from the body. The thyroid body may show enlargement due to parenchymatous, telangiectatic, or interstitial changes, or be associated with hypertrophy of the thymus and dilatation and hypertrophy of the heart. The colloid material may be considerably increased in amount and deposits of lime sometimes occur. Congenital goitre is now and then observed. The colloid goitre may become cystic and form cystic adenoma, into which hemorrhage may later occur. Thyroiditis is found in some of the infectious fevers, as diphtheria. Myxœdematous degeneration, or cachexia strumipriva,

¹For a recent book upon this subject, see RICHARDSON'S *Thyroid and Parathyroid Glands*, 1905.

is due to disease or removal of the gland. In cretinism, due to a goitrous thyroid, the body is small, the head large, the countenance heavy, the abdomen protruding, kyphosis is often present, the lips are thick, the skin and mucous membranes are dry and pale, and the hair is coarse and lustreless. Primary malignant tumors of the thyroid are seen, a mixed-celled sarcoma, at times angiomatous, being more common than cancer. Salmon and trout not infrequently show a cancer of the thyroid gland.¹ There may be accessory thyroid glands, as at the base of the tongue, and these may be affected with goitre. Iodothyrim is a normal constituent of the thyroid, and is especially abundant in old age and after the administration internally or the application externally of substances containing iodine. It may appear as such or be combined with albumin and globulin. (Baumann.) A large number of the older reported cases of iodism were said to be Basedow's disease. A curative serum has recently been produced in the Cornell Medical School by the injection into rabbits of human thyroids affected with Graves's disease.

The parathyroid glands,² which were discovered by Sandstroem, are four in number and are histologically different from the thyroid. They are usually unaffected by changes in the thyroid, colloid material being only rarely present. The superior parathyroids are situated behind the junction of the upper two-thirds with the lower one-third of the posterior thyroid body and near the cricoid cartilages. The inferior group is posterior to the lower part of the thyroid lobes. The parathyroids probably develop from the third and fourth branchial clefts, those from the lower cleft eventually becoming the higher ones. They are of epithelial structure and furnish an internal secretion. They possess duct-like passages, probably analogous to the thyroglossal duct, and often become cystic. The parathyroids bear a distinct relation to the larger thyroid vessels and their shape varies considerably. As age advances the amount of fibrous tissue and fat increases. The vessels enter at a slight depression which may be regarded as a hilum. Tumors sometimes develop in the parathyroids, and their removal may give rise to symptoms of myxœdema. Graves's disease is probably due to partial aparathyroidism, notwithstanding the fact that the disease is benefited by section of the cervical sympathetics.

¹ PICK, *Berl. klin. Wchnschr.*, November 13 and 20, 1905.

² *El policlinico*, 1902, no. 21, fasc. 3; *Ziegler's Beiträge*, 1902, vol. xxxi, p. 142; *Virchow's Archiv*, vol. clxxiv, no. 3.

SUPERFICIAL EXAMINATION OF THE PLEURA AND LUNGS.—The appearance and situation of the presenting portions of the lungs are now observed (Fig. 72), as when the thorax is opened, the normal lung retracts, on account of its own elasticity. This contraction of the lung may not occur because of the absence of elasticity; presence of emphysema or of pleural adhesions; because the alveoli are full of solids or fluids, the result of inflammation; or stenosis of the larynx, trachea, etc., may prevent the egress of air. In cases of alcoholic intoxication and suffocation the lungs are generally found to be markedly expanded (Orth). The normal color of the lungs at birth is a pinkish white; in adult life, a dark slate color, mottled in patches; as age advances this mottling may become nearly or quite black, owing to the deposit of carbonaceous material. Changes in color may be due to differences in the amount and character of the blood present or to some pathologic process, as white in the pneumonia of congenital syphilis or black in anthracosis.

Next note the condition of the parietal pleura and the amount of fluid contained in the pleural cavity; whether or not the latter is clear, bloody, turbid, or of an inflammatory nature; and whether or not adhesions are present. Bread-and-butter pleurisy, etc., may be found. The remarks made upon the peritoneal fluid apply with equal force to that found here and in the pericardium. As a practical point it is well to remember that serous membranes when normal are barely visible to the naked eye, being smooth and glistening, but when inflamed their appearance depends upon the nature of the inflammation; the membrane will then be found roughened and more or less opaque, especially if examined by an oblique light. The situation and extent of any lesion present should be noted.

If for any reason a pneumothorax be suspected, after carefully removing the fluid present fill the pleural cavity with water and inflate the lungs with air by means of an intubation tube connected with a pump by a piece of rubber tubing. The rising air bubbles will reveal the situation of the laceration in the lung. In examining the pleural cavities inspect the left one first.

PERICARDIUM.—Note the position and condition of the pericardium, whether or not it is distended with fluid and to what extent it is covered by the lungs. When there is much distention of the pericardial sac, the direction and length of its principal diameters and borders—the latter, it should be remembered, are anatomically the

reverse of those of the heart—should be noted before any fluid is allowed to escape. To open the pericardium it should be grasped near its centre by the fingers or a tenaculum, and a longitudinal fold elevated before it is incised in order to prevent injury to the heart and the escape of any excess of fluid which may be present. A small incision is then made at the highest point, under strict precautions if a bacteriologic examination is to be made, and the fluid present drawn off with a syringe or pipette into a graduated glass and its quantity noted. The opening in the pericardial sac may now be enlarged sufficiently to admit two fingers, which are then spread apart, thus elevating the pericardium and protecting the heart while the pathologist cuts between them. With a knife or a pair of scissors two incisions are made—one downward and to the right, the other downward and to the left—as far as the diaphragmatic attachment. The right flap is then drawn strongly forward away from the heart and another cut is made in an upward direction to the point where the pericardium is reflected around the vessels coming off from the heart (Fig. 73). The phrenic nerves are now plainly seen on the lateral inner surfaces of the pericardium and the anterior portion of the heart is exposed to view. Adipose tissue may often be found at the point of attachment to the diaphragm.

Now is a favorable time to examine the cardiac plexus and the ganglion of Wrisberg; for their situation the reader is referred to Fig. 74, which has been drawn from one by Letulle.

Hydropericardium.—Normally there are from one to two teaspoonfuls of clear, citron-colored, alkaline fluid in the pericardial cavity, which may or may not coagulate spontaneously. In certain renal, cardiac, and pulmonary diseases this may be increased to over a gallon, the greatest amount being seen in general anasarca. The serosa is smooth, glossy, and transparent. Later it may become serofibrinous, hemorrhagic, or purulent.

Hæmopericardium.—The presence of pure blood in the pericardial sac is usually due to the rupture of an aneurism of the heart or of the aorta, to trauma, etc. Under such conditions the blood is present in large amounts and is usually clotted. Hemorrhagic exudates may be the result of inflammatory diseases, as in cancerous and tuberculous pericarditis, of rheumatism, of chronic nephritis, of hypertrophy of the heart, of infectious diseases, of poisons, etc. Here the blood is small in amount and is derived from the newly formed

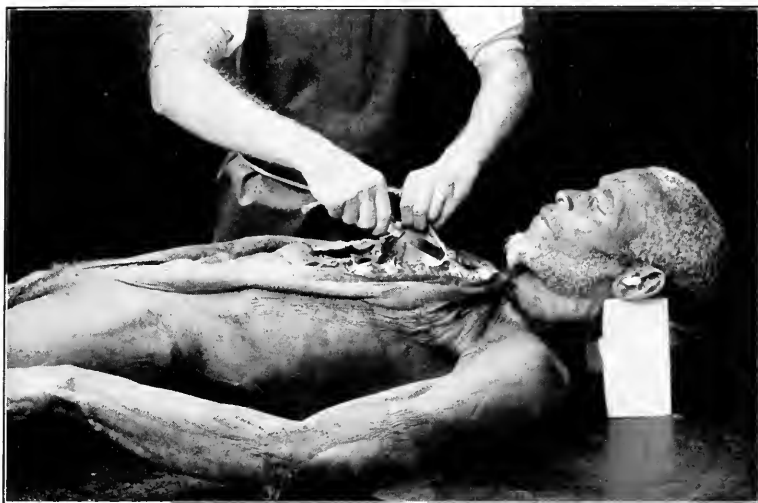


FIG. 73.—Method of opening pericardium. The left hand supports the right flap of the pericardial sac, while the knife cuts the pericardium up to its attachment to the great vessels coming off from the heart.

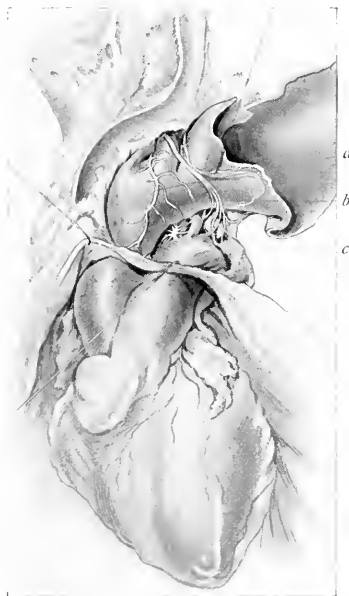


FIG. 74.—*a*, *b*, cardiac plexus; *c*, ganglion of Wrisberg. (After Letulle.)

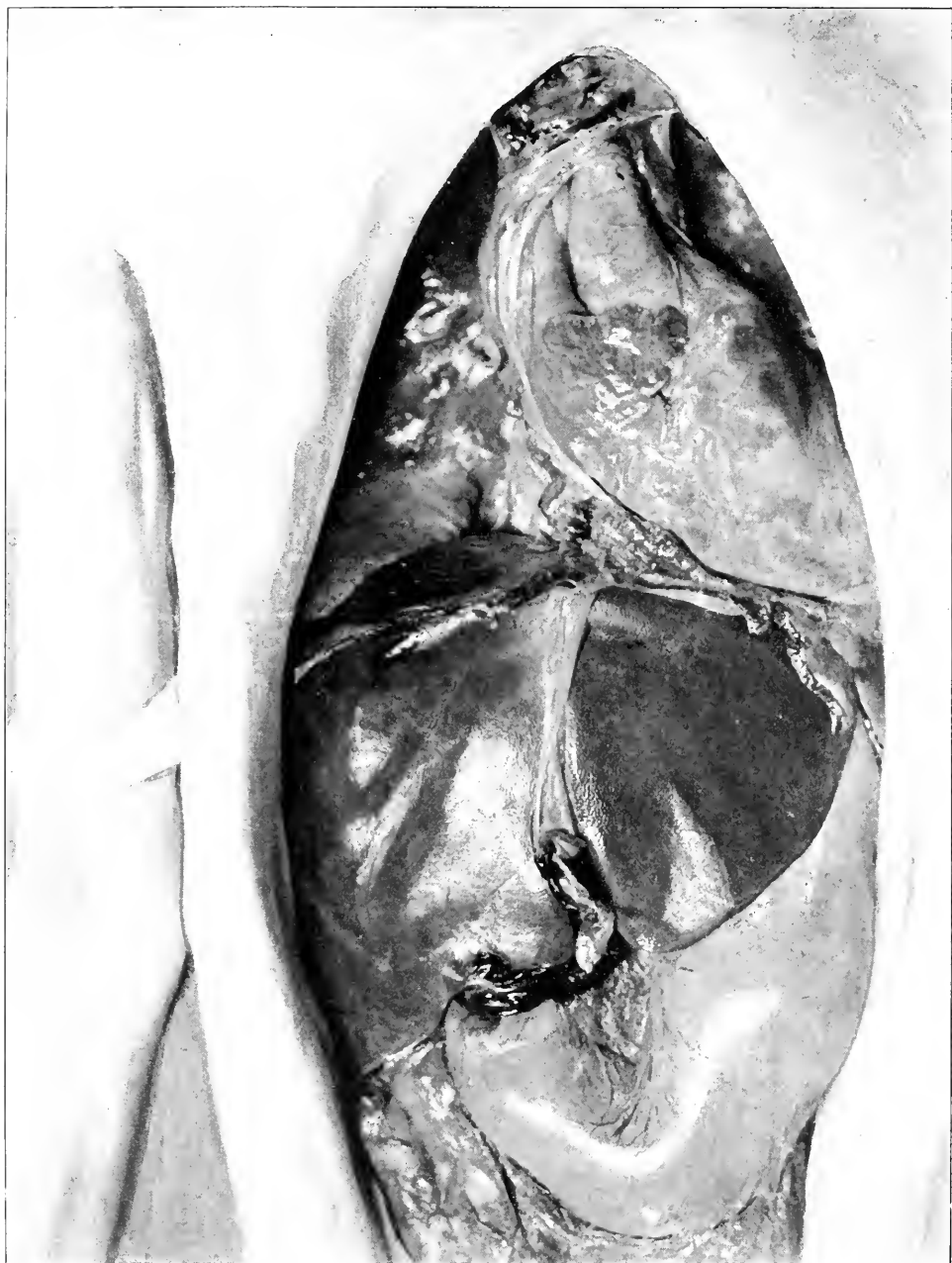


FIG. 75.—Pericardium laid open.

vessels in the inflammatory tissue. The red tint due to the dissolving out of the hæmoglobin may be distinguished from hemorrhage by the absence of red blood-cells in the liquid when examined under the microscope.

Pneumopericardium (Pneumatoxis).—The presence of air in the pericardial sac is rare and is nearly always caused by perforation from without, as in cases of stab-wounds, though it may be due to communication with the lung, œsophagus, or stomach. Or it may be consequent upon decomposition, especially of an exudate. Its pathology resembles that of pneumothorax.

Pericarditis.—The pericardium, normally transparent and glistening, may lose its lustre, become rough and hyperæmic, and be covered with a more or less dry fibrinous exudate. When there is but little fluid and abundant exudate, the latter is thrown into villoid projections by the movements of the heart, and the characteristic buttered surfaces, the hairy heart or *cor villosum*, may be found. Newly formed granulation tissue may succeed a fibrinous exudate, with the formation of a productive pericarditis and the later plastic adherence of the visceral layers of the pericardium, thus causing a complete obliteration of the sac. Suppurative pericarditis shows pus in the sac, and may be the result of trauma or be secondary to suppurative mediastinitis or cancer of the ribs, or it may be an extension of pulmonary or pleural affections or a general infection. Minute hemorrhages are seen, with flocculent or curdy collections in the dependent parts of the sac, and erosions are sometimes present. Organization may take place, vessels growing into the exudate from the subpericardium and even from the endothelium. This may be followed by calcification or, rarely, by osseous formation. In some epidemics of pneumonia I have found that pericarditis was the immediate cause of death in nearly all the fatal cases. There is also a gonorrhœal variety. Milk spots, the result of friction or of old pericarditis, may or may not be elevated.

Other Lesions.—Cancer, usually secondary, may be met with. In a specimen of melanotic sarcoma of the heart and pericardium at the laboratory of morbid anatomy in the University of Pennsylvania, the lesion was secondary here as well as in the lungs, the diagnosis of sarcoma being made by Professor Guitéras from the discovery of pigmented cells in the sputum. Foreign bodies, gummata, cysticerci, echinococci, and trichinæ have been described. Tubercles may be seen

along the course of the vessels, or old cheesy tuberculous deposits may be found in chronic cases.

Injuries.—Wounds of the pericardium and heart may be caused by stabs, broken ribs, and foreign bodies in the œsophagus. If the main axis of the muscle fibres has been cut, the pericardium will be full of blood; if the injury be parallel to its long axis, there may be no bleeding and the wound of the heart may heal spontaneously. Suturing of the heart muscle is now a well-recognized surgical procedure. Foreign bodies, like bullets, have been found encapsulated in heart muscle.

If an aneurism be discovered, it is usually best not to separate the aorta from the heart, but to remove the aneurismal sac and the heart together. In endocarditis vegetations are sometimes present in the arch of the aorta, and might easily be overlooked if not especially searched for. To discover air emboli, the pericardial cavity is filled with water and the heart opened under water *in situ*. Gas may arise from decomposition of the blood.

HEART.¹—The heart is to be observed before it is touched. (Fig. 75.) Its normal position may be altered by fluid in the pericardium or in the pleuræ, by cardiac hypertrophy, in which case the apex may reach to the anterior axillary line, or by tumors of the mediastinum. Abnormalities in position of the heart caused by peculiarities of development may also be found. The heart is about as large as the right fist. It measures from base to apex about $3\frac{1}{2}$ inches (from 85 to 90 millimetres) in men and $3\frac{1}{4}$ inches (80 to 85 millimetres) in women between the ages of twenty and sixty years; its greatest transverse diameter varies from 92 to 105 millimetres in men and 85 to 92 millimetres in women; it is about $1\frac{1}{4}$ inches (35 or 36 millimetres) thick in men, and from 30 to 35 millimetres in women. Any displacement is determined by the situation of the apex and the base, which are anatomically described especially in relation to the ribs, sternum, nipples, and median line of the body. Cardiac enlargement may be due to excessive exercise, heart disease, or secondary to disorders of the lungs, kidneys, aorta, etc. The color of the surface of the heart depends very much upon the condition of the epicardium and the underlying

¹ For a description of cardiac lesions, see Chapter VIII, p. 126; of weights and measurements, Chapter XXIV, p. 400; and of the cardiac vessels in children, Chapter XVIII, p. 289.

fat. The auricles, especially when well filled, are dark blue, while the color of the ventricles differs with the condition of the muscle. The consistence of the various portions of the heart depends upon the degree of contraction of its muscular tissue, as well as upon the amount and composition of its contents (Orth).

The contraction (systole) and the relaxation (diastole) of the two auricles and the two ventricles are considered in relation to the amount of blood contained within them. The amount of blood, especially if it be fluid, does not afford a criterion of the quantity therein during life, owing to the free communication of the vessels and cavities of the heart and to post-mortem rigidity of the cardiac muscle. After death from asphyxiation the right chambers of the heart are distended with dark, fluid blood, while after death from digitalis the left ventricle is contracted. Overfilling of the left ventricle is found when death was caused by cardiac paralysis. For bacteriologic examination or chemic analysis the blood is usually taken with the sterilized pipette, as described on page 383, from the cavity which is most distended by it, unless, of course, for some reason blood from a special cavity or side is desired. The circulation of the lymph and its deposits should be carefully studied.

The epicardium and the amount of subepicardial fat are to be carefully observed for the detection of milk spots and other pathologic conditions. In cachexia the subpericardial fat may become mucoid and be transformed into a soft, transparent, gelatinous mass, which becomes whitish on the addition of acetic acid. Small lipomata may be found near the apex. Minute, sometimes confluent, subpericardial ecchymoses—the so-called spots of Tardieu—are of medicolegal importance, as they are frequent in cases of death due to suffocation, particularly in the new-born; but they may occur in the infectious fevers, as in diphtheria.

The situation and condition of the coronary arteries should be noted, and they, more especially the anterior one (the left), should be palpated, to ascertain whether or not they are "pipe-stem" in character. Their interior is to be examined when they are opened later on. The coronary veins are easily distinguished from the arteries by the relative thinness of their walls as well as by their course. Overfilling of the larger veins indicates an obstruction to the outflow of blood from the right auricle (suffocation, etc.), unless it be confined to the posterior parts, in which case it is due to hypostasis.

The interior of the heart is now to be examined, and here again, to secure the best results, it is expedient to adhere to a definite plan of procedure. There are several so-called "methods" of opening the heart, but all have the same object and all accomplish it more or less completely,—viz., that of exposing the cavities and valves with the least possible interference with the septa and the parts subsequently to be examined, and in such a way as to permit, as far as possible, the component parts of the heart to be reconstructed and returned to their original shape and relations. The method adopted and described by Virchow for use in the Berlin Charité is undoubtedly the best, although the others may, if thoroughly understood and properly executed, yield very satisfactory results.

Ordinarily it is advisable that certain incisions be begun while the heart is still *in situ* and completed after it has been removed from the body. As each cavity is opened, careful note should be made of the quantity, color, and consistence of the contained blood and of the size and character of any clots that may be present. If the opening is occupied by a clot, this should be removed.

Primary Incisions.—After breaking up pericarditic adhesions, if present, the heart should be gently rotated towards the right on its long axis by slight pressure between the index-finger and thumb of the left hand, at the same time that slight traction is made downward and to the left of the body. This will bring the points of entrance of the superior and inferior venæ cavæ into view; midway between which the first incision is begun and then carried downward in the direction of the right ventricular ridge until the right auriculoventricular septum is reached (Fig. 76, *A B*, and Fig. 79¹). Next make an incision in the right ventricle, just below the auriculoventricular septum, passing down the right ventricular ridge to the interventricular septum, which is a little to the right of the apex (Fig. 76, *C D*). On the left side make an incision in the auricle, beginning in or slightly below the lowermost pulmonary vein (Fig. 80) and continuing in the direction of the left ventricular ridge as far as the auriculoventricular septum (Fig. 76, *E F*). Open the left ventricle along the entire length of the left ventricular ridge, and, as this ventricle normally forms the apex of the heart, the incision will be carried to and

¹ For the sake of clearness, the illustrations show the incision in the heart already removed from the body, though the text describes the heart as still attached to the body.

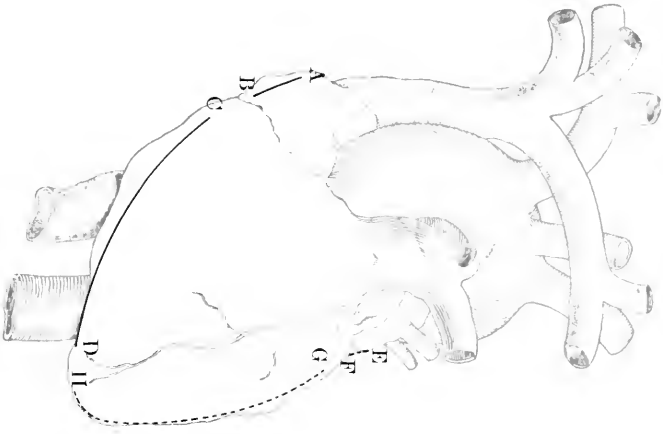


FIG. 76.—Primary incisions for opening the heart, usually made while this organ is still in the body.

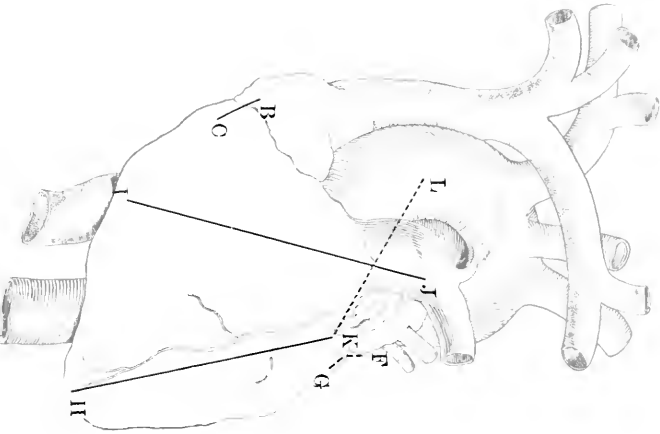


FIG. 77.—Secondary incisions for opening the heart.

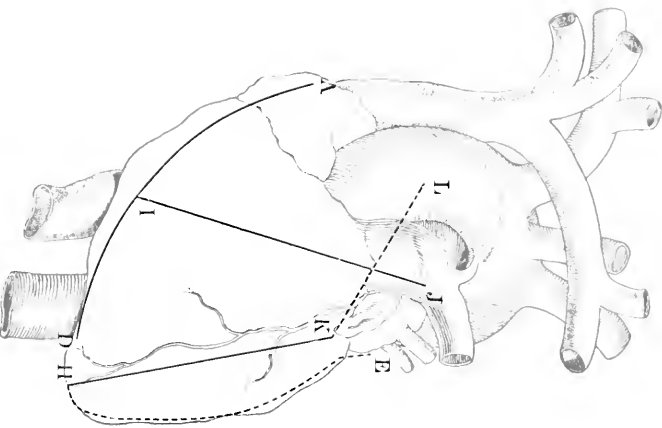


FIG. 78.—The completed incisions for opening the heart.



through that point before the ventricular septum is reached (Fig. 76, *G H*, and Fig. 81). This incision must not join that of the other ventricle, but should be separated by an interval of about one-half inch. From the fact that these incisions are made while the heart is still in the body, they may be called primary incisions.

In cases of sudden death in which an embolus of the pulmonary artery is suspected, it is best to open that blood-vessel before removing the heart. This assures the finding of the embolus, which might otherwise be obscured in cutting the pulmonary artery for removal of the heart. By this method, also, the ductus arteriosus and congenital heart lesions in infants may be investigated.

Removal of the Heart from the Body.—To remove the heart, introduce the index-finger and thumb of the left hand into the left and right ventricles, respectively, grasp the ventricular septum near the apex, and elevate the heart sufficiently to make slight traction on the great blood-vessels (Fig. 82). Then, if no aneurism be present, sever all the normal attachments as near their point of passage through the pericardium as possible, and in the following order,—viz., the inferior vena cava, the superior vena cava, the pulmonary artery, the aorta, and last the pulmonary veins. Or, the heart is drawn upward and laterally, first to one side and then to the other, preparatory to severing the vessels, as may be seen illustrated in Fig. 80. Avoid injury to the œsophagus during the removal of the heart from the body. The large opening seen in the superior vena cava near its termination in the right auricle is the point of entrance of the great azygos vein.

Measuring and Testing the Valves.—Immediately upon the removal of the heart from the body the blood and clots should be carefully removed from about the valves. The valvular openings are then to be measured. Their size is usually estimated by the number of fingers that the ostium will admit. Normally the mitral ostium will admit the index- and middle fingers, whereas through the tricuspid opening the index-, middle, and ring fingers of one hand can be introduced. This method is, of course, convenient, but is unscientific and inaccurate and should be superseded by the use of a constant unit of measure. Graduated cones or balls of definite sizes placed on rods (Figs. 50 and 51) answer the purpose well. They are gently inserted in the direction of the blood-current, and the exact size of the opening can then be given in millimetres or inches. Vegetations upon the valves

may be injured by careless handling. An equally scientific method is to measure the attached margins and to determine the diameter in terms of a circle by dividing by 3.14 (π).

The competency of the valves should now be tested. To do this, trim the great vessels down so that the valves may be plainly seen. The heart is then evenly supported by each of the vessels in turn,—*i.e.*, held in air and in such a way that the semilunar valves will be as nearly horizontal as possible, at the same time receiving no unnatural support from beneath. Water or mercury is then to be poured in by a second person until the vessel is filled, and note is made of the action of the valve. If the operator have no assistant present, the heart may be immersed in water and then quickly taken out, and the valve being tested observed. If there be any leakage from the aorta, make sure that it is not from a cut branch of one of the coronary arteries. The best result of the water-test is seen in the semilunar valves, the competency of the auriculoventricular valves not being accurately determined by this method, which has of late rather fallen into disuse.

Should it be necessary or desirable to ascertain the competency of the auriculoventricular valves, the primary incisions above described are not made until the heart has been removed from the body, and the test is begun by cutting a transverse slice from the apex and exposing the ventricles. The heart is now everted and each ventricle is filled separately with liquid. This method of removing the organ before opening is also useful in examining the heart of a child or when it is desired to make a bacteriologic examination of the valves. In the latter event no water should previously be used, lest some of the vegetations be washed out or other bacteria than those present be introduced, thus creating more or less serious confusion.

Hamilton advises the use of air for testing the competency of the valves, and gives the method as follows: ¹ "An incision is first made into the left auricle, and any post-mortem clots are carefully removed from the left chambers through it. Another incision large enough to admit the nozzle of a half-inch tube is made into the ventricle near its apex and in the line of that required for laying it fully open. The tube is joined to a bellows, and air is driven intermittently into the ventricle by means of it, the aorta having been meanwhile closed. The valve will be seen to open and close, according as the air is aspirated

¹ HAMILTON, *Text-book of Pathology*, vol. i, p. 9.

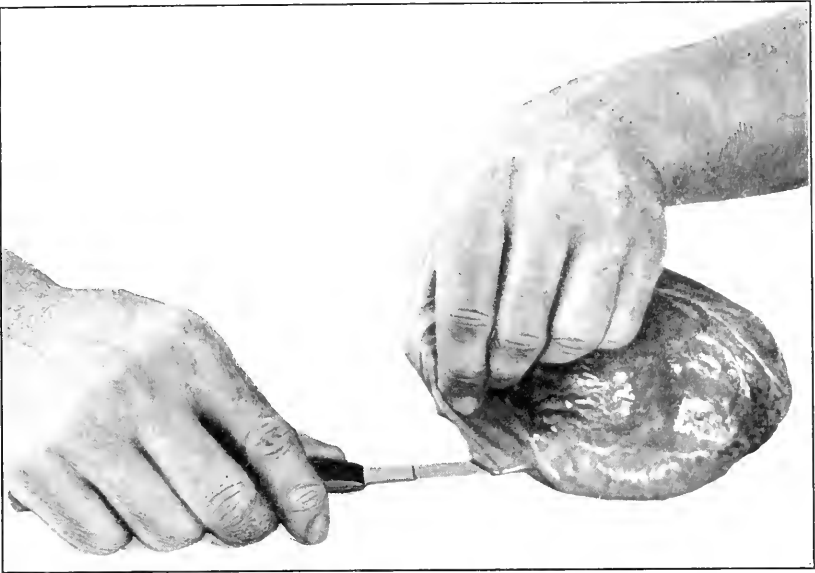


FIG. 79.—Method of opening the right auricle; an incision is made down to the auriculoventricular septum of the right side. This incision is usually made while the heart is *in situ*, but for the sake of clearness is here shown as being made outside of the body.

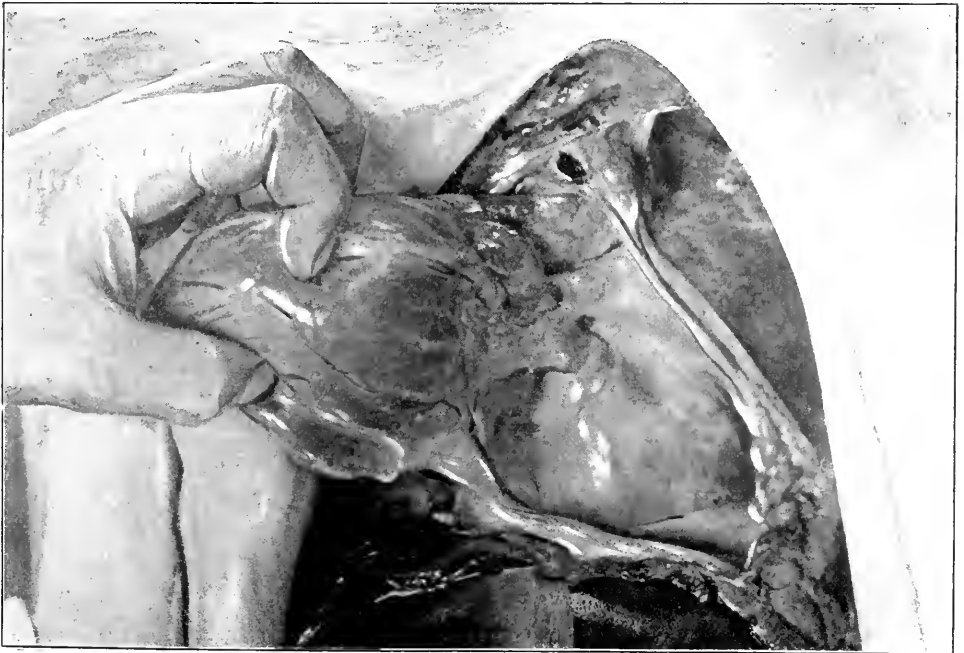

FIG. 80.—The pulmonary veins are placed on a stretch and are ready to be incised. There are two veins on the right and four on the left side, six in all.

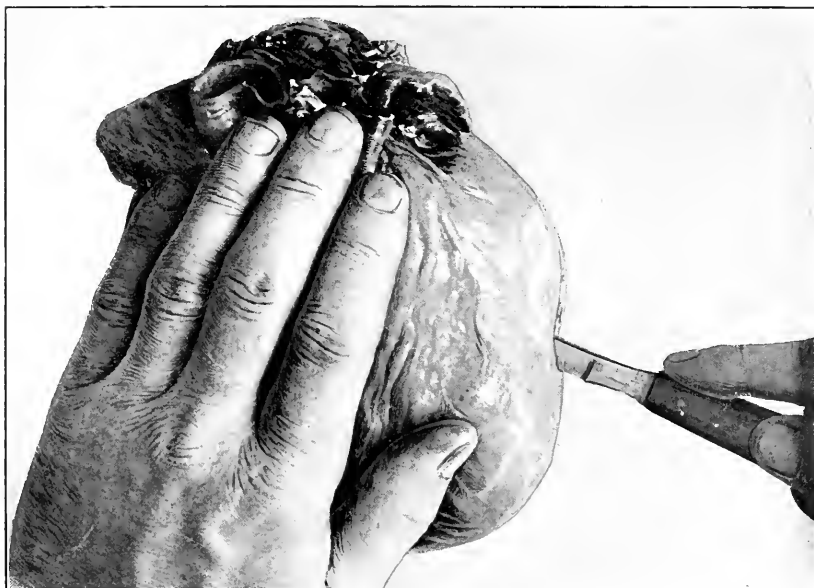

FIG. 81.—Method of opening left ventricle. The heart is being opened outside of the body. The left hand steadies the heart while the knife cuts along the left ventricular ridge, starting just below the auriculoventricular septum and ending at the apex.

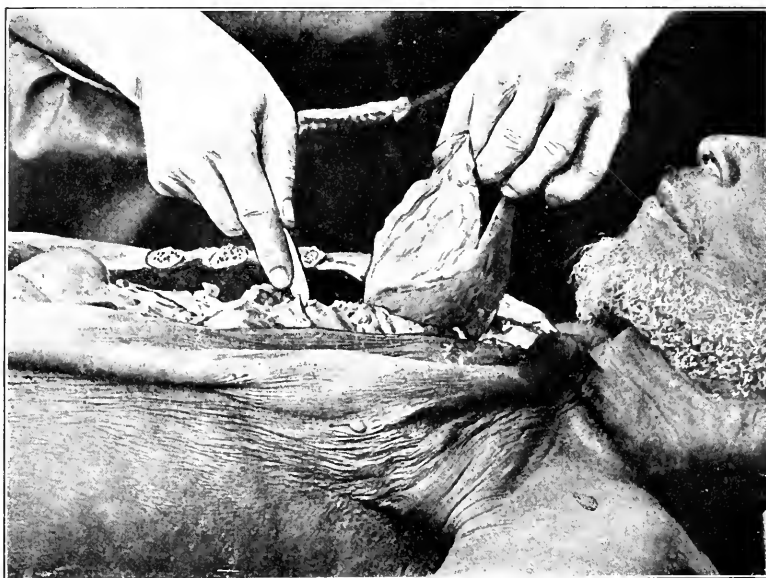


FIG. 82.—Method of removing the heart from the body. The index-finger is placed in the left ventricle and the thumb in the right ventricle, and the ventricular septum is grasped. The heart is then raised upwards and towards the chest, placing on a stretch the blood-vessels which enter the heart. These are cut, starting with the lower pulmonary vein and going from left to right in a circular direction until the upper pulmonary veins are reached, or the initial incision may be made at the inferior vena cava and end with the pulmonary veins.

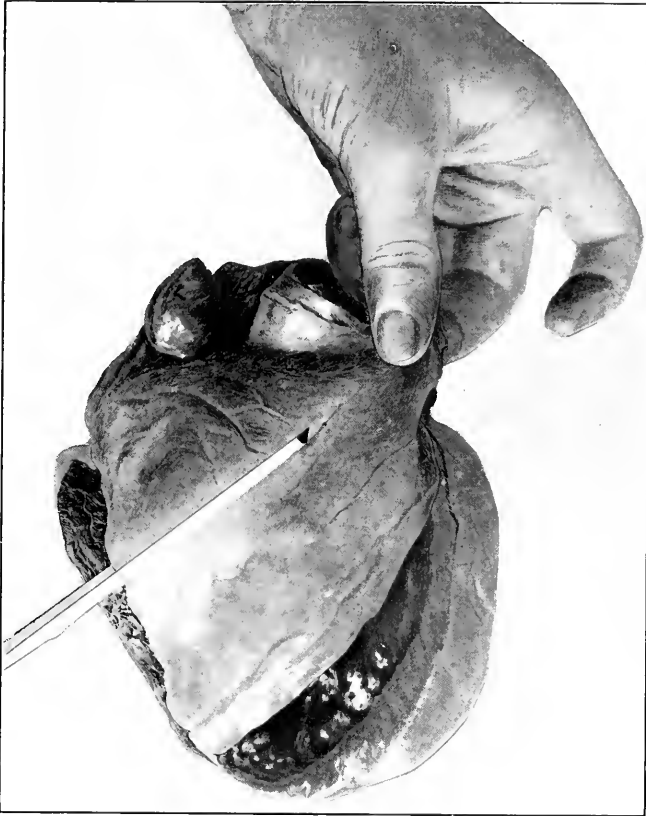


FIG. 83.—The pulmonary artery is made tense with the left hand, while from the centre of the right ventricular incision the anterior portion of the right ventricle is cut in the direction of the thumb and middle finger which mark the junction of the two anterior pulmonary semilunar cusps.

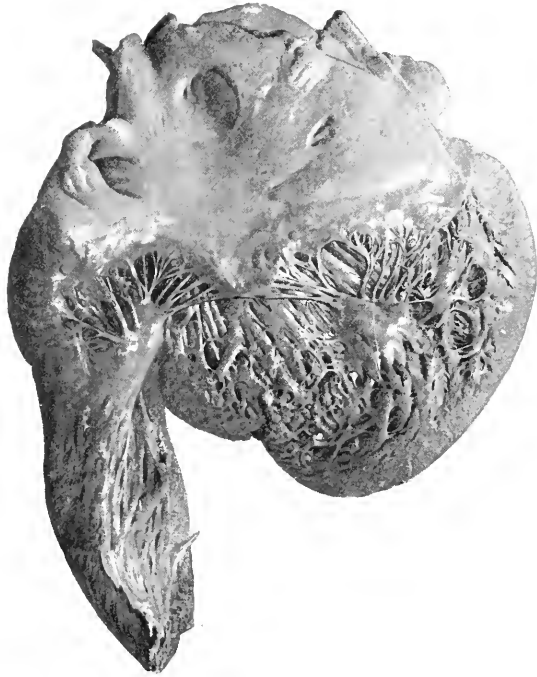


FIG. 84.—The left auricle and ventricle are fully opened, exposing the mitral valve, chordæ tendineæ, papillary muscles, endocardium, etc.

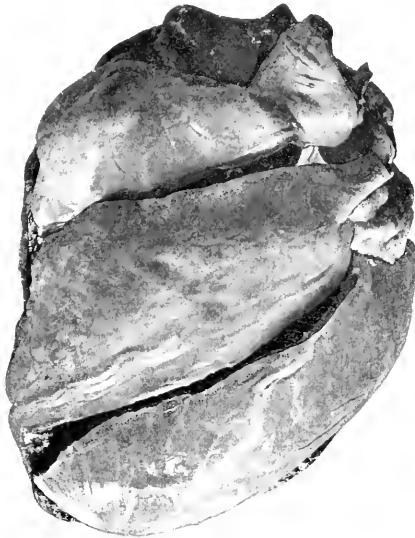


FIG. 85.—Completed incisions of the heart, the organ having been reconstructed after the examination of all its cavities and parts. The coronary artery has not been dissected out. This is done for several inches with the scissors, and then transverse incisions may be made with the knife about three-eighths of an inch apart as the artery becomes smaller and branches.

or driven out of the bellows. A like procedure is adopted for the demonstration of the tricuspid. To test the aortic valve, the incision before described as necessary to lay open the left ventricle is continued up as close to the valve as possible without injuring it. The tube is tied into the aorta, and the action of the valve is watched from below. The same method is used to test the competency of the pulmonary artery valve. As a matter of fact, the tricuspid, in the human heart, will always be found more or less incompetent."

Secondary Incisions.—Place or hold the heart with its posterior surface downward. This can be told by the situation of the pulmonary artery, which leaves the heart *anteriorly*. Insert a pair of probe-pointed scissors or the blade of the enterotome (now a cardiome) into the incision in the right ventricle, and cut from the centre of that incision through the centre of the attachment of the two anterior leaflets of the pulmonary artery (Fig. 77, *I J*, and Fig. 83). The point of junction of the anterior leaflets can usually be seen from the outside, but, if not, it can very easily be determined by looking into the vessel or feeling it with the index-finger. This incision is to be continued until it opens up the entire portion of the pulmonary artery which has been removed from the body. Some pathologists advise making this incision towards the left of the pulmonary artery, so as to cut between the left anterior and posterior cusps. The right ventricle is now exposed so that the condition of the pulmonary valves, endocardium, myocardium, chordæ tendineæ, etc., of this side of the heart may be noted. Now dissect away the connective tissue binding together the pulmonary artery and the aorta.

In opening the left ventricle, cut the anterior wall as near the ventricular septum as possible, starting from the apical extremity (Fig. 77, *H*) and stopping at the point overlapped by the left auricular appendix (*K*). Then, using the cardiome, the incision is completed (either from the aorta or from the ventricle) by cutting between two leaflets (*L K*). In the aorta there is but one anterior leaflet; consequently the incision should be to either one or the other side, but preferably as close as possible to the curves of the pulmonary artery. After examining the valves, myocardium, aortic intima, etc., dissect out the coronary arteries with probe-pointed scissors, starting with the anterior one at its origin in the aorta just above the semilunar valves.

Lastly, unite the auricular and the ventricular incisions of each side by cutting through the auriculoventricular septa (Fig. 77, *B C*

and *F G*). The completed lines are shown schematically in Fig. 78. In Fig. 84 is shown how well the auricle and ventricle of the left side may be examined after the completion of this incision. The knife is best introduced from the auricle to the ventricle with the edge of the blade down and then turned, the cutting being done from within outward. It will be noticed that the instruments are passed through the valvular openings in the same direction as the blood flows. The valves will not be injured by this method and the entire heart can be folded together so as to show its original contour (Fig. 85). In extreme mitral stenosis it is often advisable not to complete the left auriculoventricular incision.

In the examination of the auricles an aperture in the foramen ovale may be overlooked if the heart be so held as to put the auricular wall too much on the stretch. As the communication between the auricles usually takes place by openings most frequently coming off from beneath the former edges of the valve, all suspicious cracks, orifices, or slit-like communications should be searched for with a pointed probe while the heart is relaxed, care being taken not to tear or puncture the tissue or to mistake the ending of the coronary veins, which empty near the obliterated opening, for a patulous foramen. In the left auricle the pulmonary veins rarely come out intact; should they do so, a V-shaped incision is made between each pair so as to expose them. The "dog's ears" are opened by cutting towards their tips, with an extra incision transverse to this should it be required. Softening clots may then be discovered which otherwise would escape attention. The small veins of Thebesius empty into the auricles and ventricles. These may under certain conditions nourish the heart after infarction of the coronary artery.

The situation of the mitral and pulmonary valves can be easily remembered by the mnemonic *Martin Luther, The Reformer*,—*mitral* on the *left* side, *tricuspid* on the *right*. That there is but one *posterior* cusp to the *pulmonary* valve and one *anterior* cusp to the *aorta* affords an easy way to recall this oft-forgotten point.

A simple method of opening the heart, and one which yields fair results, is to place two fingers on the anterior ventricular septum, which is recognized by the situation of the anterior coronary artery, and make two parallel incisions into each ventricle. The pulmonary artery and the aorta may then be opened.

The heart, freed from blood and clots, is now to be weighed. The

normal heart weighs about 250 grammes in women and about 300 grammes in men; but when hypertrophied it may weigh over a kilogramme. In the puerperal state the heart is normally increased in size, the right side often dilated (Letulle), the subpericardial fat increased, and hemorrhages may occur.

The gross appearance of the heart, as well as the thickness, color, and consistence of the various parts of the cardiac muscle, can now be observed. The wall of the right ventricle is normally from 2 to 3 millimetres thick (in women slightly less than in men) and may pathologically measure from 7 to 10 millimetres. The thickness of the wall of the left ventricle is from 7 to 10 millimetres, and may be increased to 25 millimetres or more by pathologic changes.

The color of the heart muscle varies according to the amount of blood it contains, but is always lighter and more grayish red than the skeletal muscles. It may be of a brownish red or even brown, as in anæmia and brown atrophy of the heart. In the latter condition the tortuous vessels and mucoid covering form a striking picture. A brown muscle is an atrophic muscle. The scattered yellowish patches seen throughout the muscle appear in bands, making a sort of net-work (wren's breast or tiger markings). This yellow streaking is often most conspicuous on the papillary muscles of the left ventricle. When this condition is at all extreme, the endocardium and pericardium will be found greatly thickened.¹ In septic conditions the heart is of a dirty-red color and very friable. Light-gray spots or streaks indicate the formation of fibrous tissue. The consistence of the heart muscle varies with the color: brown hearts are hard and dense, while those of a yellowish tinge are apt to be soft and flabby. The fibroid heart is always hypertrophied. After dilatation of an hypertrophied heart sets in, the muscle becomes softer by the process of fatty degeneration. The heart muscle is very soft in sepsis and in cases of heart weakness developing after infectious diseases, especially after typhoid fever and diphtheria.

As hypertrophy of the heart may be due to post-mortem contraction or to marked systole, this organ should, in some cases, be soaked in tepid water before the measurements are taken. The conical shape is often lost by the broadening of the apex and deepening of the muscles.

¹ E. BEER, *Jour. of Path. and Bact.*, December, 1903.

If it be desired to follow out the subclavian vessels by careful dissection, the entire clavicle of that side should first be removed.

If a sound be used for finding the opening of the thoracic duct into the vein, care must be taken not to injure the valve which is present at this point. It is much more difficult to find the entrance of the lymphatic vein of the right side at the junction of the jugular and the right subclavian veins, as the parts are correspondingly smaller on this side of the body.

REMOVAL OF THE LUNGS.—To remove the lung the left hand, palm inward, is introduced along the costal curve until the under portion of the upper lobe can be elevated without undue pressure being made upon the pulmonary tissue. Should there have been no antecedent inflammation and consequent adhesions, a condition especially liable to be found at the apices, this procedure is readily accomplished, but sometimes, when the adhesions are very strong and cannot be broken down by the hand, a probe may be used for this purpose, or it may be necessary to dissect away the costal pleura and even the ribs and remove them along with the lung. When strong adhesions are found in the performance of routine postmortems, the examination of the affected lung may be accomplished by making the incisions while the organ is still in the body. The upper lobe is now carried away from the median line of the body, anteriorly and downward, thus exposing the structures forming the root and giving a fine picture of the arch of the aorta. Then, separating the index- and middle fingers of the left hand, the root of the lung is surrounded so that the upper lobe rests on the palm. In this way pressure can be made downward and away from the spinal column. Next a perpendicular incision should be made in the direction of the spinal column and the bronchus severed. The advantage of this procedure is that it enables the operator to observe the character of the fluid in the bronchus, avoiding its (otherwise very probable) contamination with blood. When the character of the fluid is noted, the rest of the structures, including the intercostals arising from the aorta, may be severed with a few horizontal incisions, care being taken to avoid cutting the aorta, the œsophagus, the large azygos vein, and the thoracic duct. It is well to remember when cutting these vessels that the left bronchus, which is considerably longer and smaller in diameter than the right, is situated *below* the left pulmonary artery, while the right undivided bronchus is entirely *above* the right pulmonary artery. The left lung should be removed first, and, as it has usually two lobes while the right has three (I have seen this condition

reversed but twice), there is no necessity of adopting any method of distinguishing them after they have been removed from the body. Then, too, the left lung has a depression in its anterior border for the apex of the heart, it is longer and narrower than the right, not quite so heavy, and, as already stated, the arrangement of the bronchus and artery is different on the two sides. If, however, it is deemed necessary to do this, a single cut in the apex or bronchus of the left lung and two in the right will afford a ready means of distinguishing the one from the other. Normally, the lungs are darkened from inhalation of pigmented material, the deposit of pigment often assuming a mosaic or net-work appearance, corresponding to the situation of the lymphatics in the external lobules of the lung. Examine the visceral pleura for fibrinous deposits, exudates, adhesions, etc.; note the color, which varies with the age, the quantity of contained blood and air, minute hemorrhages, excessive pigmentation, cicatrices, spicules of bone, emphysematous spots, miliary tubercles, calcified tubercles with cheesy interiors, nodules, patches of consolidation, hemorrhagic and anæmic infarcts, tumors, infectious granulomata, etc. The lungs should be weighed at this time, before they are opened for further study.

Each lung is then carefully and lightly palpated from above downward throughout its entire extent by running the fingers over its surface, the fissures being separated and the anterior and posterior edges examined. By gentle pressure between the fingers crepitation is now produced. What this is like in the normal lung can be learned only by actual trial. In marked emphysema the crackling sound of the larger blebs as they break can sometimes be heard across the room. The presence of liquid naturally decreases crepitation. In hepatization the pulmonary parenchyma may break down even under gentle pressure. After squeezing a crepitant portion of the lung, there is ordinarily enough air left in the tissues to cause the pieces to float upon water. An interesting experiment in cases of atelectasis, infarcts, etc., portions for microscopic study having been previously removed, consists in blowing air forcibly through the bronchus by means of a cannula connected with a bellows.

Placing the lungs upon their posterior surface on a board, rather than upon the more slippery stone table, the lower lobe of one lung is grasped with the thumb, the remaining fingers seizing the upper lobe;¹

¹ If the index-finger be introduced into the fissure between the lobes (and this method holds the lung very securely), care must be taken not to cut the finger in the subsequent procedures.

in this way the organ may be firmly held (Fig. 86). With a single stroke an incision should be made from apex to base, commencing at the lateral convexity and passing to the entrance of the large vessels in the direction of the bronchi, the lung being now laid open like a book (Fig. 87). In the case of the left lung the base had better be turned towards the operator, while in the right it will be *vice versa*, requiring an extra incision to open the middle lobe. *Immediately note the color of the cut surface.* The normal color without blood is light gray, while with different quantities and qualities of blood the shade ranges from light red or brick-red to dark, black, or blue-red. In heart disease the color of the pulmonary tissue is apt to be brown; in anthracosis it is black. The amount of hypostatic congestion, and the character of the fluid which exudes on lightly squeezing, with the fingers, areas not intended for microscopic study, are now determined. A microscopic examination of the scrapings collected by passing the knife-blade over the cut surface should be made. The appearance of the surface after removal of the liquid is determined, and any unusual spots more carefully examined. Next it is necessary to examine the substance of the lung for cavities, to observe the shape and position of areas of consolidation, and to ascertain the specific gravity of consolidated areas in cold water. In pneumonic cases the entire lung may be placed in water to determine the portion containing air. A hemorrhagic infarct or a portion of an apoplectic lung will sink in water, as well as the lung of croupous pneumonia. Cubes of normal lung may sink in fluids having a low specific gravity.

EXAMINATION OF THE PULMONARY VESSELS.—Now is the time to open the pulmonary veins (Fig. 88), artery, and bronchi (Fig. 89). Parallel or transverse incisions may be made, but care should be taken not to make them so deep as to detach any portions of the lung. The pulmonary arteries resemble the veins in character, though they are thicker, more elastic, and whiter than the latter. By following the pulmonary artery up on its anterior aspect from the heart there is no danger of mistaking one for the other, this error most often occurring when the dissection is not started until after the lungs have been removed from the body. Again, there is but one artery for each lung, while there are two veins. In other words, the two blood-vessels which are alike are the veins, and the remaining one is the artery.

REMOVAL IN ONE PIECE AND SUBSEQUENT EXAMINATION OF TONGUE, ŒSOPHAGUS, TRACHEA, AND ADJACENT STRUCTURES.—It is frequently advisable to excise as one piece the tongue, œsophagus,




FIG. 86.—Method of opening the left lung. The organ, lying on its posterior surface, is held steady by slight pressure with the left hand on its upper portion, while a long, clean cut is made from the apex to the base of the lower lobe. In opening the right lung the incision is best made in the opposite direction—*i.e.*, from the base to the apex.




FIG. 87.—Lung laid open for minute inspection. The lung from this case was emphysematous and showed bronchiectasis. Letulle makes seventeen incisions in the lung in its examination.

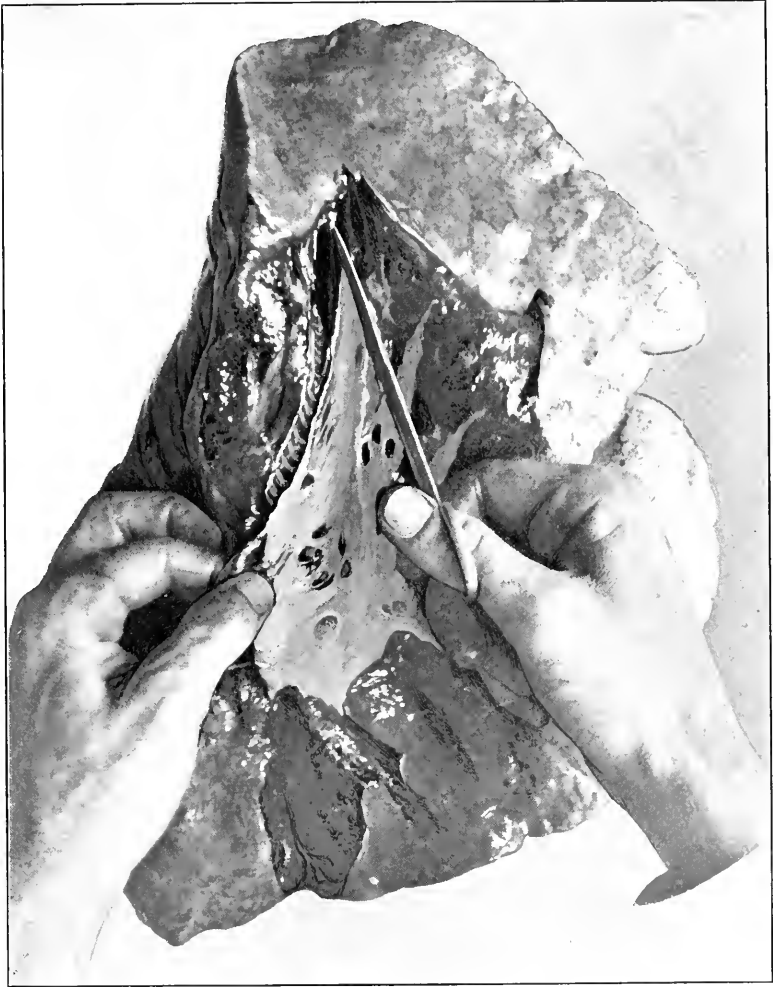


FIG. 88.—Method of opening the branches of the pulmonary vein. The artery is thicker and more elastic than the vein. The veins are best opened after the primary incisions shown in Fig. 87 have been made. It is naturally impossible in the same lung to make a complete dissection of the bronchi, artery, and veins, owing to cutting of vessels not belonging to the system undergoing dissection.

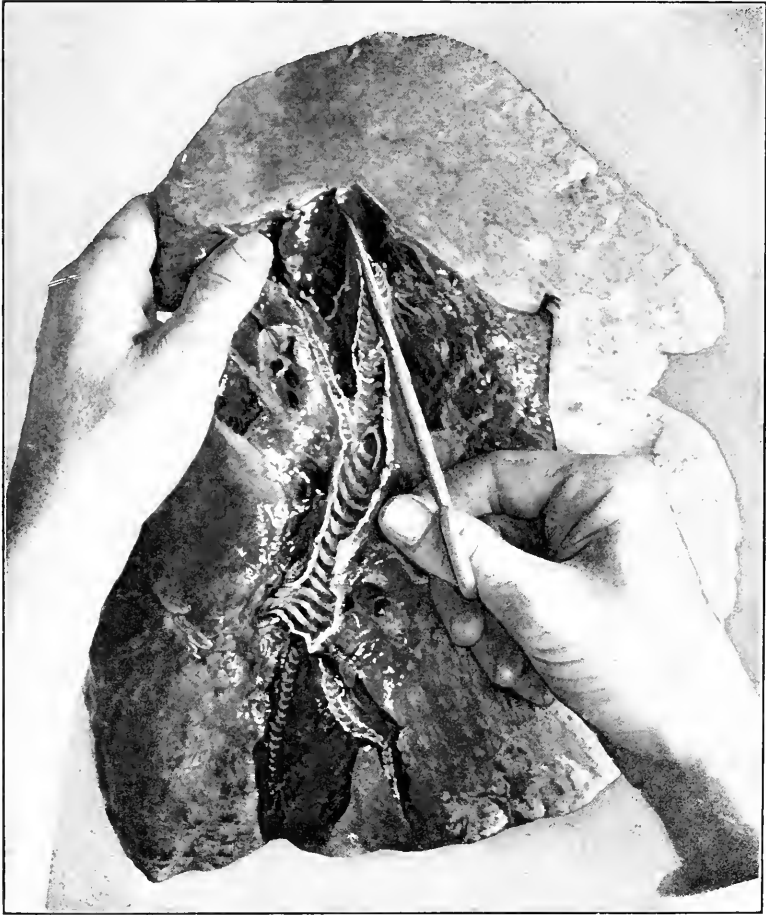


FIG. 8c.—Method of opening the bronchial ramifications.

thyroid gland, trachea, epiglottis, etc., so that a minute examination of these parts may be made while they are exposed to good light in a convenient situation. For this purpose, in those cases where disfigurement of the body is of no importance, the primary incision over the thorax may be extended up to the symphysis menti and the parts dissected out with ease. Orth's method of doing this is as follows: The skin is first reflected. Then by the use of the cartilage-knife an incision is made into the mouth at one angle of the jaws as close as possible to the bone, cutting with a sawing motion to the chin and then back on the other side to the angle of the jaw, severing the genioglossus muscle. The tongue, after being separated from the jaw, is pulled down with the forceps held in the left hand, after which the soft palate should be separated from the hard by the use of a knife, including in the operation the tonsils. A cut should now be made as high up as possible to remove the pharynx, trachea, and œsophagus from the spinal column and the deep pharyngeal muscles. This should be done with small perpendicular incisions on the spinal column through the retropharyngeal and retro-œsophageal tissue, the tongue being pulled strongly forward. The parts may now be left intact for later dissection, or the œsophagus may be cut off just above its entrance into the stomach and the trachea below the vocal cords. These parts may be removed in a single piece, however, without the incision being extended to the chin, as by careful manipulation the hand can tear the skin away anteriorly from its attachments by working from beneath, and a knife may be introduced from below into the centre of the tongue (through the genioglossus muscle) posterior to its frænum, thus leaving the tip *in situ* in case an examination of the mouth is to be made. (Fig. 90.) By a circular incision of the muscles, fasciæ, etc., with the knife beneath the skin, keeping as close as possible to the bony walls of the jaw, to the carotids, and to the bodies of the vertebræ, the pharynx, larynx, trachea, and œsophagus may be separated, drawn forward and downward, and removed. The tonsils are either torn out bodily with the fingers from below, or else incised while in the body and examined from above or below by reflected light. The velum palati may also be removed by cutting the hard palate in front and dissecting it away from its bony attachment. This should always be done in cleft palate. The edges of the tongue may be examined for injuries, such as wounds made by the teeth during a fatal convulsion. The mucous membrane is flattened in syphilis, and the tongue may be the seat of lymphangioma. The vessels of

the arm should now be cut and the arch of the aorta detached from the œsophagus and bronchi. The whole aorta may be examined later, if it is deemed better, or this vessel as far as the diaphragm can be removed with the œsophagus. This procedure is particularly useful when disease of the latter is suspected, as a cancer of the gullet may rupture into the aorta or an aneurism of the aorta break into the œsophagus. The aorta is from seven to eight centimetres in diameter at its commencement and gradually narrows to forty-five or even thirty-five millimetres in the abdominal cavity. The œsophagus and the trachea are preferably opened up posteriorly throughout their entire extent. (Figs. 91, 92, and 93.) Carefully examine the vocal cords; see if there are any tumors, syphilitic or tuberculous ulcerations, inflammation, malformations, foreign bodies, diphtheritic membrane, etc. The condition of the mucous membrane of the trachea and the elasticity of its cartilages should be carefully tested. I have seen the whole transformed into a rigid tube by infiltration with lime salts. The trachea and larynx may show abrasions and injuries, as by cut throat, deformities, stenosis, pressure defects, etc. The œsophageal veins frequently carry on a large part of the collateral circulation in cirrhosis of the liver, and the rupture of one of them may cause death from hemorrhage, much blood being found in the intestinal tract. The œsophagus may show peptic or typhoid ulcers, and diverticula of various kinds and degrees are seen. The œsophagus may be so dilated as to hold several pints of water. Ulcerations on healing may result in stricture, which as time goes on may be the starting-point of a cancer, as in one of my cases where a stricture due to the taking of lye was followed by a squamous epithelioma. Various other forms of tumors, as papillomatous outgrowths, occur, and thrush is also found.

In cases of strangulation, as by hanging or otherwise, the examination of the vessels of the neck is of great importance. For this purpose the incision behind the ear, made for the removal of the brain, may be extended down the neck, and the skin, fat, and superficial fascia of the face dissected away, thus making easy the exposure of the jugulars, carotids, etc. The tearing of the intima of the carotid indicates hanging or strangulation; marks produced by pressure of the rope, in the form of parchment-like skin at the sides of the neck and hemorrhages into the tissues, are also found after death by hanging. Emboli of the carotid may cause sudden death, and thrombophlebitis of the jugular in cases of thrombosis of the lateral sinus is to be

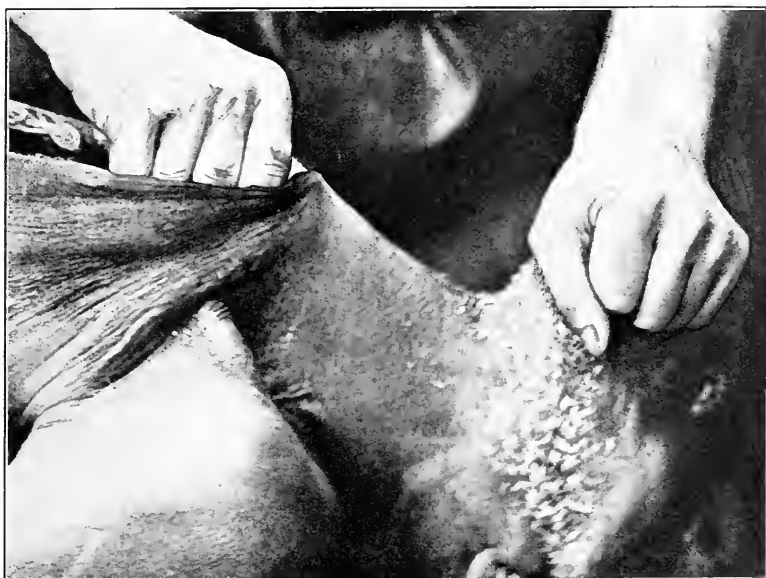

FIG. 90.—Method of removing tongue, tonsils, cesophagus, trachea, etc., in a single piece, without incising the skin more than is done in the primary cut.

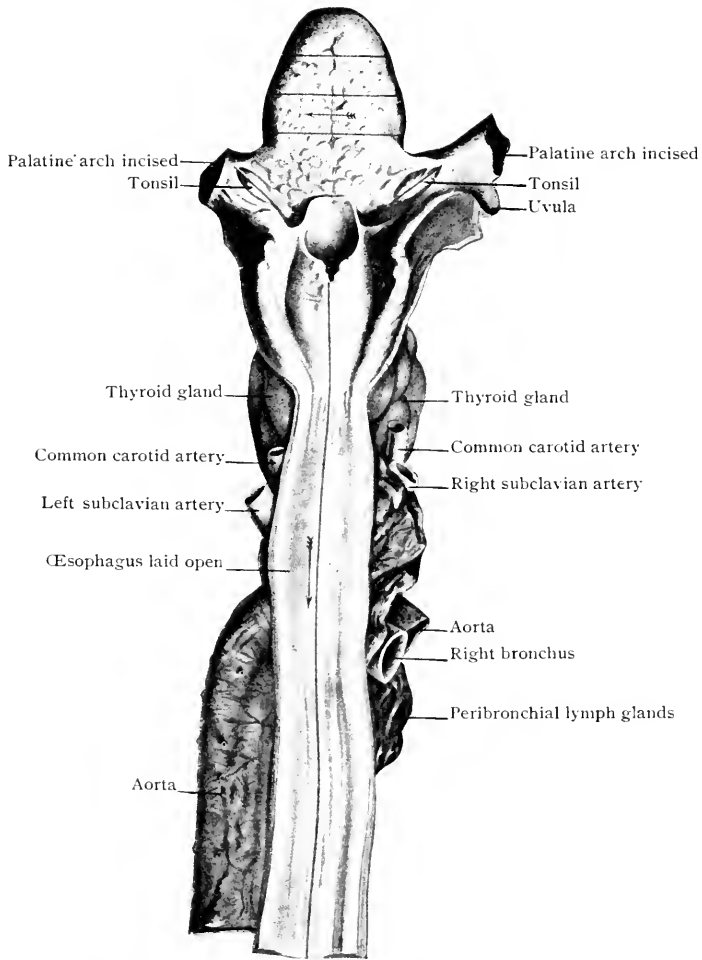


FIG. 91.—Examination of the organs of the neck. The arrows show the direction in which the incisions in the tongue and in the posterior wall of the œsophagus are to be made. (After Nauwerck.)

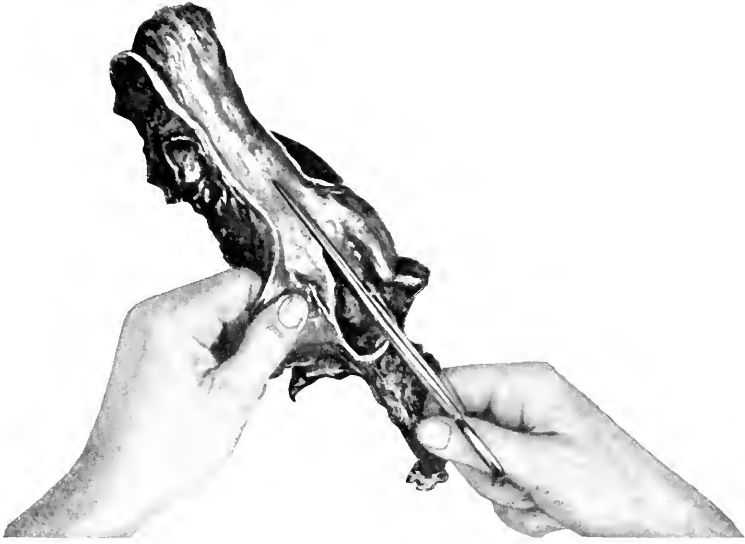

FIG. 92.—Method of opening trachea posteriorly. The incision starts from above and extends downwards.

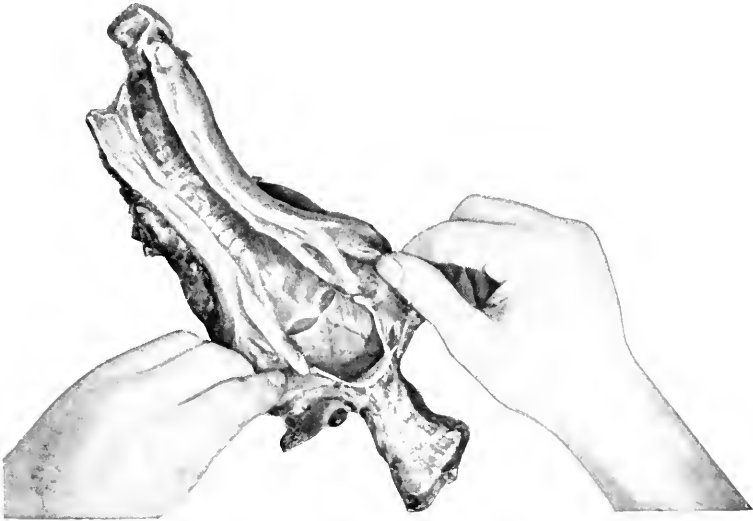


FIG. 93.—Examination of trachea and vocal cords. The incision may be made anteriorly, thus leaving the walls between the two parts intact.

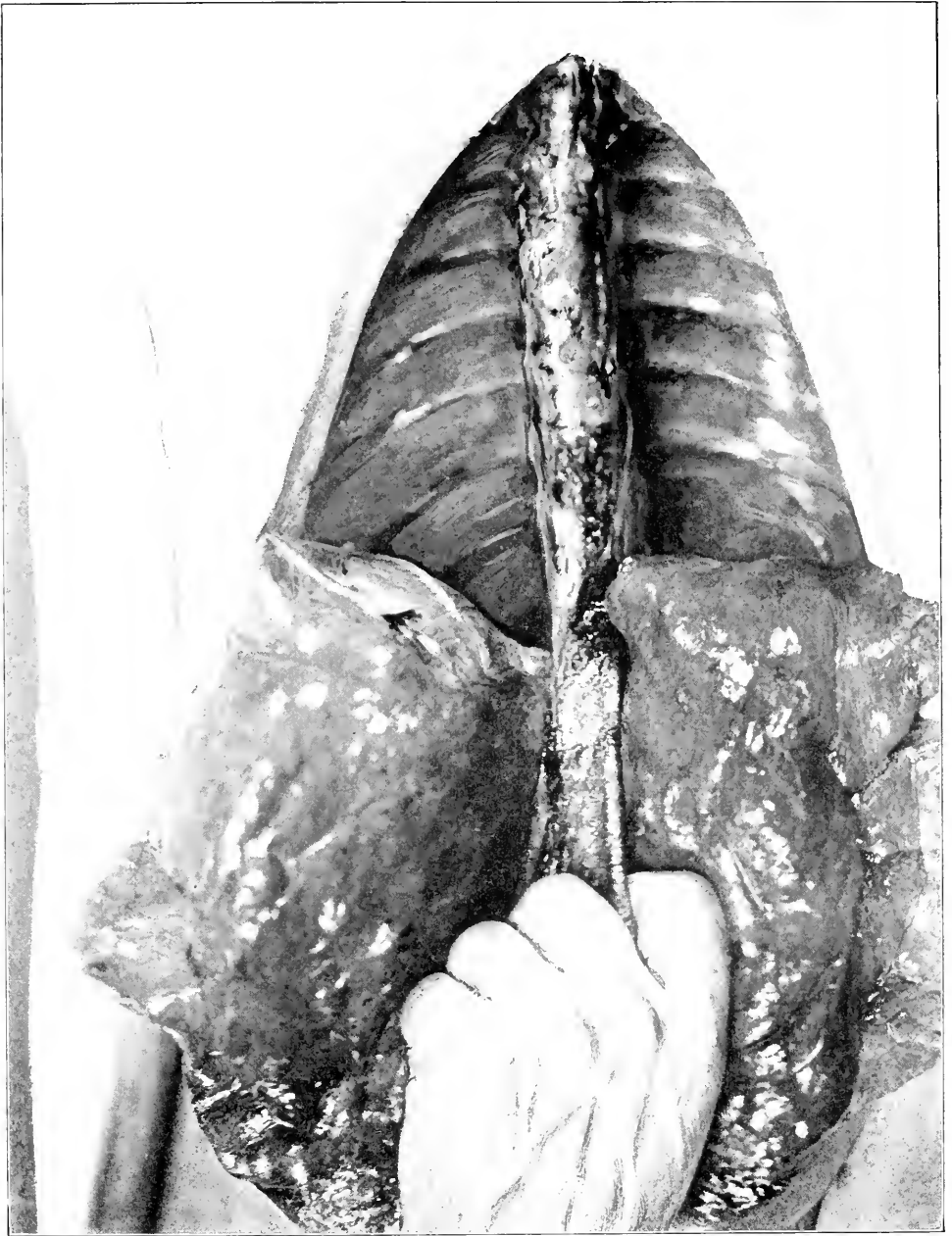


FIG. 94.—"Grand swipe" of the thoracic and abdominal organs.

searched for. Aneurisms are sometimes seen. Hemorrhages into the sympathetic nerves may occur in cases of fever with delirium and of heat-stroke; pigmentation and fatty changes also take place in the cachexias and in fevers.

The finding of the carotid body is facilitated by the removal of the common carotid artery along with about one-half inch of the internal and external carotids. The ganglion is located usually at or slightly posteriorly to the angle formed by the bifurcation of the carotid, but it may be situated at any place in this neighborhood. It closely resembles the superior cervical ganglion and is the size of a grain of rice, somewhat oval in shape, vascular, and of good consistency. It is attached to the artery by means of a small band of connective tissue; bands from the capsule divide it into nearly equal parts and again into lobules. Funke¹ has tabulated fifteen tumors arising from the carotid body, his own case being a perithelioma. Such tumors are potato-shaped (Hutchinson, 1888) and may cause death in a year, metastases occurring, as to the liver.

REMOVAL IN ONE PIECE OF THE THORACIC AND ABDOMINAL ORGANS.—As was seen on page 17, Letulle advises in the performance of an autopsy, the routine removal of the thoracic and abdominal organs in one piece. This procedure presents exceptional advantages in the case of a child, and the method of its accomplishment is described in Chapter XVIII. Fig. 94 shows the method of pulling down the thoracic organs, their attachment to the vertebral column having been previously loosened with a knife. Should it be so desired, the tongue, œsophagus, trachea, and adjacent structures may be left attached to the thoracic organs and removed at the same time.

¹ *Amer. Med.*, July 16, 1904.

CHAPTER VIII

DISEASES OF THE HEART, BLOOD, BLOOD-VESSELS, AND LYMPH-VESSELS

ANOMALIES.—Abnormalities in the development of the heart are frequent and varied, occurring especially in non-viable infants. Thus, one may find acardia, double hearts, two- or three-chambered hearts, rudimentary hearts, malformed blood-vessels, premature closure or patency of fetal passages, as of the foramen ovale and ductus arteriosus, imperfections of the septa, increase or decrease in the number of semilunar leaflets, stenosis and atresia of the pulmonary, aortic, and arteriosal conuses, transposition of the primary arterial trunks, ectopia, with deformity of the anterior part of the chest, etc. Dextrocardia may be part of a general congenital *situs inversus* or be confined to the thoracic organs alone. Acquired malformations are considered under the separate diseases of the heart.

BLOOD.—Many of the changes which the blood undergoes are macroscopic and can be studied *post mortem*, though it should be remembered that numerous factors tend to alter its composition and color in a dead body. A pocket spectroscope and a Tallqvist or a Wetherill (Plate III) hæmoglobin scale are useful for studying the characteristics of the blood. Reproductions of the spectra of hæmoglobin, reduced hæmoglobin, carbon-monoxid hæmoglobin, etc., will be found in many of the works on physiology and toxicology. In using the Tallqvist blood-color scale due allowance must be made for the difference in the color of the blood after death and for the abstraction of the water. At my request, Dr. Wetherill prepared the post-mortem color scale found on the inside of the back cover and which shows the approximate percentage of hæmoglobin in the blood twenty-four hours after death.¹ The method of using the scale is quite simple. A drop of blood taken from one of the large veins, such as an

¹ The writer is at present engaged upon the preparation of a scale designed to show the changes of color in human blood twenty-four hours after death resulting from the more common poisons. He will be thankful to receive from the reader reproductions showing any such alterations except those induced by hydrocyanic acid and illuminating gas.

innominate, or from the right side of the heart, is placed upon or absorbed by a small piece of filter-paper or white blotting-paper and held in the centre of the disk, so as to compare the color with the scale in daylight at an angle (by preference) of 45 degrees. As soon as the colors are nearly matched, the paper is run out along the black dividing line, thus affording an opportunity of forming an intermediary judgment, which can be approximately determined to within 2.5 per cent. The black lines separating the colors and the outer white paper best bring out by contrast the various shades of color.

While printing this scale, the opportunity was afforded of supplying a copy of Dr. Wetherill's moisture scale, which is naturally of more use clinically than at the postmortem. The change in color depends upon the action of moisture on pieces of filter-paper soaked in a four-tenths of one per cent. saturated solution of chlorid of cobalt. To measure the moisture in a room or upon the surface of a dead or living body, the disks are dried over a burning match or in a desiccator and placed under celluloid or glass to exclude the atmospheric conditions, if the latter procedures be desired. After ten minutes a comparison is made with the scale and the percentage determined. In uræmia and diabetes the skin is dryer, as well as upon the side affected by a recent paralytic stroke. The scale may be used for determining the amount of moisture in the air at the place where the body is found or the autopsy performed.

The specific gravity of the blood is best obtained with the specific-gravity bottle, there being no difficulty here, as during life, in securing the desired quantity of blood. Hammerschlag's method of mixing benzol and chloroform of a known specific gravity until a drop of blood remains stationary may also be employed. The specific gravity of the blood in health is normally from 1.057 to 1.059, and varies directly as the amount of the hæmoglobin present. In leukæmia the specific gravity is high, while after drowning it differs according as the person has been drowned in salt or fresh water. The cryoscopic index is -0.57° C., showing but slight variation during health.¹ For its use in drowning, see Chapter XXVIII.

There may be observed at the time of the postmortem all degrees of coagulation of the blood, from an almost absolutely fluid condition,

¹ CATTELL, *International Clinics*, April, 1904. Revenstorff (*Vjhrschr. f. gericht. Med.*, vol. xxii, 1903) thus determines the length of time which has elapsed since death.

as in poisoning by hydrocyanic acid, to a hard and dense fibrinous clot,—the so-called heart polyp,—which contains almost no red blood-corpuscles. The firm, yellowish to olive-tinted, semitransparent “chicken-fat” clots, seen so frequently in pneumonia, adhere to the walls of the heart, and indicate slow death, with gradual paralysis of the heart’s action. When all the coagula are rich in fibrin, some acute inflammatory process has caused an increase in the leucocytes and blood-plaques, the generators of fibrin. In the left auricle they at times assume polypoid or spherical shapes, and may even become attached to its wall and undergo organization. The ordinary post-mortem coagulum is the red clot, the so-called currant-jelly clot (cruror), which is not attached to the endocardium, though it may adhere to the muscular interstices of the heart. The situation of the body after death may sometimes be tentatively determined by the formation of the different kinds of clot. Thus, should the frontal part of the longitudinal sinus contain a mixed clot, and the occipital a cruror, the inference would be that the body had remained on its back after death. A thrombus is not usually removed by washing, while coagula are. *Hyperinosis*, or increased capability for fibrin formation in the blood, is at times met with in certain anæmic affections and infectious diseases. *Hypinosis*, or decreased capability for fibrin formation, occurs in leukæmia, hydræmia, certain of the acute exanthemata, hemorrhagic diathesis, obstruction of the biliary tract, and in cases of suffocation or intoxication with certain poisons, as carbonic acid. Methæmoglobin, found in cases of poisoning by chlorates, nitrites, toadstools, etc., gives a brownish tinge to the blood. In putrefaction, if the blood be left standing, the clear serum separates and leaves a yellowish-green sediment. Under the microscope shadows of red cells are seen. The blood is normally alkaline, but at the end in Asiatic cholera it may be markedly acid or its alkalinity much diminished. We have already seen that the organs quickly become acid after death, but their alkalinity returns as decomposition sets in.

The following diseases may be diagnosed by their agglutinative reaction: Typhoid fever, paratyphoid, dysentery, Malta fever, cholera, plague(?), tetanus (in the horse, but not in man), psittacosis, tuberculosis(?), and pneumonia. The reaction with the *Proteus* may be used to distinguish between invasion after death and infection during life. Auto-agglutination of the erythrocytes has been observed in Hanot’s hypertrophic cirrhosis. Flexner believes that the liability of

the red corpuscles to become agglutinated in the blood-serum is the cause of thrombi which so frequently occur in certain of the infectious fevers, as typhoid.

Pathologic Conditions.—(a) *Plethora Vera*.—A condition in which all the elements of the blood are proportionately increased. (b) *Plethora Scrota*.—A marked increase in the watery and salty constituents, appearing after transfusion, increased ingestion of liquid, acute cardiac failure, etc. (c) *Hydræmia*.—Abnormal increase in the watery portion of the blood; seen in cardiac, pulmonary, hepatic, and renal diseases. (d) *Anhydræmia*.—Here there is a concentration of the cellular elements of the blood, due to an abstraction of its watery constituents, the blood becoming thick and even tarry, as in cholera. It is seen, at times, after tapping, as for ascites, and in starvation. (e) *Anæmia*.—A diminution in the actual amount of the blood (*oligæmia*) or in one or more of its essential constituents, as hæmoglobin and albumin. When the *erythrocytes* (red blood-cells) are diminished relatively or absolutely, there is *oligocythæmia*. Anæmia may be *local*, as in Raynaud's disease and erythromelalgia, or *general*, as in the rupture of an extra-uterine pregnancy. (f) *Primary, Essential, Cytogenic, or Idiopathic Anæmia*.—An anæmia, the cause of which is not definitely known, but usually attributed to the blood-making organs, and characterized by a *disproportionate* reduction in the elements of the blood. (g) *Secondary, Simple, or Symptomatic Anæmia*.—An anæmia due to a definite cause, as from the parasites *Anchylostomum duodenale*, *Anguillula stercoralis*, *Bothriocephalus latus*, *Ascaris lumbricoides*, *Tricocephalus dispar*, and *Trichinæ*, or from infectious fevers, as diphtheria, toxic agents, as lead and arsenic, etc., and characterized by a *proportionate* reduction of the erythrocytes. (h) *Polycythæmia rubra* is an absolute increase in the red cells; seen in cured cases of anæmia,—usually associated with engorged organs,—in new-born children, and in persons living at high altitudes or suffering from chronic phosphorus and carbon monoxid poisoning. (i) *Poikilocytosis*.—Bizarre and irregular configurations of the red corpuscles (crenated, reniform, and pyriform are most common); seen especially in pernicious anæmia. (j) *Macrocytosis* and *Microcytosis*.—The red cells are respectively increased and diminished in size. (k) *Crenation*.—The hæmoglobin is extracted from the corpuscles and their subsequent contraction into irregular shapes with serrated edges takes

place. (*l*) *Laking*.—The solution of the hæmoglobin in the plasma. (*m*) *Hæmolysis*.—Destruction of red corpuscles; occurs after burns, certain poisons, infectious fevers, etc. (*n*) *Cytolysis*.—The dissolving of cells by poisons. (*o*) *Leucocytosis*.—Temporary increase in the number of polymorphonuclear neutrophilic elements; marked in the new-born, in pregnant and parturient women; usual at postmortem; appears with many infections, suppuration, malignant disease, and hemorrhage. A leucocytosis of 15,000 per cubic millimetre nearly always shows that suppuration is going on in some part of the body. (*p*) *Leucopenia*.—A diminution in the number of the white blood-cells; this condition is to be seen most characteristically in typhoid fever, starvation, cancer, influenza, measles, tuberculosis, and Hodgkin's disease; normal in pregnancy, obesity, alcoholism, nephritis, icterus, typhus, malaria, and cardiac and pancreatic diseases. (*q*) *Lymphocytosis*.—An absolute and relative increase of lymphocytes; commonly associated with hereditary syphilis, scurvy, chlorosis, pernicious anæmia, Graves's disease, splenic tumors, pertussis, pneumonia, and lymphatic leukæmia. (*r*) *Myelocytosis*.—An increase in the number of myelocytes is always pathologic, and is seen in the greatest degree in myelogenous leukæmia, pernicious anæmia, acute infections, as typhoid, mania, Graves's disease, syphilis, tuberculosis, osteomalacia, etc. It may occur in all diseases with marked anæmia. (*s*) *Eosinophilia*.—An increase in the number of eosinophiles; occurs in asthma, fibrinous bronchitis, acute and chronic skin diseases, especially in trichinosis, amœbiasis, and anchylostomiasis; also after acute infections and with malignant tumors (moderate increase). It is a compensatory reaction with diseases of the spleen. Eosinophiles are decreased after castration, and in the febrile stages of pneumonia, grippe, typhoid, diphtheria, and sepsis. The bone-marrow should always be examined, as it is from this source that the eosinophiles arise. (*t*) *Lipæmia*.—Fat globules in the blood, giving it a milky appearance; seen in leukæmia, diabetes, alcoholism, phthisis, etc. (*u*) *Uræmia*.—The presence in the blood of an excess of chemical compounds, as urea, which should be eliminated by the kidneys or other excretory organs. There may have been during life an increase in blood-plaques, but they are most difficult of demonstration even shortly after death. In uræmia, besides the macroscopic lesions of œdema of the brain, a condition of chromatolysis of the cells in the central nervous system may be demonstrated. The

destructive changes are especially found in the motor cells, and may be followed later on by degeneration of the motor tracts.¹

Blood-Stains.—When any suspicion of violence arises, look carefully for blood-stains. If in doubt, treat all suspicious findings as if they were such, unless some special reason exists for not doing so. *Such stains should be most critically examined in the privacy of the laboratory* before expressing an opinion as to whether or not they are consistent with human blood. Try to ascertain: (1) Their connection with the body under examination or with the person suspected of the crime. (2) Their extent, using great care in determining the nature of the substance stained. (3) Conditions,—whether fluid or clotted, wet or dry, cracked or caked, etc. (4) How made,—whether by smear, by splash, by flow, by absorption, as in cloths, etc. (5) Connect, if possible, the amount, shape, and condition of the stains with their probable source, and note any peculiarities. When practicable, preserve parts or all of stains. It is often well to saw off an entire step or remove a panel of a door in order to produce the same as evidence in court. In the present state of our knowledge it is not practicable to state from what part of the body the blood came and the age of the stain, though the more recent the blood the more soluble it is said to be.

Two illustrations from my case-book will show the importance of this line of research. A man committed rape on a seven-year-old child and murdered her. Blood was seen on the fly of his trousers by his room-mate. In order to divert suspicion from himself, the murderer accused his room-mate of the crime. The trousers of both men were sent to me for examination. In the pair of pants belonging to the perpetrator of the crime the lining of the fly had been cut away and neatly sewed, but there remained a few telltale threads containing blood, which was found to possess the characteristics of human blood. On the trousers of the other man was found a red substance, which examination showed to be lumberman's red chalk, the crime having been perpetrated in the backwoods. In the second case blood splashes on a white curtain were stated by a murderer to be red paint which one of his children had put there with a paint-brush.

The presence or absence of blood is determined by (1) physical examination; (2) chemic tests; (3) spectroscopic examination; (4) microscopic examination; and (5) the hæmolytic serum or biologic test.

¹ EDITORIAL, *Jr. Amer. Med. Assoc.*, April 23, 1904.

The diameter of a red corpuscle may be placed at $\frac{1}{3200}$ of an inch; that of a leucocyte at $\frac{1}{2400}$ of an inch. Mammals (with the exception of the camel, alpaca, and allied species) and cyclostoma among fishes, are found with circular red blood-cells. For the first time on record Melvin Dresbach,¹ of the Ohio State University, was able systematically to study the blood of a healthy mulatto student, from whom about ninety per cent. of the red cells taken were elliptic in outline, averaging 10.3 microns in length and 4.1 microns in width. The cellular constituents were normal and no nucleated blood-cells were found. Ehrlich and Ewing consider the shape of the cells in this case to be due to a congenital condition.

The agglutinative reaction or antiserum test for the diagnosis of human blood has been applied in a number of recent trials. It would seem to afford positive proof of the special source of the blood under examination, though Robin secured the reaction from the blood of a monkey and Linossier, Nuttall, Dieudonné, and others have demonstrated the reaction in pus, nasal mucus, saliva, urine, pleural exudate, and sweat derived from the human body. Uhlenhuth² was put to a severe test by the German Department of Justice. Various objects stained with the blood of man and of different animals were sent to him, the nature of the blood being known to the Department of Justice but not to him. When the blood was furnished in sufficient quantities, his results in each case were positive.³ One method of preparing the antiserum and applying the test is as follows: Ten cubic centimetres of defibrinated human blood, as that freshly obtained from the human placenta, are injected into the peritoneal cavity of a rabbit at intervals of six days, and after five such injections an effective serum should be obtained. Butza⁴ prepares the animal by injecting from ten to twenty cubic centimetres of a centrifugated human pleural exudate intraperitoneally into a rabbit for five or six successive days. The animal need not be killed, but bled again and again, as in the preparation of the diphtheritic antitoxin. The blood should not be brought

¹ *Science*, March 18, 1904; March 24, 1905.

² *Deutsche med. Wchnschr.*, September 11 and 18, 1902.

³ For an account of trial cases see PATEK and BENNETT, *Amer. Med.*, September 6, 1902, p. 374; WHITTIER, *Amer. Med.*, January 18, 1902; FERRAR, *Bolletino della reale Accad. medica di Genova*, 1901, no. 7; OGIER and STICKIS, *Soc. de méd. légale*, Paris, May, 1901; and Bechtel case tried at Allentown, Pa., in 1904.

⁴ *Spitalul.*, 1902, vol. xxiii, p. 377.

to too high a point of efficiency, as it will then require too high a dilution for practical purposes. The blood to be tested is diluted with water, one to one hundred, and filtered. Of this clear, slightly red solution two cubic centimetres are placed in a small tube and mixed with an equal quantity of 1.6 per cent. salt solution; six to eight drops of the serum of the rabbit are then added to each tube to be tested, but all will remain perfectly clear except the tube containing human blood. The reaction is extremely delicate and can be obtained with very slight traces even of old dried blood. The clouding should occur within thirty minutes in the proportion of 1 to 30, and a precipitate within two hours; other samples of blood remain clear after six hours. The test should always be repeated. Bordet,¹ Deutsch,² Wassermann and Schütze,³ and Dieudonné⁴ describe practically the same method as Uhlenhuth, and have obtained similar results. Bordet and Deutsch each claim to have been the first to use this method.

Corin⁵ believes that the active principle of the serum in the biologic differential diagnosis of the blood is paraglobulin, for not only may blood-serum be used for the purpose, but also transudates containing globulin. The paraglobulin in an ascitic fluid was precipitated by magnesium sulphate, dried, and injected into animals in an aqueous solution. In like manner the paraglobulin can be precipitated from the blood of the animal experimented upon and preserved in pulverized form. This powder when wanted for use is dissolved in water and employed in testing the blood under examination. Biondi⁶ finds that the reaction occurs with the semen, so that human and animal spermatic fluid can be differentiated. Meyer⁷ has even shown that Egyptian mummies give this reaction. This test might, for example, have been used in the boiled and alkali-eaten bones found in the vat in the Luetgert case of Chicago. Evans and Gehrmann⁸ have suggested this test for the purpose of distinguishing horse meat when used in sausages. The writer, in the *International Medical Magazine*, March, 1897, and earlier to his classes at the University of Pennsyl-

¹ *Annales de l'Institut Pasteur*, 1899, pp. 225 and 273.

² *Orvosik Lapja*, 1901, no. 11.

³ *Berl. klin. Wchnschr.*, 1901, vol. xxxviii, no. 7, p. 187.

⁴ *Münch. med. Wchnschr.*, 1901, vol. xlviii, no. 14.

⁵ *Vrhljschr. f. gerichtl. Med.*, 1902, vol. xxiii, p. 61.

⁶ *Vrhljschr. f. gerichtl. Med., Suppl.-Heft*, 1902, vol. xxiii, p. 1.

⁷ *Münch. med. Wchnschr.*, April 12, 1904, p. 663.

⁸ *Amer. Med.*, vol. iii, p. 1062.

vania, suggested the possibility of the Widal test being used in certain cases for the identification of human blood. It may be noted that the paratyphoid reaction might in certain instances assist in distinguishing animal blood.¹ Leblanc² and Bonnel have endeavored to identify human blood by the form of crystallization assumed by the hæmoglobin, but this method, even should it prove to be an accurate one, requires a considerable amount of blood.

Abnormal Constituents of the Blood.—(a) Tumor cells, as in neoplasms growing into veins, portions of the valves of the heart and of thrombi, fat, as after a fracture, etc. (b) Blackish pigment particles, melanæmia, as in malaria, melanosarcoma, and Addison's disease, coal dust, often found in the spleen, etc. (c) Hæmatoidin crystals. (d) Bilirubin crystals in the shape of needles are sometimes found microscopically in a clot that has been well washed in water. They occur in icterus neonatorum, pernicious anæmia, acute yellow atrophy, pyæmia, etc., but not in ordinary icterus. (e) Bile. Gmelin's test for bile may be applied direct to the serum of the blood, the bile sometimes imparting to the serum an orange-red tint which may be recognized by the naked eye. (f) Glycogen. The glycolytic reaction in the blood, first described by Gabritschewski in 1891, is determined by placing for one minute a blood smear, face down, upon a solution of iodine, iodide of potassium, and gum arabic. If the glycolytic reaction is positive, small or large brownish granules are observed under the high powers of the microscope in the polynuclear leucocytes, or the cells themselves may even assume a diffuse brownish color. Some brownish extracellular masses may also be found. The reaction is found in suppuration, bacterial infection, uræmia, diabetic coma, etc. Locke and Gulland³ have demonstrated that the reaction is always present in an acute attack of appendicitis, and may even afford valuable information concerning the severity of the disease. Serous pleuritis and simple obstruction of the bowel do not give the reaction. (g) Gas bubbles may be due to putrefaction, as air-producing bacteria develop very rapidly after death. In fresh blood air

¹ The Marx-Ehrenrooth test will be found in *Münch. med. Wchnschr.*, 1904, vol. li, no. 16. Deutsch's book is entitled *Impfstoffe und Sera*, Leipzig, 1903. Nutta's article (*Jr. of Hygiene*, 1901, vol. i no. 3) is the best of the early publications in English. Uhlenhuth's latest method of differentiating blood from closely related animals is found in the *Deutsche med. Wchnschr.*, 1905, vol. xxxi, no. 42.

² *Thèse*, Paris, 1903.

³ *Brit. Med. Jr.*, April 16, 1904, p. 880.

bubbles, particularly when in the right heart and surrounded by a clot, are due to the entrance of air into the veins during life. (h) Charcot-Leyden crystals, seen in leukæmia. (i) Lower organisms, as the *Spirochæta* of relapsing fever (not always found after death), the organisms of anthrax, influenza, tetanus, tuberculosis, typhoid fever, paratyphoid, Malta fever, glanders, etc., and micro-, strepto-, staphylo-, and diplococci, such as the *Gonococci* and *Pneumococci*, *Plasmodia*, *Filaria sanguinis hominis*, *Distoma*, found especially in the portal and splenic veins, *Trypanosoma*, and many other parasites. Many names have been given to those conditions produced by organisms and their products acting upon the living tissues of the body: as, septicæmia, where there are pyogenic micro-organisms in the blood and tissues, without areas of suppuration; pyæmia, where metastatic abscesses are found in the tissues and organs of the body; and sapræmia, where the symptom-complex is produced by the presence in the blood and tissues of the vital chemic products known as toxins. These toxins may be formed by the metabolism of pyogenic or saprophytic micro-organisms. (j) Various vegetable and mineral poisons, such as carbon monoxid, hydrocyanic acid, nitrobenzol, etc.

BLOOD-DISEASES.—*Anæmia, Progressive Pernicious*.—An idiopathic, chronic anæmia characterized by definite blood-changes, by pallor of the mucous membranes, by a lemon-yellow coloration of the skin, and by progressively developing weakness without corresponding emaciation. It is most common in adults of the male sex, but may occur in children. Rare cases are seen during pregnancy and parturition. It is associated with an extreme anæmia, poor teeth, unclean mouth, overwork, and intestinal parasites, especially the *Bothriocephalus latus* and *Anchylostoma duodenale*. The chief changes seen in the blood during life, but which cannot always be demonstrated *post mortem*, are: (1) Marked reduction in the number of red corpuscles (to one million or less per cubic millimetre). (2) Alteration in their shape,—poikilocytosis. (3) Alteration in size,—microcytes, macrocytes, megalocytes. (4) Nucleated reds.—normoblasts, megaloblasts. (5) Increase of neutrophilic whites. (6) Hæmoglobin markedly decreased, but color-index usually high and blood of a raspberry-red color. (7) Blood-plates absent or scanty. At the postmortem the skin is, as a rule, lemon-yellow in color. The skin and the serous membranes commonly reveal hemorrhages, which may, however, be present only in the retina. Certain brown discolorations are often

found, especially on the abdomen and buttocks. The subcutaneous fat is well preserved and of a light-yellow color. The muscles resemble horse-flesh and are often degenerated. The heart is usually large, flabby, empty, intensely fatty, and tawny-brown in color. The other organs exhibit fatty changes. The stomach may be normal or the disease may be associated with chronic gastritis, gastric carcinoma, or atrophy of the gastric tubules. Iron is deposited in excess in the lobules of the liver, especially in the outer and middle zones. The spleen and hæmolymp glands show a marked accumulation of leucocytes and excess of iron pigment. The spinal cord may show extensive posterior sclerosis with hemorrhagic foci, due to the action of the toxins and nerve-fibre degeneration. The lesions are usually most marked in the part of the tract farthest from the trophic centre. Changes in the ganglion-cells of the sympathetic system have been reported. The marrow of the long bones is reddish, resembling that seen in the infant. In pernicious anæmia there is incomplete formation of serum. It is stated that the clot of pernicious anæmia and that of anæmia secondary to cancer may be distinguished by the contraction of the cancer clot and the resulting expression of the serum.

Chlorosis.—Chlorosis is a primary anæmia which occurs usually in girls between fifteen and twenty years of age, and is characterized by a marked diminution in the percentage of hæmoglobin, by alterations in the number, shape, and size of the red blood-corpuscles in severe cases, and sometimes by hypoplasia of the circulatory and generative organs. The white blood-cells rarely show much variation. Cases of simple chlorosis rarely come to autopsy. Subcutaneous fat is usually well preserved or even increased in amount. The skin is pale and of a greenish hue, and other evidences of anæmia may appear. Areas of pigmentation, particularly about the joints, occasionally occur. The internal organs will be found pale and flabby. The heart, large blood-vessels, and generative organs may show insufficient development. (Virchow.) The heart and large veins are often filled with a greenish clot. Thrombi, at times multiple, are common, especially in the femoral vein and the longitudinal sinus. Pulmonary embolism has been observed.

Leucocythæmia (or *Leukæmia*).—A primary anæmia characterized by a great increase in the number of the white corpuscles, by an alteration in the relative proportions of the various white corpuscles the one to the other, and by marked structural changes in the lymphatic

glands, spleen, and bone marrow. It may be (*a*) splenic, (*b*) medullary, (*c*) lymphatic, or (*d*) mixed. As a rule, the body is apparently well preserved, but in some cases emaciation may be extreme, while in others the amount of adipose tissue may be increased and of a peculiar punctate appearance, owing to the presence of petechial hemorrhages. The skin is waxy and has a peculiar lemon-yellow color. The mucous membranes are blanched and œdema is often present. The blood is pale, even grayish, in color, the hæmoglobin being often reduced one-half or more. It rarely clots with any degree of rapidity, and in the clot red cells settle, leaving a white film above. At the postmortem the heart and large veins may be found distended with large, greenish, pus-like blood clots. In splenic leukæmia microscopic examination of the blood shows that the increased white corpuscles are largely myelocytes, while in the medullary form they are lymphocytes. The white corpuscles are enormously and permanently increased, so that one white to twenty red, or even one to one, is not uncommonly found. The organs in general are pale; the heart is flabby and frequently fatty in appearance. The liver, spleen, and lymphatic glands are usually markedly hypertrophied, while the thyroid may be normal or but slightly enlarged. The thymus gland has in several instances been found enlarged. Lymphoid masses are seen in the lungs. The Peyer patches are often increased in size.

(*a*) In splenic leukæmia, which is a comparatively rare form of the disease, the spleen is markedly enlarged, somewhat firm in consistency, and of a reddish-brown color. The capsule is thickened and the whole organ is bound down by adhesions. The Malpighian bodies are frequently obliterated, their place often being taken by grayish-white, circumscribed tumors throughout the organ. The hyperæmia in some cases is so excessive that rupture of the spleen is said to occur from this cause. The vessels at the hilum are enlarged. Dropsy from pressure on the abdominal viscera may result. As in other forms of leukæmia, the bone marrow may show decided changes, especially in the long bones. Instead of fatty tissue there may be splenization, or the marrow may resemble the consistency of the matter which forms the core of an abscess. (*b*) Medullary leukæmia very seldom occurs as an inflammatory process. Where the marrow changes are excessive, the flat bones—as, *e.g.*, the sternum—undergo alterations similar to those occurring in the long bones. There is a hyperplasia of the red marrow; this may resemble pus or be of a dark-brown color.

There may be localized swelling of the bone. (*c*) In lymphatic leucæmia the lymphatic glands throughout the body, especially those of the neck, the axillary and inguinal regions, also the glands of the mesentery and the intestines, are swollen, pale in color, firm to the touch, but seldom suppurate or show any tendency to run together. The spleen, liver, and lymphatic glands, as the tonsils, lymph-follicles of the tongue, pharynx, and mouth, often show marked thickening of their capsules. On section the glands are somewhat resistant, and often exhibit nodule-like bodies, which are firm in consistence and largely composed of proliferating leucocytes and connective tissue. The liver as well as the spleen is enlarged and may exhibit marked structural changes. This form may be associated with, or most difficult to differentiate from, lymphosarcoma.

Von Jaksch's Anæmia.—This is a primary anæmia of infancy, closely resembling leucæmia, but without the visceral lesions. The red cells are diminished, though many of these are nucleated. The spleen, liver, and lymph-nodes are enlarged, and the number of leucocytes is increased.

Osler's Disease (Chronic Cyanosis).—A chronic disease of people usually past middle life and not associated with dyspnœa, kidney, lung, or heart disease, but characterized by marked blueness of the skin. There is a marked polycythæmia, the red cells varying from 10,000,000 to 12,000,000 per cubic millimetre and the hæmoglobin being increased as much as fifty per cent. above the normal. At the postmortem the heart and spleen are found enlarged and the internal organs markedly congested. At times small hemorrhages are noted.

Hodgkin's Disease (Pseudoleucæmia; General Lymphadenoma).—A disease characterized by a progressive hyperplasia of the lymph-glands, by anæmia, and sometimes by secondary lymphoid growths in the liver, spleen, and other organs, but with no severe leucocytosis. The lymphatic glands most frequently enlarged are those in the cervical, axillary, and inguinal regions, though the mediastinal, thoracic, and abdominal glands, especially the retroperitoneal, are often affected. In the early stages the glands are moderately enlarged, soft and elastic, isolated, and freely movable. Later they increase in size and tend to run together, become stony hard, and are surrounded by a dense capsule. The capsule may perforate, and the growth invade the surrounding structures. On section the tumor appears grayish white; it is smooth and the interior may be firm and dry or soft and juicy. Sup-

puration sometimes occurs when the growth reaches the skin. Emaciation at the time of death may be extreme. The spleen and liver are usually somewhat enlarged, but rarely greatly so, and on section show lymphoid tumors varying in size from that of a pea to a walnut. The Peyer patches frequently show enlargement. Pleural effusions are not uncommon. The skin may be the seat of adenoid growths. The glandular enlargements may be due to simple inflammatory hyperplasia, lymphadenoma, or lymphosarcoma. The bone marrow may be converted into a rich lymphoid tissue. The blood-changes are those of a distinct anæmia of the simple type. The red cells are less numerous and are slightly smaller; the hæmoglobin is always diminished; the leucocytes are normal or decreased in number. I have made the clinical diagnosis in the case of a Newfoundland dog, confirming the diagnosis by microscopic study of the tissues after death.

Hæmophilia.—An hereditary constitutional disease characterized by a marked tendency to excessive hemorrhage from very slight causes. It is transmitted through the females of a family to the males. Little regarding its morbid anatomy is definitely known, and therefore any opportunity for the study of a case *post mortem* should be taken advantage of. The vessel-walls are unusually thin, brittle, narrow in calibre, and do not readily contract. In some cases the blood itself presents marked alterations. Owing to the ease with which the joints are injured, hemorrhages are often found about the capsules of joints, with inflammation of the synovial membranes. In a few cases increase in the number of red cells and diminution of white cells and blood-plates have been noted. Geier¹ finds the cytoglobin, which is produced by the destruction of the red blood-cells, to be markedly increased in hæmophilia.

Purpura.—This is characterized by extravasations of blood into and from the skin, by great debility, evidences of anæmia, and often multiple arthritis. Infectious purpura is seen in pyæmia, septicæmia, malignant endocarditis, typhus fever, etc. The forms are (*a*) purpura simplex, (*b*) purpura hæmorrhagica, (*c*) purpura rheumatica, (*d*) iodic purpura, (*e*) Hænoch's purpura, (*f*) neurotic purpura, (*g*) mechanical purpura, (*h*) toxic purpura (seen in snake poisoning, after the use of certain medicines, etc.), (*i*) cachectic purpura. The blood clots slowly and imperfectly; leucocytosis may or may not be present;

¹ *Med. Obozrenije*, Mosk., 1904, vol. lxi, no. 1.

the blood-plates may be scanty; and the red cells are often reduced in number. There is a large percentage of lymphocytes and an increase in the eosinophiles. The skin is dry and pale, except for the blotches of extravasated blood, which vary from one to four millimetres in diameter, are bright red in color, later become dark, and finally remain as brown stains. The hollow viscera and serous cavities may contain considerable quantities of blood-stained serum. The serous membranes and solid organs may also reveal hemorrhages varying in size from a pin's head to the palm of the hand. Congestion and œdema of the lungs are frequently present. There is generally an acute diffuse nephritis. Ulcerations of the intestines with enlargement of the solitary and agminated glands are sometimes found. In one of my cases, in which the purpuric blotches were unusually large and widely distributed over the body, a husband was accused of beating his wife and thus causing her death.

Scurvy.—Scurvy is a constitutional disorder characterized by anæmia, great debility, spongy gums, and tendency to hemorrhage. This disease is by no means so frequent as formerly, owing to better hygienic conditions and to the proper feeding of those in ships, prisons, work-houses, etc. The blood is dark and fluid; there is a decrease in the number of the red cells, many of which are pale and distorted; microcytes are present; there is no leucocytosis. After death decomposition sets in rapidly. There is very little wasting of the subcutaneous fat or of the muscles. The hemorrhagic patches observed in the skin during life are often obscured by post-mortem lividity; œdema is common. The subcutaneous tissues, especially those of the lower extremities, contain a blood-stained fluid, with here and there discolored patches, some black and others of a pale color. About the back of the thigh and knee the muscles and tendons may be embedded in a thick, firm clot, and themselves contain numerous hemorrhagic foci. Occasional hemorrhages occur within the joints, or into any of the serous and mucous membranes or internal organs, especially the kidney and bladder. The gums are swollen and may present fungous appearances; they are sometimes ulcerated, and the teeth may have fallen out. Rarely there may be ulcers in the intestines. Hemorrhagic infarcts are at times seen in the lungs and spleen, the latter organ being enlarged and soft, while fatty changes are quite constant in the liver, kidneys, and heart.

Scurvy, Infantile (Barlow's Disease).—Usually associated with

improper food, such as too much malted or condensed milk. Cases, however, have been reported in breast-fed children. The most important lesions are increased vascularity and extravasation of blood between the periosteum and the bone and into the cavity of the long bones, especially those of the lower limbs, producing tumor-like swellings. Epiphyseal fractures are not uncommon. In fact, in the majority of cases there are bone changes analogous to those of rickets, and the disease often develops in a rickety child.¹ Deep-seated extravasations may give rise to muscular swellings and in some cases to extravasations in the joints. Smaller extravasations are observed in the pleura, lungs, spleen, intestines, and kidneys. The gums are spongy, sodden, distended with serum, and sometimes covered with blood. One of the most characteristic lesions is extravasation of blood into the orbital cavity, causing displacement of the eyeball downward and forward.

Diabetes Insipidus.—A constitutional condition characterized by continued secretion of large amounts of pale urine of low specific gravity, containing neither albumin nor sugar, attended with excessive thirst and at times with emaciation; usually the patient looks well nourished. It occurs most often in young males and is usually hereditary. The urinary system may show merely signs of the passage of an abnormal amount of liquid,—enlarged and congested kidneys, dilated pelves, dilated ureters, and an hypertrophied bladder.

Gout.—A constitutional disease characterized by excessive formation of uric acid and the gradual deposition of its salts, especially sodium urate, in and around the joints of the extremities, producing an acute arthritis. Anatomic changes are found most frequently in the great toe, though the disease shows a marked tendency to involve the smaller joints, both of the feet and the hands. In acute stages there are notable hyperæmia and round-celled infiltration and diffusion into the joint and swelling of the ligaments. Macroscopically the joint is swollen, glazed, tense to the touch, and of a purplish color. In the chronic form the ligaments and fibrocartilages of the joint become infiltrated with chalky deposits (tophi). These consist of sodium urate in the form of crystalline needles or rhombs, which are quickly dissolved by hydrochloric acid, but whetstone-shaped crystals of uric acid make their appearance. Necrosis in the cartilage always

¹ *Lancet*, May 3, 1902, p. 1246.

precedes the formation of tophi (Ebstein). These deposits may be slight or may lead to enormous distortion of the joint. In some cases the skin may ulcerate and the tophi be extruded. The deposits may be found in the cartilages of the ear, the nose, the eyelids, and occasionally the larynx. In some cases the synovial fluid contains crystals. In chronic cases the joint becomes immovable, due to the exostosis and excess of deposits. The kidneys usually show chronic interstitial inflammation, with deposits of urates in the form of small flakes or stripes, chiefly in the pyramids. Arteriosclerosis, with hypertrophy of the left ventricle, is very common. Cutaneous affections, such as eczema, are not infrequent. The blood contains an excess of uric acid.

Varieties of Hemorrhage. — The following terms are applied to hemorrhages from various parts of the body: Epistaxis, hemorrhage from the nose; hæmoptysis, pulmonary hemorrhage; hæmatemesis, or gastrorrhagia, hemorrhage from the stomach; enterorrhagia, hemorrhage from the intestine; metrorrhagia, uterine hemorrhage not occurring during the regular menses; menorrhagia, excessive menstrual flow; post-partum, hemorrhage from uterus after delivery; complementary, hemorrhage occurring in some place other than that in which the original bleeding occurred; consecutive or secondary hemorrhage; extrameningeal, a hemorrhage external to the cerebrospinal meninges; hæmorrhage per diapedesis; hæmorrhage per rhexin (diabrosin); hæmatometra, collection of blood in the uterus; hæmothorax, collection of blood in the thorax; hæmaturia, hemorrhage from the urinary organs; hæmathidrosis, hemorrhage from the sweat-glands; hæmatocèle, a collection of blood in the tunica vaginalis testis; hæmopericardium, a collection of blood in the pericardial sac; purpura, extravasation of blood into the skin; hæmorrhagic blebs, blood blisters; hæmorrhagic infarct, a blood clot obstructing a blood-vessel; hæmatoma, a circumscribed collection of escaped blood; extravasation, the escape of blood (extravasat) from the vascular system into the tissues or upon the surface; it is either arterial, venous, capillary, or cardiac; petechiæ or ecchymoses, small, discrete, punctiform collections of blood, when larger and not so sharply defined as suggillations and hæmorrhagic suffusions.

Causes of Hemorrhages.—(a) Traumatism. (b) Acute inflammation. (c) Passive congestion. (d) Corrosive poisons. (e) Malignant growths. (f) Diseases of the vessels. (g) Rupture of an

aneurism. (*h*) Cachectic disease. (*i*) Dyscrasias. (*j*) Nervous disturbances. (*k*) Vicarious menstruation. (*l*) Toxins.

Many Coroner's physicians give hemorrhage from the umbilical cord as a cause of death in new-born children. Although this fatality does occur, it is extremely rare, some obstetricians treating without tying the cord hundreds of cases without hemorrhage; nor is the condition seen in the lower animals. It is facilitated by cutting the cord too close to the abdomen, by forced artificial respiration, and by the presence of hæmophilia. It may come on several days after birth, and at the postmortem the liver appear especially blanched.

ANGINA PECTORIS.—A symptomatic affection commonly associated with more or less myocardial degeneration and occlusion of the coronary arteries from atheroma and thrombosis. At the autopsy the heart is often enlarged and the pulmonary artery and the cavities of the heart are filled with post-mortem clots. While aortic and mitral thickenings are usually present, I have examined cases where they were absent. The coronary arteries are "pipe-stem" in character, the anterior one being usually most markedly affected.

INFILTRATIONS AND DEGENERATIONS.—In fatty infiltration, or *obesitas cordis*, there is an increase of fat in those places where it is normally deposited, especially along the grooves of the larger blood-vessels. The deposits start from the outside and extend inward along the trabeculæ of connective tissue, while in fatty degeneration the changes originate from within. The heart may be embedded within such an enormous deposit of fat as to leave no muscle exposed to view. Fatty infiltration and degeneration occur most markedly in cases of poisoning, as by phosphorus, and the atrophy of the muscle may be very extensive. In such cases the heart is so soft that the finger can readily be pushed through its walls. Hyaline and amyloid degeneration may also occur. Hyaline degeneration affects tissues protected from the atmosphere and not accessible to the organisms of putrefaction (Flexner). Calcareous infiltration, fragmentation, and segmentation may be found. (See Myocarditis.) Calcium salts are not deposited on a living tissue under normal conditions, except as in formation of tears. Muscle-fibres in the heart are united by a cement substance, which, if destroyed, produces segmentation; when the fibres themselves are broken up we have fragmentation. Both conditions are usually found associated. A heart thus affected is easily torn apart by the fingers. Brown atrophy is common; the degenerated fibres are dark brown in

color, contain yellow-brown pigments within the muscle-cells, and the cavities are decreased in size. An atrophy of the left ventricle is sometimes seen in cases of extreme mitral stenosis. Senile atrophy always accompanies fibrosis. Fibrosis occurs most often in the aortic valves; the corpora Arantii are first affected, later the chordæ tendineæ become thickened, first at the valvular ends. Papillary muscles may also become markedly fibroid. (Osler.)

As a result of degeneration spontaneous rupture may occur, usually in the anterior wall of the left ventricle. This results from fatty infiltration, degeneration, gumma, or tuberculosis. It has been found associated with abscess, aneurism, ulceration, myomalacia, arteriosclerosis, and thrombosis. Fatty degeneration may end in rupture (spontaneous) of heart. Rupture may be due to trauma. Blows upon the chest may rupture the heart and also cause localized myocarditis, injury to mitral leaflets, or tear holes in valves where the chordæ tendineæ had been attached. This also occurs from extreme muscular action, gunshot wounds, etc.

Aneurism of the heart itself is usually due to myomalacia, with thickening and narrowing of coronary arteries and chronic myocarditis, often associated with valvulitis, syphilis, etc. It occurs usually in the left ventricle near the apex, or may be found in the intraventricular septum or posteriorly. The endocardium is usually opaque, the muscles are sclerotic, and layers of thrombi are found in the sac. The aneurism may or may not be lined with endothelial cells. Two aneurisms may be found existing in one heart. Now and again an aneurism appears on the valves of the heart, and is then spheroid and projects from the ventricular face of the semilunar valve. Literature is full of reported cases of cardiac and aortic aneurisms, there being several pages devoted to this subject in the *Index Catalogue of the Library of the Surgeon-General of the United States Army*.

MYOCARDITIS.—In the myocardium large hemorrhages may be met with, as a result of the rupture of small aneurisms of branches of the coronary arteries or as a hemorrhagic infarct. Anæmic infarct may also be due to a partially obstructing embolus or the formation of a thrombus or to disease of the coronary artery. It usually occurs in the left ventricle, at the apex, or in the septum. It is irregularly shaped, yellow-white in color, and sometimes turbid or parboiled in appearance. This is a common cause of sudden death. Tardieu's spots, or small hemorrhages beneath the endocardium and at times

extending into the muscle, are found especially after suffocation and in cases of rapid death from acute infectious fevers. Myocarditis usually is secondary to inflammation of the heart muscle. Parenchymatous myocarditis may be diffuse or limited. When the inflammatory process involves all of the musculature of the heart, as is frequent in the infectious diseases, it is characterized at first by the flabbiness and the turbid grayish-red color of the heart muscle. In the later stages there is much fatty degeneration. Segmentary parenchymatous myocarditis is marked by a cloudy appearance of the heart muscle, which is flabby and friable. (Orth.) Fibres may separate at the cement line. Transverse fragmentation of the fibres is the form which usually occurs during the death agony. Acute circumscribed interstitial myocarditis, or abscess of the heart, is usually a part of a general pyæmic disease, with infection through the coronary circulation. These metastatic abscesses occur in cases of puerperal sepsis, with osteomyelitis and other intensely septic diseases, but particularly in cases of malignant endocarditis. There may be only a few abscesses or the heart substance may be studded with innumerable suppurating points. In size the abscesses vary from the merest dots to cavities of the size of a cherry; they may perforate or form ulcers in the cardiac wall. Acute diffuse interstitial myocarditis occurs in various forms of infectious fevers. The affected heart muscle is soft and often distinctly friable; there may be spots of hemorrhagic infiltration, but, as a rule, the color is rather lighter than that of the normal organ. The cavities of the heart are frequently dilated, particularly the left ventricle. Chronic interstitial myocarditis or fibrous myocarditis may also be diffuse or localized, though the circumscribed form is the most common. The process is usually secondary, due to a primary disease of the coronary arteries, or to disturbances of the circulation therein, consequent perhaps upon old age, intemperance, gout, syphilis, and the like. This fibroid overgrowth is very commonly met with at the tips of the papillary muscles, on the trabeculæ, or in the substance of the cardiac muscle, and often at the apex of the left ventricle, where it may lead to such a degree of atrophy that a chronic localized aneurism of the heart may be formed by the constant pressure of the blood upon this thinned area. The heart is usually hypertrophied and the cavities dilated. The characteristic change is the formation of dense, grayish sclerotic areas, which appear either as more or less irregular spots or as streaks or lines running in the direction of the cardiac

fibres. The entire substance of the heart may be involved and thickening of the walls may result. (Stengel.) The condition of softening of the organ, or myomalacia cordis, has already been referred to. The degenerated tissue may form a scar, but more frequently leads to an aneurismal dilatation, which may subsequently rupture. Aneurisms of the sinus of Valsalva may form and rupture in unexpected places; I have seen, for example, an aneurism of an aortic sinus rupture into the right ventricle.

ENDOCARDITIS.—Disturbances of the circulation of the endocardium are rare, as this membrane possesses no blood-vessels of its own. A diffuse redness in this situation may, however, be the result of imbibition, and in the case of long-diseased valves, in which there are newly formed blood-vessels, reddish streaks and spots may be observed, which are due to small hemorrhages. Inflammation of the inner lining of the heart is frequently a secondary affection, dependent upon inflammatory disorders of other organs, such as suppurating wounds, purulent peritonitis, and pneumonia, or to rheumatism, gonorrhœa, chorea, tuberculosis, cancer, etc. The most common organisms found are the various forms of cocci. Sometimes, however, the endocarditis is the first local manifestation of an infection, the exciting agent of which has left no recognizable traces at the seat of its entrance into the body. In the fœtus endocarditis is usually situated in the right side of the heart, because the blood enters the organ on that side, and may be associated with lesions of the ductus Botalli. After birth the opposite condition prevails, the lesion being most commonly found on the left side. In the great majority of adult patients acute endocarditis affects the endocardium of the valves only,—the mitral, the aortic, and the pulmonary valve in order of frequency; but it is sometimes found in the endocardium of the cavities of the heart,—in the left ventricle, the left auricle, and the right ventricle. Various names have been applied to these conditions, as simple, verrucose, benign, ulcerative, septic, mycotic, rheumatic, syphilitic, diphtheritic, fibrous, or malignant endocarditis. Such cases differ much in their appearance, even when produced by the same organisms. Endocarditis starts on the endocardium as a minute, roughened area, which is red in color and slightly elevated. This can easily be scraped off, but, if the spot where it was found is carefully examined with a hand lens, a small ulcer will be seen. More and more fibrin is now deposited, and the corpuscular elements are caught in its meshes; the organisms multiply

and the clot undergoes a liquefaction necrosis, the process not stopping in the newly formed tissue, but often penetrating the valves or even the walls of the heart. Embolic occlusion of certain vessels and metastatic inflammations in other organs, especially the kidneys, spleen, brain, lungs, meninges, and skin, are not infrequently associated with endocarditis (Ziegler). Such hemorrhagic areas are to be sought for in the palpebral conjunctiva; their discovery therein during the external examination of the body has more than once led me to suspect ulcerative endocarditis, even when there was no clinical history of its existence. This previous observation is of special value when a bacteriologic examination of the heart is desired. These ulcerative areas of valves on healing are replaced by scar tissue, which, by contraction and by various degenerative changes, such as necrosis, fatty degeneration, and calcification, give rise to the most fantastic shapes and appearances of the parts affected. Old cases are often associated with aneurism of the leaflets, dilatation, pouching, or perforation of valves. Often small tumor-like masses remain on the leaflets, which become thick, rigid, and calcareous.

HYPERTROPHY AND DILATATION.—These conditions are usually associated the one with the other. In hypertrophy the individual muscle-fibres are increased both in number and in size, the condition being due to too much nourishment or overwork, and may be due to intrinsic (cardiac) or extrinsic (extracardiac) causes. In concentric hypertrophy the cardiac walls are thickened and the cavities are smaller than normal. In simple hypertrophy the overgrowth of the walls is associated with normal cavities, while in eccentric hypertrophy dilatation is found along with the thickening of the walls. There may also be simple dilatation without hypertrophy. The highest degrees of enlargement which I have seen have been found in cases of double aortic disease, where, too, moderator bands are sometimes found. It would seem that the long-continued administration of digitalis may produce hypertrophy.

VALVULAR DISEASES.—An extreme degree of mitral stenosis is seen in the so-called buttonhole mitral, a condition more frequently observed in England than it is in this country and which causes hypertrophy and dilatation of the left auricle. Cyanotic induration of other viscera, especially of the lungs, and dropsical effusions may follow mitral incompetence. In aortic stenosis the valves are usually thickened, rigid, and cartilaginous; later they become calcified and the

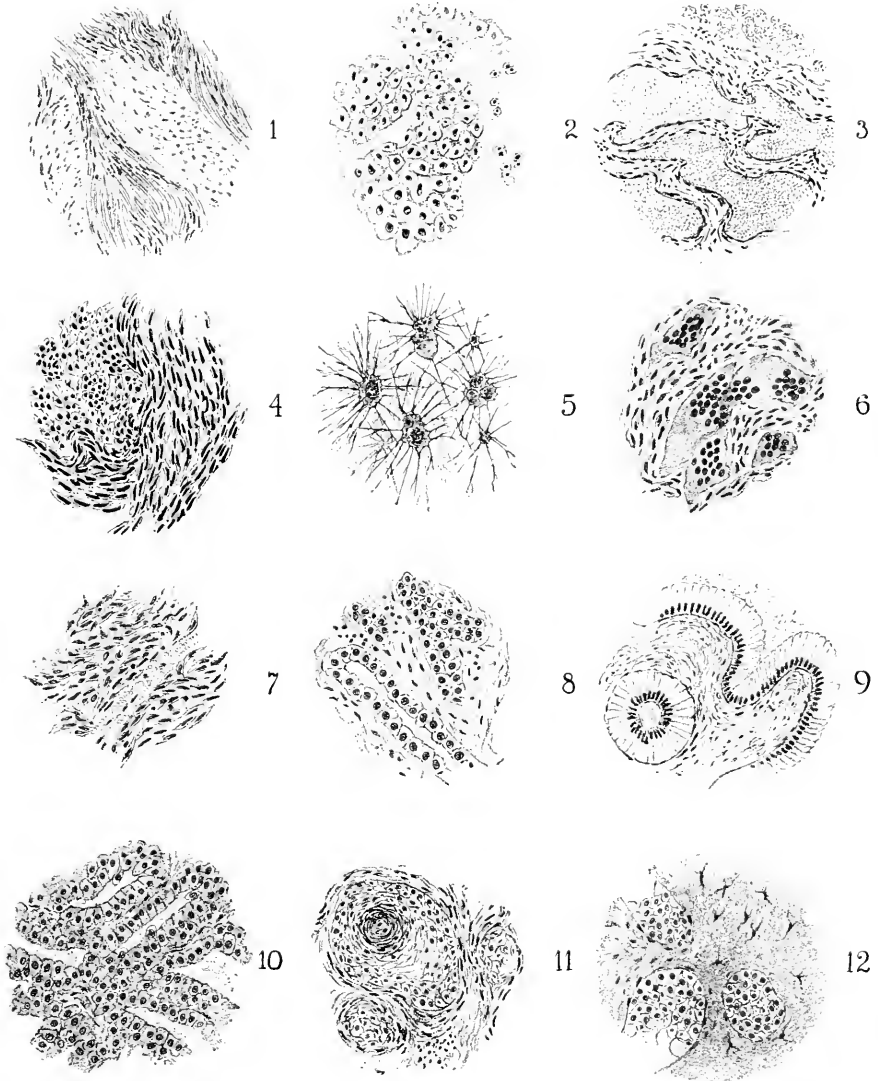
division between the different cusps is lost. First there is ventricular hypertrophy, later right-sided enlargement, and finally dilatation with pulmonary congestion. In aortic incompetency arteriosclerotic changes are marked, being seen not only in the valves but also in the aorta, and associated with dilatation and hypertrophy of the left ventricle and of the left auricle, and often followed by fibroid myocarditis. Sudden death is frequently due to aortic stenosis, a condition usually associated with hypertrophy of the left ventricle and a dilated cavity. The aortic ring and segments are atheromatous, puckered, and contracted, often calcareous, and may admit only the tip of the little finger. The aorta above the stricture is usually dilated. Tricuspid regurgitation is seen generally associated with cases of cirrhosis of lung and chronic emphysema. Cyanosis is common. Pulmonary-valve disease is rare, except as a congenital lesion. Stenosis is usually associated with patency of the ductus Botalli.

SYPHILIS, TUBERCULOSIS, ACTINOMYCOSIS, TUMORS, ETC.—Syphilitic gummata appear in the heart as rather large yellow foci surrounded by fibrous tissue; they may also be found in the arch of the aorta. Miliary tubercles, when present, are usually subendocardial or situated in the large vessels coming off the heart. At a postmortem in Ziegler's mortuary I once saw where caseation of a peribronchial gland had extended through the pulmonary artery and given rise to a most marked local and general miliary tuberculosis. Actinomycosis has been observed. Tumors are rare; myxomata, lipomata, fibromata, fibrous polyps, sarcomata, and rhabdomyomata may be met with as primary tumors of the heart, while, as secondary deposits, carcinomata and especially multiple melanotic sarcomata may be observed. (Plate IV.) In v. Pessl's case¹ of extensive lymphosarcomatosis, the heart at autopsy showed the anterior wall of the left ventricle and a large part of the septum almost converted into a "shell of lime." A carcinoma may thus develop here secondary to one of the penis.² Foreign bodies, as needles, hat-pins, pieces of bone, etc., have been found in the cardiac wall and even in the cavities of the heart. Cysticerci, echinococci, and very rarely pentastomata may be discovered in the various parts of the heart.

¹ *Münch. med. Wchnschr.*, June 10, 1902, p. 956.

² PEPPER, *Phila. Path. Soc.*, meeting of November 12, 1903.

PLATE IV



1, fibroma; 2, chondroma (after Ziegler); 3, cavernous angioma of the liver; 4, myoma; 5, glioma of the brain; 6, giant-celled sarcoma; 7, spindle-celled sarcoma; 8, endothelioma of the pia mater; 9, adenoma; 10, cancer; 11, epithelioma with an epithelial pearl; 12, myxomatous cancer.



ARTERIES, MORBID CHANGES IN.—*Arteriosclerosis*.¹—A chronic thickening and hardening, diffuse or circumscribed, of the arteries, characterized by a diminution of elasticity of the vessels and marked alterations in blood-pressure. The arch of the aorta is the most common seat. In the *first stage* there are a loss of elasticity and some dilatation, due to hyaline or other changes in the subendothelial coat, and thickening of the intima. The *second stage* is characterized by a thickening of the media, atrophy of the muscular and elastic tissue, with proliferative changes in all the coats; the increase of new tissue gives rise to pressure on the vasa vasorum, with interference of nutrition, which leads to the *third stage*, in which there are more or less marked macroscopic changes. New elastic tissue, derived from the splitting off of the internal elastic layer of the artery, may be found in the intima. The vessels are hardened, firm to the touch, do not retract or close when cut, and their lumina may be smaller or larger than normal. On the intima may be seen milk-white or yellowish patches, containing fat, cholesterin, and detritus, intermingled with calcareous plates and areas of ulceration and atheroma. There may be a marked tendency to dilatation, with the formation of an aneurism, or to contraction with obliteration. Some cases are associated with fibrosis of the aortic valves. As described by Heller, this form when found in the thoracic aorta is usually syphilitic. Loss of elasticity may be general or local; when permitting more distensibility, we have angiomalacia or softening, as in phosphorus poisoning and scarlet fever; if less, arteriosclerosis or angiosclerosis, or hardening. An interesting experiment is to remove the aorta and see how much it will stretch by the addition of weights before it ruptures. *Special forms*.—(a) Senile. To a certain degree this may be regarded as physiologic, the elastica being developed as in scar tissue. The condition affects the larger arteries most; they are dilated, lengthened, tortuous, thin but stiff; often show atheromatous changes in the intima. Even to the naked eye the subendothelial tissue is degenerated. Cyanotic induration and senile atrophy of the heart, liver, and kidneys are common. Moist gangrene of the extremities may follow calcification in the iliac arteries. The changes produced by sclerosis of the coronary artery have already been referred to. (b) Nodular. Knob-like, flat, yellowish-white projections are seen in

¹ WELCH's paper, read at the June, 1904, meeting of the American Medical Association, should be consulted by those interested in this important subject.

the aorta and its branches, particularly about the orifices. These in later stages undergo liquefaction and form atheromatous ulcers. Dilatation or aneurism may then ensue. (c) Diffuse. The lesion is wide-spread and more uniform; the intima, as a rule, does not show marked naked-eye changes, though there may be elevated spots of a milk-white color. The aorta and its branches are dilated, the branches sometimes more than the trunk. Cardiac hypertrophy is constant. The kidneys are sclerosed, their capsule is adherent, the cortex irregular and often cystic. (d) Endarteritis obliterans. There is particularly a thickening of the intima, the entire lumen of the vessel being closed, and is practically a compensatory arteriosclerosis. It is not uncommon at the base of the brain. Erythromelalgia is largely due to arteriosclerosis. Lead and alcohol are considered to be frequent causes of arteriosclerosis.

Amyloid Degeneration.—Usually microscopic, and best demonstrated by staining. *Atrophy.*—A general diminution in the size of arteries, best seen in stumps after operations. *Calcareous Infiltration.*—In the media of the arteries of the old, particularly involving those of the extremities, calcification frequently occurs. It interferes with the flow of the blood, predisposes to thrombosis, and may be the cause of senile gangrene. Seen as a diffuse or circumscribed process, usually in connection with atheroma, and as a later stage of fatty degeneration. *Fatty Degeneration.*—In fatty degeneration the affected areas of the intima have a white or a citron-yellow appearance. These areas occur in the form of points, stripes, and regular or irregular net-shaped figures. A frequent location is the posterior wall of the aorta around the origin of the intercostals. For more careful macroscopic study the surface of the fatty area should be removed with a fine forceps and in the centre a shallow incision should be made. Here small and large fat droplets can be seen. When placed in Flemming's solution these droplets become black. The fatty degeneration may involve the media and even be the cause of rupture. It is often associated with calcareous degeneration. *Hyaline Degeneration.*—Almost always microscopic; affects principally the elastic coat and is often the beginning of an arteriosclerosis. It most frequently involves the small arteries. Best seen in the glomeruli of the kidney. *Hypertrophy.*—There is hypertrophy of the muscular layer in some diseases of the kidney, and hypertrophy of this layer in arteries of medium size in aortic insufficiency. A general enlargement, best seen in the collateral circulation after ligation

of a large vessel. *Hypoplasia*.—Hypoplasia of the aorta is congenital and is the result of stenosis, most commonly situated near the insertion of the ductus arteriosus Botalli. It usually soon causes death; if not, the aorta is contracted and thinner, but very much more elastic. Virchow attributes chlorosis to it.

Inflammations.—I. Acute endarteritis (proliferative or obstructive endarteritis, thrombo-arteritis). This starts with an injury to the endothelium, proliferation occurs, and an obstruction is formed in the vessel wall, on which a thrombus forms, partially or completely obstructing the vessel. The intima is yellow and may be covered with many arcuate limited or confluent ulcers, with a loss of substance. Cholesterin and fat cells are found in the detritus. The lesion may terminate in absorption, suppuration, ulceration, or fibroid change. II. Chronic endarteritis. This usually follows the acute form, but is sometimes primary. It may be local (organization of a thrombus) or general (arteritis deformans); when in the media it is known as mesarteritis and in the adventitia as periarteritis. Thrombosis is more common in the veins; it is usually caused by embolus from the right heart or from the left and associated with hemorrhagic infarct. Cases have been reported of thrombosis in the aorta above its bifurcation, in which the aorta and the femoral and popliteal arteries also revealed a marked thrombosis. It may occur in a vein during pregnancy, chronic nephritis, rheumatism, diphtheria, or typhoid fever. Marantic thrombi may form in cases of enfeebled circulation, as in the cachexia and anæmia of severe infections, sometimes associated with arteritis obliterans. In these cases it occurs usually in the large superficial veins of the lower extremities and in the sinuses of the brain. Thrombosis of the superior mesenteric artery, with a slate-colored to black gangrene of the small intestines for many feet, is sometimes seen. The thrombi are gray white, red, or mixed; if recent, they are attached, of bright-yellow color and membranous consistency; if old, they are firmly organized and may be calcareous. Thrombus is generally supposed to be due primarily to bacteria. The whitish-yellow thrombus is made up of platelets, leucocytes, fibrin, and a few red blood-cells, and is rich in serum. Thrombi are not at all rare in the heart, occurring usually in the auricle of the right side or the apices of the ventricles between the papillary muscles. They often have a root-like process, which is especially marked in the appendix, and are most frequently found in cases of cardiac aneurism and in endocarditis.

Softening by a process of liquefaction necrosis may occur in organized thrombi, and autolytic ferments also act. Calcification may take place later and vein stones (phleboliths) arise. Arterioliths are shot-like bodies, especially found in the arteries of the spleen, bladder, etc.

Syphilis is usually a diffuse process affecting all the coats, especially the intima, and thus giving rise to a local or general sclerosis. Gummata are rare. Orth, quoting from Heller, gives the numerous small foci of cell-infiltration necrosis, and particularly induration, with small thickenings of the inner surface, as the characteristic differences between syphilis and chronic aortitis.

Tuberculosis.—Tuberculous lesions are less common in the arteries than in the veins. The small arteries are most frequently affected, as those of the pia, the brain, the kidneys, and particularly the lungs. The disease starts as a local gray tubercle of hæmatogenous origin in the intima or as an extension from a neighboring tuberculous process. *Thrombosis* and *embolism*, especially in the brain, are of extreme importance. In embolism air, fat, portions of tumors, micro-organisms, etc., are brought to a smaller vessel from a larger one (though the converse may occur), and there set up characteristic changes, as infarcts, softening, abscesses, etc.

Tumors.—The new growths found in arteritis are angioma, an erectile tumor; capillary nævus, usually found on the face, in which the capillaries are dilated and tortuous; a nævus composed of dilated and tortuous arteries forms a racemose or cirroid aneurism, which is usually found in the subcutaneous tissue. The skin over the tumor is, as a rule, very much thinned. An arterial varix consists of a dilatation and lengthening of a single artery. Venous nævus is a tumor made up of communicating spaces lined with endothelium into which arteries empty and from which veins arise.

Aneurism.—An aneurism is a circumscribed, tumor-like dilatation of a blood-vessel, especially an artery, containing blood in direct connection with the blood-current. A *true aneurism* has a sac composed of one or more of the arterial coats. A *false, spurious, or hernial aneurism* is one in which some of the walls are formed by the tissues surrounding an opening in the artery; these sometimes attain an enormous size. The aneurism is called *cylindric* when the lumen of the artery is symmetrically increased in all directions; *saccular* when the aneurism is sac-like; *cirroid* when a large extent, or even the whole ramification, of an artery becomes dilated and tortuous; this form most

often occurs in the frontal, occipital, or iliac arteries; *fusiform* when it is spindle-shaped; sometimes these form near a tear of the intima, the media and adventitia becoming markedly sclerosed (arteriosclerotic). A *traumatic* aneurism results from injury or laceration of the intima by force. A *dissecting* aneurism arises when blood circulates between the coats of an artery. Extensive degeneration must precede this form. I have seen such an aneurism beginning at the transverse arch of the aorta and opening again into the blood-stream just above the aortic bifurcation. *Arteriovenous* aneurism arises where there is a communication existing between an arterial aneurism and a vein; a variety of this is the varicose, where an artery and a vein communicate through a false aneurismal sac lying between them. When bleeding was more frequently practised than it is now, these aneurisms in the arm were of quite common occurrence. In the *varicose* aneurism there is a communication between an artery and vein with the interposition of a *sac*. Aneurismal varix is a communication between an artery and a vein without the interposition of a sac. *Mycotic* or *infective* aneurisms are apt to be multiple and are caused by micro-organisms. This variety is often seen in connection with malignant endocarditis. The mesenteric arteries of the horse sometimes become dilated with considerable numbers of the *Strongylus annatus*. *Miliary* aneurisms are usually multiple and consist of small dilatations; they are found especially in the brain and lungs, and often antedate a hemorrhage in these regions. They are best seen in the brain by excising the middle cerebral or basilar artery and floating it out in a white dish partially filled with water. These aneurisms may be due to emboli. *Traction* aneurisms have been reported by Thoma at the concavity of the arch of the aorta. Aneurism by distention, rupture, erosion, and anastomosis, and also valvular and congenital aneurisms have been described. Aneurism is often associated with arteriosclerosis, embolism, trauma, and infections. The change is now believed to start in the elastic coat.

The walls of the blood-vessels may be present or altogether absent; they may be thickened and opaque or almost transparent. If the aneurism be large, the cavity has a roughened wall, often lined with endothelium, and frequently contains clots which are white, red, organized, or softening. They often show lamination. I have seen a fibrinous clot of an aneurism of the carotid mistaken for a sarcoma of the neck, a gluteal aneurism opened for an abscess, and a femoral aneurism mistaken for a hernia. Rupture of an aneurism, usually from the

aorta into the pericardium, is a most frequent cause of death in cases brought to the notice of the Coroner. The rupture often occurs during the act of defecation. Three cases of aneurism of the sinus of Valsalva have come under my notice. The direction of the increase in size of a forming aneurism depends on its location. Constant pressure of the sac may overcome the resistance and cause absorption of the densest tissue, even bone. Hence aneurisms of the arch of the aorta may rupture externally or erode the vertebral column, even to the spinal cord. Life has been prolonged in such cases by wiring and treatment with electricity, though the aneurism usually appears in another situation. In Stewart's case the patient lived three and a half years, the man finally dying from an alcoholic pneumonia. The clot around the gold wire may become markedly fibrinous. The danger in the operation would seem to be from an embolus. Aneurisms are most common in the thoracic aorta, abdominal aorta, cœliac axis, splenic artery, and very rare in the hepatic artery. I have seen a few cases of that rather rare condition, aneurism of the superior mesenteric artery.

Congenital aneurism, periarteritis nodosa, closely resembles at times sarcoma; nodules may be felt in the abdominal wall, in arteries of muscles, and in the viscera. There is marked thickening of the intima and infiltration of other coats.

The question as to the etiology of aneurism is much debated. My own statistics on this subject confirm the opinion that syphilis is a frequent cause, especially in the early stages before marked arteriosclerotic changes have taken place in the arteries. This view is also supported by the fact that animals are rarely affected with aneurism. The experimental production of aneurism in animals by alcohol, trauma, etc., affords an interesting field for future investigators.

DISEASES OF VEINS.—The more common lesions in veins are *thrombosis* and *phlebitis*. Phlebitis occurs in connection with many cases of thrombosis, in gout, and after traumatism; micro-organisms are usually found. It appears commonly in sinuses of the brain, associated with leptomeningitis. The intima is rough, uneven, corroded. Vein walls are infiltrated and discolored. On the surface over an infected vein there is a dusky-red line. Thrombosis always occurs. Suppuration or pylephlebitis, associated with thrombosis and with purulent softening, occurs in the portal veins. The vein is filled with puriform fluid, which may cause a branching abscess all through the liver. A varix is a permanent dilatation above a valve.—a long, fusiform dilata-

tion (phlebectasia) or cirroid aneurism. It is most common in the leg and is often associated with diseases of the heart, liver, lungs, or pleura, or may be caused by the pressure of a tumor. Phleboscrosis is seen at times with dilated veins. The vein in these cases is nearly always distorted and thickened. Thrombi often form in dilated parts and are sometimes converted into phleboliths. Associated with this lesion are cedema, chronic catarrh of a mucous surface, chronic ulceration of a cutaneous surface, pigmentation, and productive fibrosis. Certain varices have special names, as varicocele, dilatation of spermatic veins; hemorrhoids, dilatation of veins of lower rectum; caput Medusæ, dilatation of superficial abdominal vessels, etc. Primary tumors are rare in veins. Any tumor may be present secondarily. Often there is a fibrous endophlebitis, etc. Syphilitic inflammation is seen in portal and other veins and is a congenital form. Tuberculosis of a vein from a lymph-node is not uncommon in general miliary tuberculosis.

CHIEF LESIONS FOUND IN LYMPH-VESSELS.—*Dilatation* is especially seen in elephantiasis Arabum and is due largely to *Filaria*. Certain parts, as the scrotum, labia, and thigh, are generally the seat of the lymph stasis. This lesion is always associated with hypertrophy and thickening of the tissues. *Lymph tumors (lymphangioma)*—(1) simplex, not much enlarged, (2) cavernosum, much dilated—are usually found in the tongue (macroglossia), cheek, etc. Lymphangioma cysticum occurs most frequently in the neck or the sacral region. The contents of the cyst are often very fatty, at times partially coagulated. Endothelioma and carcinoma may occur. The lesions of tuberculosis and syphilis are found.

CHAPTER IX

DISEASES OF THE RESPIRATORY TRACT AND ACCESSORY PARTS¹

NASAL PASSAGES.—Malformations of the nose are very common. The entire nose, the septum, or the turbinates may be absent. Deviation of the septum occurs in about one out of every ten persons. *Acute Nasal Catarrh (Rhinitis, Coryza).*—This condition accompanies various infections, as variola, scarlatina, measles, influenza, r theln, and diphtheria. In infants it is often a manifestation of syphilis or gonorrhoeal infection. The nasal mucous membrane is red, swollen, and covered with exudate, the accessory sinus, pharynx, and Eustachian tubes being sometimes secondarily inflamed. Empyema of the antrum of Highmore may result, but more frequently arises from carious teeth. Herpetic eruptions are often seen on the lips. *Chronic Nasal Catarrh.*—Varieties: hypertrophic, atrophic, fibrinous, or membranous. There is usually a persistent mucopurulent discharge. In the hypertrophic form there are flattening of the nasal bridge, thickening of the alae and the mucous membrane, exostoses on the septum, and hypertrophy of the cavernous tissue. In the atrophic variety the mucous membrane is pale, dry, glazed, and covered with scabs, ulcers, and, at times, necrotic tissue, which may lead to perforation of the septum, but this is much more commonly seen in syphilitic rhinitis. Adenoids are, as a rule, confined to the roof of the nasopharynx, but may occur upon the lateral walls. They are smooth, rounded masses, or pedunculated, varying in size from a hemp-seed to an almond and of a pale-pink color. These may replace entirely the normal pharyngeal tonsil. Nasal tuberculosis, especially in the form of lupus, syphilis, glanders, and leprosy, may occur in the nose. Rhinoscleroma gives rise to nodular thickenings and ulcerations of the tissues of the nose, lips, pharynx, and larynx. *Tumors.*—Fibrous, myxomatous, and cystic growths are by far the most common varieties found in the nose, and are most commonly situated in the lower third of the chamber. Cysts, fibroma, fibromyxoma, chondroma, osteoma, epithelioma, and angiosarcoma are seen. Sarcoma usually affects the nares and ethmoid cells. Carcinoma is rare. Rhinoliths are sometimes discovered measuring an inch or more

¹ Based on ALLCHIN'S *Manual of Medicine*, 1902.

in length and nearly as broad. They are quite thin and easily broken in their removal. Especially in childhood *foreign bodies*, such as food, coins, seeds, which may sprout, eggs, especially of certain flies, which may here assume the larval form, buttons, rags (especially in the newborn), blood, vomit, and pus, may be discovered.

Hay Fever.—An asthmatic disorder manifesting itself by paroxysmal attacks of nasal catarrh with marked periodicity, the attacks being induced by certain localities, odors, the pollen of many plants, dust, etc. The nasal mucous membrane shows usually some abnormality or chronic hypertrophic rhinitis, with free exudation, polyseptal irregularities, adenoids, and turgescency of the mucous membrane, especially over the inferior and middle turbinates.

Epistaxis.—Bleeding may be due to injury or to acute or chronic rhinitis, ulceration of the nasal mucous membrane from tuberculosis, syphilis, typhoid fever, diphtheria, or foreign bodies, and is very common in malignant new growths and in valvular disease.

LARYNX.—The larynx is frequently deformed from hypoplasia or asymmetrical development. The sinus of Morgagni may be dilated or there may be fistulous canals from imperfect closure of bronchial clefts. *Acute catarrhal laryngitis* is usually secondary, following infections, as measles, typhus, smallpox, whooping-cough, etc. The vocal cords are reddened, swollen, and covered with viscid mucus. In very severe cases erosions and ulcers are observed. Varicose veins and punctate hemorrhages are seen, especially in chemic cases. *Diphtheritic laryngitis* is generally a part of a general infection. The mucous membrane is covered by a gray-yellow membrane, under which the epithelium is eroded and necrotic. *Erysipelas* also affects the larynx. *Œdematous laryngitis* may be acute or chronic, and is due to septic infection, traumatism, certain drugs, or chronic visceral diseases,—*c.g.*, Bright's disease. This may be inflammatory, non-inflammatory, or dropsical. (1) The epiglottis, the aryepiglottic folds, and the ventricular bands are the parts chiefly affected. The vocal cords are seldom included, but the œdema may go below them. The mucous membrane is pale, except at the borders of the swelling, which are injected. (2) The exudation may be serous, seropurulent, or purulent, and may or may not be blood-stained. (3) In very severe cases the larynx may be entirely closed, and the mucous membrane swollen and reddish purple, the epiglottis appearing as a round, translucent tumor. In *chronic laryngitis* the mucous membranes are reddened, the cords

are thickened, sometimes with adherent secretion, and the vessels are injected. In *laryngitis sicca* the cords are covered with dry crusts, which may be blood-stained. *Pachydermia laryngis* is a condition in which symmetrical fleshy-looking thickenings are found on the cords. Singers' nodes resemble these and are round nodules on the upper surface and free border of one or both cords. *Perichondritis* is always secondary, the lesion appearing first as a smooth, nodular, unilateral swelling, which is soon followed by necrosis or abscess, most often involving the cricoid cartilage. It is a common manifestation of syphilis or malignant disease. This condition may be followed by *ankylosis of the crico-arytenoid joint*, which is associated with tumefaction, abnormal position of the arytenoid cartilages, and fixation of the vocal cords, or by *laryngeal stenosis*. The latter is also secondary to healing of tuberculous, syphilitic, or chemic ulcers, pressure of foreign bodies, etc. In one case a fish-bone was found, transverse in the larynx, resting on the ventricular bands and arytenoid cartilages.

Tumors of the Larynx.—Benign growths are quite frequent. There is usually a diffuse hyperæmia or a warty or infiltrating growth on one cord, situated about the middle and surrounded by a zone of congestion. Ulceration, perichondritis, and exfoliation of the cartilages are common complications. The most common tumors are papilloma, papillary fibroma, and fibroma tuberosum. The malignant tumors are carcinoma, sarcoma, and epithelioma. Foreign bodies, inducing suffocation, are by no means uncommon. I have known a piece of lead-pencil and a bolus of food thus to cause death.

TONSILS.—These glands are inflamed in the course of many infections and may be primarily affected, as with tuberculosis, gangrene, syphilis, and lacunar keratosis. In simple catarrhal inflammations the tonsils are uniformly swollen, red, and covered with tenacious mucus. In the follicular variety yellow plugs of degenerated epithelium are held in the crypts by the swelling of the gland. In the phlegmonous form the tonsils may be so swollen that they meet and occlude the pharynx and may be yellow from the contained pus. Hypertrophied tonsils are manifestations of chronic inflammation, and are often associated with rickets, tuberculosis, adenoids, and chronic nasopharyngeal catarrh. There may be a true hypertrophy or overgrowth of but one tissue. The follicles may be dilated and filled with cheesy material. Sarcoma is a not uncommon tumor. Epithelioma, angioma, fibroma, myoma, papilloma, and lymphoma occur. Bone and cartilage are seen.

THE TRACHEA AND BRONCHI.—*Malformations*.—Fistula is due to imperfect closure of the third and fourth branchial clefts, a small orifice remaining, which may communicate with the trachea, or end blindly on the anterior edge of the sternomastoid muscle three or four centimetres above the inner end of the clavicle. The inner portion is at times dilated, forming a bronchiogenic cyst. These are the so-called “gill openings” of the human body.

Asthma.—This condition being due to a spasmodic contraction of the bronchial tubes and air-vesicles, the lesions found at the post-mortem are not marked, consisting only in hypertrophy and widening of the bronchial tubes with thickened mucous membrane and a dilatation of the air-cells, giving the chest a barrel-shaped appearance and the dorsal spine a curvature. Pressure on the vagus by enlarged bronchial glands is sometimes the only lesion found, or it may be associated with hypertrophic rhinitis. Charcot-Leyden crystals and Curschmann's spirals are often discovered in the sputum.

Bronchiectasis.—There is a local or general dilatation of the bronchial tubes, which may be congenital and unilateral or the result of various diseases of the lungs and bronchi. A non-patulous bronchus, closed alveoli (atelectatic bronchiectasis), puckering of the peribronchial or interstitial fibrous tissue, parenchymatous changes of chronic bronchitis, or the circumscribed narrowing of tumors, etc., sometimes produce bronchiectasis. Cylindrical, saccular, spherical, ovoid, fusiform, and moniliform dilatations are seen. At the postmortem large sacs may be situated immediately beneath the pleura or a number of sacculi varying in size may be found opening one into another. The walls are covered with smooth, glistening, or hypertrophied epithelium, which may be ulcerated in the dependent portion. Putrefaction (putrid bronchitis), fatal gangrene, or a tuberculous lesion may follow the retention of the material thus collected. Calcification sometimes occurs. The lungs usually show some fibroid change. The air-vesicles are emphysematous or condensed by pressure. The liver, spleen, and kidney often show chronic congestion or lardaceous degeneration. Pleuritic abscesses, peritonitis, adhesive pericarditis, dilatation of the right heart, etc., are complications which are sometimes found to be present in bronchiectasis.

Bronchitis.—Bronchitis is an acute, subacute, or chronic inflammation of the bronchial tubes, not involving the terminal bronchi, due to infection, exposure, irritants, or extension from neighboring organs.

In *acute catarrhal bronchitis* the mucous membrane is thickened, swollen, at times hemorrhagic, and at first covered with tenacious mucus, which later becomes profuse, thin, and purulent, and may fill the large bronchi. Lobular atelectasis surrounds the affected areas. *Suppurative bronchitis* results from septic embolism, forming small abscesses in the bronchial tubes. *Croupous bronchitis* is characterized by the formation of a diphtheritic membrane, sometimes of complete casts of the smaller bronchi, but is not, as a rule, associated with the Klebs-Löffler bacillus. Bronchopneumonia, extension to the small bronchioles and air-vesicles, œdema, congestion, and local emphysema are frequent complications. In *chronic hypertrophic bronchitis* the whole lung is larger, firmer, and darker than normal. The mucous membrane is thickened, reddish or slate-gray in color, and often shows petechial hemorrhages. The bronchus is sometimes dilated, or is thicker and more fibrous, with its lumen narrowed by small, firm, villous granulations. This obliterating fibrous inflammation usually affects the smaller bronchi and may cause stenosis. The surrounding lung is usually emphysematous, pigmented, and shows an increase of fibrous tissue. The bronchial glands are enlarged, indurated, and pigmented. Dilatation of the right heart and chronic congestion of the liver, spleen, and kidneys are common complications. The lung of *atrophic bronchitis* is smaller and lighter in weight and color. Its elasticity is impaired, it feels "cottony" to the touch, and there may be increase of connective tissue, the longitudinal bands of elastic tissue standing out prominently. The mucous membrane is smooth, atrophied, and the lumen of the tubules may be widened. *Putrid bronchitis* is practically a bronchiectasis. The bronchi are dilated; their walls are usually smooth, but are frequently ulcerated. Fatty plugs and purulent masses such as are found in the sputum during life are seen in the ulcers. Purulent œdema of the lung is more or less general. *Plastic (fibrous) bronchitis* may be regarded as a chronic form of croupous bronchitis, occurs only rarely, and is paroxysmal, usually being limited to a certain number of bronchi. The membrane is a fibrous, fairly consistent pseudomembrane about two millimetres thick with no epithelium under it. The mucous surface is hyperæmic and infiltrated with cells. The thick ducts of the glands push the fibrous tissue off and it is coughed up. The smaller bronchi show catarrhal inflammation, but no membrane. Sometimes coagula are found in the tubes after death. *Tuberculous bronchitis* may be acute, manifesting itself as a part of

a diffuse caseous process and involving an entire wall (peribronchitis) or appear as tuberculous ulcerations like those of the larynx. *Cheesy bronchitis* is a caseation of retained catarrhal secretion. The mucous membrane is infiltrated with cells and these also subsequently caseate. *Gangrenous bronchitis* is associated with bronchiectasis.

Stenosis of the trachea or bronchi is due to pressure from tumors, aneurisms, mediastinal abscesses, hemorrhages, swelling of the lining mucous membrane, impacted foreign bodies, etc., to perforating caseous glands or to contraction from syphilitic or tuberculous ulcers.

Primary tumors of the bronchi are rare. Carcinoma may develop from the muciparous glands of the bronchial mucous membrane. Secondary tumors are more common. Calcareous, papillomatous excrescences, annular in shape, may be found in the trachea. *Foreign bodies* in the air-passages are discovered usually in the right bronchus. If the blocking is partial, vesicular or interstitial emphysema results. Œdema, local inflammation, and ulceration of the bronchus, lung, and pleura, with rupture of vessels, may occur.

DISEASES OF THE MEDIASTINUM.—*Mediastinitis* is rare, and when present is generally due to infection by *Pneumococci*. The cellular tissue is infiltrated with a puriform lymph. Pericarditis, pleurisy, abscess, gangrene, ascites, cedema of the upper part of the body, and albuminuria may follow mediastinitis. *Mediastinal adenitis* may be simple, suppurative, or tuberculous. The simple form occurs with any inflammation of the neighboring organs. Suppurating glands may rupture into the œsophagus, bronchus, or aorta. Tuberculosis of glands is usually a secondary involvement from the bones, lungs, or pleura. The *spindle-celled sarcoma* is the most common growth in this region. Carcinoma, lymphoma, and lymphosarcoma are also found. Dermoid cysts may occur in the anterior mediastinum.

GOITRE.—A local or general hypertrophy of the thyroid gland, characterized pathologically by a variety of morbid changes. In the same gland may be found cystic disease and mucoid, fatty, gelatinous, or colloid degenerations. On section the gland appears as a yellow or brownish mass with scattered areas of colloid matter, varying in size from a pin-head to a millet-seed. In cystic goitre there is a distinct limiting membrane, brownish red if the cyst be due to hemorrhage. If slender masses of tissue project from this membrane, the condition is known as papillary cystadenoma. In some cases the enlargement of the gland may be due to marked vascular dilatation without the

formation of new gland-tissue. If the arteries only are dilated, Orth calls it *struma aneurysmatica*; if the veins only, *struma varicosa*. Fibroid or calcareous changes also occur. In fetal adenoma the structure maintains its fetal characteristics,—*i.e.*, solid masses or rosettes of epithelial cells with little or no colloid material are seen.

Goitre, Exophthalmic (Basedow's or Graves's Disease).—A disease common to women of early adult or middle life, which is characterized by functional disturbance of the heart; diffuse or unilateral hypertrophy of the thyroid gland, rarely as great as in ordinary goitre; a marked increase in the number and size of its blood-vessels; absorption of its colloid material, a replacement of it by a more mucinous fluid, and undue prominence of one or both eyes, due to an increase of the orbital fat. There is separation of the epithelium lining the cavities from the basement membrane, with swelling of the individual cells. The thymus gland may persist and undergo enlargement, and there is an increased amount of connective tissue in the neck. Marked pigmentation of the skin may simulate Addison's disease. Myxœdema may develop in the later stages or the emaciation may be extreme. Glycosuria and albuminuria are not infrequent. The heart is usually hypertrophied, but may be dilated or normal in size.

LUNGS.—*Abscesses.*—Abscesses of the lung and neighboring parts may arise from pyæmia, embolism, tuberculosis, pneumonia, or the presence of foreign bodies, and are due to many varieties of bacteria, as *Pneumococci*, tubercle bacilli, *Gonococci*, *Actinomycetes*, the amœbæ, and various pyogenic micro-organisms. Acute miliary tuberculosis without any areas of softening in the lung may be found. An abscess may discharge itself through a bronchus or otherwise and leave only a dense cicatrix. The solitary abscess is comparatively rare, and usually results from disease of the neighboring parts, as the pleura, liver, or mediastinum. Such an abscess may become encapsulated and contain a greenish-yellow pus of an offensive odor. Multiple abscesses are common, generally superficial, frequently wedge-shaped, rarely encapsulated, and vary in size from that of a pea to an orange. They are at first firm, grayish red in color, and surrounded by a zone of hyperæmia. Later they become distinctly purulent, with an irregular, ragged cavity. The pleura is usually covered with a greenish lymph and may be perforated, causing empyema or pyæmia.

Atelectasis.—Collapse of the lung, partial or total, may exist in the foetus at birth (fetal atelectasis), or be caused by closure of the

bronchi (capillary bronchitis), compression from a tumor, hernia of the diaphragm, pleuritic transudates and exudates, or marantic conditions. The last is due to weakness and is most marked in the smaller ramifications of the lower and posterior bronchi, often ending by subsequent œdema in pulmonary splenization. The air in the shut-off portion is absorbed, and the portion on section is dark red or bluish red and firm. In old cases the lungs cannot be inflated, the tissue is dense, firm, deeply lobulated, and paler than the rest of the lung. The lung is usually atrophied or may be entirely replaced by a fibrous cicatrix. When the collapse is superficial, as in rickets or pleurisy, the lung is reduced in bulk and wrinkled, fleshy in appearance, smooth, tough and inelastic, and dark red in color. If due to bronchial obstruction, scattered patches of atelectasis occur over the lung, the bronchi leading to these areas being filled with mucopurulent secretion. The surrounding lung may be œdematous or perhaps the seat of chronic pneumonia.

Circulatory Disturbances.—Anæmia, hemorrhage, infarcts, fat embolism, or even air embolism, of the lungs may be associated with a similar condition in the right heart. A number of fatal cases of pulmonary embolism have occurred after intramuscular injections of calomel for syphilis, caused by detachment of clots from the femoral, iliac, or uterine arteries, by hydatids, and by phlebolites. Fat embolism of the lung should always be thought of in cases of fractures or of extensive injuries to the subcutaneous fatty tissues or of traumatic rupture of the liver, from which source parenchymatous emboli may also occur. Hæmoptysis may occur from hemorrhagic infarcts, brown induration, tuberculosis, an aneurism rupturing into the trachea or bronchi, acute inflammations, purpura, scurvy, apoplexy, etc. It is interesting to note that a pulmonary hemorrhage in tuberculosis may be the beginning of an attack or precede a fatal termination. Pulmonary thrombosis may arise from embolus, engorgement of the capillaries, or disease of the pulmonary artery. It is not an infrequent complication in pneumonia and tumors, and often occurs in cases of atheroma of the pulmonary artery. Thrombosis of a pulmonary vein has been reported, usually the result of gangrene, pleurisy, or œdema. Hemorrhage into the air-cells and lung tissue is due to thrombosis or aneurism of the pulmonary artery, or to aspiration, as in gangrene and tuberculosis, or to the hemorrhagic diathesis. The extent of lung tissue involved differs very greatly. The lung is large, firm, dark, and heavy. On section there is extravasation of considerable amounts of more or less frothy fluid blood.

Passive congestion occurs where there is obstruction of the circulation, in chronic illness requiring the recumbent position, and in diseases of the central nervous system. It is basic or hypostatic. (*a*) In mechanical congestion, if the condition has lasted some time, the lungs are voluminous, russet-brown in color, œdematous, and cut and tear with difficulty, giving rise to the so-called brown induration. On section they are of a maroon tinge, which on exposure to the air soon gives place to a vivid red. The alveolar capillaries are distended and tortuous, the fibrous tissue is increased, and hæmatoidin deposits are found in the epithelial cells. (*b*) In hypostatic congestion the bases of the lungs are deeply cyanosed and heavy and the posterior parts engorged with blood and serum. In some instances portions of the tissue will sink in water and on section exude a bloody serum. In prolonged coma the hypostatic congestion may be associated with patches of consolidation due to the aspiration of food into the air-passages. (*c*) Passive congestion occurring in cerebral apoplexy is most marked in or may even be confined to the paralyzed side.

Notwithstanding its ample collateral circulation, the lung is frequently the seat of small or large *infarcts*, especially of the hemorrhagic variety, usually situated peripherally and associated with brown induration. They may be single or double. Thrombus, rupture from overdistention, and infection of an embolus are the most common causes of this condition. When recent the infarcts are dark red, firm, resistant, and vary in size, sometimes occupying the greater part of a lobe. Sloughing and gangrene may follow. The pleura is congested and covered with exudate, the branches of the artery going to the lesion being filled with clotted blood. In old cases a pigmented scar may alone show the seat of a former infarct.

Pulmonary œdema, which is a transudation of serum into the alveoli and their walls, may be general or confined to the bases of the lungs. The organ is bulky, heavy, and pale, and pits on pressure. In some cases there is a partial consolidation, the lung appearing gelatinous and containing less air than normal. On section it exudes a clear, frothy serum. The dependent parts may be red in color and boggy.

Emphysema.—The dilatation of the air-vesicles is due to some weakness of the lung structure, as a congenital absence of elastic tissue, atrophy of the diaphragm, etc., and a dilating force, usually expiration, as chronic cough, certain occupations, etc. It may follow senile changes or a traumatism. The thorax is barrel-shaped and increased in its

anteroposterior diameter. The clavicles, the sternum, and the costal cartilages are prominent. The intercostal spaces are enlarged and the sternal fossa is deep. The back is rounded and the curve of the spine increased. The neck appears to be shortened. Dilated veins may be seen along the line of the attachment of the diaphragm. On removing the sternum, the anterior mediastinum is found completely occupied by pulmonary tissue, the pericardial sac being entirely covered; the lungs are large, light in color or only slightly pigmented. They are inelastic, do not collapse, but pit readily on pressure. To the touch they are soft, like feathers; expulsion of the air causes a crackling sound, and a paper-thin tissue remains. The edges are rounded and obtuse. Beneath the pleura, especially about the anterior margins and the lungs irregular in shape. The right heart is dilated and of a delicate bladder-like appearance may be seen, varying in size from that of a pea to a hen's egg (bullous emphysema). Amyloid bodies are sometimes found loose or embedded in the walls. Local emphysema is common around old fibroid or tuberculous lesions, the dilatation affecting also the bronchi. In the atrophic form, really a senile atrophy, the lungs are small, pale, dry, and pigmented, pit on pressure, and collapse when the thorax is opened. The chief seats are at the edges and the apices. The mucous membrane of the large bronchi may be rough and thickened; bronchiectasis may be present, and the inner surface of the lobe near the centre, enlarged air-vesicles hypertrophied; the pulmonary artery is enlarged and atheromatous. Emphysema may be vesicular, being confined within the dilated alveolar spaces, or it may be interstitial, the alveolar walls being broken. This is seen especially beneath the visceral pleura and may be produced *post mortem* by decomposition.

Gangrene (Pneumomalacia).—Gangrene may be circumscribed or diffuse, and affects usually the peripheral portions of the lower lobe rather than the central. It is by some supposed to be due to a specific bacillus. The gangrenous part is large, firm and solid or of a pulpy consistence, heavy, and of an ash-gray to greenish-black color. The outer tissues are intensely cedematous, next is an area of deep congestion, and then a cavity with shreddy, irregular walls containing a greenish fluid of a most offensive odor. The pleura may be inflamed and contain an abnormal amount of exudate, or it may be perforated, causing a pyopneumothorax. The gangrenous material gives rise to an intense bronchitis, the bronchial tubes being

obstructed by a thin, highly offensive pus or by mucus containing fatty acids, tyrosin, and leucin. The elastic threads disintegrate later than the remaining tissue, a fact of considerable diagnostic value. Embolic processes are common, abscesses of the various organs, especially the brain, being the result.

Parasites.—Certain parasites may infest the lungs. The *Aspergillus niger* and *fumigatus* are sometimes found in these organs, always associated with a pneumomycosis, and the *Mucor mucedo*, a yeast fungus, in cases of cancer. *Cysticercus cellulosa*, *Strongylus*, and *Distoma hæmatobium* are now and again found. Mackenzie¹ reports a case in a Japanese from Portland, Oregon, of parasitic hæmoptysis or infection with the *Distoma Westermanni* (*D. pulmonale*).

Pneumonia.—The chief forms of pneumonia are catarrhal (bronchopneumonia), chronic interstitial, and lobar (croupous and fibrinous). In cattle there is also found a very infectious variety known as pleuropneumonia. *Catarrhal pneumonia* is an acute or chronic inflammation of the lungs, involving both the bronchial tubes and air-vesicles, and due to extension of inflammation from neighboring parts, aspiration or inhalation of irritants, or micro-organisms,—*e.g.*, *Diplococcus pneumonia*, *Staphylococci*, *Streptococci*, the diphtheria bacillus, and the bacillus of pneumonia, or it may follow as a sequel to the infectious fevers. The lung is larger, heavier, and firmer than normal, and in my experience the lower lobe of the right lung is most frequently affected. On section the surface is somewhat dark red in color, distinctly mottled, and may drip blood. On palpation irregular nodular areas of gray hepatization can be felt, surrounded by crepitant tissue. The nodules, seldom larger than a hazel-nut, contain a central bronchiole surrounded by a grayish-red elevated area of consolidation and filled with tenacious purulent mucus which can be pressed out. Recent patches are red-brown in color, firm, smooth or finely granular, but later they are gray and soft. Minute hemorrhages are common near the affected areas and on the pleural surfaces. The pleura is bluish in color and rough. Emphysema is seen on the anterior and upper portions of the lung, especially within the inflamed areas. Fibroid changes seldom follow bronchopneumonia. Associated with this variety of pneumonia may be found enlarged bronchial glands, a dilated right heart, gastritis, enteritis, congestion of the

¹ *Jr. Amer. Med. Assoc.*, April 30, 1904, p. 1133.

liver and kidneys, and rarely pericarditis or pulmonary thrombosis. Catarrhal pneumonia in itself, except in the very young or the very old, is rarely fatal.

Chronic interstitial pneumonia may be due to acute inflammations (rare), tuberculosis, chronic pleurisy, chronic poisoning, or syphilis, and is usually unilateral. The chest on the affected side is sunken, deformed, and the shoulder depressed, the heart being drawn over to the affected side. The opposite lung is usually emphysematous. On opening the chest the affected part, more or less deeply pigmented, is seen to be almost airless, quite firm, and very resistant to the knife, lying back against the spine, and usually held by dense adhesions. On section grayish fibroid tissue of variable amount is found, which may be more or less dilated. The unaffected lung is much enlarged, occupying the greater portion of the mediastinum. The heart is hypertrophied and the blood-vessels may be atheromatous. Associated lesions are tuberculosis or syphilis, a cavity of the apex, pulmonary aneurism, and amyloid disease of the viscera.

Croupous (lobar) pneumonia is discussed on p. 327.

TABLE SHOWING DIFFERENCES BETWEEN CROUPOUS AND CATARRHAL PNEUMONIA.

CROUPOUS PNEUMONIA.	CATARRHAL PNEUMONIA.
1. Whole lobe usually affected; hence the name lobar pneumonia.	1. Lobules affected; hence the name lobular pneumonia.
2. No areas of healthy lung tissue in affected lobe; other lobes healthy, but may be congested, especially adjacent portions.	2. Irregular areas of lung tissue in various stages of degeneration intermingled with normal lobules.
3. Lung weighs much more than normal. An entire lobe may sink in water.	3. Lung weighs but slightly more than normal. An entire lobe will float on water, though small portions may sink.
4. Microscopic appearance varies according to stage. Much fibrin; hence the name fibrinous pneumonia for this condition.	4. Microscope reveals three zones: central, a small bronchus; middle, a desquamative area containing many cells, but little or no fibrin; outer, a zone of congestion. Hence the synonym bronchopneumonia.
5. An extensive fibrinous exudate on the pleura covering the affected area ("bread-and-butter" pleurisy); hence the name pleuropneumonia for this affection.	5. Exudate slight, if present.

TABLE SHOWING DIFFERENCES BETWEEN CROUPOUS AND CATARRHAL PNEUMONIA.

CROUPOUS PNEUMONIA.	CATARRHAL PNEUMONIA.
6. Pneumococcus usually found; Rose-now grew it from the circulating blood nine times out of ten.	6. Pneumococcus rarely found.
7. Usually at base and posteriorly.	7. Usually at the termination of the smaller bronchioles and anywhere in the lung.
8. Usually one-sided.	8. Usually on both sides and associated with other diseases.
9. On section the lung varies according to stage, the marbled appearance being especially seen in the third stage. Notice the fibrinous plugs.	9. On section the lung is congested. Small, angular, irregular patches, the central portion being the oldest, are seen.
10. Sputum,—so-called rusty sputum.	10. Sputum more purulent.
11. Lung lesions of same age.	11. Diseased portion of the lung varies; some spots are old, some are new, the oldest being around the bronchioles; healthy tissue between affected areas. Caseous pneumonia, really a form of catarrhal pneumonia, is due to the action of a toxin, as from the tubercle bacilli. In phthisis there may be small areas of croupous pneumonia.
12. Experimental production difficult or impossible.	12. Capillary bronchitis and catarrhal pneumonia are, pathologically, practically the same. Seen especially in the very old and the very young.

Pneumonoconiosis.—This fibroid condition of the lung, often associated with tuberculosis, and produced by the inhalation of particles of mineral or metallic substances, occurs in persons employed in such occupations as coal-mining, the manufacture of pottery, steel-grinding, stone-cutting, tobacco-sorting, etc. Various names are thus applied to it, depending upon the nature of the inspired dust,—*e.g.*, anthracosis, siderosis, calcicosis, lithosis, silicosis, etc. Unless, as is frequently the case, emphysema coexists, the affected lungs are harder, firmer, often smaller than normal, and usually of a blue-black, yellowish, or buff color, affording a striking contrast to the lung of a child. Even when the inspired dust is white, the lungs are apt to be of a dark color, due to the carbon and the altered blood pigment. In advanced stages of anthracosis an ink-like juice may exude from the

cut surface. In siderosis, caused by oxide of iron, the lung is of a reddish color. On section condensed portions of highly fibroid tissue are seen, with numerous raised points, which give it a coarse, granular appearance. These raised points are small, thickened, fibroid bronchial tubes protruding above the surface. The deposits are found microscopically everywhere along the course of the lymphatics. The pleura is usually adherent, thickened, and pigmented. The signs of chronic bronchitis are present, though the mucous membrane of the bronchi remains unpigmented. The bronchial and peribronchial glands as well as the peribronchial lymph-nodules are frequently intensely pigmented, and may be either soft or indurated. The liver and spleen may also be pigmented. True osseous formations, coral-like in shape, may be found in the lungs.

Traumatism.—In accidents foreign bodies may enter the lungs. In one case reported ¹ a woman fell from a ladder and a broom-handle passed through her chest from one axilla to the other; she recovered.

Tuberculosis.—See p. 341.

Tumors.—The benign tumors of the lungs are fibroma, adenoma, osteoma, and chondroma. Hydatids are common in countries infested by that disease, and may attain considerable size. Dermoid cysts are found, but very rarely. Primary malignant growths are rare, involving one lung only, while secondary tumors are comparatively common, affecting both lungs. Carcinoma may originate in the epithelium of the alveoli, the bronchi, or the mucous glands. Secondary cancer is more frequent in women than in men and may be scirrhous, encephaloid, epitheliomatous, or colloid. Endothelioma starts from the lymphatic apparatus. Primary spindle-celled sarcoma and melanosarcoma are found, which often extend to the liver. The tracheal or bronchial glands are sometimes the seat of metastatic growths. In malignant diseases of the lungs, pleurisy, generally of a hemorrhagic type, is commonly present.

PLEURA.—*Empyema (Pyothorax).*—Suppuration in the pleural cavity is usually accompanied by the presence of air, and is due to pleurisy, extension of inflammation from neighboring organs, trauma, and micro-organisms, especially the tubercle bacillus, the *Diplococcus* of pneumonia, and the *Streptococcus* and *Staphylococcus pyogenes*. The pleuræ are much thickened; their surfaces are irregular and cov-

¹ FRANKE, *Arch. f. klin. Chirurgie*, 1903, vol. lxxi, no. 2, p. 543.

ered with a yellowish-green exudate of varying thickness. There may be evidences of more or less extensive hemorrhage, also erosions, fistulæ, or perforations. In severe cases there may even be gangrene. The pus separates into two layers,—a clear, greenish-yellow serum above; a thick, cream-like pus below. It has a heavy, sweet odor, and is rarely fetid unless gangrene supervenes. A sterile culture on ordinary media suggests tuberculosis.

New Growths.—The benign tumors of the pleura are fibroma, osteoma, chondroma, and lipoma. Endothelioma originating from the lymphatics may cause a diffuse thickening of the pleura. Teratoma has been reported, in one case attached to the tenth rib, aorta, and vena cava. Carcinoma and sarcoma occur, usually as secondary deposits. Hydatid cysts are very rare in this country.

Pneumothorax.—This is the presence of air in the pleural cavity, and may be due to traumatism, tuberculosis of the lung rupturing into the pleura, other infectious granulomata, and malignant growths. The thorax is usually distended and the intercostal spaces may be obliterated. The introduction of a trocar allows the escape of the air. Unless pneumothorax kills suddenly, it is always accompanied by a pleurisy, generally of a purulent variety. The pericardium and heart are pushed or drawn to the opposite side. The lung is usually compressed and carnified and may be adherent to the chest wall at the apex, this site being frequently the seat of caseous nodules or cavities. Localized pneumothorax is probably often overlooked at the postmortem.

Hydrothorax.—This is part of a general dropsy, and is usually due to chronic valvular disease, chronic Bright's disease, cirrhosis of the liver, cachexia, or pressure on the azygos veins. As a rule, it is bilateral, although not equal in extent in the two sides. The lungs are compressed and the pericardium and heart pushed upward.

Hæmothorax.—This is generally due to trauma, sometimes to cancer of the lung or pleura, also found with tuberculosis, purpura, scurvy, leukæmia, cirrhosis of the liver, and granular kidneys.

Chylothorax.—An effusion of chylous fluid is rare, and is due to traumatic rupture or obstruction to the thoracic duct.

Pleurisy.—Inflammation of the pleura may be acute or chronic. It is due to exposure to cold and wet, traumatism, extension of inflammation from neighboring organs, pyogenic micro-organisms, many infectious fevers, infectious granulomata, or malignant tumors.

Acute pleurisy is classified by the character of its exudate into serous, serofibrinous, fibrinous, purulent, and hemorrhagic. In all, the serous membrane is at first red, sticky, and lustreless, and the vessels are dilated; later it becomes pale, thick, and rough. The pleural cavity may contain an inflammatory exudate, varying in amount from a few cubic centimetres to one or more litres, resembling that seen in other serous cavities. The serofibrinous exudate contains more fibrin but less fluid. Coagula may be found *in situ*. The characteristic of the fibrinous exudate is the so-called "bread-and-butter" appearance of the pleura. The deposit varies in thickness from a millimetre to a centimetre or more. *Purulent pleurisy* may follow the acute form or may be primary. It is frequently associated with tuberculosis. The serous membranes are covered with a creamy exudate and the cavity contains from a few cubic centimetres to a litre or more of greenish-yellow, offensive pus. In the tuberculous exudate Ravaut and Widal have found a predominance of lymphocytes, while other effusions contain polymorphonuclear neutrophiles. *Hemorrhagic pleurisy* may be due to asthenic conditions, as tuberculosis and cancer, or may occur in perfectly healthy individuals, from wounds to the lungs during aspiration by the mixing of any fluid present with blood. The pleural cavity contains blood, usually fluid and varying considerably in density. The serous membranes are generally inflamed and stained with blood-coloring matter. *Chronic pleurisy* with effusion may persist for months without undergoing any alteration in its character. The post-mortem appearances are very similar to those of an acute pleurisy. *Chronic dry pleurisy*, resulting from the partial absorption of a pleuritic exudate and the organization of the remainder, occurs usually at the base, causing marked flattening of the chest. Small pockets of fluid are often found and it is frequently impossible to separate the layers of pleura. The lung is compressed, airless, and fibroid. *Primitive dry pleurisy* may be limited or universal, unilateral or bilateral, and may be accompanied by a similar condition of the pericardium and peritoneum. The layers of the pleura are firmly adherent to one another and, especially about the lower lobe, are much thickened. In tuberculous cases reddish-gray fibroid masses and small tubercles are present between the layers, sometimes infiltrated with serum. The bronchi may present marked dilatations and the pulmonary tissue be more or less sclerosed. In diaphragmatic, encysted, and interlobar pleurisy the morbid anatomy is similar.

CHAPTER X

CRITICAL EXAMINATION OF THE ORGANS OF THE ABDOMINAL CAVITY

THE OMENTUM, MESENTERIES, AND PERITONEUM.—The superficial examination of the peritoneum having been made during the general inspection of the abdominal cavity, any thickened regions or surface irregularities are now felt with the index-finger and thumb, and, should anything abnormal be found, such areas are at once incised and critically studied. A regular order should be observed in the study of the peritoneum,—say, from above downward,—so that nothing of importance shall escape the attention of the operator.

The peritoneum covering the diaphragm may become inflamed as part of a general peritonitis, or show the presence of aberrant pulmonary tissue, cysts, filaria, actinomycosis, lipomata, fibromata, endotheliomata, secondary tumors, etc. The *Distoma hepaticum* has been found embedded in the peritoneum of this region. Subdiaphragmatic (subphrenic) abscesses are not uncommon, especially on the right side, and may rupture into the pleural cavity or remain localized. In Körte's¹ sixty cases, which were operated on by himself, infection was found to originate most frequently from the vermiform appendix. Among the other causes giving rise to this condition may be mentioned: (a) Perforation of a gastric or duodenal ulcer (most common cause), typhoid ulcer; (b) Abscess of the liver and pancreas; Rupture of the gall-bladder or bile ducts; inflammations about the kidney. (c) Diseases of the lower ribs, pleura, and mediastinum.

A volvulus or hernial opening in the omentum may require removal, although, as a rule, it is better to make examination of any abnormalities or pathologic lesions that appear and afterwards to remove the omentum along with the transverse colon. In thin subjects the separation of the omentum into its four layers, one anterior and three posterior, forms a striking picture, especially if studded with recent miliary tubercles or the wild strawberry-like nodules of a sarcoma. The hæmolymp-h-nodes in man and in animals have recently been studied with special care by Warthin. They are found in greatest

¹GRÜNEISEN, *Arch. f. klin. Chir.*, 1903, vol. lxx, p. I.

numbers in the cervical and prevertebral regions, in the neighborhood of the adrenal vessels, along the brim of the pelvis, and in the root of the mesentery. The hæmolymph-nodes are thought to be concerned in the destruction of red blood-corpuscles, and present pathologic features, especially in the various anæmias and leukæmias.

The mesentery may be shortened by contraction, as following granulations; or lengthened, as by traction upon the bowel in a strangulated hernia, diastasis of the recti following pregnancy, or in enteroptosis. Congenital redundancy of the sigmoid flexure may be the cause of chronic obstipation and hypertrophy of the colon. Hemorrhage may take place into the mesentery in phosphorus poisoning and acute yellow atrophy of the liver. The glands are red and swollen in enteritis, especially in typhoid fever, where they may be very numerous and break down. They afford a favorable spot from which to secure cultures for the different varieties of colon and typhoid bacilli. When the glands become tuberculous, they may become very large and often caseate. In children they are normally proportionately larger than in adults. All statistics bearing upon tuberculous infection of these glands are extremely useful at the present time, in order to assist in determining the primary routes of infection and to place upon a sound scientific basis the relation of tuberculous milk to infant mortality. One also finds here enlarged glands in the leukæmias, particularly lymphatic leukæmia, and Hodgkin's disease. By occlusion of vessels in this region the mesentery may become dark in color and cause many feet of the small intestine to become gangrenous. It may be wholly converted into a mass of fat. Search should be made for calcified tubercles, tumors, parasites, chylocysts, etc. Hemorrhagic infarcts are sometimes seen. Ortner has recently called attention to arteriosclerosis of the mesenteric vessels producing conditions in the gastro-intestinal tract clinically analogous to angina pectoris. In one of my post-mortems the infiltrated blood into the mesentery from a ruptured aneurism of the superior mesenteric artery showed the distribution of the blood to the mesenteries of the jejunum, ileum, cæcum, vermiform appendix, colons, and rectum. It is well to remember that the duodenum is not supplied with a mesentery.

Secondary cancer of the peritoneum is found especially in the female sex, more often after the menopause than before, and is most often the result of metastasis from cancer of the stomach or ovaries. It is spoken of as "miliary carcinosis" because the nodules are small,

spherical, and diffuse. The peritoneum is pale, thickened, with marked fibrinous deposits, which form adhesions to neighboring viscera, producing the condition spoken of as carcinomatous peritonitis; the omentum is indurated, and forms a mass transversely across the abdomen; the bowels are often firmly matted together. Ascites is usually found; the amount of fluid present may vary from a few ounces to several pints. In some cases of colloid cancer the secondary growths are of considerable size.

Among the micro-organisms which have been demonstrated in acute general peritonitis may be mentioned the *Streptococcus pyogenes*, *Bacillus coli communis*, *Staphylococcus aureus*, *Streptococcus lanccolatus*, *Bacillus proteus*, *Bacillus pyocyaneus*, and, more rarely, the *Gonococcus* (in the female) and anthrax and typhoid bacilli. The cause of the peritonitis is usually a perforation of the bowel, frequently the appendix. It may be: (a) Serous. (b) Serofibrinous. (c) Fibrinous. (d) Purulent. (e) Putrid. (f) Hemorrhagic. (g) Ulcerative. In acute general peritonitis the peritoneum has lost its lustre, is opaque, and is covered with an exudate varying with the type of the disease. The intestinal coils are, in places, distended, in other spots displaced and compressed, reddened, and glued together with lymph or fibrinous adhesions; their walls are easily torn. The serous membrane may be easily separated from the muscular coat. In peritonitis due to perforation, the peritoneum and its contents are discolored by the fæces, while the peritoneal cavity contains gas, which escapes with a hissing noise when an opening is first made in the abdominal cavity.

Causes of chronic peritonitis: (a) Follows the acute form. (b) Tuberculosis. (c) Extension of inflammation from the abdominal or pelvic organs. (d) Cancer. *Classification.*—(a) Local adhesive. (b) Diffuse adhesive. (c) Proliferative. (d) Hemorrhagic. (1) *Localized peritonitis* occurs about the spleen, diaphragm, liver, gall-bladder, intestines, mesentery, and pelvic organs. Bands of connective tissue more or less firmly organized bind the various organs together, producing marked alterations in the appearance and position of the parts. The peritoneum is thickened and puckered. (2) *Diffuse adhesive peritonitis* follows acute inflammation, of either a simple or a tuberculous nature. The abdominal cavity is often obliterated; the intestinal coils are firmly matted together by the plastic exudate, which eventually becomes converted into bands of fibrous tissue. In this variety I have seen a central cavity produced which contained the entrance and

exit of several coils of the small intestines, the functions of life having apparently been carried on for a considerable time. (3) In the *proliferative* form there is great thickening of the peritoneum, which is opaque and white in color. The omentum is usually rolled into a thick mass between the stomach and the colon. The liver and spleen are the subjects of a chronic capsular inflammation; both are usually smaller than normal, with thickened, wrinkled capsules. There are seldom many adhesions, and serous effusion may be present in the abdominal cavity. The intestinal wall is greatly thickened and the mucous membrane of the ileum is thrown into folds. Nodular thickenings may be present and be mistaken for tubercles. (4) The *hemorrhagic* form occurs particularly in cancerous and tuberculous conditions. Layers of new connective tissue form on the surface of the peritoneum; they contain new blood-vessels, from which the bleeding occurs. It is commonly a circumscribed process. Orth compares it to chronic internal hemorrhagic pachymeningitis.

In order to obtain more room for the examination of the abdominal cavity and a more favorable opportunity for the subsequent inspection of the gall-bladder, biliary ducts, and portal vessels, the attachments of the diaphragm to the ribs on the right side may now be severed with the knife and the liver rolled over into the thoracic cavity of this side. (Fig. 121.)

THE SPLEEN.—The spleen varies greatly in size and weight, even during health and in the same individual at different times. Its normal weight is about five ounces and the measurements are one and one-fourth by five inches. I have removed a spleen which weighed only one hundred and eighty-six and one-half grains (senile atrophy) and another weighing over seven pounds (malarial enlargement). Enlargement of the spleen is seen in sepsis, typhus, typhoid, leukæmia, syphilis, etc. Remember that the spleen affords a favorable opportunity for the study of micro-organisms, especially of the typhoid and colon groups. The spleen may now be removed from the abdominal cavity, although some pathologists recommend its excision later in connection with the pancreas. It is easily found by passing the hand along the left under surface of the diaphragm from the eighth to the eleventh rib, well towards the side and beneath the cardiac end of the stomach. Usually but little force is necessary to bring it into view, with the gastrosplenic omentum and splenic artery and vein still intact. These parts are then cut or torn with a sort of twisting movement. In some

cases the spleen is so soft that lacerations are very easily made in its substance by the fingers. These should not be mistaken for traumatic rupture of the organ, as from a kick, or for the rupture that sometimes, although rarely, results from disease. Occasionally the spleen is absent, its place being taken by a large number of supernumerary spleens or by an increase in the hæmolympf-nodes of the abdomen. The spleen may be found attached to the surrounding parts, or a wandering spleen may be found displaced as far as the left inguinal region. Before detaching the spleen, examine the course of the splenic artery for aneurisms, supernumerary spleens, enlarged glands, etc. When this has been done, the artery may be divided and the organ removed from the body. Notice whether or not the capsule is thickened, wrinkled, or opaque; it should be thin, smooth, and transparent. At times the capsule, from which trabeculæ extend into its pulp, appears as if melted tallow had been poured over the surface and allowed to harden.

Now lay the spleen, resting upon the hilum (posterior surface), on the table, fix it with the left fingers, and with one stroke make a deep incision in its longest diameter. The spleen being turned, incisions transverse to those made upon the anterior surface may be made for further investigation. The color of the normal spleen is dark red, but somewhat darker and of a bluish tinge in children; it may be brownish, from the presence of hæmosiderin; or yellow, as in jaundice or in the new-born, due to bilirubin crystals; or streaked with blue, owing to the presence of melanin. Coal-dust may be found in the spleen, having probably entered the circulation through the rupture of a peri-bronchial gland. Hyperplasia of the fibrous stroma in cases of chronic enlargement of the organ, as in malaria and leukæmia, may give the spleen a grayish tinge.

The structure of the splenic tissue may then be examined, and the changes in the splenic pulp, the Malpighian bodies, and the connective-tissue trabeculæ noted. The elastic tissue of the spleen may be destroyed, as in tuberculosis, or hypertrophied around the capillaries, as in leukæmia.¹ A disturbance of the local circulation may lead to various changes. Oligæmia is marked by the light-red or grayish-red color of the spleen, with wrinkling of the capsule and prominence of the trabeculæ. Obstruction to the portal circulation causes congestion. Hyperæmia due to congestion in cardiac diseases is

¹ FISCHER, *Virchow's Archiv*, 1904, vol. clxxv, no. 1, p. 69.

characterized by an enlarged, hard, dark-red splenic pulp, with smooth surface on section and thickening of the capsule, trabeculae, and vessel-walls. In cirrhosis of the liver, particularly the hypertrophic form, the spleen is found to be usually enlarged, the capsule smooth and tense, and the splenic substance soft and friable. Infarcts of the spleen are common, and are usually wedge-shaped, with the apex towards the hilum. They vary in size from that of a pea to that of a cherry, and may at times include half of the spleen; they may become infected. Anæmic infarcts are of a cloudy-yellow color, while the less common hemorrhagic infarcts are very dark red, and later become yellowish red, and even whitish yellow as the coloring-matter of the blood disappears. Acute splenitis, resulting in the formation of pus, is not frequent. An acute proliferative splenitis, the cause of the so-called splenic tumor, is characterized by enlargement of the spleen, with the capsule markedly tense, and the pulp, on section, being of a vivid red, at first darkish and later somewhat lighter. The pulp is soft and exudes on section, thus concealing the Malpighian bodies. Fibrous, productive, or chronic inflammation of the spleen causes the chronic splenic tumor, recognized by the large size of the organ, which is hard, of a light or dark brownish hue, with thickened trabeculae, that may appear as streaks through the splenic substance. The *Bacillus aerogenes capsulatus* was shown by Welch to be the probable cause of many cases previously reported as malignant œdema, emphysematous *gangrène foudroyante*, etc. Some of the deaths supposedly caused by the entrance of air into the veins may likewise have been due to this infection. At the postmortem, the muscles, the blood in the heart and great vessels, and the other internal organs may contain bubbles of gas. It has been known since 1857 that the *Infusorium balantidium coli*, an oval-shaped ciliated organism, may cause intestinal infection in man and the orang-outan. A leukæmic spleen with its umbilicated nodules is hard and of a reddish-gray color, sometimes weighing twenty pounds. Miliary tubercles, with caseation, and other tumors of the spleen occur. In the colored race miliary tubercles at times do not undergo caseation and may attain the largest size of any developing in the body. I have not infrequently seen them as large as wild cherries. The arteries in the splenic pulp rarely show macroscopic atheroma, although the tissue of the spleen may be infiltrated with the salts of lime. The most important of all the forms of retrocedent disturbances of nutrition

of the spleen is amyloid degeneration. In this disease the spleen is firm and inelastic, so that the pressure of the finger leaves a decided mark. Amyloid degeneration of the pulp is characterized by the smooth, shining, almost transparent appearance of the cut surface, while the so-called sago spleen—the amyloid degeneration of the Malpighian bodies—is recognized by the enlargement of the lymph-nodules, which on section appear somewhat transparent and scattered over the cut surface. The amyloid reaction would be more frequently demonstrated if Lugol's solution were applied as a routine practice. A small piece of the spleen should also be tested for iron with ammonium sulphhydrate. The *Pentastomum denticulatum* and echinococcus cysts of the spleen are sometimes found, as well as multiple angiomas, cancer, and sarcoma, the latter occurring, in rare instances, primarily in this organ. On healing, gummata leave behind stellate scars of varying size.

THE INTESTINES BELOW THE DUODENUM.—When the exudation in the peritoneal cavity is fibrinopurulent and has a fetid odor, its source should be sought in a perforation of the intestine, although it may have originated elsewhere, as from the uterus or adnexa. If the peritoneal fluid suggest perforation, the gut may be examined under water, as pressure on the intestine will then cause bubbles of gas to appear. The site of perforation is usually marked by an area of fibrinous exudation, which may be so dense as to occlude the opening; or there may be several perforations, as in a case of typhoid fever. In duodenal ulcer the contents will be stained with bile. Erysipelas and poisoning by arsenic should be remembered as occasional, though rare, causes of intestinal ulcer. The exterior of the entire intestinal tract should be critically inspected, starting from below and going upward, and any adhesions should be very gently broken down, care being taken not to make an artificial opening in the bowel,—an accident quite apt to occur in certain diseased conditions. When, however, the intestines are extensively agglutinated, as in appendicitis, tuberculous peritonitis, etc., the parts may often be better studied by first carefully noting their relations and then removing them *en masse*. Observe whether there be distention or contraction of the bowels. Distention is marked in cases of stenosis or strangulated hernia, and when a large amount of feces is contained within the intestines. Contraction is noted in enteritis and after starvation. Localized constrictions may be due to bands of peritoneal adhesions. A Meckel diverticu-

lum¹ should not be overlooked, and its omphalomesenteric attachment going to the umbilicus should be searched for. It usually comes off at right angles from the ileum, about three feet from the ileocæcal valve. Its proximal end may consist of several fingers or glove-shaped subdivisions. It is present in from one to two per cent. of the cases examined. The duct sometimes remains patulous until puberty, or may never close. The lymph-follicles may be injected, and are noticeable as irregular, whitish lines which, when pricked, exude a drop of milky fluid,—chyle.

A proper examination of the intestines can be made only after they have been removed from the body. For this purpose the intestine is doubly ligated in three places,—viz., (1) at the end of the duodenum and the commencement of the jejunum; as this portion of the intestinal tract is usually empty, this ligature is often omitted; (2) in the ileum, several feet above the ileocæcal valve; and (3) at the end of the sigmoid flexure and the commencement of the rectum. The method of doing this is as follows: First, the contents of the intestine are milked backwards by catching the intestine between the thumb and forefinger, and a loop of string is then carried by the nail of the index-finger (Fig. 95) or a pair of forceps through an opening in the mesentery made with an instrument or the fingers and the intestine is ligated. A second ligature, far enough from the first to allow of the gut being divided between them later, is then to be securely applied (Fig. 96). Care should be taken that the ligatures hold tightly without slipping, so that no opportunity be afforded for the escape of fecal matter. The large intestine is then cut between the ligatures, and its proximal extremity grasped and the mesentery severed by a sawing or fiddle-bow movement close to its intestinal attachment along the whole extent of the colon, until the ligatured spot in the ileum is reached, when the small intestine is incised between the ligatures. This portion is then removed to the sink or bucket preparatory to being

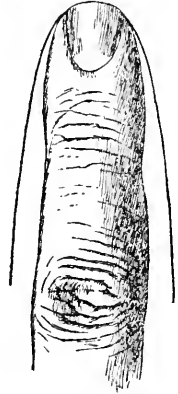


FIG. 95.—Method of passing the string through an opening in the mesentery previous to tying it.

¹ See an interesting article by ZONDEK, *Berliner klin. Wchnschr.*, August 28, 1905, upon this subject. A case of congenital umbilical hernia containing Meckel's diverticulum is reported by LANDMAN, *Lancet*, November 11, 1905.

cleansed (Fig. 97), and the remainder of the ileum and the jejunum is removed, as seen in Fig. 98, and also placed in the sink or bucket.

The intestines are opened either by pushing them into the open blades of the scissors or, better, by thrusting the enterotome or scissors through the bowels along the line of the mesenteric attachment (Fig. 99). Meckel's diverticula, like Peyer's patches, usually occur opposite the mesenteric attachment and, therefore, on the free anterior border of the ileum; hence the reason for opening the bowel at its mesenteric attachment. The ileocæcal opening is guarded by the two valves of Bauhin, the superior one normally overlapping the inferior. Each valve is to be examined on its ileac and cæcal surface. The ileocæcal cut is to be made between the two valves; this is readily done by dissecting the ileum down to the valves, and then, as is usual, pushing the enterotome through the opening in the direction in which the intestinal contents pass,—*i.e.*, towards the cæcum and between the two valves. The appendix is better opened opposite its mesenteric attachment, contrary to the rule in the case of the intestines. The situation of the valve of Gerlach is very variable. If a competent dead-house assistant is at hand, the opening of the bowel may be intrusted to him, as it saves the operator's time and prevents his hands from becoming impregnated with the disagreeable fetid odor of the gut. The assistant is instructed to save some of the contents for microscopic study and to call attention at once to any abnormalities observed. He opens all the intestinal tract except the ileocæcal valve and the vermiform appendix, which are to be incised and examined by the pathologist himself. The small and large intestines, after being freed of their contents, should be measured and weighed apart, the ileocæcal valve counting with the large intestine. After washing, the entire bowel is arranged, mucous surface upward, upon the post-mortem table, so that the pathologist may at a glance examine the intestines throughout their entire extent. In cases in which haste is a matter of importance, the intestines need not be removed from the body, but at the end of the autopsy the region of the ileocæcal valve is opened as well as the sigmoid and rectum, and, if no lesions are discovered here, the remaining portion is left unopened, unless palpation or inspection in the preliminary examination of the abdominal cavity has led one to suspect a lesion in other situations. If a spigot is at hand, the open end of the intestine may be drawn over it, and the water allowed to run through until clean. Passage of water from a stopcock to cleanse

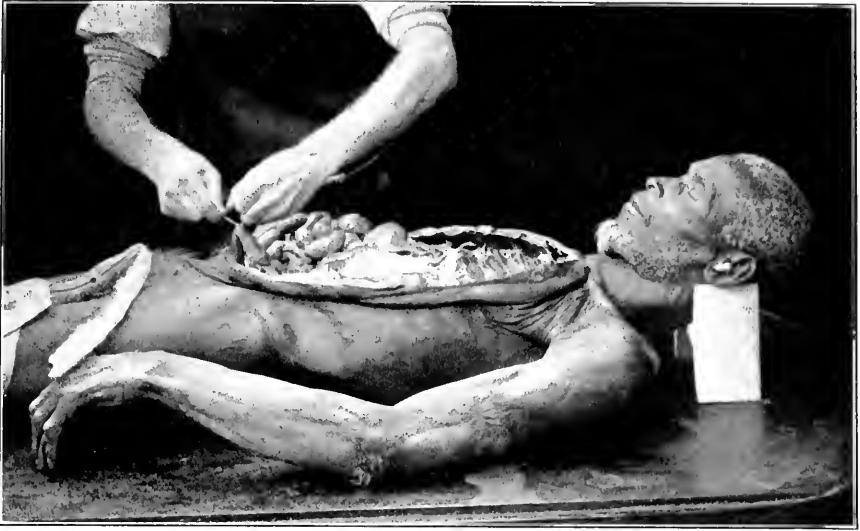

FIG. 96.—Method of tying the intestines preparatory to their removal. They are tied in two places, a foot or so above the ileocecal valve.



FIG. 97.—Bucket method of opening and cleansing intestines, especially useful in private cases.



FIG. 98.—Method of removing the small intestines. They are elevated and traction is made on the mesentery, which is cut as close as possible to its attachment to the bowel.

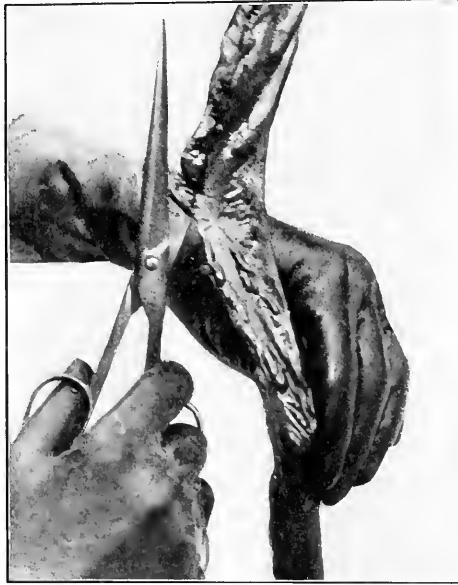


FIG. 99.—Opening of the small intestine after its removal from the body, the incision being made with the enterotome along the mesenteric attachment.

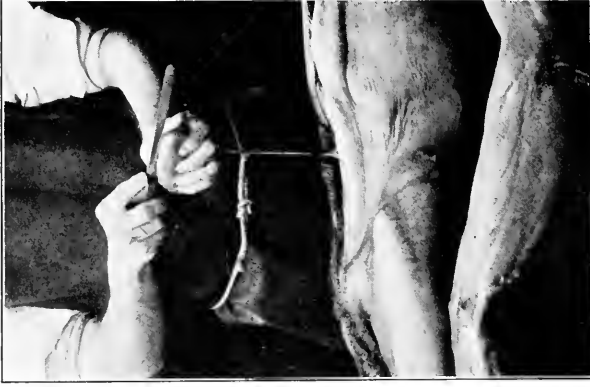

FIG. 100.—Method of incising the kidney with its ureter still attached



FIG. 101.—Method of opening the kidney. The organ is held in the left hand with its hilum downward, and an incision is made with a brain-knife along its upper convex border and more than half through the renal substance. It is then reversed (Fig. 102) and the incision continued until the gland is nearly, but not quite, divided. In this manner there is no danger of cutting the hand.

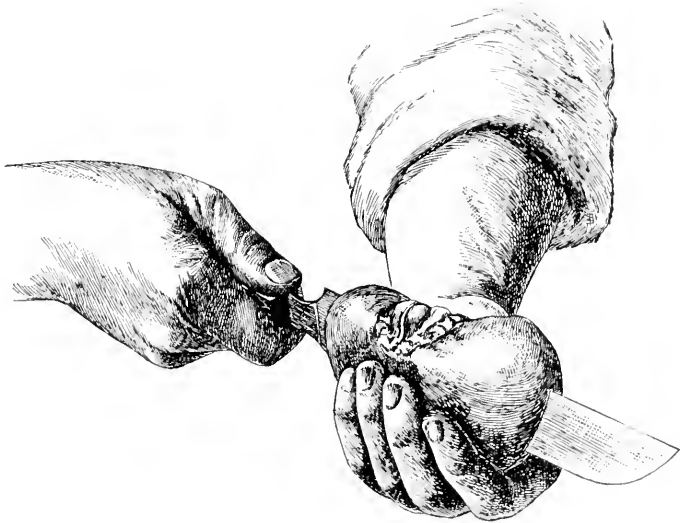


FIG. 102.—Method of opening the kidney in such a manner as not to injure the hands of the operator.



FIG. 103.—Method of removing the capsule of the kidney with the bare hands.



FIG. 104.—Method of removing the capsule of the kidney with the knife when gloves are employed.

the intestines is not, however, always a proper procedure, as it may injure the mucous membrane, rupture a Peyer patch in a case of typhoid with ulceration, loosen some of the intestinal contents, change their consistence by admixture with water, etc. The bucket method of opening and cleansing the intestines—a very useful one in private cases—is illustrated in Fig. 97. In warm weather these viscera are particularly liable to undergo rapid decomposition after exposure for even a short time to the air.

The color of the normal mucous membrane of the intestine is light gray, varying according to the contents of the bowel and the amount of blood present. Congestion of the small capillaries causes a general redness, while injection of the larger vessels produces red streaks; the two conditions may occur together. The greater the distention of the bowel, the paler is the grayish shade of the mucous surface, and if the contents of the gut are bloody the walls are dark red. This diffused color is to be distinguished from the redness due to hyperæmia, occurring in inflammations, congestions, etc., by the marked injection of the capillary blood-vessels which is seen in the latter case. Even the vessels of the submucosa are observed to be overfilled. Thickening of the walls as well as partial overgrowth of the mucous membrane, often in the form of small polyps, may be observed in many of the chronic inflammations of the intestines. Enlarged villi, individually made out with the naked eye, may be noted in some cases of inflammation. (Orth.) In the leukæmias the lymphatic nodules of the intestinal tract may be greatly hypertrophied and the intestinal wall may be the seat of amyloid degeneration when one of the usual causes of amyloidosis is present.

The tabulation found on p. 354 will be found of use in distinguishing typhoid and tuberculous ulcers.

In cases resembling typhoid fever clinically the finding of paratyphoid organisms may explain the occasional failure of the Widal test. A most careful study of all typhoid cases should, therefore, be made where the Widal reaction was not obtainable during life. The anatomic findings in the cases of paratyphoid fever¹ which have come to autopsy are those of septicæmia with splenic swelling and at times ulcers which resemble those of dysentery and do not seem to affect the Peyer's patches.

¹ WELLS and SCOTT, *Journal of Infectious Diseases*, vol. i, January, 1904, p. 72.

Whether during life an enema may, by reversed peristalsis, be carried to the stomach and then vomited is an interesting but debated question which I believe should be answered in the affirmative. It is very difficult by pressure to force liquid past the ileocæcal valve, but in relaxed conditions, as in cholera, this is perfectly possible. The problem is interesting as bearing on the possibility of a gastrocolic fistula and reversed agonal invaginations.

Mayo Robson¹ has reported a case of peptic ulcer which developed in the jejunum forty months after the performance of a gastroenterostomy. A rare form of intestinal ulcer, not seen, however, in America, is that found in ergotism in Europe.

An abundance of fæces in the large intestine indicates constipation, which occurs in an extreme form in partakers of opium, where one may find scybalous masses lying in pouches in the transverse colon as hard and dry as if they had been retained there for many weeks or even months. A similar condition is sometimes found in old persons subject to chronic constipation; the masses may even become encrusted with salts of lime. Distention of the small intestine shows that considerable food was recently taken. When the lacteals are well dilated, some three and a half hours have elapsed since the taking of the food which has reached this portion of the intestine. Pavlof finds that psychical secretion of the gastric juices varies markedly according to the character of the food ingested. When the fæces are light in color, an absence of bile is shown; when dark or light red, blood is probably present, although it must be remembered that medicines, such as hæmatoxylin, may give a similar appearance. When dark or black, the presence of iron or bismuth may be suspected; if yellow, the possibility of rhubarb having been administered should be considered. Occult blood may be found.

Gall-stones and worms may be found anywhere in the intestinal tract, but most frequently above the ileocæcal valve and in the lower rectum. In one of my cases I found, not far apart, two *Tania medio-canellata*, their heads being firmly attached to the mucous membrane beneath folds of the valvulæ conniventes at the end of the duodenum. A specimen of ascarides in the Wistar and Horner Museum of the University of Pennsylvania shows where one of them had entered the bile ducts. As these worms try to escape from the

¹ *Ann. Surg.*, August, 1904, p. 186.

body after death, this may be an instance of post-mortem invasion. Seat-worms are found in the lower rectum. Packard removed *post mortem*, at the Pennsylvania Hospital, a specimen of *Tania nana*. The *Anchylostoma americanum* has been seen several times in Philadelphia. Loeb and Smith have recently pointed out the presence of a substance inhibiting the coagulation of the blood in the *Anchylostoma caninum*. Of course, any of the varieties of intestinal worms seen in man may be found at a postmortem, but it is surprising how few cases are described in the post-mortem notes of our hospitals. The foulest odors arise in icterus and dysentery, while in cholera the odor may be hardly perceptible. True intestinal sand may be found, and is largely composed of the phosphate and carbonate of calcium. It is most often caused by a purely milk diet or one of milk and lime-water. False sand, composed of biliary and fecal concretions, is more common, being seen especially in the vermiform appendix. Salol, when taken medicinally, may cause the formation of crystalline enteroliths. In Brossard's¹ case, one of a number of calculi weighed two grammes. The tumors of the intestines are myomata, fibromata, polypi, lipomata, adenomata, carcinomata, and sarcomata, the latter variety being of rare occurrence. (Plate IV.)

In hemorrhage of the bowel the bleeding may be localized or diffused. In the former variety petechial spots or ecchymoses are found on the mucous membrane. The mucous membrane surrounding the hemorrhages may be normal in appearance or show the results of active or passive congestion. In diffuse hemorrhages the blood is free in the bowel or may be extravasated into the mucous membrane. In the former case it is brownish black or black in color and usually semi-liquid or tarry. In the latter case the extravasated blood is in slate-colored or black patches.

THE APPENDIX.²—The average length of the appendix is about three inches, although it may measure as much as six. There is a mesentery often reaching to the tip and containing fatty deposits. The appendix is rarely absent and probably never double. Its usual direction is towards the brim of the pelvis, but it may point in any direction. Appendicitis is most common in males and in early adult life, and is favored by fecal concretions, but rarely by foreign bodies. Among

¹ *Bull. gén. de thérap.*, 1897, vol. cxxvii, p. 363.

² The appendix has received special attention in the recent elaborate works of DEEVER and KELLY.

the articles found in appendices have been pins, fecal masses, calculi, worms, gall-stones, fish-bones, tip of a thermometer bulb, seeds and fruit-stones, as of grapes, cherries, prunes, etc. I have only found grape-seeds in the appendix three times, and then this organ was in no way diseased. In cases of ulcerative appendicitis with perforation at the head of the cæcum, enteroliths have frequently been found. The theory has recently been advanced that influenza and syphilis are common causes of many cases of appendicitis. Metschnikoff thinks that the condition is often associated with worms of various sorts. Burfield¹ reports a case of *Bilharzia* infection of the appendix. The principal micro-organisms are the *Bacillus coli* (most common), *Streptococcus pyogenes*, *Staphylococcus pyogenes*, *B. tuberculosis*, *B. typhosus*, *B. influenzae*, *Proteus vulgaris*, *B. pyocyaneus*, *Actinomyces*, *B. pseudotetanus*, *Micrococcus tetragenus*, and *B. adcmatis maligni*. A mixed infection is usually present, upon an average three species being found in each case. The normal appendix is never sterile, while the diseased organ is sterile in ten per cent. of all cases. (Lanz and Tavel.) Acute forms: catarrhal, follicular, ulcerative, suppurative, and gangrenous. Of the chronic: catarrhal, obliterative, and chronic infective. In acute forms the appendix is reddish brown, black, or greenish yellow in color. The mucous membrane is swollen, reddened, and presents hypertrophied follicles, ulcerations, or a false membrane. The whole appendix is thickened, the serous membrane red and lustreless. In the suppurative form the abscess may be small and limited to the appendix; when large the pus frequently invades the peritoneal cavity, the sac being formed by peritoneum, fibrinous exudate, and fibrous adhesions. It should be remembered that in cases of appendicitis abscess formation may start outside of the appendix and there be no perforation. In severe cases following ulcerative or obliterative conditions the abscess-cavity may contain the whole or a portion of the appendix which has been sloughed off. The abscess-cavity may become limited and remain so and be subsequently absorbed, or it may later open into the general peritoneal cavity. Rarely it breaks through the skin. It may rupture into surrounding organs or structures, as the vagina, bladder, and rectum. The appendix may invaginate into the cæcum and, by reason

¹ *Lancet*, February 10, 1906, p. 368.

of its blood-supply being obstructed, become gangrenous, slough off, and be passed by the bowel. This, however, must be rare.

Ulceration and perforation of the appendix following typhoid are found. In obliterative appendicitis the entire tube is thickened, firm, and stiff; the peritoneal surface is smooth or injected, and may be adherent or free. It may become cystic, the contents being clear fluid or pus. The situation of the appendix varies greatly; rarely it may be found on the left side, as in transposition of the viscera, or it may be entirely absent. I have seen the tip of the appendix resting beneath a distended gall-bladder, entering into the formation of a *left* femoral hernia, or lying in the sigmoid flexure in a case of ileocæcal intussusception. On microscopic examination the lymph-follicles are numerous and close together, but as age advances they become separated and smaller. Late in life the appendix undergoes marked fibrous change, which must be distinguished from obliterative appendicitis. Primary cancer and sarcoma of the appendix have been found in a number of cases. Lafforgue¹ reports a double hydatid cyst of the appendix.

More people die from dysentery than from plague, cholera, and yellow fever. The blood of patients affected with tropical dysentery has an agglutinative reaction with the bacillus of dysentery. For a description of the lesions found in this disease, see p. 315.

In colitis, or inflammation of the large bowel, consider: (a) Early life. (b) Hot weather. (c) Errors of diet. (d) Certain micro-organisms of the colon group. (e) Poisons. (f) Some infectious diseases. *Classification*.—(a) Simple. (b) Membranous. (c) Ulcerative. (d) Chronic. (1) In *simple colitis* the mucous membrane is much thickened and reddened, the rugæ are prominent, and petechial hemorrhages are common. In ordinary inflammation the follicles are swollen and œdematous and on section they appear like pearls. When there is a marked cellular increase, they are white or gray and more prominent. These follicles may become confluent. (2) *Membranous colitis* is characterized by the formation of a more or less complete cast of the intestine, usually from one to six inches in length, but it may extend a distance of several feet. The membrane usually appears homogeneous, but may be distinctly laminated and show deposits of fecal matter between the layers. The end of the cast may be well defined, but often shades off into a transparent, gelatinous material. Associated with it are swelling

¹ *Gaz. des Hôpit.*, January 12, 1904, p. 33.

and œdema of the submucosa. The mucous membrane not involved in the formation of the cast is very much inflamed and there may be hemorrhagic infiltration. The intestine may show that perforation has occurred and gangrene may sometimes supervene. (3) In *ulcerative colitis* the appearances vary greatly: the ulcers may be small and numerous or they may be large in size and few in number. They may be perfectly regular in outline, but are usually irregular, with slightly undermined edges. The floor of the ulcer generally shows a somewhat sloughing bowel. The ulcers may have communications with one another between the layers of the intestines. In long-standing cases they are often intensely congested and tend to become transverse. Sometimes the floor of the ulcer becomes thin and is pushed out in the form of pouches. In very acute cases the mucous membrane is much reddened and highly vascular, and the surface is soft. The peritoneal coat of the bowel may be normal in appearance, but is usually red, somewhat sticky, and shows many dilated blood-vessels. Small hemorrhages are common. (4) In *chronic colitis* the bowel is often much thickened in all its coats. It may be larger in diameter. It is firm, even leathery, to the touch. The mucous membrane is hypertrophied, often much pigmented, and shows many small hemorrhages. The follicles are swollen and have a slaty appearance. There may or may not be ulceration.

There are four forms of dilatation of the colon: (a) Distention from gas. (b) Distention due to some solid substance within the bowel. (c) Distention caused by an organic obstruction in front of the dilated bowel. (d) The so-called idiopathic dilatation.

Malignant disease of the colon is generally a cylindric-celled epithelioma, usually confined, in the earlier stages, to a small area, where its contraction sets up an annular stricture.

The appendices epiploicæ are a frequent cause of disease. I have often seen them strangulated by becoming twisted on their axis. They may even become calcified.

THE KIDNEYS AND ADRENALS.—The spleen and intestines having been removed and the liver turned over into the thorax, the kidneys and adrenals yet remain behind the peritoneum, often deeply embedded in the perinephric fat. In anomalous cases, in certain diseases and deformities (notably Pott's disease), and in floating kidney they may be considerably displaced. In any event it is best and simplest first to find each ureter as it descends on the psoas muscle and enters

the pelvis. The exact situation of the ureters is as follows: Each ureter at first passes obliquely downward and inward to enter the cavity of the true pelvis and then curves forward and inward to reach the base of the bladder. In its whole course it lies close behind the peritoneum and is connected to neighboring parts by loose areolar tissue. In its upper portion it rests upon the psoas muscle and is crossed very obliquely from within outward by the spermatic vessels, which descend in front of it. The right ureter is close to the inferior vena cava. Lower down the ureter passes either over the common or the external iliac vessels, behind the termination of the ileum on the right side and the sigmoid flexure of the colon on the left. Descending into the pelvis, it enters the fold of the peritoneum forming the corresponding posterior false ligament of the bladder, and, reaching the side of the bladder near its base, runs downward and forward in contact with it, below the obliterated hypogastric artery, and in the male it is crossed from without inward by the vas deferens, which passes down between the ureter and the bladder. In the female the ureters run along the sides of the cervix uteri and the upper part of the vagina before reaching the bladder. (Quain.)

Incise the peritoneum on the left side first, then on the right over and in the direction of the brim of the pelvis, and follow up each ureter, gently tearing away the loose connective tissue, but being careful not to disturb seriously the relationship of the kidney and adrenal and their vessels until they have been noted. If this method be adopted, there is no need of making an incision in the peritoneum directly over the kidney, as is recommended by most pathologists. A careful examination of the vessels entering and leaving the kidney is next made,—vein, artery, ureter, etc.,—all of them being subject to many anomalies. The left spermatic or utero-ovarian vein enters at right angles into the renal vein, which I have known to be followed out in mistake for the ureter. The organs may next be “shelled out” of their bed of cellular tissue and fat and the vessels severed, thus permitting their removal from the body. The adrenal¹ is then separated from the kidney, weighed, measured, and incised in its greatest plane. Should disease of the bladder or ureters be present, the kidneys may be removed from

¹The right adrenal is more difficult to find than the left, and may be permitted to remain in the body until *after* the removal of the stomach, duodenum, and pancreas, but should be sought for *before* the removal of the liver. Testut, quoted by Gerrish, gives admirable illustrations of the situation of the adrenals.

the body with the ureters attached. This is always better in those very common cases in which double ureters are found. One nick is then put in the left kidney, so as to distinguish it from the right, at its upper or lower border, and the kidney and adrenal are removed, or the kidney may first be dissected. Another method of distinguishing the right kidney from its fellow is to make a uniform rule as to which ureter shall be left the longer, by several inches, on the separation of the kidneys from the body. The kidney is then cleaned and weighed, and any peculiarities are noted.

To remove the kidney while the intestines are still in the body, first hold aside the left sigmoid flexure and pull away the fundus of the stomach and the tail of the pancreas. Then make an incision over the convex border of the kidney. Next separate it from the surrounding tissue and cut the kidney out along with the adrenal. The right kidney lies under the liver, and in removing this adrenal be careful not to cut the inferior vena cava. If you remove the ureters with it (Fig. 100), on the right side, a long incision must be made through the peritoneum that goes from the abdominal wall to the cæcum and colon. (Orth.) Nauwerck recommends a more complicated method. He cuts the descending colon from the mesocolon first. His primary incision is vertical and between the hilum and the spinal column, a second one being made in the convex border of the kidney.

Holding the kidney longitudinally in the hand, the hilum towards the palm and the convexity upward, a clean brain-knife or large cartilage-knife is used to divide it through its middle parallel to its greatest surface. The knife must be so sharp that it will cut without tearing, and care should be taken not to extend the incision through to the hand (Fig. 101). The wisest precaution for this purpose is first to bisect the kidney only to its centre, then reverse the organ in the hand and complete the incision by cutting outward (Fig. 102). The pyramids and the calices with their papillæ will now be completely exposed and the two halves held together by the tissues composing the pelvis. If it be desired to lay open the hilum or a hydronephrosis, scissors should be employed. Precipitates of urinary salts in the pelvis are often mistaken for pus. A microscopic examination, especially if acetic acid be added, will at once reveal the true nature of the fluid. Now examine the surface for cysts, stellate veins (veins of Verhagen), aberrant adrenals, miliary tubercles, tumors, etc. Large cysts can readily be seen. When incising a cystic kidney, it should be remembered that the

liquid therein is often under considerable pressure, and may squirt several feet when the cavity is opened, and thus injure the eyes or soil the clothing of the operator or of those present at the autopsy.

The capsule, which when normal is transparent, is next stripped off from one side (Figs. 103 and 104), and its condition noted as to whether or not it is thickened, adherent, or non-adherent. If adherent, see if any of the cortical substance is removed with it.—*i.e.*, whether the inner surface is smooth or rough. In those cases in which the capsule is adherent, this portion of the kidney should be saved for microscopic study along with the renal tissue lying directly beneath. The normal color of the surface of the kidney after removal of the capsule is brownish red.

The relation existing between the lighter cortex and the darker medulla is determined by drawing a straight line from the apex of one of the largest central cones of a pyramid to the surface of the kidney. Normally this relation is as one (cortex) to three (medulla); it is, however, frequently altered and should always be noted. The cortical substance is increased in parenchymatous nephritis and decreased in chronic interstitial nephritis. Also study the color of the external and cut surfaces, the quantity of blood or fluid exuding and its character, and the consistence of the organ. Thus, in parenchymatous nephritis the color of the cortex is a grayish white or light yellow. In poisoning by hydrocyanic acid much blood exudes, and in chronic interstitial nephritis the nephritic tissue is dense and hard. Both anæmic and hemorrhagic infarcts occur. The yellowish-white radiations found in the pyramids of infants' kidneys are composed of uric acid within the collecting tubules and are known as uric acid infarcts. Scars are often found, and may be due to many different causes, as gummata, thromboses, infarcts, stones, former operations, etc. Tumors of the kidney, especially fibroids, are quite common. It is not rare to find numerous small fibroids just beneath the capsule which might be mistaken for tubercles. With arteriosclerosis and granular kidneys, never fail to examine the brain, especially if there has been a clinical history that points to apoplexy. As a routine practice in the examination of the kidney the amyloid reaction should be tried. A thin slice about one inch square, including both cortex and medulla, is removed from the organ and placed in Lugol's solution (which is preferably diluted four or five times) for several minutes and then examined with a hand glass in a good light. In weighing the kidney the fat which is adherent—as

found in old renal cases in the renal hilum—is weighed along with the organ, and unless its presence is mentioned may give a false idea as to the real weight.

Where decapsulation as an operative therapeutic measure has been practised, also after the scraping of the hepatic peritoneum for ascites, the post-mortem examination should be very thorough, as any information concerning such cases is most important at the present time.

The adrenals are covered by the under surface of the diaphragm, although not usually attached to it, and above and lateral to the tips of the kidneys. They are embedded in the same kind of tissue as surrounds the kidney, which is of a fatty, cellular nature, the difficulty of finding the glands being in proportion to the amount of this tissue present, which differs, however, in its color unless stained with bile. After the gland is found, its dissection is best accomplished by a pair of scissors. It is sometimes intimately connected with the kidney or even with the liver by bands of fibrous tissue. Accessory adrenals (generally discovered only by microscopic study of other parts) are found at times in the neighborhood of the main gland or even several inches away. Hydronephromata may be found in the kidney, liver, pancreas, broad ligament, spermatic cord, in the inguinal canal, or in the retroperitoneal tissue. They may assume a considerable size, and be either benign or malignant. The adrenal of one side may in rare cases be absent. Supernumerary adrenals are found rather frequently in the ox, being connected more or less intimately with the main gland. They must not be mistaken for the hæmolympf-nodes also found here. (Wynn.)

The adrenals are best removed attached to the kidneys, though, as already stated, the ablation of the right adrenal with the kidney is more difficult than that of its fellow, and for this reason it is often left in the body and examined at the time of the removal of the pancreas. The adrenals are very delicate, and care must be exercised lest they be injured in their excision. Normally the adrenals consist of three layers, which differ more or less in the young and the old. The outer or cortical layer is light yellow in adults and grayish red in children. This tissue somewhat resembles that found in the thyroid gland. It is composed of radiating follicles whose cells are undergoing fatty degeneration. It will be seen in the new-born that the adrenals are relatively of large size in comparison with the kidneys and when examined microscopically no fatty metamorphosis is discovered. The inner or

medullary substance is composed of neuroglia and ganglionic cells connected with a rich vascular supply. The middle zone, or intermediary substance, is brown, owing to pigmentation of the follicles. The amount of intermediary substance is subject to considerable variation. (Langerhans.) Later in life there is a tendency for the central part to become separated from the intermediary portion,¹ and in atrophy of this organ, when it takes place unevenly (as it frequently does), nodes are left on the surface which are not infrequently mistaken for tubercles. These organs are subject to numerous pathologic changes and are hyperplastic in many varieties of congenital deformities in which other nerve-tissue is affected. There may be here hæmatomata, melanomata, cysts, gliomata, primary cancer, echinococcus cysts, hypertrophy, hæmatoid degeneration, tuberculosis, purulent infiltration, infarcts, and internal proliferations. The recent discovery of the marked action of adrenalin would seem to show the presence of an internal secretion acting directly upon the vascular apparatus. Exquisite miliary tubercles are seen in the adrenals, and in advanced tuberculosis the caseating mass may reach the size of a walnut.

Addison's disease is most frequently seen in laborers between the ages of twenty and forty years. It is by no means certain that the adrenals will be found affected, either macroscopically or microscopically, in all cases of Addison's disease. It may be due to: (a) Tuberculosis, simple atrophy, fibrosis, hemorrhage, or tumors of the adrenals. (b) Inflammation of and pressure by structures bordering the adrenals. (c) Changes in the semilunar ganglia and the sympathetic system. The adrenals are not infrequently tuberculous, and there is then a deficiency of the internal secretion of these organs. The brownish pigmentation so characteristic of Addison's disease (bronze disease) is most marked on the chest. The spleen may be enlarged, as may also the thymus, if the latter gland be present. The stomach and intestines may show hypertrophied lymphoid follicles. No specific blood-changes have been observed. One of the most marked cases of pigmentation of the abdomen which I ever saw was that of a girl who had undergone an operation for the removal of a large dermoid cyst of the ovary. It is possible that in this case the semilunar ganglia or the adrenals were affected by pressure or otherwise. In two

¹Letulle considers the formation of a central cavity as usually due to traumatism in its removal or to post-mortem changes.

cases of primary sarcoma of the adrenal, and in one of general tuberculosis with marked involvement by caseous tubercles of both adrenals, I observed no pigmentation of the skin at the time of the autopsy.

THE SEMILUNAR GANGLIA.—The semilunar ganglion or cœliac plexus, which receives the great splanchnic nerves and the pneumogastrics, is situated behind the stomach and in front of the crura of the diaphragm, by the side of the cœliac axis and the root of the superior

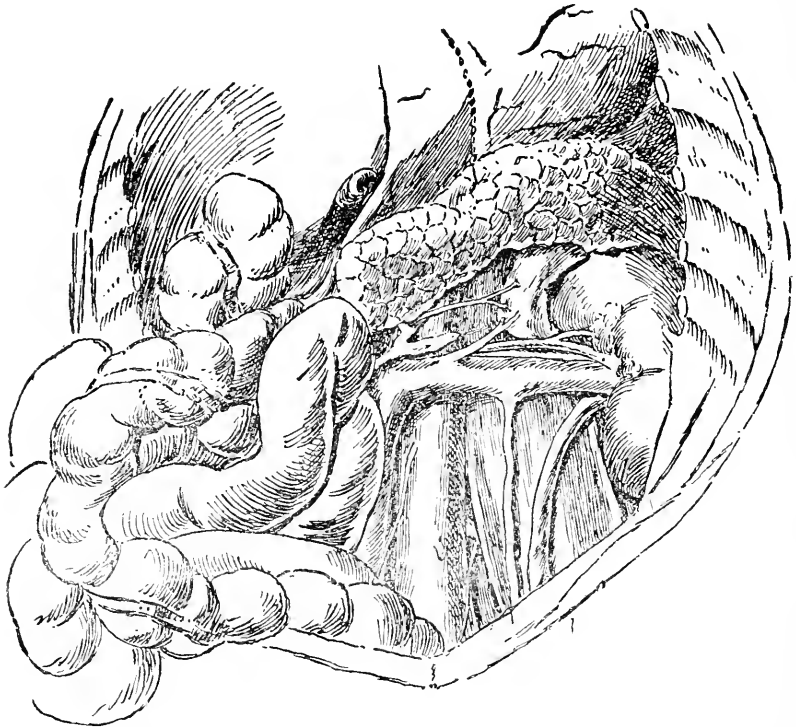


FIG. 105.—The relations of the pancreas, left kidney, ureter, adrenal, and solar plexus are shown, the liver having been turned upward and the intestines pulled over to the right.

mesenteric artery, and close to the suprarenal body (Fig. 105). It may also be found by tracing the nerves from the adrenals to their entrance into the ganglion. The ganglia should be carefully studied microscopically in all cases in which lesions are suspected in the adrenals or in the sympathetic system. The color and vascularity as well as the condition of the surrounding connective tissue should be noted. In cholera and typhus fever the ganglia are hyperæmic and may show evidence of the occurrence of hemorrhage (Rokitansky).

THE URETERS AND BLADDER.—The ureters may be distended with urine, as from an impacted stone, stricture of ureter, twist of ureter (as in floating kidney), ligature, adhesions, or pressure from without, or from overfilling of the bladder. They are often double, most frequently uniting in their middle third, more rarely in the structure of the bladder, but may enter this viscus by separate papillæ. The ureters being slit open throughout their entire extent, the appearance of the mucosa is described, taking into account the color and character of any catarrhal exudate, should it be present. Many microscopists teach methods of diagnosing the situation of a lesion in the urinary tract from the shape of the epithelial cells. A most interesting experiment is to take at a postmortem scrapings from the pelvis of the kidney, the ureter, bladder, and urethra, examine them under the microscope, and determine whether or not such a diagnosis is possible. Hemorrhages, abscesses, papillary fibromata, the *Distoma hæmatobium*, calcified bodies, etc., are found in the ureter. Miliary tubercles of the mucous membrane are seen, often of typic shape and large size.

In some three hundred consecutive autopsies performed in one year, I met with three cases in which the ureter had been tied during abdominal operations on the uterus and its adnexa. The right ureter seems to be ligatured oftener than the left. In pregnancy there may be considerable pressure hydronephrosis.

If it be desired to collect the urine for microscopic, chemic, or medicolegal examination, it should be drawn off into a sterilized vessel with a sterilized catheter. Should strychnine poisoning be suspected, place a live frog in the urine, and if strychnine is present in any amount the frog will show the typic strychnine convulsions. Unfortunately, however, in strychnine poisoning the quantity of urine secreted is often very small, and the alkaloid is not always present in the urine of those dying from its effects.

PELVIC ORGANS.—*Removal of the Female Genitalia.*—The parietal peritoneum is freed around the entire brim of the true pelvis by a circular incision, starting and ending at the symphysis pubis and including the anterior portion of the sacrum. Orth begins the incision between the rectum and the sacrum, while Schottelius recommends the ending of the incision at the posterior superior spine of the ilium. The body is then placed in the position seen in Fig. 106, and the thighs are separated. An oval incision is next made, starting above the external genitalia, below the symphysis pubis, and ending behind the anus near the

coccyx (which may be examined at this time), passing to the outside of the labia on each side. Traction is then made upon the soft parts towards the median line and the incision deepened, keeping as close as possible to the pelvic bones and taking care that the knife or scissors, held so as to cut in the direction of the long axis of the body, does not injure the rectum, bladder, or external genitalia. It is now possible to remove the external genitals, bladder, and rectum through the abdominal cavity, or the internal parts through the oval incision exteriorly

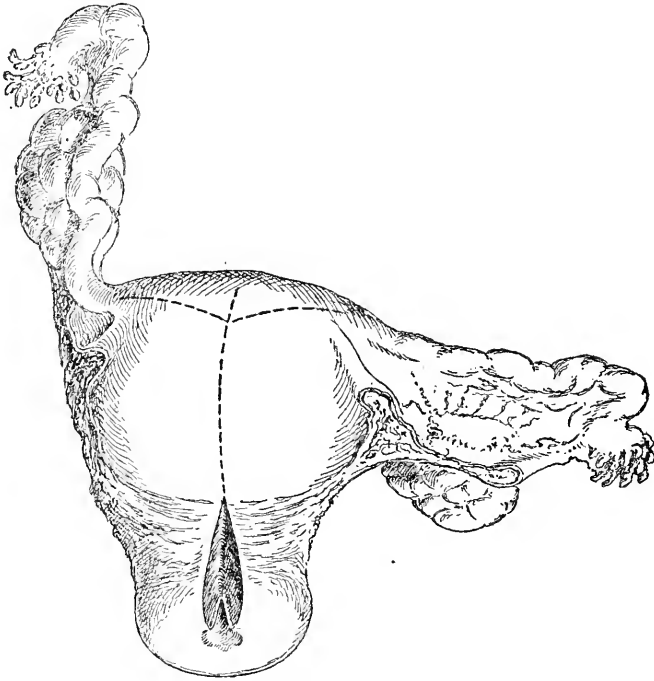
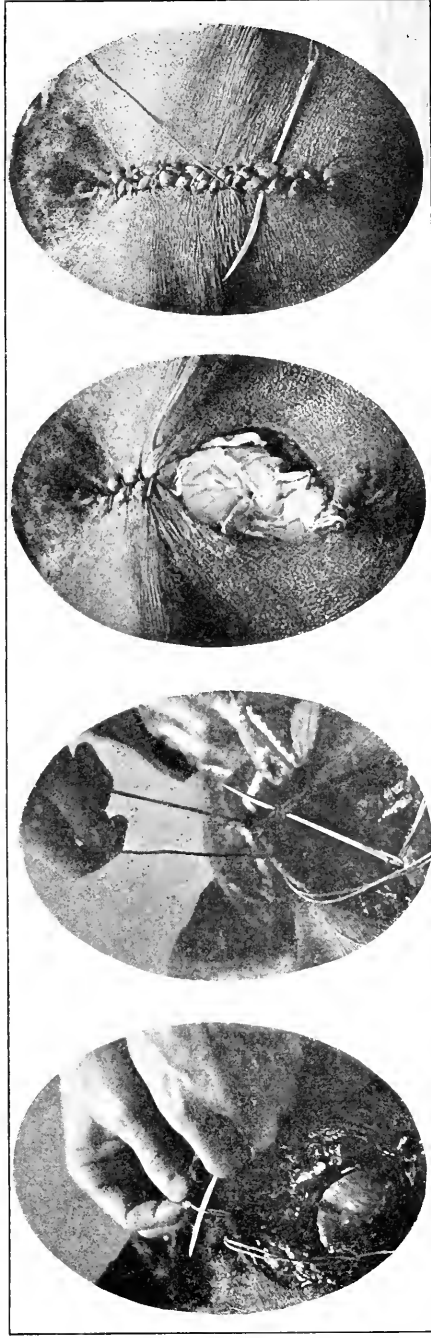
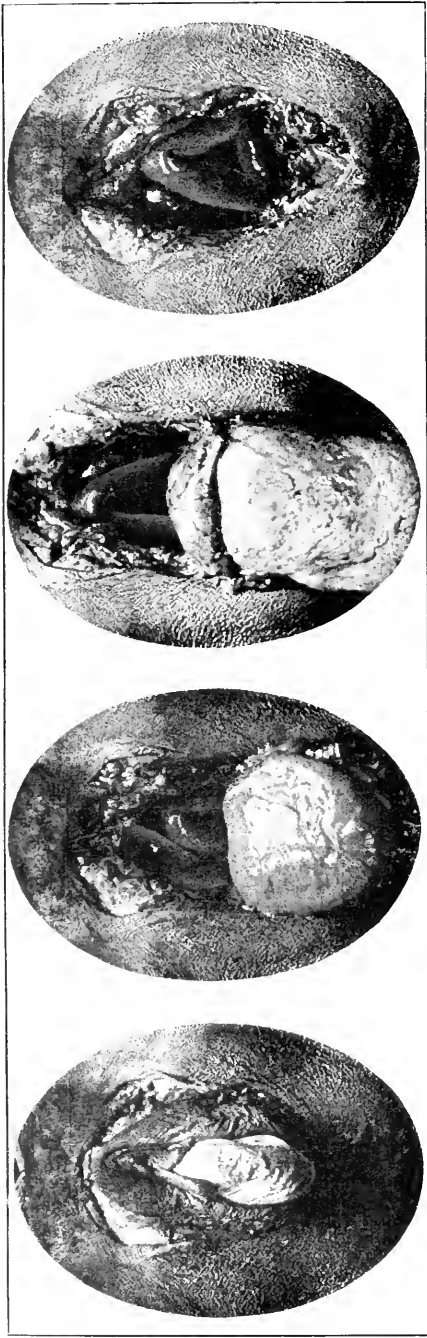


FIG. 115.—Method of opening the uterus; the lines show the places for the incisions, one of which has already been started at the cervix. Letulle prefers to open the uterus posteriorly.

(Figs. 107 to 114, inclusive). Whichever method is adopted, the muscles, fatty tissue, and fascia holding the parts in place are to be severed without injury to the tissues to be examined; or an internal or vaginal hysterectomy may be performed, if for any reason the external incisions should be avoided. If the ureters and kidneys have been left connected, they may be removed at the same time. The pelvic organs having been excised, they are placed on a board upon the table in the same relative

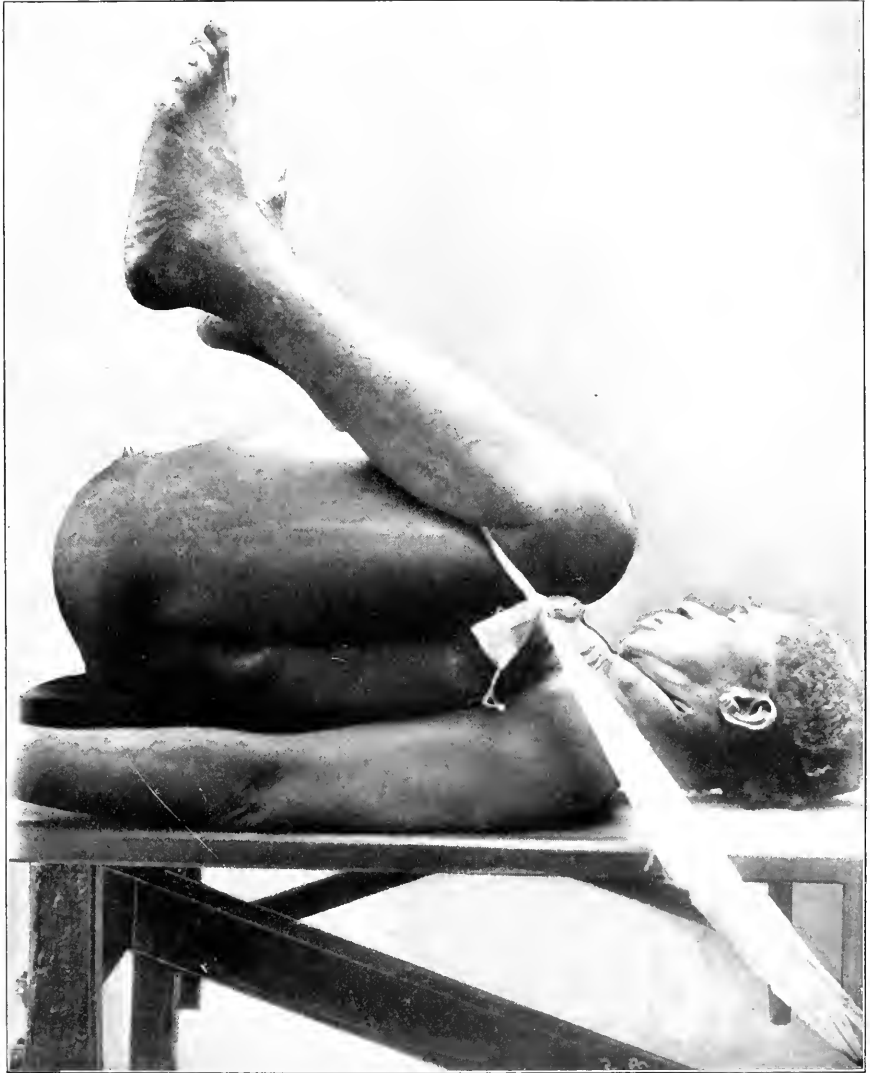

FIG. 106.—Position in which the body is advantageously placed for examination of the rectovaginal region and for the performance of a postmortem *per vaginam* or *per rectum*. The body is drawn down towards the end of the table and the hips are elevated with a block. The thighs are then strongly flexed and each one held securely in place by a separate bandage fastened beneath the table.



FIGS. 107-114.—Method of performing a post-mortem extirpation of bladder, uterus, and adnexa through the vagina and the restoration of the parts afterwards. An ovoidal incision, Fig. 107, is made through the skin about an inch from the external genitalia; this is then enlarged and deepened until the pelvic cavity is reached, when with the hand the bladder is loosened and the parts desired brought through the opening. Figs. 108 and 109 show the parts *in situ*; Fig. 110, after their removal. In sewing up the parts afterwards to prevent leakage double thread is used. It is introduced at the upper or lower portion of the wound and the needle passed through the two threads so that when it is pulled tight there will be no chance of the thread slipping. (Fig. 111.) Figs. 112, 113, and 114 show method of sewing. (In this case there was a prolapse of the uterus, which is well seen in Figs. 107 and 108. The figures are numbered, starting at the top, from left to right.)




FIG. 117.—Author's method of examining testicles, epididymis, spermatic cord, etc., without disfigurement. The primary incision is made in the median raphe in such a manner as to be covered when the penis is returned to its normal situation.

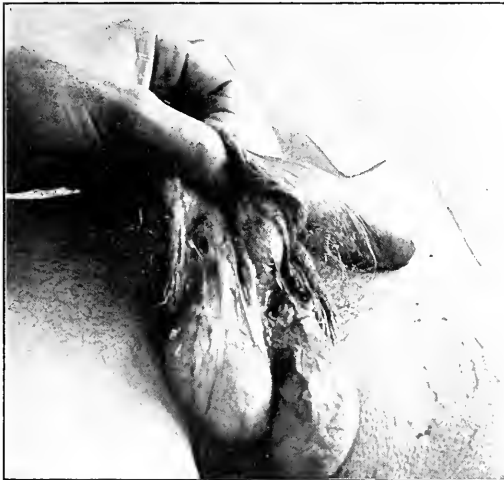

FIG. 118.—Testicles shelled out of the scrotum through the opening made in Fig. 117.

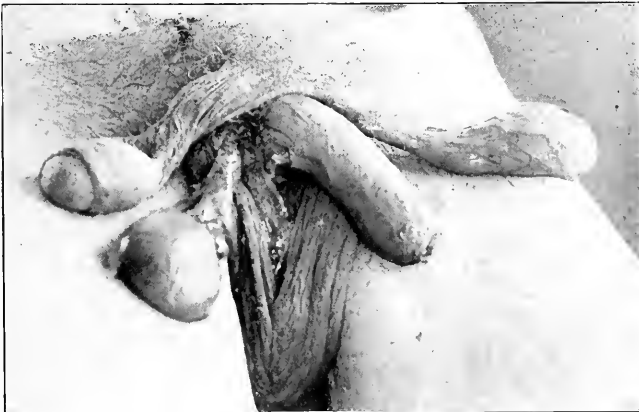

FIG. 119.—Appearance of the male external genitalia preparatory to minute examination in the author's method of exposing them without disfigurement.

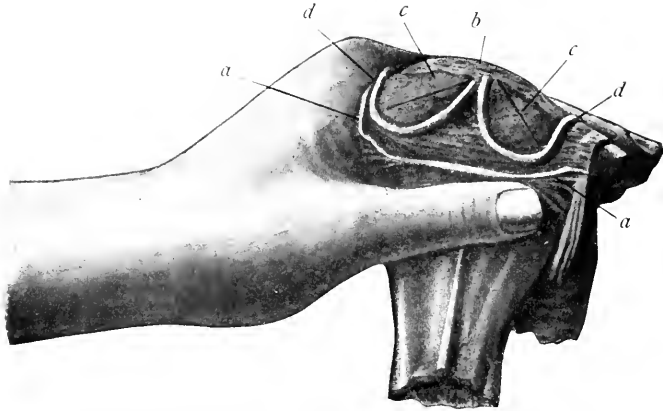


FIG. 120.—Method of examining the seminal vesicles, which are exposed by incisions at the places indicated by the lines above the seminal ducts. *a*, *a*, edge of severed portion of peritoneum; *b*, urinary bladder; *c*, *c*, seminal vesicles; *d*, *d*, spermatic ducts. (After Nauwerck.)

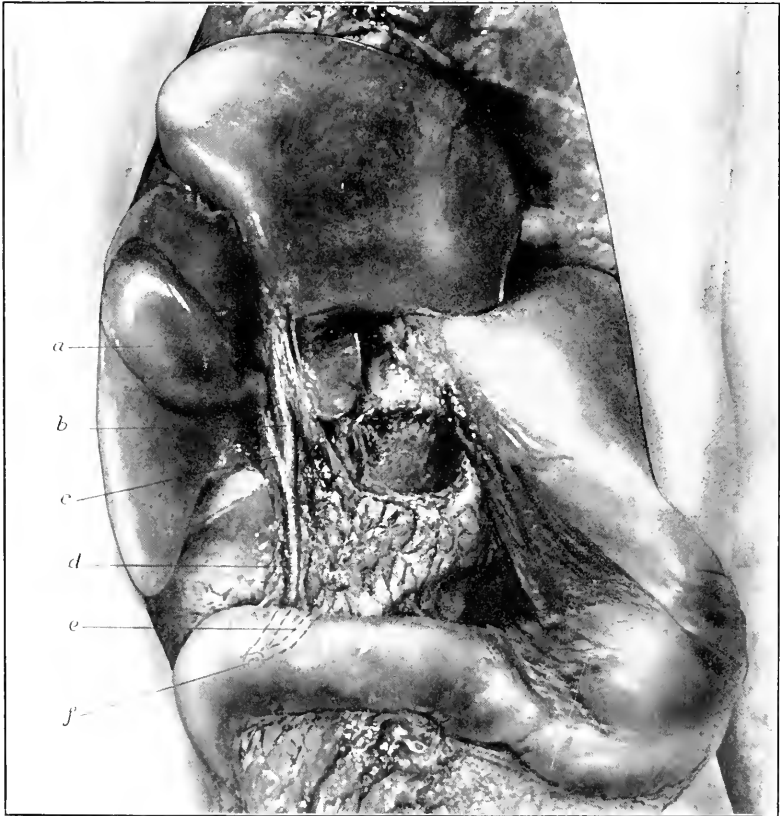

FIG. 121.—Relations of the ducts of the liver, gall-bladder, and pancreas to the duodenum. *a*, gall-bladder; *b*, liver; *c*, cystic duct, just above its junction with the hepatic duct; *d*, common bile duct; *e*, pancreatic duct; *f*, papilla in the duodenum, at which point the common bile duct and the pancreatic duct terminate.

position that they occupied while they were in the body. The bladder is then incised anteriorly with the scissors on the median line from the fundus to the urethra, which should be opened. In the male, the prostate should be carefully observed.¹ The rectum is slit up along its posterior wall, while an anterior incision is chosen through which to examine the uterus. When it is desirable to preserve the exterior of the bladder intact, the rectum may be dissected away and the womb incised posteriorly, or the bladder may be removed so as to permit of the uterus being opened up anteriorly. A transverse incision in the

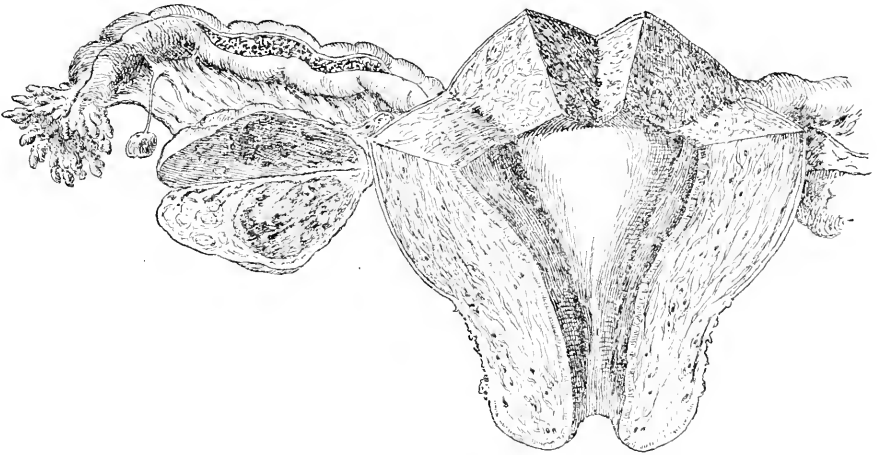


FIG. 116.—The uterus has been incised in the manner described in Fig. 115. The ovary and the tube are opened. The fimbriated extremity, the hydatid of Morgagni, and a corpus luteum are well shown in the illustration.

uterus from the entrance of one oviduct to that of the other will give an opportunity for a study of their uterine termini, which are sometimes rather difficult to find. Each ovary is completely bisected through its free surface, with the exception of enough tissue at the bottom to hold the two halves together (Figs. 115 and 116). The oviducts are now opened. Ch. Robin has pointed out that the normal mucous membrane of the oviducts secretes a creamy material which, without a microscopic examination, may be mistaken for pus. For the method of closing the external opening, see directions under Figs. 107 to 114,

¹ Many obducent's partially open the bladder while it is still attached to the body; indeed, the entire examination of the pelvic organs can be made with the parts *in situ*.

inclusive. The older the ovary, the more is it distorted, irregular, and cicatrized.

Removal of the Male Organs of Generation.—In the male the bladder is pressed downward well towards the rectum, and the tissues thus put on a stretch are incised close to the under portion of the symphysis pubis. A circular incision is then made anterior to the rectum and as close as possible to the parts to be removed (seminal vesicles, prostate, Cowper's gland, bulbus, etc.) without injuring them or buttonholing the skin. The soft tissues of the penis (cavernous and membranous portions of the urethra) are dissected away from the skin from *within* the pelvis, traction being made to bring these parts into the pelvic cavity as fast as those above are loosened. The corpora cavernosa and corpus spongiosum being now fully exposed, they are incised transversely near the attachment of the prepuce, just below the corona glandis and frænum. By pulling on the spermatic cords from above and pushing up the testicles from below, these organs are then removed together. To facilitate removal, a few cuts may first be made into the internal inguinal ring. The skin of the penis and scrotum is well stuffed with cotton, so that they may conform as nearly as possible to their original shape. A preliminary symphysiotomy may even be performed, or a V-shaped portion of bone taken from the symphysis pubis, or, if desired, after dissection of the testes and their appendages, they may be returned to their normal situations. Unless by an accidental perforation of the skin,—as the knife is working in the dark,—there need be no visible deformity, if this method be properly carried out. The rectum and the bladder and its component parts may be left attached or they can be separated, as preferred. The testicles may also be removed and examined by dissecting beneath the skin *in front* of the symphysis pubis until their situation in the scrotum is reached. They are then pushed up with the hand from below. The tunica vaginalis and the spermatic duct and its vessels are then dissected out.

The technic of my external method of examining the testicles, urethra, spermatic cord, etc., without mutilating or disfiguring the external genitals, is as follows: The penis is grasped with the left hand and drawn upward and backward over the symphysis pubis in such a manner as to expose its under surface and the scrotum. With the thumb and forefinger of the same hand a fold of skin is taken up at the point where the integument of the penis merges into that of the scrotum. This fold, which should be in the line of the long axis of

the penis, having been drawn taut, incision is made across it at right angles to the line of the penis. If this transverse incision be not carried too far, it will leave an oval gap about an inch and a half in diameter when the fold of skin is allowed to fall back. This will be quite large enough to permit the proper execution of the subsequent steps of the operation, and the wound, after being sewed up, is so small that it is entirely concealed by the penis when replaced in its normal pendent position. The finger is next introduced into the scrotum and swept around so as to break up the delicate areolar connective tissue that forms the septum scroti and unites the dartos with the testes; then by slightly dilating the external wound the testicles can be removed from the scrotal sac. Next the root of the penis is grasped from within, and the extremely loose bands of connective tissue that unite the body of the organ to the integument are broken up, still using only the finger. These connections having been severed, the body of the penis can be drawn from its cutaneous sheath as far as the point of union of the prepuce with the tissues at the cervix, so that now the testes and the penis, as far as the glans, are exposed without their cutaneous investment. In severing the body of the penis from the glans and the tissue included in the inverted sheath of skin, great care must be exercised not to buttonhole the delicate structure of the prepuce. This accident can be avoided by amputating the glans at a point one-fourth of an inch from the corona (which can be plainly seen and felt through the delicate skin covering it) and carrying the incision parallel to its plane. The direction of the incision will be downward and forward, for in the position in which the integument attached to the cervix now holds the penis, the frænum is below and in front. The amputation of the glans is most conveniently performed with scissors, the body of the penis being supported by the thumb and first finger of the left hand (Figs. 117, 118, and 119).

Nauwerck describes the following method of finding the seminal vesicles: They lie as long, flattened organs on the lateral side of the spermatic duct immediately above the prostate and the posterior wall of the bladder. The fundus of the rectovesical excavation is held up, and the index-finger is placed in the incision in the prostate, the middle finger in the posterior wall of the bladder, and the thumb on the rectum, which on being pulled downward exposes the back part of the neck of the bladder, upon which rest the seminal vesicles. Or cut through the peritoneum in the depth of the excavatio rectovesicalis,

and dissect up the spermatic cord until the vesicles are reached. They are then to be incised and the duct opened up with a fine pair of scissors (Fig. 120). The mucous membrane of the seminal vesicles is of a brownish color, like that of the testicle.

THE DUODENUM AND ITS DUCTS.—The duodenum may be slit while still *in situ*, or it can be excised together with the stomach, liver, and pancreas, and the whole dissected after removal from the body. If a careful dissection of the pancreas be desired, it is well to leave the duodenum attached to the stomach and not to dissect these parts away from the pancreas, which in the Russian language is so aptly called the “under-the-stomach gland.” The length of the duodenum is determined by laying a string along the centre of its anterior surface and measuring the same. The gut is best opened with a knife, starting at the tied end about the centre of its anterior surface and with the enterotome cutting more and more to the right until at the pylorus the incision almost reaches the posterior surface of the duodenum (Figs. 121 and 122). Notwithstanding the presence of the glands of Brunner in the lower third of the duodenum, the appearance of the mucous membrane closely resembles that of the jejunum. The papilla, the outlet of the ductus choledochus communis (common bile duct), can usually be discovered if it be remembered that it appears as an elevation of the mucosa near the junction of the second (descending) portion and the third (transverse or oblique) portion of the duodenum, about three and one-half inches from the pylorus, just below the head of the pancreas, and towards the inner and back part of the duodenum. The duct runs for three-quarters of an inch in the muscular coat of the bowel, where it is usually joined by the pancreatic duct. A small magnifying-glass will often enable one to distinguish the papilla from the *valvulae conniventes*. Pressure upon the gall-bladder, as suggested by Virchow, will cause bile to flow out (but care must be taken not to dislodge a gall-stone, either here or in the cystic duct) and thus reveal the opening of the duct. Another way is to follow down the cystic duct, make a transverse incision in it, introduce downward a small probe, a broom-straw, or a grooved director until this emerges through the opening in the papilla, and then slit it with a knife or scissors. Orth says that if, after finding the head of the pancreas, the intestines are stretched transversely, the outlet will readily be discovered a little below the middle of the head. Congenital diverticula of the duodenum are sometimes found, as well as those of the stomach and œsoph-

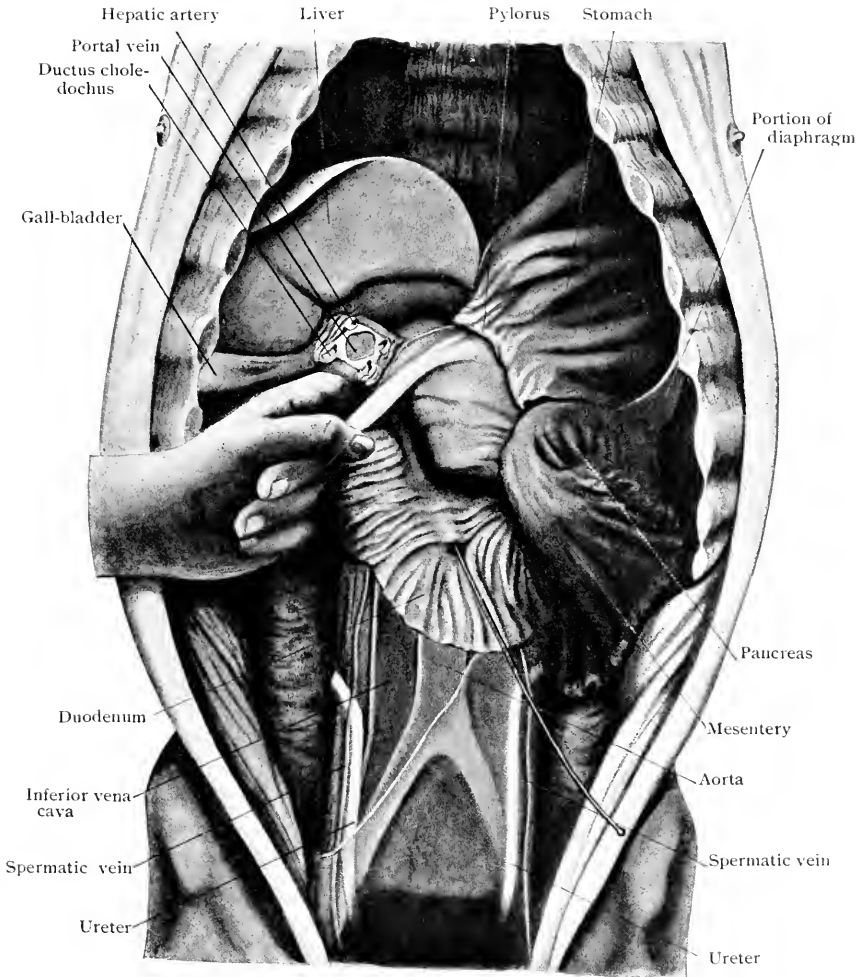


FIG. 122.—Examining the bile ducts. The left index-finger is introduced into the foramen of Winslow and supports the hepatic artery, the portal vein, and the ductus choledochus, into the latter of which a sound has been introduced and is seen coming out of the opening in the duodenum. (After Nauwerck.)

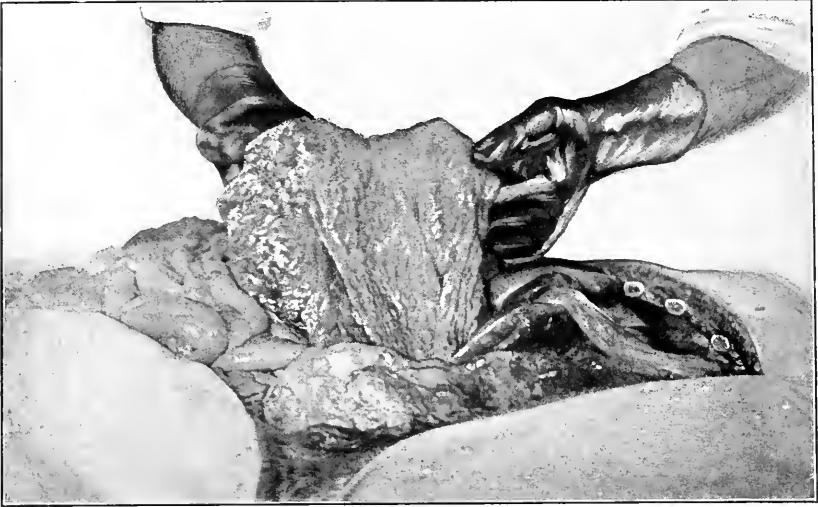


FIG. 123.—Method of examining the stomach, which in this case was markedly hypertrophied. Rubber gloves are very useful for this purpose.

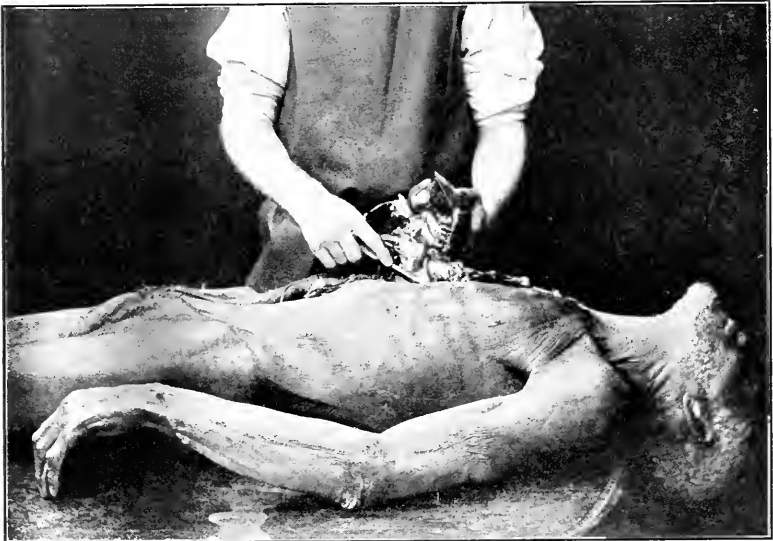


FIG. 124.—Removal of the liver from the body. It is held in the left hand and an incision is made towards the operator. This stretches the diaphragmatic attachments of the large blood-vessels, so that they may readily be incised.

gus. Accessory pancreatic tissue may be found hid in the walls of the duodenum. The canal of Wirsung and its accessory canal should be opened. For this purpose the transverse incisions stop at the centre of the gland, and the canal is searched for. It is usually situated about the centre, is small in size, and is recognized by its pearl-like color. When found, it is dissected out until within about one and one-half centimetres of the ampulla, when a flexible probe or small grooved director is passed through the ampulla. The opening of the caruncula minor is often closed and the pancreatic fluid finds its way out from that portion of the pancreas drained by it by means of the ampulla of Vater, or the converse may be true. Branches from the canal of Wirsung, when dissected out, may lead to accessory pancreases.

THE STOMACH AND ŒSOPHAGUS.—Unless poisoning be suspected (see pages 442 and 486), the stomach is incised along the greater curvature, a *little below* the cardiac orifice and a *little above* the pyloric, the contents are removed, and the openings examined, after which the incision is extended in both directions until the entire viscus is laid open. The mucous membrane may be washed by allowing a gentle stream of water, as from a sponge, to flow over it, but it should not be rubbed with the sponge. The organ may be opened and examined without removal from the body (Fig. 123). Should it be desired to find the artery from which a hemorrhage has occurred in a gastric ulcer, water is injected into the gastric artery supplying this area, and it will be seen to exude from the open part. The usual situation of a gastric ulcer is upon the posterior wall near the pylorus. Examples of a carcinoma developing from the edges of a gastric ulcer are sometimes found. Guitéras has pointed out the frequency of small abrasions of the mucous membrane near the pylorus and the collection of small round cells in this vicinity. These should not be confounded with post-mortem digestion of the nucous membrane. I know of no extended series of examinations of the gastric contents made after death. In nine cases of pernicious anæmia, Arneill¹ found free hydrochloric acid in none, whereas it was present in some of the gastric carcinomata examined.

The contents of the stomach should be examined as to their quantity, consistency, reaction, odor, color, gas formation, and presence of foreign bodies. In one of my cases an aneurism of the thoracic aorta

¹ *Amer. Med.*, January 16, 1904, p. 93.

had ruptured into the stomach. Blood coming from the lungs is apt to be mixed with air, frothy in character, and redder than blood issuing from the œsophagus or the stomach itself, where, if the vessel be of good size, large, compact, blackish-red lumps appear. The blood from cancer is blackish brown (the so-called coffee-grounds appearance); that from diapedesis, cirrhosis of the liver, and inflammations is a brownish, homogeneous mixture combined with mucus. The biliary pigments often impart to it a yellowish or greenish hue. Bile in the stomach and erosions point to vomiting during life. In peritonitis and in obstruction of the bowel the gastric contents may be fecal in character.

The most unexpected articles may be found in the stomach,—gall-stones, hair-balls, scarf-pins, glass, rupees (in one case weighing seventeen and three-fourths ounces), hundreds of pins and needles, etc. Thus, eight teaspoons and seventeen other articles were removed by operation from a would-be suicide and thirty feet of wire from an insane patient.¹ Thieves often swallow articles stolen. The larvæ of the *Diptera*, maggots of cheese, earth-worms, ascarides, tæniæ, and *Oxyuris vermicularis* and rhizopoda have been found. (Ewald.)

The œsophagus is opened up along its anterior surface throughout its entire median extent, either while *in situ*, in case it has not been removed in the manner suggested on page 122 (Fig. 91), or after its removal from the body (Fig. 92). Its calibre may be directly determined by graduated cones, or may be calculated by dividing its circumference by 3.14 (π). Its linear measurements can be made after it has been laid open. The longitudinal folds can plainly be seen, and may be discolored, due to post-mortem changes. Note carefully the change of color and elevation of the œsophageal epithelium as it passes into that of the stomach. Sometimes it is wise to differentiate by placing it in Müller's fluid or in alcohol for several hours, thus coloring or bleaching the part. Traction diverticula are not uncommon, while pulsion diverticula are of rarer occurrence. An aneurism with a very small opening, usually slit-like, may rupture into the œsophagus. Collateral circulation is often established by means of the veins in the lower third of the œsophagus. Peptic, typhoid, syphilitic, and tuberculous ulcers occur here, as well as abscesses, congenital diverticula, and stricture due to a cicatrix, neoplasm, spastic contractures, etc.

¹ MONNIER, *Bull. de l'acad. de méd.*, 1903, vol. lxxvii, no. 34, p. 210.

In cancer of the stomach consider heredity, sex (more common in the male), age (average about fifty years), previous history of a gastric ulcer, and place of origin, inquiring particularly whether or not other cases have occurred in the same house. Cylindric-celled cancers are found especially at the pylorus, while squamous epitheliomata occur principally at the cardiac end of the stomach. The tumor may be hard (scirrhus), soft (medullary), or colloid. (a) *Scirrhus*.—The growth starts as a small nodule, usually at the pylorus, often sharply defined, and very hard. It is whitish on section and no cancer-juice exudes from the cut surface. Stricture of the pylorus with hypertrophy and dilatation of the stomach is common. Connective tissue is very abundant and cancer-cells are few. Ulceration occurs late in the disease. (b) *Medullary*.—This tumor tends to become larger than the scirrhus variety. It contains much less connective tissue and is therefore softer. It involves all the coats and is not circumscribed. It ulcerates very early and hemorrhages are frequent. As in the previous instance, metastasis is very common. (c) *Colloid*.—This variety usually consists of gelatinous cancer-cells in a condition of colloid degeneration. It extends over the entire stomach and metastasis takes place very rapidly. Metastasis in all the forms affects the various tissues and organs in the following order: lymphatic glands, liver, peritoneum, omentum and intestine, pancreas, pleura, lung, and spleen. The squamous variety is a somewhat flat, tubular swelling involving the superficial layers. It may constrict the œsophageal orifice and cause atrophy of the stomach. Cases in which a cancerous stomach has been removed entire during life demand special attention at the postmortem.

Gastrectasis, or dilatation of the stomach, is due to: I. *Pyloric Stenosis*.—(a) Carcinoma. (b) Congenital conditions. (c) Hypertrophy of the pyloric sphincter. (d) Cicatrix of an ulcer. (e) Peritoneal adhesions. (f) Cancer of the head of the pancreas or other structure pressing on the duodenum. (g) Spasm of the sphincter. II. *Atony of the Gastric Walls*.—(a) From chronic gastritis. (b) Excessive ingestion of solids and liquids. (c) Traumatism. (d) Surgical intervention. (e) Serious infectious diseases. (f) Neurasthenia. (Hemmeter.) At first there is hypertrophy of the muscular walls. Soon, however, interstitial sclerosis comes on, the stomach may become either pyriform or hour-glass in shape, and the mucous coat is thrown into exaggerated folds. As atrophy advances all the layers of the stomach become thinner; the bundles of muscles are separated by

connective tissue; the surface may show evidences of pigmentation and petechial hemorrhage; and while the serous surface sometimes remains unaltered, it is usually thick, pale, and opaque.

Gastritis, or inflammation of the stomach: I. *Acute*.—(a) Errors in diet both as regards quantity and quality. (b) Irritant poisons. (c) Mechanical: external (severe injury to the epigastrium); local (fish-bone, etc.). (d) Thermal (hot or cold ingesta). (e) Infectious diseases. (f) Psychic shock (grief, sorrow, etc.). (g) Extension of inflammation from other organs. II. *Chronic*.—(a) Follows repeated acute attacks. (b) Slow poisons (alcohol, tobacco, gout, rheumatism). (c) Errors of diet. (d) Anæmia and chlorosis.

I. (a) In simple gastritis the mucous membrane is hyperæmic, swollen, and covered with much thick mucus. There are localized areas of ecchymosis and often small erosions. In severe cases there is considerable denudation of epithelium, with perhaps an exudate of grumous blood. (b) Phlegmonous or suppurative gastritis may exist in two forms: the abscesses may be small, multiple, and miliary, or they may be diffuse. The pyloric end is most commonly involved. The submucous and muscular layers are much altered, being swollen, œdematous, purulent, and sometimes even bloody. The mucous membrane overlying the abscess may be normal in appearance, it may slough off, or, again, it may be swollen and hemorrhagic. Abscesses generally grow towards serous, and not mucous, surfaces. On the other hand, the surface is sometimes studded with numerous areas of focal necrosis of a yellowish appearance, and, on section, may discharge pus. (c) Diphtheritic gastritis sometimes follows laryngeal or pharyngeal diphtheria, and frequently accompanies pyæmia, scarlet fever, variola, and malignant endocarditis. In this form of gastritis we find a variable number of circumscribed areas of false membrane firmly adherent to the underlying structures and leaving a raw surface when removed. It is apt to attack particularly the crests of the rugæ. The diphtheritic patches are usually surrounded by areas of more or less pronounced congestion. (d) In toxic gastritis the appearance of the viscus depends upon the amount of contained food at the time of ingestion and the concentration and kind of poison. If the latter is diluted, the mucous membrane alone suffers; if concentrated, all the coats may be involved. Alkalies appear to be more destructive than acids, the lesions produced resembling those of an intense congestion, more or less localized. Around an area of necrosis is a brown-black

eschar. In very severe cases perforation may follow. Sloughs or ulcers are almost invariably found where the poison has been concentrated. Mycotic gastritis may be due to: (a) Anthrax. (b) Favus. (c) Thrush. II. *Chronic*.—(a) *Hypertrophic*.—Virchow calls a condition of the mucosa when there are swelling, cloudiness, and a yellow color, gastritis parenchymatosa or glandularis; it is due to poisons, as arsenic and phosphorus, to acute infectious diseases, to acute atrophy of the liver, etc. This may be localized or diffuse. In the former case numerous mucous polyps can be seen over the affected area. This variety occurs in drunkards. These warty elevations show considerable cystic degeneration. In the diffuse variety the stomach is almost invariably enlarged and the walls are thickened, particularly the mucous coat, which is decidedly velvety both to sight and touch, slate gray in color, with insular, deeply injected areas of scarlet and brown-red thickened patches. Besides being swollen, rugæ are often present in exaggerated folds. Petechial hemorrhages and areas of pigmentation are common. There are often evidences of previous ulcerations (cicatrices). The stomach frequently contains a variable quantity of thick, tenacious, sour-smelling, greenish mucus. (b) *Atrophic*.—When this variety of the disease exists the walls of the stomach become thinner. There is connective-tissue overgrowth, which by its contraction causes the epithelial cells to undergo degeneration and disappear. The mucous membrane is thin, smooth, and pigmented.

In hemorrhage from the stomach, if the blood come from without, as from a rupture of an aneurism, the stomach presents but few changes. The blood may be fluid or clotted; it may be bright red or dark in color. When the hemorrhage is due to actual disease of the stomach, this blood is apt to be coffee-brown. Petechial hemorrhages in the mucous membranes are common. Extensive hemorrhage from the wall of the stomach is most usually associated with gastric ulcer. Behrend reports the autopsies of three cases in which death resulted from the diagnostic and therapeutic inflation of the stomach with carbon dioxid gas.¹

THE LIVER AND GALL-BLADDER.—The clinician, having felt the lower border of the liver during life, often wants to know its exact situation at the postmortem, and is disappointed, on reading the report of the autopsy, if he does not there find what he desires. The attach-

¹ *Med. News*, December 19, 1903.

ment and the presence of any lesions near the suspensory ligament are carefully noted. In the round ligament are sometimes found small collections of blood in places where this vessel has not become entirely obliterated. The bile may now be collected in a sterilized tube such as is described on page 383. The so-called "corset-line" produced by tight lacing may be due to other causes, as a pleuropneumonia or subphrenic abscess. The grooves at times running anteroposteriorly on the upper surface of the liver, known as Liebermeister grooves, are the result of pressure by hypertrophied portions of the diaphragm. Beaver-tailed livers of the left lobe are not infrequent.

The liver is removed from the body by severing its attachments to the diaphragm, falciform ligament, blood-vessels, and ducts, and breaking up existing adhesions. For this purpose traction is made by introducing the left hand behind the right lobe and raising the liver so that it hangs over the ribs of the right side (Fig. 124). Nauwerck removes the organ by finding the hepatoduodenal ligament and then, introducing the index-finger into the foramen of Winslow, pulling it somewhat towards the duodenum and cutting, from right to left over the finger, the ductus choledochus to the right, the hepatic artery on the left, and, finally, the portal vein with its four main branches lying between the two posteriorly (Fig. 122) and quite constantly distended with blood. The liver is then weighed and measured, and the color, normally of a chestnut brown, and the condition of the surface are noted. The true color of the surface of the liver is best determined from an examination of its anterior aspect, as its lower part is apt to be bile-stained and, being in contact with the intestine, is more apt to show post-mortem changes. The right and left lobes may sometimes be measured separately with advantage. I have sometimes made a tracing of the outline of the liver by cleansing it from blood, placing it on paper, and then drawing with a pencil its outlines, indicating in their proper places any lesions which may be noted or the areas from which pieces are cut for microscopic study. As blood, when fresh, is quite adhesive, the paper must not be folded until any blood which may be on it has dried. After examination of the serous surface of the gall-bladder and duct, the sac should be laid open by a longitudinal incision carried through the duct. To find the ductus choledochus, first note the situation of the gall-bladder and then follow down the cystic duct either with the eye or by dissection to where the hepatic duct joins it. The bile duct running to the right of the portal vein

may then be dissected out to its outlet at the papilla in the duodenum. In case the liver is to be removed at once, the dissection should be continued beyond the place where it is to be cut. Should resistance be met in the passing of a probe during the process of dissection, such a part should be at once investigated. The hepatic duct may be opened with scissors until it has branched several times in the substance of the liver. A bacteriologic examination of the bile ducts or gall-bladder may now be made. It will be recalled that the portal vein

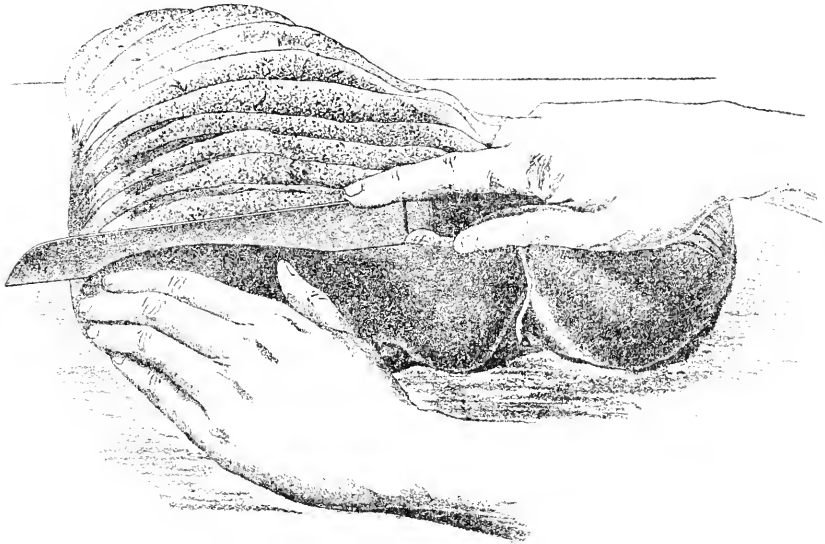


FIG. 125.—Method of incising the liver. Long parallel incisions are made from the right lobe to the left, care being taken not to cut entirely through the organ, which would prevent reconstructing it to its normal state, nor to extend the incisions so deeply as to injure the gall-bladder. If desired, the liver may now be turned and a second set of incisions at a right angle to the first may be made upon its posterior aspect. The structures of the under surface of the liver have been previously dissected out in a manner similar to that described in the case of the lungs. The history of the case will usually give information as to which of the vessels may have to be sacrificed in the dissection. On p. 379 will be found methods for injecting the vessels with different colored materials.

is formed by the union of the splenic and superior mesenteric veins and after running three or four inches divides in the liver substance into two main branches. The inferior mesenteric vein may empty into the splenic or superior mesenteric or take part in the formation of the portal vein.

The liver is laid on its posterior surface and a series of parallel incisions about half an inch apart, which do not completely pass through the organ, are made, either longitudinally or, still better, transversely (Fig. 125).

In pernicious anæmia the presence of free iron may be shown by placing a thin strip of hepatic tissue in a ten per cent. solution of potassium ferrocyanid for several minutes and then washing it thoroughly with a two per cent. solution of hydrochloric acid. The production of a blue color (Prussian blue) indicates the presence of iron. When Lugol's solution is applied to test the presence of the amyloid reaction, it is well to remember that the glycogenic reaction is also produced by the iodine. A weak solution of the violet of Paris is recommended by Letulle for securing the amyloid reaction. Observe: Bile ducts: (*a*) calibre,—normally that of a thin goose-quill, may be closed or may be of the size of a finger; (*b*) gall-stones; (*c*) ulcers. Portal vein: (*a*) color of blood; (*b*) thrombosis; (*c*) calibre,—may be thin, as result of old inflammation; (*d*) periphlebitis. I recall a case operated upon for cirrhosis of the liver where the postmortem showed an infected thrombus of the portal vein. Gall-bladder: (*a*) size; (*b*) adhesions; (*c*) tumors; (*d*) contents,—1, bile (note its color,—light or dark yellow, reddish yellow, greenish yellow,—quantity, quality, etc.); 2, foreign bodies,—gall-stones; 3, mucous membrane,—thickening, change in color, and inflammation. Liver: (*a*) position; (*b*) size,—increased in parenchymatous inflammation, decreased in atrophy; (*c*) form,—fissures or granular distortion of surface; (*d*) color,—brown or brownish red normally, yellow in fatty infiltration, dark brown in atrophy, gray in amyloid and interstitial overgrowth, ochre-yellow in acute yellow atrophy, green in icterus, or dirty green when decomposition sets in; (*e*) consistence,—normally rather hard (pitting soon disappears), increased in amyloid disease, the pitting remaining for some time, softer in parenchymatous affections and early stages of acute yellow atrophy, fluctuates in echinococcus cysts and abscesses; (*f*) capsules,—normally transparent, but thickened in chronic inflammation, syphilis, etc.; (*g*) section,—smooth, uneven, rough, or granular; (*h*) lobules,—notice that they are separated by connective tissue, more distinct in cirrhosis, less so in acute yellow atrophy. It is well to remember that in man the separation of the lobules by the connective tissue of Glisson's capsule is not at all well marked. Observe whether the lobules are larger or smaller than normal. Notice that the color is darker in the centre of the lobule than at its periphery (cyanotic induration). See if the periphery is yellow (fatty infiltration). On section note whether the tissues retract. Miliary tubercles are especially difficult of recognition in a hobnail liver.

PANCREAS.—The position of the pancreas having been determined in the preliminary examination of the abdominal cavity, its isolation and detachment are attended by no difficulty unless there be disease of neighboring parts, in which case its removal may necessitate taking an additional viscus with it. Many students are singularly unfamiliar with the normal anatomy of the pancreas, the splenic artery often being mistaken for the pancreatic duct and the sensation of hardness which this gland normally imparts to the touch being regarded as an evidence of sclerosis; the head and tail of the pancreas, too, are not infrequently left in the body and thus escape examination. In warm weather the pancreas is early affected with signs of decomposition, demonstrated by a brownish-red color, softening of its tissue, and the escape of a greasy brownish-red serum. Disease may extend from the pancreas to the portal vein, bile ducts, pylorus, or duodenum, or from these organs to the pancreas. Hemorrhages, tumors, degenerations, calculi (they may be found in the intestines), atrophic changes, cancer, cysts, etc., may be found in this organ. The possible presence of fat necrosis—a not infrequent cause of sudden death—should be borne in mind. The submucous, interstitial, or subperitoneal patches of pancreatic tissue in the wall of the intestine should not be forgotten. Accessory pancreases may be found in the stomach, intestines, and mesentery, the opening usually going to the intestinal tract. Langerhans's islands have been absent in nearly all the accessory pancreases examined.

EXAMINATION OF THE RETROPERITONEAL LYMPH-GLANDS, DIAPHRAGM, VENA CAVA, CHYLE-DUCT, ETC.—The retroperitoneal lymph-glands, best exposed by dividing the vertebral attachments of the mesentery at its roots, may be thickened from inflammation (as in syphilis) or be the seat of primary tumors (especially sarcoma and lipoma), secondary cancer, amyloid degeneration, and tuberculosis, or may have undergone changes due to various other inflammatory, cystic, and systemic affections.

Examination of the diaphragm may reveal the existence of hernia, abscess on the under surface, perforation (as in echinococcus cysts or amœbic abscess of the liver), trichina spiralis, inflammation of its serous investment, fatty degeneration and brown atrophy, hypertrophy (as in obstruction to normal respiration), atrophy (as in pseudo-hypertrophic muscular atrophy and lesions of the phrenic nerve), etc. The muscular fibres of the diaphragm may undergo granular, cloudy,

or fatty degeneration. Traumatic rupture and congenital deficiency are occasionally met with.

The vena cava and the aorta should be inspected for signs of inflammation, thrombosis, etc. To remove the aorta it should be grasped as high up as possible, drawn forcibly forward, and cut obliquely from within and above outward and downward. In order to secure a firmer hold one finger may be inserted into its lumen. (Orth.) Its elasticity should always be tested by pulling both longitudinally and laterally. The color should also be noted and the presence of atheromatous patches and plates described, especially when found around or near the point of exit of its various branches.

The receptaculum chyli rests behind the aorta, mainly on the body of the second lumbar vertebra, and between the pillars of the diaphragm and the insertion of the psoas muscles. It arises from three roots which spread out over the third lumbar vertebra. As the thoracic duct ascends, it crosses above the left azygos vein, and lies between the aorta and the right azygos vein, and has a caliber of from three to eight millimetres. At the fourth dorsal vertebra it passes behind the œsophagus and opens into the left subclavian vein, at or near the entrance of the left common jugular vein. It is readily found by dissecting away, with an up-and-down movement of the tip of a grooved director, the cellular tissue situated at the top of the arch of the aorta and the œsophagus. This is near the left subclavian artery and *before* the duct which bends around this artery, like a shepherd's crook, to terminate in the vein. It has a rosy-white tint with longitudinal striæ, and at this point gives off few collateral branches. The azygos vein is much larger and not nearly so elastic. It can be opened by splitting with a pair of fine scissors. The *right* thoracic duct empties into the vena anonyma and collects the lymph from the upper part of the right thorax, neck, heart, and upper extremity. Failure to find the duct may be due to its previous removal while still attached to the descending thoracic aorta. Tuberculosis of the thoracic duct is quite common in abdominal tuberculosis. Leaf's translation of Cunéo and Delamere's *The Lymphatics*, contains much valuable information.

Abscesses in the psoas muscles may be secondary to Pott's disease, coxitis, perforation of the intestine, tumors, etc. Examine the spinal column for kyphosis, lordosis, and scoliosis. In death after fright and from chloroform narcosis much blood is found in the abdominal veins, as the result of vasomotor paralysis.

CHAPTER XI

DISEASES OF THE GENITO-URINARY TRACT

KIDNEY.—No little confusion exists in the description of the pathologic lesions of the kidney, owing to the multiplicity of terms employed. A classification of inflammatory renal diseases depending upon the structure affected is: (1) epithelial (parenchymatous or desquamative) nephritis; (2) fibrous (interstitial) nephritis; (3) vascular nephritis. Bright based his description clinically upon albumin in the urine and the presence of dropsy. The epithelial cells which eliminate substances from the blood are granular, a non-granular variety lining the ducts. It should be borne in mind that there is no such thing as a perfectly pure form of nephritis and that the condition which predominates gives the name to the lesion. For example, when we speak of parenchymatous nephritis, we do not mean that the epithelial cells alone are affected without involvement of the connective tissue, for it is entirely proper to describe a case as chronic parenchymatous nephritis in which the interstitial changes are beginning to predominate. The character of the nephritis is frequently designated by the application of a term descriptive of some prominent features, as acute hemorrhagic nephritis when petechial hemorrhages are prominent; glomerulonephritis when the epithelium of the glomeruli is especially affected.

Amyloid Changes.—These may be due to (a) prolonged suppuration (tuberculous or syphilitic), (b) chronic disease of the kidney, or (c) deficient cardiac compensation. The amyloid kidney is usually enlarged (the condition occasionally occurs in a contracted kidney), pale in color, and firm in consistency. The capsule is adherent in places and shows petechial hemorrhages beneath it. The cortex is increased in size. The glomeruli are first affected and usually prominent, although the cortex is pale in contrast to the somewhat reddish color of the pyramids. The organ has a bacony or waxy appearance. The urine contains albumin. The tube-casts are hyaline, waxy, or finely granular. Œdema of the extremities is common. The large white kidney may or may not show amyloid degeneration.

Congenital Defects.—(1) Total absence. (2) Absence of one, with hypertrophy of the other. (3) Rudimentary, cystic. (4) Du-

plication. (5) Partial coalition, usually lower end (horseshoe). (6) Remnants of fetal lobulation.

Congestion.—(a) In traumatism the kidney is large; the capsule is tense; the color is dark red. On opening the capsule the contents are found to be soft and bulge out and blood drips freely from the surface of the section. The dependent portions are more congested than the cortex. In passive congestion the organ is enlarged and firm; the capsule strips off readily; the cortex is wider than normal; the surface on section looks coarse and connective tissue is plainly visible; the cortex is of a deep-red color and the pyramids are of a purple-red. Congestion may be due to (b) drugs, as cantharides or turpentine, (c) infectious fevers, (d) alterations of the circulation in the kidney itself or in the vena cava (rare), (e) valvular lesions of the heart, (f) diseases of the liver, or (g) diseases of the lungs. Hæmatoma of the kidney occurs, sometimes reaching a large size and holding over a quart of blood and clots.

Cystic Disease.—(a) Congenital cystic kidneys are greatly enlarged, so much so at times as to impede labor. There may be a conglomeration of cysts varying in size from that of a pea to a small apple. In some cases no renal tissue can be seen without the aid of a microscope. The cysts are lined with flattened epithelium and contain a fluid in which are found albumin, blood-crystals, cholesterin, triple phosphates, and fat-drops. (b) Chronic nephritis (which see). (c) Adenocystomata, of similar origin as the corresponding cysts in the ovary. (d) Concretions block up the uriniferous tubules and press upon the still-intact epithelial cells, which later become flattened and disappear. The stroma and vascular supply are next affected and a cystic condition is produced, or the disease may progress to the formation of large concretions.

Hydronephrosis.—The outflow of liquid from the pelvis of a kidney may be obstructed by (a) congenital deformities, as when the pelvis comes off too high up on the kidney, (b) twists of the ureter, (c) calculi, (d) morbid growths, or (e) cicatricial bands. There is an accumulation of non-purulent fluid, which by steady pressure produces an atrophy of the organ and a gradual distention of its pelvis. The papillæ become more flattened and disappear, and their place is taken by concave recesses in the medulla, which becomes narrower. In extreme cases the kidney may be converted into a large cyst with some imperfect septa. There may be an enormous quantity of the contained

fluid or only a few ounces. It is yellowish in color and contains urea, uric acid, and sometimes albumin and sugar. There is usually compensatory hypertrophy of the opposite kidney.

Infarcts.—(a) Calcareous infarcts extend through the tips of the papillæ as stripes through one-half or more of the medulla, mainly along the canals, but also in interstitial tissue. There is effervescence on the application of hydrochloric acid. (b) Uric acid—found as acid ammonium urates in very young children and as acid sodium urates in mature years in cases of gout—may be deposited within the kidneys in the form of flakes (uric acid nephritis or gouty kidneys). In babes they appear as yellow radiations from papillæ into medulla, and show that the child was born alive, as they occur only after breathing has taken place. Sodium hydrate dissolves the acid ammonium urates. (c) Hæmoglobin occurs in hæmoglobinuria. It exists in the canals first as lumpy brown, later as granular, and seldom as crystalline masses. Hæmatoidin crystals are seen where old hemorrhages were (Virchow). (d) Bilirubin infarct gives the bile reactions. It occurs in the icteric new-born, in acute atrophy of the liver, and in progressive pernicious anæmia. (e) Infarcts caused by salts of silver are very rare. (f) Hemorrhagic infarcts. (g) Anæmic infarcts.

Interstitial Nephritis.—In acute interstitial nephritis the whole kidney is increased in size; the color is uniform, making it hard to distinguish the border line between the cortex (which is swollen) and the medulla. The process is essentially a productive one. There is a marked migration of the leucocytes and the connective tissue undergoes proliferation. The cells increase in number and the intercellular substance disappears. Pus-cells lodge between the epithelial cells, and the lumina of the canals can no longer be followed. Such areas may be found anywhere in the kidney substance. The process is essentially due to pyogenic bacteria brought from the heart, as in malignant endocarditis, or the uterus, as in puerperal sepsis. The process ends in abscess formation, often affecting the perinephric tissues. (Langerhans.) A similar condition may start from without the kidney or extend up from the pelvis or farther down the urinary tract.

Chronic interstitial nephritis may start as an acute form, but most frequently affects alone the connective tissue of its stroma, the blood-vessels not being involved. The process naturally ends in contraction. The canals are freed from their epithelial cells and the glomeruli may be brought so close together as to touch each other. The capsule is

adherent and the surface lumpy or granular and grayish red in color. The cortex is much smaller and may measure only a few millimetres in thickness, but its consistence is markedly increased. Compensatory hypertrophy may occur. If the canals are fatty they appear as yellow stripes or points. Cysts are common and are most marked at the junction of the cortex and medulla. The vessel walls are thickened. Localized interstitial nephritis is usually syphilitic, while the diffuse form is due to gout, lithæmia, lead, over-indulgence, alcoholism, etc. In the latter form we have granular atrophy, the so-called red granular kidney, in which, as contraction takes place, cysts are found.

Movable Kidney.—(a) Especially in females. (b) Due to absorption of perinephric fat. (c) Repeated pregnancies. (d) Traumatism. (e) Displacement by tumors. As a rule, the displacement is not great. The kidney usually moves downward or upward and inward, generally rotating so that the outer border and upper end move forward and the hilum is directed inward and backward. Nearly all cases are associated with a medial displacement of the colon. The right kidney is the one most frequently affected.

Parasites.—Of the parasites the following are found: (a) *Distoma hæmatobium* (*Bilharzia hæmatobia*). (b) *Filaria sanguinis hominis*. (c) Echinococci. (d) Cysticerci. (e) *Pentastoma*. (f) *Strongylus gigas*. All are rare in this country.

Parenchymatous Nephritis.—Acute diffuse inflammation of the kidney is due to: (a) Acute infectious fevers. (b) Poisons,—*e.g.*, turpentine, arsenic, etc. (c) Traumatism. (d) Exposure to cold and wet. Macroscopically the organ is swollen, tense to the touch as the capsule is stretched, but the substance of the kidney is softer than normal, the color is gray to yellowish, and the stellate veins on the surface are prominent. The capsule strips off easily and is somewhat thinner than when normal. On slitting the capsule the renal substance bulges out. The cortex, which is increased in amount, is somewhat pale, swollen, and soft; the glomeruli appear as minute red dots. The pyramids are distinct and striated. The radiations in the medulla may be gray or transparent, gelatinous or watery. The larger blood-vessels are overfilled and prominent.

Parenchymatous Nephritis, Subacute.—The large white kidney is more swollen than in the acute form and the tissue itself is of denser consistency. The width of the cortex may be increased, therefore, before contraction commences. Yellow spots where the degenerative changes

are most marked are found in the gray glossy substance. Cysts are absent, unless interstitial changes are associated. The kidney is dry on section, and the pyramids of the medulla show reddened stripes pointing towards a papilla. This condition may be associated with amyloid degeneration, most marked in the glomeruli. The mucous membrane of the pelvis is frequently swollen and of a pinkish color. Microscopically the changes are those of an acute diffuse inflammation, including cloudy swelling, proliferation, desquamation, and a granular change in the cells lining the tubules. The straight collecting tubules may entirely escape, though there is a form of catarrhal nephritis, usually of an ascending variety, in which this part of the kidney is alone affected. In the surgical kidney there is an acute parenchymatous nephritis with abscess formations. Each individual cell is larger, the transverse diameter of the tubule increased, and the lumen diminished or even obliterated. Death most frequently takes place before the degenerative changes are complete; otherwise resorption and contraction follow, and on the surface there are slight indentations, often associated with a hemorrhagic condition, hence bloody casts, as in poisoning by cantharides and potassium chlorate, where even pigmentary infarcts may be found. The urine is scanty, high colored, albuminous, and contains casts and free blood. There may be an extensive œdema, with effusions into the serous cavities.

Parenchymatous Nephritis, Chronic.—This process is latent and runs a slow course, often of years; not all of the kidney is affected at once, some portions showing normal parenchyma, while at other places degenerative changes are going on and at still others degeneration is complete and the parts are already in an atrophic condition. The cortex contracts irregularly, and has not the regular granular appearance seen in the kidney affected with interstitial nephritis (Langerhans), nor is there much increase in the stroma except at those places where contraction has taken place.

Perinephric Abscess.—(a) Traumatism. (b) Extension of inflammation from the kidney or from neighboring organs. (c) Perforation of the bowel. (d) Infectious fevers, particularly in children. The kidney is surrounded by pus, a thick coating being found posteriorly. The abscess-cavity is usually extensive. The pus is often offensive and may have a distinctly fecal odor. It may burrow and discharge into the lung, bowel, peritoneum, or bladder, or it may follow the psoas muscle and appear in the groin.

Pyelitis and Pyelonephritis.—Due to: (a) Tuberculosis. (b) Infectious fevers. (c) Calculi. (d) Cystitis. (e) Tumors. (f) Drugs. (g) Cold and wet. *Classification.*—(a) Simple catarrhal. (b) Purulent. (c) Hemorrhagic. (d) Calculous. In simple acute pyelitis the mucous membrane of the pelvis is swollen, hemorrhagic, and turbid. In the purulent form the mucous membrane is swollen and covered with a cream-like exudate of a yellowish or yellowish-green color. Ecchymoses are common. The kidney itself is enlarged, softened, œdematous, grayish in color, and shows little distinction between cortex and medulla. Areas of necrosis or miliary abscesses are distributed through the kidney substance. The kidney may attain the size of a human head. It is usually firmly adherent to the adjacent organs, tissues, and vessels. A quart of pus may be contained in the cavity; in these extreme cases all traces of the gland substance may be lost. The hemorrhagic variety occurs in anthrax, sepsis, and leukæmia. In calculous pyelitis the mucosa is roughened, grayish in color, and thickened. There are also more or less dilatation of the calyces and flattening of the papillæ. These may be covered by a gray membrane. After the renal substance has been destroyed, if the pelvic orifice is still obstructed, the pus may become inspissated and ultimately impregnated with the salts of lime.

Stones.—The following varieties of stone may be found in the kidney or its pelvis: (a) Oxalate. This is very hard, dark, brownish yellow or gray in color, with rough surface and of mulberry shape. (b) Uric acid. This is usually smooth or a little rough, light brownish yellow in color and often striped, and of medium consistence. (c) Phosphate stones are white, crumbling, and chalky. (d) Cystin and xanthin stones are rare. Shield¹ reports a case of gigantic renal calculus, removed during life, which when dry weighed over a pound. It measured $5\frac{1}{2}$ inches long.

Tumors.—(a) Fibromata are the most common of benign tumors. (b) Lipomata. (c) Myxomata. (d) Myomata. (e) Angiomata. (f) Lymphadenomata (or lymphomata). (g) Rhabdomyomata. (h) Carcinoma may be primary or secondary; it is comparatively rare. The cancer may infiltrate the whole cortex or may be knotty and separated sharply from the surrounding tissue. (i) Sarcoma may be primary or secondary. It is more common than cancer, and may

¹ *Lancet*, October 15, 1904.

attain an enormous size. (*j*) A group of tumors usually occurring in children and containing various histologic elements, connective, muscular, and epithelial tissue, that Birch-Hirschfeld classes together as embryonal mixed tumors. (*k*) Patches of adrenal tissue may start growing and give rise to large tumors, the so-called hypernephroma heterotopes. Such growths are by no means rare. (*l*) Deposits of liver-tissue have been reported as occurring in the kidney, especially in the cortical layer.

URETERS.—In some malformed fetuses both ureters are absent. In other cases double bilateral ureters are found. They may open into the vagina or the uterus. Stenosis often occurs as a congenital or acquired condition. Cysts and polyps are found not infrequently. Parasites, as the *Distoma hamatobium*, round worms, and echinococcus, are found. A calculus may fill the pelvis of the kidney and extend down in the ureter.

BLADDER.—The color of the vesical mucous membrane is normally a pale gray, but is red in recent inflammation and blackish red if the inflammation be very severe. The mucosa affords a favorite location for the multiplication of various organisms, which usually reach the bladder either from the kidney or from the urethra. Typhoid bacilli may frequently be detected in the urine of patients suffering from typhoid fever. Cystitis is due to irritants in the urine, extension of inflammation from adjacent parts, traumatism, septic infection through the blood of the urethra, infectious diseases, and most frequently occurs in stricture of the urethra, enlarged prostate, or diseases of the cord (myelitis). It may be œdematous and especially hyperæmic after the ingestion of certain poisons, as phosphorus and cantharides. When cystitis is caused by the colon bacillus, the blood of the patient may give the agglutinative reaction in a dilution of one to fifty with this bacillus and thus show invasion during life. In acute cases the mucous membrane is swollen, reddened, and covered with a thin film of mucus or pus. The veins may be distended, especially when hemorrhoids exist and venous thrombosis occurs. When hemorrhage has occurred, the surface of the membrane is of a universal gray tint or mottled with gray, black, or reddish-brown patches. In severe cases necrosis, abscess, or even perforation may occur. In the diphtheritic form of the disease necrotic patches are seen and also small hemorrhages in the region of the trigone and the surrounding fundus. These tend to increase in size. There is submucous swelling, which subsequently

becomes infiltrated with pus. The whole mucous membrane over it degenerates and can easily be removed from the muscular coat. In chronic cystitis the bladder may be enlarged, but it is often smaller than when normal. The various coats are much thickened and there may be true hypertrophy of the muscular coat. This condition is best seen in cases of long-standing chronic cystitis, where the inner surface may even be thrown into folds and roughened so that the picture resembles that of the interior of a heart, and shows how difficult it is for injections into the bladder to cleanse thoroughly the walls when there is inflammation. In severe cases the inner coats often feel rough and sandy to the touch, on account of encrusted salts. Gangrene and tuberculosis may occur. There is a considerable variety of tumors to be found in the bladder: papilloma, adenoma, carcinoma, fibroma, myoma, sarcoma, cavernous angiomata, dermoids, and mixed tumors. Pockets (diverticula) may develop in the walls of the bladder, sometimes being covered only by the peritoneum. Their openings may be very small, though the size of each diverticulum may reach that of a hen's egg. These pockets are at times produced by and may contain stones. In exstrophy the inner surface of the bladder is exposed externally above the pubes through a hiatus in the median abdominal wall. The intestines may protrude into or open through the bladder. Professor Guitéras once related to me an interesting case of primary diphtheria which developed upon this exposed mucous membrane. The organ may be completely or partially divided by an anteroposterior septum. The bladder may be entirely absent or may be double. Cases have been reported in which the two bladders were of the same size and located the one behind the other. The remnant of the urachus may undergo cystic change. In hypertrophy dilatation of the cavity exists along with increase in the thickness of the wall, which may exceed an inch. The female bladder may become inverted and appear through the urethra. It may also take part in herniæ of various forms. The bladder may be ruptured by external violence, of which there may be no external visible sign. In overdistention the bladder may reach to the umbilicus. It may open into the rectum or vagina (vesicorectal or vesicovaginal fistula). In the interesting condition called trichosis vesicæ the hair is usually referable to the breaking of a dermoid cyst into the bladder or it may be a product of growth from the mucosa itself. In one case—an autopsy on a female—I could not see where the dermoid had arisen if not in the walls of the bladder itself.

In a body examined at the Pennsylvania Hospital a bundle of hair was found which had become encrusted with salts, thus forming a calculus.

Garrod¹ gives the following causes of black urine: (1) jaundice, especially when of long standing; (2) hæmaturia; (3) hæmoglobinuria; (4) hæmatoporphyrinuria; (5) melanotic sarcoma; (6) alkaptonuria; (7) ochronosis; (8) abundance of indican; (9) long-standing pulmonary tuberculosis; (10) the taking of certain drugs and articles of diet; (11) certain rare cases of undetermined nature.

Vesical calculi, usually associated with some form of cystitis, may contain any of the normal or abnormal constituents of the urine. If this liquid be allowed to stand, precipitation occurs, the character of which depends upon the acidity or alkalinity of the urine. Bacteria in the body may cause an alkaline decomposition, with the formation from urea of carbon dioxide and ammonia, which uniting with the uric acid forms ammonium urates and triple phosphates. The most important sediments are uric acid, sodium urate, ammonium urate,—all of which give the murexid test.—calcium oxalate, calcium carbonate, calcium diphosphate, calcium triphosphate, and triple phosphate. Concretions may be found in the form of sand or as calculi. They are held together by an albuminous or cement-like substance, to which may be added cast-off epithelial cells, shreds of tissue, blood, mucus, etc. Primary stone formation may take place in urine which has not undergone decomposition; such calculi are usually composed of uric acid and urates. Secondary stone formation occurs in an alkaline urine, the starting-point being a foreign body introduced through the urethra from without or a small calculus which has found its way down from the kidney; these stones are apt to be composed of ammonium urates and phosphates. They often consist of different substances concentrically arranged. Metamorphosed calculi are produced, for example, where a primary stone has been partially dissolved by the action of an alkaline menstruum and the remainder covered by secondary deposits. (Schmaus.) Calculi assume a large number of shapes and differ much in size. In addition to those named above, cystin and xanthin stones exist.

Parasites in the bladder are rare. The following have been found: (a) *Distoma hæmatobium* (*Bilharzia hæmatobia*). (b) *Filaria sau-*

¹ *The Practitioner*, March, 1904.

guinis hominis. (c) Echinococci. (d) Cysticerci. (e) *Pentastoma.*
(f) *Eustrongylus gigas.*

FEMALE GENITAL TRACT.—*Fallopian Tubes.*—One Fallopian tube may be absent or rudimentary, and, on the contrary, I have seen an oviduct lengthened to over ten inches by traction from a growing uterine fibroid, and have observed in a tube extra openings supplied with fimbriæ, the presence of which might at times have an important bearing upon the question of ectopic pregnancy. This dangerous condition may occur anywhere within the tube, or the fecundated ovum may escape into the abdominal cavity or become caught in a corpus luteum of either ovary. It is doubtful whether ovarian extra-uterine pregnancy ever existed; in two cases so diagnosed and brought to me for examination, careful study showed that fecundation occurred near the ostium, and the fimbriated extremities became attached to the ovary just as in a case of ovarian abscess, making it appear as if the pregnancy had started in the ovary. Zinke tabulates a series of 88 cases of simultaneous intra- and extra-uterine pregnancies. An interesting abnormality is lithopedion, in which condition a foetus may stay in the abdominal cavity for thirty or forty years with certain of its tissues remaining recognizable. The convoluted interior of the oviduct offers a favorable place for the growth of various organisms, especially the *Gonococcus*, the *Streptococcus*, the colon bacillus, and the organism of tuberculosis. The tube itself may be affected with cysts and with many kinds of benign and malignant tumors, the latter being primary or metastatic. It is subject to different forms of hemorrhage.

In acute salpingitis the Fallopian tubes are swollen. The neighboring blood-vessels are dilated, tortuous, and overfilled with blood. There is often a considerable exudate on the serous surfaces, causing adhesions of the tubes to the surrounding structures. On section the lumen of the tubule is found to contain serum (hydrosalpinx), mucopurulent matter (pyosalpinx), or hemorrhagic fluid (hæmatosalpinx). The tube may rupture and give rise to a general peritonitis. The mucous membrane is thickened, swollen, and often intensely congested. To show the ciliated cells, though these may have been shed by the inflammatory process, care must be taken to harden the tissue at once after removal and according to the methods for showing karyokinesis. In chronic (proliferous) salpingitis the tubes may become enormously thickened, hard, and resistant to the touch. The adhesions to surrounding tissues are very marked and more or less completely organ-

ized. The new connective tissue may contract and so alter the appearance of the oviducts that they bear little resemblance to the normal.

Ovaries.—These show perhaps a greater variety of pathologic changes than any other organ of the body. The ovary may be divided into lobes by bands of connective tissue, or actual duplications of the parts may occur. Supernumerary ovaries are found. An ovary may form part of a hernia; in a child, I found one in the canal of Nuck. The organ may be absent, hypoplastic, or prolapsed in an abnormal position. As the opportunity arises, study the differences between a true and a false corpus luteum and a corpus hæmorrhagicum. These glands are subject to various forms of inflammation, an entire ovary at times being converted into a pus-sac. They are often bound down by adhesions, and in later life undergo senile atrophy and may even become calcareous or calcareous concretions may be found in them. In certain conditions they may undergo hypertrophy. Among the tumors here found may be mentioned adenomata, dermoid cysts, which are of an almost endless variety, enchondromata, endotheliomata, fibromata, fibromyomata, myomata, cancers, cystomata, sarcomata, psammocarcinomata, angiomas, etc. Dropsy of follicles, fungous excrescences, and tuberculosis occur. Dermoids of the ovary are closely related to malformations and pass without sharp division into true monstrosities. (Orth.) Ovarian cysts may grow to an enormous size and weigh nearly 300 pounds. Wagner reports a case treated by puncture in which during eight years 9867 pounds of fluid were drawn off from the tumor. The ovaries may be enlarged in mumps.

Uterus.—In examining the womb notice any abnormalities on the exterior and be sure to search every portion of the interior for any lesions which may exist. The situation of the organ may be markedly altered, and its individual parts may present abnormal relations to each other. Thus, we may discover antelexion, anteversion, retroflexion, retroversion, prolapse, inversion, dilatations, elongations, bendings, or even find it forming part of an inguinal or a crural hernia. The chief congenital malformations are uterus bicornis, bicornis duplex, bilocularis, subseptus, and bipartitus, unicornis, didelphys, cordiformis, and septus duplex. The uterus is subject to atrophy, hypoplasia, rudimentary (infantile) atresia, stenosis, and hypertrophy. Uterine tumors are of great variety,—adenoma, adenocystoma, cancer, deciduoma malignum (syncytioma malignum), hæmatoma polyposum, fibroma, myoma, myofibroma, myosarcoma, lipoma, leiomyoma, hydatiform moles, at

times to the number of several thousands, etc. There is considerable elastic tissue in a myoma; little or none in a fibroma. A placental polyp may assume destructive characteristics. Fleishy moles are the result of hemorrhage into the decidua. Dermoid cysts are found. Hemorrhages are common, and, besides those due to menstrual disturbances, are often associated with polyps, cancer, etc. After parturition and after the menopause marked changes take place in the blood-vessels, which may undergo hyaline or amyloid degeneration. Infarcts are seen. The ovarian veins should be especially studied in infections of the uterus, as by this channel arise infarcts and abscess in the kidney and lungs, and right-sided endocarditis. Many varieties of endometritis exist, such as gonorrhœal, tuberculous, diphtheritic, syphilitic, decidua, fibrous, gangrenous, glandular, interstitial, catarrhal, purulent, mycotic, villous, etc. Langerhans describes an interesting case of an old woman in whom the womb was so enlarged by a solid mass of thrush fungi and other bacteria that it measured some two inches in diameter. The uterus may rupture, as from childbirth, trauma, etc. A case is reported of a Cæsarean-section scar rupturing at a following parturition. Anspach considers that by an examination of the elastica it can be stated whether a woman has had children or not.

In acute forms of endometritis the mucous membrane is red, swollen, and sodden; the discharge is profuse, stringy, and often purulent; in severe cases blood is present. If infection follow contusion during labor, there may develop a suppurative process which transforms the parts into a soft, stinking, grayish-green or brown mass that tends to become gangrenous. The cervix is the most often involved. In diphtheritic endometritis there is formed a thick, grayish-yellow or white membrane, the decidua lying loosely on the surface. The process may begin and remain at the placental attachment or may involve the cervical portion of the uterus. The infection may spread through the lymph stream or blood-vessels. Acute (ulcerative) endocarditis is a frequent complication of puerperal infection. In hemorrhagic endometritis the mucous membrane is red from engorgement of blood-vessels and numerous punctiform hemorrhages. It is distinguished by the condition of the ovaries from a similar appearance in menstruation. Tuberculous endometritis sometimes resembles carcinoma in gross appearance, but on microscopic and bacteriologic examination shows the presence of tubercle bacilli.

In chronic hypertrophic endometritis there is a hyperplasia of the mucosa, with softening and congestion, forming polypoid excrescences; the glandular structures also hypertrophy, become occluded, and form cysts of various sizes. In the cervix enlarged Nabothian cysts should be looked for. In atrophic endometritis the mucous membrane becomes thin and pigmented and the glandular structures disappear. Follicular erosion of the cervix occurs after lacerations.

Foreign bodies may be found in the uterus. These are introduced to prevent conception or to produce abortion, or find place through surgical manipulation or expulsion from some adjacent organ. Twenty-four hours after the birth of a full-term child the uterus weighs from seven hundred to twelve hundred grammes. Friable, elevated, mushroom-like fibrous masses formed after the removal of the placenta are found in the area where the latter was attached.

Vagina.—The vagina may be absent or appear as a mere connective-tissue cord. It may be wholly or partially divided by a longitudinal or transverse septum. It may be entirely closed or so small that coitus, if attempted, takes place through the urethra, which thus becomes markedly dilated. The normal flora is considerable, and of pathogenic organisms the *Gonococcus*, *Bacillus diphtheriæ*, and *Oidium albicans* (thrush) are of importance. It is well to remember that diplococci other than the *Gonococci* are frequently found in the vagina. After rape the condition of any secretion present should be noted,—whether dried, fluid, watery, or purulent; also its color and odor. Examine microscopically for spermatozoa and *Gonococci*. Observe all discharges in cases of abortion. Severe inflammation may follow, and even gangrene may supervene. Erosions, fissures, fistulæ, and lacerations are seen after labor. Syphilitic ulcers are common; those of a tuberculous nature are rare. Tumors of the vagina include cysts, carcinomata, fibromata, fibromyomata, myxomata, rhabdomyomata, and sarcomata. Malignant neoplasms of the cervix uteri may by extension of the growth involve the vaginal walls, which should, therefore, always be examined in such cases. The epithelioma is almost always verrucose or nodose. Prolapse often accompanies tumors or is seen in multiparæ accompanied by prolapse of uterus, rectocele, and cystocele. The exposed surface is eroded, and covered with ulcers and patches of necrosis. Vaginal hæmatocele, hernia, abscesses, and hypertrophic vegetations are not uncommon. Poisons, as mercury, phosphorus, and arsenic, may be found in the vagina; at times used to produce abortions.

MALE GENITAL TRACT.—*Testicles.*—The testes are subject to many lesions, but the exposed situation and the extremely specialized character of these organs are sufficient to account therefor. The undescended testicles are peculiarly liable to injury and favor the subsequent development of tumors. Adenomata, sarcomata, enchondromata, fibromata, osteomata, myxomata, and rhabdomyomata occur. Dermoids and mixed neoplasms containing cartilage are not rare. Inflammation is common. In typhoid fever the condition of the testicles should always be noted, as they may become infected with the typhoid bacillus. They may be affected by syphilis, tuberculosis, leprosy, etc. In guinea-pigs infected with glanders the testes are especially apt to become diseased. Sarcoma and cancer of these organs are often indistinguishable. Cysts also occur, often combined with tumors. Hemorrhage may take place in the tunica vaginalis and the testicle may atrophy owing to pressure from the fluid in a hydrocele. True abscesses are found in them, and the testicles may show brown atrophy, glycogenic infiltration, or pigmentary or amyloid changes. In elephantiasis they may show hypertrophy. The cords sometimes rupture and varix is common. Albers Schoenberg experimenting on guinea-pigs found that Röntgen rays caused necrospermia (in 197 minutes) and azoöspermia (in 377 minutes). Has radium a similar effect upon these organs?

Spermatic Cord.—The cord may become twisted and thus cause testicular atrophy; this condition is, as a rule, associated with undescended testicle or swollen epididymis. The cord may be thickened or lobulated. Its arteries sometimes show marked atheroma and its veins, varices. I have also several times seen the duct itself converted into a rigid, thickened tube by salt-like deposits.

Prostate.—The most common lesion of the prostate is enlargement due to interstitial hyperplasia. This is almost always accompanied by atrophy of the gland cells. Acute inflammation is very common. Abscesses occur; they are often not recognized until their sequelæ are prominent, and are usually seen in the area around the posterior urethra. Cystic formation (cystic adenoma) is seen in many enlarged prostates, but true neoplasms are much less common. Carcinomata and fibromata are the most frequent. Moderate atheroma and endarteritis are seen almost always in the arteries of the part. In men over sixty years of age small prostatic calculi or sand, often dark in color, are quite commonly found on careful sectioning of the prostate.

CHAPTER XII

DISEASES OF THE LIVER AND PANCREAS AND THEIR DUCTS¹

LIVER.—*Abscess*.—Hepatic abscesses may be multiple, often originating from the appendix, or single, as in the amoebic abscess of the tropics. Perihepatitis is usually present, and rupture into the pleural cavity may occur. See Hepatitis, p. 229.

Acute Yellow Atrophy.—This is an acute general disease described by Rokitansky in 1842, with special manifestations for the liver, presumably of infectious origin, characterized by a rapid fatty degeneration of the organ, with invariably fatal termination. Due to: (a) A specific micro-organism (?). (b) The ordinary micro-organisms of suppuration and infectious diseases have been found in this condition. (c) Certain poisons give rise to a similar condition,—*e.g.*, phosphorus. (d) Pregnancy or the puerperium. The liver is greatly reduced in size,—one-half to one-third; in one of my cases, however, the condition had been preceded by hypertrophic cirrhosis and the organ weighed over five pounds. The liver is thin, flattened, and flabby, the capsule is wrinkled, and the gland is of a pale-yellow color. Both on the surface and on section may be seen a number of orange-yellow patches, in the centre of which are usually marked hemorrhagic areas in which the liver-cells have about entirely disappeared. The remainder of the liver is of a yellowish-brown or mottled color. The outlines of the lobules are very indistinct. The bile ducts and gall-bladder are empty. Bili-rubin crystals may be seen under the microscope. If a section of the liver be allowed to remain in the air for some time, a thin, white coating appears on its surface, which on examination is found to consist of crystals of leucin and tyrosin, which may also be found in the urine.

¹ Those wishing to go more deeply into this subject will find WARING'S *Diseases of the Liver, Gall-Bladder, and Biliary System* (1897) and OPIE'S *Disease of the Pancreas* (1903) most instructive reading. VIRCHOW'S remark in his *Post-Mortem Examinations* (1876) of "the slight importance of the pancreas" is interesting as showing the small consequence attached even until a short time ago to the functional activities of this gland. An account of the "Zuckergussleber" and fibrous polyserositis will be found in ROSE, *Würzburger Abhandlungen aus dem Gesamtgebiet der prakt. Medizin*, 1904, vol. iv, no. 5, and KELLY, *Trans. Coll. of Phys. of Phila.*, 1902, p. 62. CAMMIDGE'S article on the chemistry of the urine in diseases of the pancreas is contained in the *Lancet* of March 19, 1904, p. 782.

The adjacent organs are usually stained with bile and present numerous hemorrhages, especially on the surface. The spleen is enlarged and the heart and kidney show marked fatty, hyaline, and granular changes. The color of the liver in acute yellow atrophy depends on the time at which death took place: in the earlier stages the organ is ochre-yellow, in the later stages it is mottled, and if much blood be present it is grayish red. The pathologic findings in the liver in eclampsia deserve especial mention. They are evident in every well-marked case of eclampsia and frequently present a striking picture. They consist of irregular areas of necrosis, grayish in color, intermingled with areas of diffuse hemorrhage. These changes are held by some to be the result of circulating toxins, by others to be caused by numerous minute emboli of liver-cells.

Amyloid Degeneration.—Found in cases of: (a) Prolonged suppuration, tuberculous or syphilitic. (b) Infectious fevers. (c) Chronic visceral diseases with cachexia. The liver is large in size, smooth in outline, and pale in color. The edges are distinctly rounded; small hemorrhages are common on the surface. On section the surface is anæmic, semitransparent, and infiltrated. It presents the characteristic lardaceous or waxy appearance. The process may be a localized or a generalized one; in either case staining by Lugol's solution is never uniform, as the diseased brown spots appear only in certain areas. The characteristic coloration may be seen upon the lining of both hepatic and portal vessels. Early in the disease this reaction is hard to detect, except by special stains under the microscope. Very thin pieces of the liver should be sectioned with a scalpel and put in a small glass dish. Add a solution of iodine and then wash out with water. Put something white under the dish and the characteristic coloration can be more readily seen.

Bile.—T. Kimura¹ has investigated the bile taken from the human gall-bladder shortly after death. He finds its pigments to be variable in quantity, being low in tuberculosis and high in conditions of stagnation, such as heart disease. The specific gravity varies from 1.012 to 1.040, and the dry residuum from 2.68 per cent. to 20.63 per cent. The relative viscosity varies widely,—from 1.46 to 58.24. These factors are all greatly increased in cases of obstruction of the common bile duct. Urobilinogen is found regularly, urobilin very frequently;

¹ *Deut. Arch. f. klin. Med.*, 1904, vol. lxxix, p. 274.

but both are wanting in cases of complete biliary obstruction, marked diarrhœa, and in the new-born. This fact supports the enterogenous theory as to the formation of urobilin. Normal fæces contain urobilin regularly, but it is wanting in cases of biliary obstruction. Meconium does not contain any. In a case of obstruction of the cystic duct, a hitherto undescribed brown pigment was found.

Cancer.—I. *Secondary Cancer.*—Most common. Histologically shows same structure as primary growth, which is usually in the stomach, bowel, or pancreas. The liver is enormously enlarged, irregular, and nodular. The nodules are usually symmetrical, often superficial, flattened, discrete, and umbilicated; they may be more or less evenly distributed throughout the liver. On section whitish masses of varying sizes are seen, contrasting with the red color of hepatic tissue, the yellow staining of bile, pigmentation due to blood, and the light-yellow areas of fatty degeneration. The cancerous masses may undergo fatty degeneration, suppuration, or fibroid change. II. *Primary Cancer.*—Rare. (a) Massive. Causes great enlargement. On section the mass is uniform grayish white in color, somewhat firm, and distinctly outlined from the liver substance. (b) Nodular. Large and small nodules are scattered throughout the organ. These usually consist of a primary growth and numerous secondary nodules. (c) Cancer following cirrhosis is rare. In such instances the liver is not much enlarged. Surface of section is grayish yellow, studded with nodular yellowish masses. In one of my cases of primary cancer of the gall-bladder the cancerous portions and the liver had become infected by the *Bacillus pyocyaneus*.

Cholecystitis, Acute Infectious.—There exists an acute inflammation of the gall-bladder due to: (a) The introduction of pyogenic micro-organisms,—for example, the *Bacterium coli commune* and the typhoid bacillus, *Pneumococcus*, *Staphylococcus*, and *Streptococcus*. (b) Gall-stones. (c) Extension of inflammation from the bile ducts. The gall-bladder is distended; its walls are thickened and tense. The mucous membrane is swollen, hyperæmic, and may be covered with a purulent exudate. The submucosa may also be involved. The contents of this sac are cloudy and dark in color, and may be mucopurulent or hemorrhagic. Orth states that the inflammation is usually of a necrotic character. The tissue is of a dirty yellow-brown color and sometimes is necrotic and easily torn. Gall-stones are frequently present. The cystic duct is often obliterated. There may be adhesions with the bile

duct or omentum. The common bile duct may be congenitally absent and yet the child may live for some time, in one case five months.¹ The gall-bladder may be absent without serious impairment of the hepatic function.

Cholelithiasis.—Gall-stones may be formed within the gall-bladder or in the ducts leading to or from it. Consider: (a) Most frequent in females. (b) Age, fifty per cent. over forty years old. (c) Sedentary habits. (d) Overeating. (e) Carcinoma (?). (1) The calculi are usually multiple, rarely single. They vary in size as well as in number. When multiple they are faceted, sometimes mulberry-shaped. They are of a dark-bluish or greenish color. On section there is a nucleus consisting of epithelium, rarely a foreign body, then comes a layer of inspissated bile-salts, the outer covering being cholesterin. There may also be bile-acids, fatty acids, or salts of calcium and magnesium, with a trace of iron and copper. When the stones consist of pigment exclusively, they are very easily broken and vary from yellowish-brown to black in color. When composed of cholesterin entirely, they are softer, easily indented with the finger-nail, but not brittle, and are crystalline, the crystals forming layers. They are colorless and more or less transparent, but turn blue when iodine and sulphuric acid are added. They generally consist of both pigment and cholesterin, which may be combined or may be separated in layers. These stones are usually firm in consistence, rarely friable. (2) The gall-stones may lead to impaction of the gall-bladder or to obstruction of the cystic and common ducts or even of the bile duct alone. There may be formation of a fistula, external or internal, with escape of bile. The bladder itself is much thickened, sometimes dilated, sometimes smaller than normal through chronic inflammation.

Cirrhosis.—Under this heading are classified various forms of disease of the liver characterized by a marked increase of its connective tissue, which may be capsular, interlobular, or intralobular, with or without increase or decrease in the size of the organ. Causes: (a) Alcohol. (b) Certain infectious diseases,—e.g., syphilis, tuberculosis, malaria, scarlet fever. (c) Micro-organismal infection. (d) Mechanical obstruction to the onward flow of the blood. (e) Rickets. (f) Anthracosis. (g) Poisons, as phosphorus and cantharides. *Classification.*—(a) Alcoholic. (b) Fatty. (c) Hypertrophic. (d) Cap-

¹ MENZIES, *Australasian M. Gaz.*, January 20, 1904, p. 20.

sular. (e) Syphilitic. (f) Cyanotic. (g) Malarial. (h) Scarlatinal. (i) Tuberculous. (j) Rhachitic. (k) Anthracotic. (1) In the atrophic cirrhosis of Laennec (hob-nailed; whisky and brandy liver) the organ is greatly reduced in size, although in the beginning it may be slightly enlarged, and later is altered in shape. The surface is irregular and nodular and the capsule is thickened. The nodules are usually small, but in some cases they may be greatly enlarged. The tissue is firm, hard, and resistant to the knife. The surface of section presents a mottled appearance, the lobules being divided by bands of connective tissue. The liver substance itself is of a yellowish or greenish-yellow color. The areas of connective tissue which are periportal are gray. (2) In fatty cirrhosis, found usually in drunkards, the organ is enlarged (even twofold or threefold), somewhat smooth, although often slightly granular. It is paler than normal and of a yellowish-white color. It is firm and resistant to the knife. The capsule is opaque and often much thickened. The peritoneal cavity usually contains ascitic fluid. The membrane is opaque and thickened. Chronic involvement of the stomach and small intestine is always present. The spleen is large and soft; the kidneys are often cirrhotic. Owing to interference with the portal circulation by the cirrhotic liver, extensive compensatory circulation is formed. The abdominal vessels above and below the umbilicus are markedly enlarged. Around the umbilicus is found the *caput Medusæ*. Acute tuberculosis of the peritoneal cavity may be associated with it. (3) Hypertrophic (Hanot's) cirrhosis is most common in young men. Ackerman compares it to elephantiasis. The organ is enlarged, but the outline is normal. The surface is usually smooth and its color an olive-green; the consistency of the organ is increased and the capsule is thickened. The surface of section is uniformly greenish yellow and the lobules may be separated by distinct bands of connective tissue. An intralobular growth of connective tissue occurs and also a considerable increase in the number of bile vessels. The spleen is greatly enlarged. Jaundice is a marked symptom of this disease. Ascites is usually absent. (4) In capsular cirrhosis there is enormous thickening of the capsule, which is irregular and somewhat wrinkled, producing great contraction of the liver. The organ itself is rarely markedly cirrhotic, its tissue being usually soft. Chronic capsulitis of the spleen, chronic perisplenitis, and ascites are often present. The kidneys usually show granular change. (5) In syphilitic cirrhosis the liver is markedly irregular in shape,

being divided into peculiarly shaped lobes by extensive bands of fibrous tissue traversing the organ in indefinite directions from healed gummata. In one of my cases over forty distinct lobulations were present. The cut surface is mottled, often fatty in appearance, and shows the presence of gummata or of syphilitic scars. The connective-tissue bands are of a gray or reddish-gray color. (6) For cyanotic cirrhosis see Passive Congestion of the Liver. (7) In malarial cirrhosis the liver is markedly enlarged, commonly extending to the level of the umbilicus. It is firm in consistence, of a dark-red color, smooth in outline, and bleeds freely on section. (8) Klein has pointed out that chronic interstitial hepatitis may follow an attack of scarlet fever, which may account for some cases of cirrhosis of the liver in children. (9) Rhachitic cirrhosis is a form of the disease in which there is a marked increase of connective tissue around the individual lobules. (10) Anthracotic cirrhosis occurs in coal-miners, in whom the coal-dust may occasionally reach the liver in sufficient quantities to cause a marked connective-tissue formation about the portal canal. (Welch.) Sears and Lord,¹ from a study of seventy-eight autopsies of hepatic cirrhosis, consider the condition to be part of a systemic disease.

Congestion.—(a) Acute infectious diseases. (b) Traumatism. (c) Extension of inflammation,—e.g., from the intestines. (d) Valvular heart-disease. (e) Pressure of tumors. (f) Other mechanical obstructions to the circulation. The condition is most marked when the veins of the liver are occluded, as in periphlebitis or Chiari's endophlebitis. (1) The post-mortem appearances of active congestion are not characteristic. The liver is swollen, dark in color, and full of blood; the hyperæmia is not limited to any one portion of the liver substance. (2) In passive congestion the liver is large in size, smooth or slightly granular in outline, and of a distinctly mottled hue. The surface of section presents the characteristic nutmeg appearance (the centre of the lobule being darker, due to a marked congestion occurring in the central veins, the congested tissues being of a reddish-brown color. This is surrounded by a large area of a pale-yellowish color (fatty degeneration), with a third zone of cellular infiltration and new connective tissue. In rare cases this order is reversed, the congested area occurring at the periphery of the lobe and the lighter or fatty parts towards the centre. In chronic and well-marked cases there may be

¹ *Bost. Med. and Surg. Jr.*, September 11, 1902, p. 285.

considerable induration and shrinkage of the liver substance, with irregular surface, so that the hypertrophy gives place to an atrophy, called cyanotic atrophy or Virchow's red atrophy.

Emphysema.—Portions of the liver when squeezed under water show the escape of bubbles. This condition may be due to putrefaction or to the growth of gas-forming organisms during life, notably the *Bacillus aerogenes capsulatus*.

Fatty Changes.—(a) Middle life. (b) Alcohol. (c) Sedentary habits. (d) Infectious fevers. (e) Certain poisons. (f) Cachexias. (g) Interference with local or general circulation. *Classification*.—(1) Fatty degeneration. The liver may be increased or diminished in size. The capsule may be smooth or wrinkled. The consistence is usually somewhat decreased; the organ is paler than normal and somewhat mottled in appearance. Periphery of lobule is first involved. The surface of section is smooth, usually bloodless, and imparts a greasy stain to the knife. The general color is a dull gray or grayish yellow. (2) In fatty infiltration the liver is often markedly enlarged, normal in outline, smooth to the touch, and of a somewhat pale, excessively fatty color. Globules of fat may be readily expressed with a knife. Hyperæmia may obscure the characteristic appearance. Recent investigations tend to show that fatty degeneration and fatty infiltration are not distinct pathologic processes, but rather that they are differences in degree of infiltration.

Hepatitis, Suppurative.—Abscess of the liver may be due to: (a) Traumatism. (b) Extension from neighboring organs,—e.g., the bowel and the pleura. (c) Pyæmia. (d) Amœbic dysentery. (e) Malignant emboli. (f) Diseases of veins, as periphlebitis and thrombophlebitis. (g) Stoppage of bile, as from gall-stone or dead ascarides. (h) Idiopathic tropical disorders. *Classification*.—(a) Pyæmic hepatitis. (b) Portal pyæmia. (c) Pyo-septicæmia or multiple abscess. (d) Tropical or endemic hepatitis. (e) Suppurative cholangitis. (1) In multiple abscess the change in the liver depends upon the number of the abscesses. If these be few, the liver tissue may be comparatively little altered; if they are very numerous, the liver is apt to be enlarged, softened, and friable. The abscesses themselves appear as minute foci which are non-capsulated, the centre containing a thick white, yellow, or greenish pus surrounded by a zone of congestion. The abscesses may vary in number from five or ten to many hundreds. These multiple abscesses frequently arise

from pyæmic embolism of the portal vein or hepatic artery or vein, or they may result from a cholangitis. They may be generally distributed or appear in clusters. If from a malignant endocarditis, they are usually situated under the capsule. (2) Large abscesses occur in two forms,—the large chronic encapsulated abscess surrounded by a pyogenic membrane and the tropical or amœbic abscess. (See Dysentery.) The large abscess is usually single, but there may be two or more. The right lobe is usually affected. There is a distinct limiting membrane. The pus is usually of a greenish-yellow color and often of a disagreeable odor. The surrounding substances often show but few changes, except as the result of pressure.

Sarcoma.—This may be primary (very rare) or secondary. The most frequent variety is the secondary melanosarcoma following sarcoma of the eye, of the skin, of the dura mater, or of the penis. In these cases the liver is greatly enlarged, weighing as much as fifteen pounds, and the secondary nodules, which are of a black or slate color, are usually uniformly distributed throughout the gland. In primary sarcoma of the liver there are but few nodules, and these reach a large size, measuring at times five or six inches in diameter. Metastases to other organs often occur, though other portions of the liver may escape.

Other Tumors.—In addition to carcinomata and sarcomata, the liver is the seat of adenomata, adenocystomata, angiomata, fibromata, and aberrant adrenal tumors similar to those found in the kidney. The cavernous angiomata are usually small in size and, when found, are usually seen on the surface of the liver in elderly persons. They may be injected with colored material by means of any of the hepatic blood-vessels, and then form excellent microscopic specimens for future study. A cystic liver may be associated with a similar condition of the kidneys.

Parasites and Infectious Diseases.—*Psorospermia*, *Pentastomum denticulatum*, *Distomum hæmatobium*, *Distomum lanceolatum*, *Distomum hepaticum*, and *Echinococcus*. Cases of primary tuberculosis of the liver have been reported, and syphilitic lesions are by no means rare.

PANCREAS.—*Anomalies.*—The tail of the pancreas is sometimes bifid, and peculiar divisions made by septa of connective tissue may occur in all parts of this organ. The pancreatic tissue by surrounding the duodenum may cause an intestinal stricture. Accessory pancreases have already been referred to in detailing the technic of removing the gland from the abdominal cavity.

Acute Pancreatitis.—This condition exhibits acute degenerative changes in the parenchymatous cells and an exudation into the interstitial tissue. It is often associated with cholelithiasis, and is usually hemorrhagic or gangrenous. In the lower animals pancreatitis may be produced experimentally by the injection of an artificial gastric juice, but it is impossible to foretell which form of the disease will result. *Hemorrhagic Pancreatitis.*—This variety of pancreatitis is usually associated with gastric or gastroduodenal dyspepsia, slight swelling of the epigastrium, and obstinate constipation. The pancreas is enlarged and infiltrated with blood. There is a cellular and fibrinous exudate present, with a necrosis of the parenchyma; also disseminated necrotic foci are found in the omentum and peritoneum. This condition often ends in *gangrenous pancreatitis*, where the organ is enlarged, swollen, soft, friable, of a color varying from mottled red and gray to dark brown and black, and gives off a foul odor. The extension of the disease to the neighboring tissues may result in almost complete sequestration of the pancreas. In some cases it has been found that the organ has entirely disappeared, its place being taken by an abscess-cavity containing a foul-smelling mass, which may discharge through the intestine. Disseminated fat necrosis often follows. Gangrenous pancreatitis may be the result of a perforating inflammation of the gastro-intestinal or biliary tracts, arterial sclerosis, and hemorrhagic pancreatitis. *Pancreatic Hemorrhage.*—The pancreatic vessels may rupture from trauma, or the hemorrhage may accompany tumors, cysts, purpura, eclampsia, and acute infections. Apoplexy in this organ is seldom associated with arterial disease. Extensive fat necrosis now and again accompanies it. Opie considers that pancreatic hemorrhage and hemorrhagic pancreatitis represent a single pathologic process.

Chronic Interstitial Pancreatitis.—This disease is related to diabetes mellitus, is secondary to morbid changes in the intestines, the bile passages, and the liver, and is associated with arterial sclerosis, syphilis, tuberculosis, and abuse of alcohol. The islands of Langerhans are frequently not affected. *Chronic Pancreatitis.*—In the interlobular form of this disease the gland is hard, dense, and nodular, with a granular surface. On section the tissue is compact and homogeneous, the loose areolar tissue being replaced by scar-like bands. The islands are unaltered, and the acini have atrophied nuclei and dilated lumina. Lymphoid cells are present in great numbers. In the interacinous

variety the gland is tough and shows newly formed connective tissue in the lobules. The lesions are diffuse and irregular in distribution; in one place thickening of the connective tissue and of the network supporting the acini may occur, while elsewhere are found compact bands or small masses of stroma. Lobulation is observed, and at times is associated with general pigmentation. The change in either case may be only microscopic. Fatty infiltration may obscure both types. Chronic pancreatitis may be due to obstruction of the pancreatic duct, to pancreatic or biliary calculi, to malignant growth compressing or invading the organ, to an ascending infection from the duodenum, to alterations of the blood-vessels, to arterial sclerosis, to association with chronic tuberculosis of other organs, and at times to alcohol and to cirrhosis of the liver. It is very rarely due to syphilis.

Congenital Syphilitic Pancreatitis.—In this form of the disease the organ is enlarged and firm. There is a diffuse interstitial proliferation of the interlobular and interacinous tissue, first with atrophy and finally ending in destruction of the parenchymatous elements. The arteries are the seat of a syphilitic periarteritis and the adventitia is infiltrated with lymphoid cells. Finally the capillary network around the acini disappears. The islands of Langerhans are not involved, but are surrounded by newly formed stroma.

Hyaline Degeneration.—This attacks especially the islands of Langerhans, and is often found in cases of diabetes, destroying the islands and obstructing the vascular supply of a large portion of the parenchyma. Hyalin is deposited between the capillaries and the parenchymatous cells. Since the islands of Langerhans are more numerous in the tail of the pancreas the affected areas are larger and greater in number in this locality and may involve two-thirds of the tissue. Epithelial cells are found arranged about a lumen, particularly at the periphery of the altered tissue, and show that the acini are also affected. In the head and body of the gland the areas are smaller and fewer.

Fat Necrosis.—This consists of small, opaque, white areas found in the fat around the pancreas, which are made up of necrotic fat-cells. In disseminated fat necrosis small foci are widely scattered in the fat of the abdomen. Large foci occur, especially in the fat of the omentum. Both a subperitoneal and a retroperitoneal fat necrosis indicate some grave alteration of the pancreas. These areas are frequently surrounded by a narrow hemorrhagic zone. While these lesions are usually limited to the fat in the abdominal cavities, they are found,

as Hauseman has observed, in the subcutaneous fat corresponding in location to the reddish areas visible during life upon the overlying skin. They are probably due to a fat-splitting ferment acting on living fat.

Diabetes Mellitus.—A constitutional disease characterized by the continued excretion of large amounts of pale, cloudy urine of high specific gravity, containing glucose and, at times, acetone, diacetic acid, and beta-oxybutyric acid. It is, as a rule, associated with excessive hunger and thirst, and sometimes with increase in fat and at other times with progressive emaciation. It occurs most frequently in adult males, Hebrews being especially predisposed. It is due to some failure properly to utilize certain carbohydrates in metabolism. Van Noorden,¹ in the Herter lectures of 1905, considers that diabetes is due to inability of the cells to transform glucose into glycogen and a consequent increased formation of sugar by the liver. The pancreas probably yields some substance which affects the glycogen formed. There is a tendency to destructive changes in the tissues and to death from coma. It may be caused experimentally by ingesting phloridzin and by puncture of the floor of the fourth ventricle. Glycosuria is seen with exophthalmic goitre, certain neuroses, some diseases of the liver, cirrhosis, lesions of the pancreas, injuries to the nervous system, destruction of gray matter in the floor of the fourth ventricle, extirpation of cervical ganglion, pancreatic calculi, atrophy, carcinoma, necrosis, fatty degeneration, cysts, acute and rarely chronic interlobular pancreatitis. Some cases of the disease show an absolutely healthy pancreas, yet it occurs often with chronic interacinous pancreatitis. Diabetes is closely related to destructive lesions of the islands of Langerhans, especially with hyaline changes and interacinous pancreatitis. In diabetes the number of islands may be diminished and the pancreas be nearly always atrophied. Arterial sclerosis and acromegaly accompany many cases of diabetes. It is occasionally associated with tabes. The cœliac ganglion is atrophic in this disease (Orth). Neuroretinitis is very common, and there may be hemorrhages in the retina and opacities in the vitreous. The most usual change is a thickening and congestion of the membrane. The blood generally appears normal, but contains an increased amount of glycogen, and may be loaded with finely divided fat which floats on the surface in a cream-like layer. There may be lipæmic clots in the vessels. Fat

¹ *Med. News*, October 21, 1905.

embolism of the pulmonary vessels has been described. The myocardium is pale and soft; rarely it may be hypertrophied. Advanced fatty degeneration of the muscular fibres is the characteristic change in long-standing cases of diabetes. Croupous pneumonia and bronchopneumonia, chronic interstitial pneumonia, and tuberculosis are common complications; many of them terminate in gangrene. The lung may soften (malacia) and, becoming mixed with stomach secretions *post mortem*, form the so-called *pneumomalacia acida*. It has a sour but not a gangrenous odor. The spleen is usually small, pale, and soft, but may be enlarged and congested. Diffuse nephritis with fatty degeneration, and frequently glycogenic degeneration, most marked in the pyramids, may occur. Boils, carbuncles, onychia, eczema, and gangrene of the extremities are common. The liver is usually enlarged, often congested, abnormally firm to the touch, and gives the glycogen reaction; fatty degeneration is common. Do not mistake diabetes mellitus for alkaptonuria; in the latter disease pigmentation of the cartilages or ochronosis may occur.¹ Some alkaptonurics do not show ochronosis, but thus far all the cases of ochronosis exhibit alkaptonuric changes in the urine. Established facts concerning diabetes: (1) Considerably more than one-half of all cases are due to a destructive disease of the pancreas. (2) When due to disease of the pancreas, injury to the islands is responsible for the disturbance of metabolism in the carbohydrates. (3) Common lesions injuring the islands are chronic interacinous inflammation and hyaline degeneration. (4) Other lesions of the pancreas do not attack the islands of Langerhans, but produce diabetes by destroying the interacinous islands along with the secreting parenchyma. (Opie.) According to the experiments of Sauerbeck² upon guinea-pigs, total extirpation of the pancreas or the tying of its secretory duct gives rise to atrophy of the islands of Langerhans and the subsequent development of diabetes.

The Bremer-Williamson reaction of diabetic blood may be obtained some time after death. The reaction is of special value in coma where urine cannot be obtained.³

¹ OSLER, *Lancet*, January 2, 1904, p. 10.

² *Ergebnisse der allg. Path. u. path. Anat.*, 1904, eighth year, part II, p. 691.

³ BROWN, *International Clinics*, January, 1903, p. 266.

CHAPTER XIII

EXAMINATION OF THE SKULL AND BRAIN

FOR the removal of the brain the body is placed in the supine position on the side of the table nearest the operator, with the head projecting slightly beyond the end of the table and elevated by a block placed under the neck and occiput. If the cadaver be in a coffin or box, it may be drawn to the upper end thereof, the head being raised and placed upon a board laid across the top, the back supported by a head-rest, a block of ice, or anything else that is convenient, as a bundle of rags or paper. Of the various forms of support employed, the Cornell head-rest (Fig. 46) is peculiarly well adapted for holding the head steady.

Any anomaly in the size or shape of the head is to be carefully noted. The scalp should be subjected to the same careful preliminary scrutiny for evidences of disease or injury, remote or recent, as the other parts of the body. It is then divided by an incision extending from one mastoid process to the other (Fig. 126), passing over the vertex when the hair is abundant and about midway between the vertex and the external occipital protuberance when it is thin. If the hair be long, it should be parted along the proposed line of incision, in order that as little of it as possible may be cut (Fig. 127). For the same reason and to guard against damage to the knife, the cutting edge of the scalpel or cartilage-knife should be directed from the skull when the scalp is being cut. In case of any previous injury to the scalp or of the presence of pathologic lesions the incision may have to be modified according to circumstances. Loose hairs should be at once removed, as they interfere with the sawing later on. When all the tissues overlying the skull have been separated, the scalp is reflected backward and forward by force, the calvarium being exposed from the occiput to or slightly beyond the frontal eminences. In the case of a woman with abundant hair, a *coiffure* as seen in Fig. 128 may be prepared. Such an arrangement keeps the hair clean and saves much time in the restoration of the body. The eyes and nose should be protected by pledgets of cotton placed beneath the anterior flap. Care should be taken to avoid tearing the scalp at the extremities of the incision behind

the ears, especially if the posterior incision with a large anterior flap be made. Indeed, it is for this reason that the incision is begun and ends behind and not in front of the ears, for a tear behind the ear would hardly be noticed, while one in front would cause considerable disfigurement. The scalp may be so adherent to the cranium—a condition more apt to occur in the posterior segment than in the anterior—as to necessitate its removal by dissection with the knife or scraping with a chisel. Whatever instrument is used, guard against its slipping, lest injury be done to the operator or to the subject. Avoid undue traction of the scalp, which would cause it to present a baggy appearance when replaced.

The skull should next be examined in detail. Fractures and other evidences of injury may now be revealed which could scarcely have been discovered in the preliminary examination. Note should be made of the presence of atrophy, hypertrophy, or softening of the bone, of premature or delayed synostosis and supernumerary bones, of tumors, of syphilitic or tuberculous abrasions or openings, of marks of previous trephining, of asymmetry and abnormal coloration, of the “greenish-yellow” discoloration due to osteomyelitis or the “citron-yellow” due to tertiary syphilitic lesions, etc. (For cranial measurements and pathologic types of skull see Chapter XXIV.)

There are two methods of removing the calvarium,—the angular, in which the skullcap is sawed in two intersecting planes meeting behind the ear, and the circular, in which the bone is divided in a single plane. The former method is usually to be preferred, as it permits more secure reposition of the skullcap, but the latter is easier of application and will, therefore, be considered first.

THE CIRCULAR METHOD.—The path of the saw, which may be marked with a pencil or the point of a knife, traverses a plane cutting the skull from half an inch to an inch above the glabella anteriorly, an inch or an inch and a half above the external auditory meatus laterally, and passing just above theinion posteriorly. This line will cross the temporal muscles obliquely, and they and their fascia should be divided with a knife instead of the saw, in order that their edges may be accurately approximated for suturing when the skullcap is replaced.

Sawing the skull is no easy task; it may be greatly facilitated by the employment of an electric or dental engine. For this part of the operation it is a decided advantage to be ambidextrous. While the



FIG. 126.—While the right ear is held back with the left hand an incision is started directly over the mastoid process. The remainder of the incision over the vertex will be made from within outward, thus avoiding dulling the knife and cutting the hair.

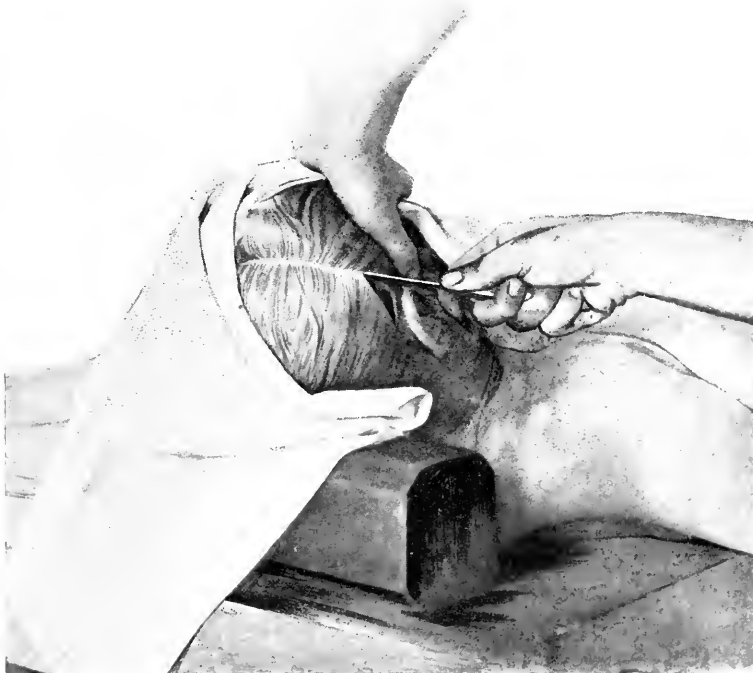

FIG. 127.—After the initial incision has been made behind the ear, the hair may be parted when it is long so as not to injure it when incising the scalp.



FIG. 128.—Toilet of hair preparatory to the removal of the brain.

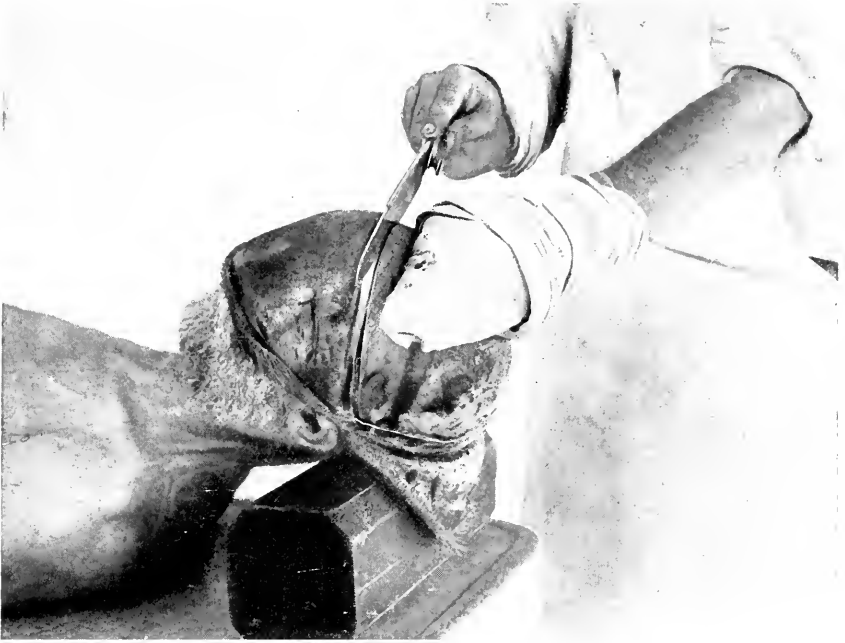


FIG. 129.—Method of sawing the skullcap. The temporal muscle has been cut through with a knife in the direction of the future sawing, and a pencil mark shows the posterior line along which to saw. The hand is protected with a towel.

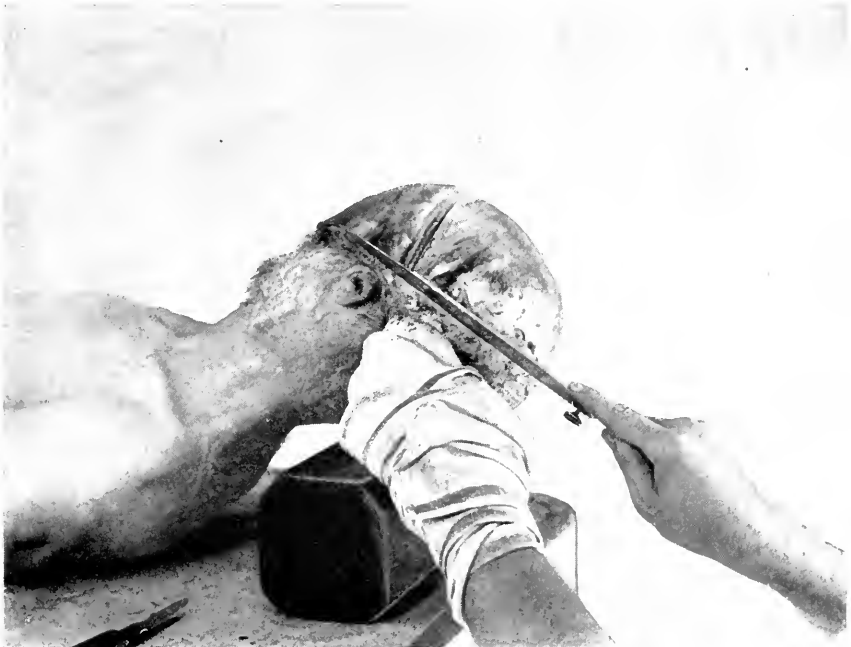

FIG. 130.—Angular method of removing the brain. The saw markings in each case pass close to the ear and meet an inch or so above it. The left hand is covered with a towel to protect it from injury.

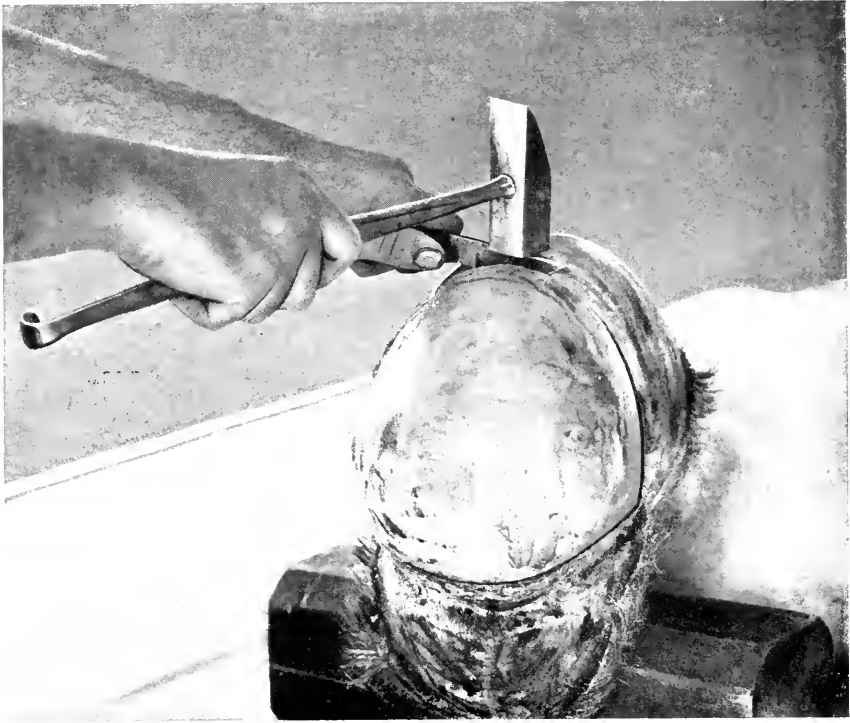


FIG. 131.—Method of breaking up the inner table with an old knife. (There are also various forms of chisels made especially for this purpose.)



FIG. 132.—Method of drawing off the skullcap with a retractor after the sawing is completed.

sawing is being done with one hand, the head must be steadied with the other, placed either on the vertex or on the face and protected by a towel, for the saw is liable to slip, especially when first applied. The scalp, especially of a female, should be protected from "sawdust" by wrapping towels about it. Rotating the head to one side will give considerable room on the opposite side for purposes of sawing. Proffered assistance should be declined, because, while it is natural to look out for one's own fingers, it is impossible effectively to guard another's. The reason I often give for not accepting aid is that "I am reasonably supposed to know where my hand is, but not where yours may be." The saw may be carried entirely through the bone or, better, only to the inner table, this being divided later with chisel and hammer. The hand soon becomes trained to the different sensations from sawing through the outer table, the diploë, the inner table, and the dura. The reddish bone-dust of the diploë is also characteristic. A bone-sounder, such as the surgeons use in trephining, may be employed, if desired. In no case, however, where it is suspected that the skull may have been fractured should the hammer be employed, as the force of the blow required might be sufficient to split the bone. While a post-mortem fracture may be recognized by the absence of extravasated blood, the enlargement of a pre-existing fracture is more difficult to differentiate. A receptacle should be placed beneath the head to catch the cerebrospinal fluid and the blood that escape when the skullcap is removed and the meninges are opened, and care must be taken to prevent spattering. The calvarium is loosened by twisting a chisel or the sharp end of a hammer in the kerf, and removed with a blunt hook. If instead of an instrument the fingers be used for the purpose, they must be well protected, as they are liable to slip and be abraded by the sharp edges of the bone. Traction should be made steadily and not in jerks, lest from a sudden giving way the calvarium be damaged by falling on the floor or surrounding objects be soiled by the spattering of blood or other fluid. When, as is sometimes the case, the calvarium does not readily yield to traction applied in front, it may often be easily detached by inserting the hook posteriorly. If the dura be adherent, as not infrequently happens in cases of chronic alcoholism, old injuries, or sunstroke, it may be loosened with a blunt instrument,¹ or it may be divided along its margin with a pair of blunt-pointed

¹ Stroud uses a long flexible spatula. *Med. News*, December 9, 1905.

scissors or a curved, probe-pointed bistoury cutting from within outward, the falx cerebri being incised close to the corpus callosum. In children under seven years of age this must always be done, as up to this time of life the dura is normally adherent to the osseous structures of the skull.

THE ANGULAR METHOD.—In this method the skull is sawed in two planes which by their intersection form an obtuse angle at a point

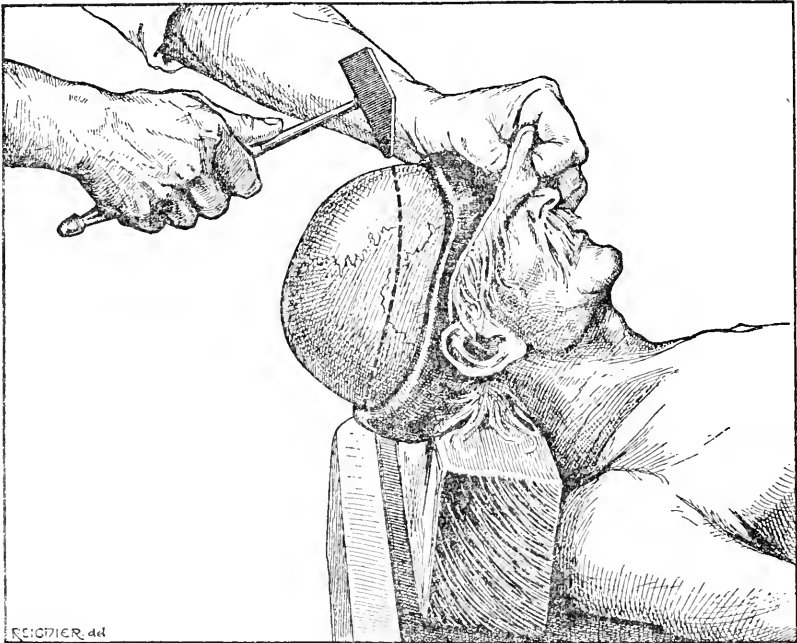


FIG. 133.—French method of opening the skull. (After Letulle.)

a little below and slightly posterior to the apex of the ear. Always to saw above the line of the hair in front. Although this makes the anterior fossa deeper and consequently the removal of the brain more difficult, it obviates the ugly ridge on the brow so liable to be made by the inexperienced. It is necessary, too, that the angles be well sawed through and carefully broken, because if spicules of bone remain the brain may be caught and injured during its removal. (For this method of opening see Figs. 129 to 132, inclusive.)

In the French method of opening the adult skull with a hammer,¹

¹ J. DEJERINE, *Anatomie des centres nerveux*, 1895, p. 13.

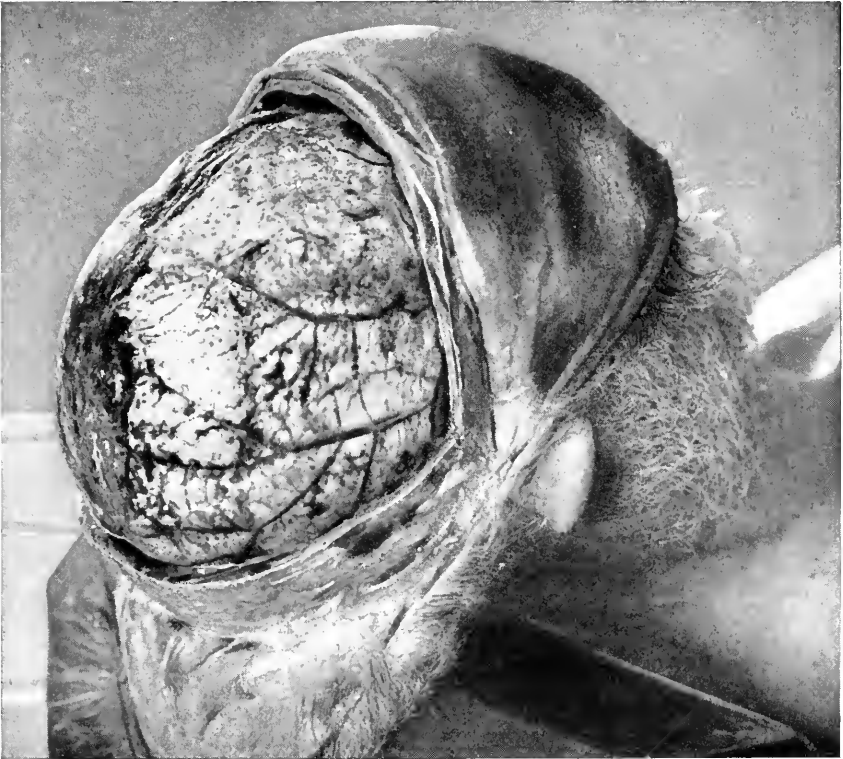

FIG. 133.—Appearance of the dura mater after removal of the calvarium, showing the superior longitudinal sinus and the meningeal vessels.

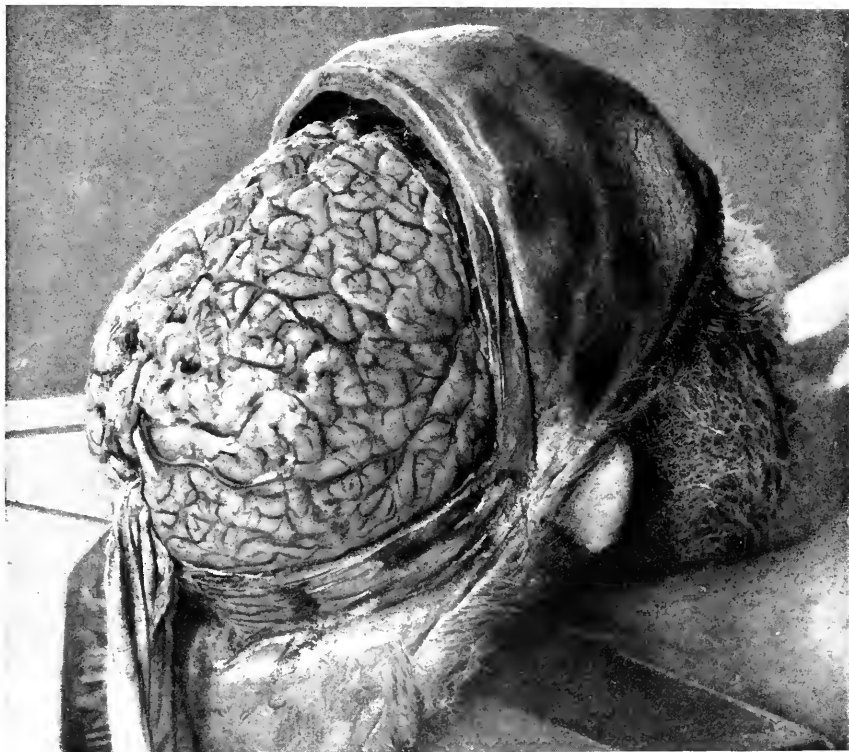


FIG. 136.—Appearance of the brain after removal of the dura, which has been left attached at its posterior extremity.

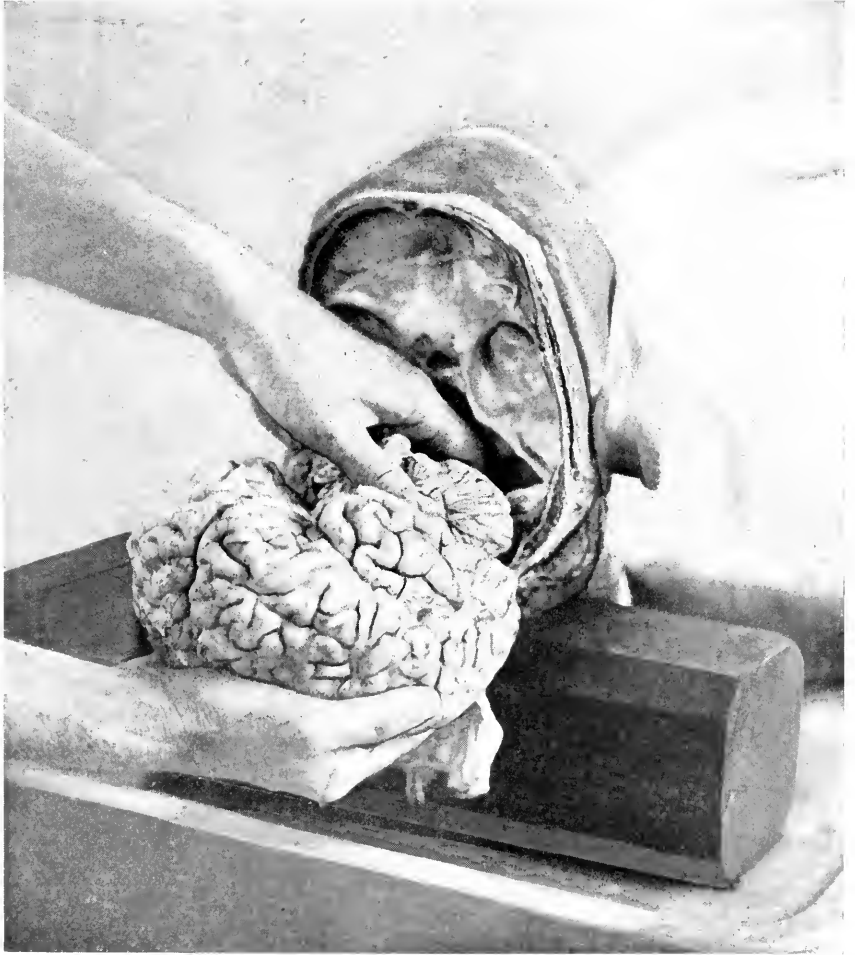

FIG. 137.—Method of removing the brain after it is severed from the body.

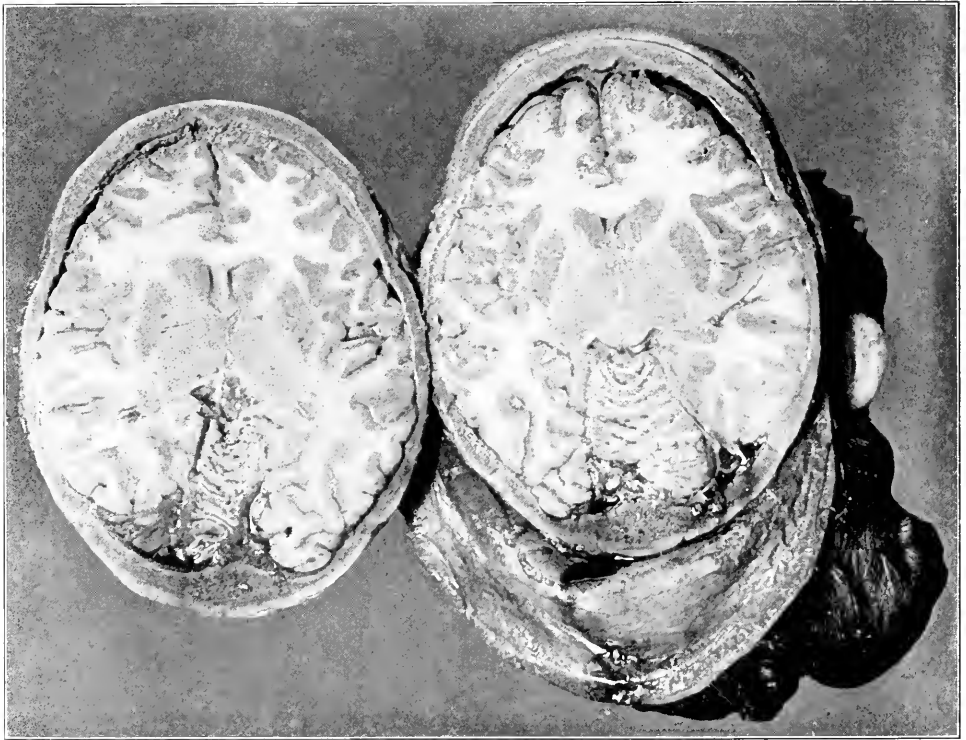


FIG. 138.—Appearance of brain after being sawed through. Notice how even, the cerebral surface seems, just as if it had been cut with a knife.

the anterior and posterior flaps are made in the usual manner. A line one centimetre above the soft tissue is drawn around the skull with a soft pencil or with ink, the temporal muscles being cut through with a knife; by means of blows with the hammer the skull is then fractured along this line. The sound tells you when the bone is fractured and warns you to proceed to a new place. (Fig. 133.) This method is much employed in France, and in the hands of experienced operators gives good results, though it is most difficult of performance in the re-

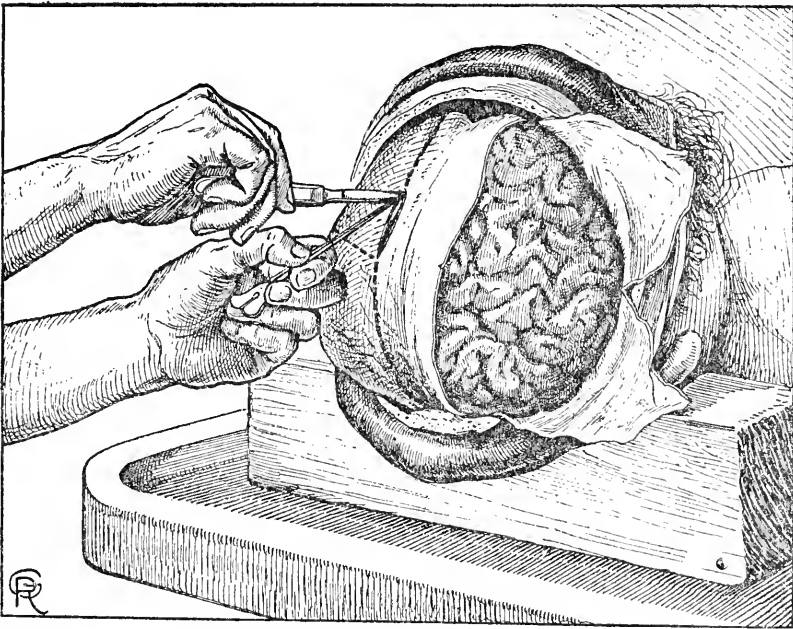


FIG. 134.—French method of opening the dura. (After Letulle.)

gion of the exterior occipital protuberance. It must not be used in children, in cases of fractures, bone lesions, etc. The dura is opened along the circular incision, or, more frequently, crucial incisions are made on either side of the longitudinal sinus and each side is incised by a perpendicular cut running from the vertex down to the upper margin of the bone. The four pieces are then turned down and the falx cerebri is cut anteriorly just behind the crista galli and with a portion of dura on each side of the longitudinal sinus pulled backward. It will be seen that the dura mater thus covers the sawed portions of the bones (Fig. 134) and affords a protection to the hands in the

subsequent removal of the brain. Aseptic compresses may also be used for a similar purpose.

The thickness of the skull is next noted. It varies much, being usually greater in negroes and, at times, in syphilitic subjects. It also varies in different parts of the same skull, being thinnest in the temporal region and thickest at the occiput, and is often unequal in corresponding points of the opposite sides. The diploë may be entirely absent in some places, in which case the bone-dust will lack the reddish color commonly observed in recently sawed bone. The skull is usually from two to six millimetres thick. In rare cases the frontal sinus may extend high up and be of unusual thickness; in one of my subjects it measured half an inch across at the top after removal of the calvarium in the usual manner. Note the relations of the external table, internal table, and diploë. Pay especial attention to the amount of blood in the latter; if abundant, suspect fracture. At times it is entirely bloodless. The skullcap should be held up to the light so that any inequality in its thickness may be perceived. The Pacchionian granulations often give rise to small nodular depressions in the inner table, which are of course perfectly normal and should not be mistaken for pressure atrophy. They sometimes cause perforation of the bone, or permit of the passage of an external infection into the interior of the skull.

The grooves of the middle meningeal artery must be looked for on each side. In one of my cases of acromegaly the inner table resembled worm-eaten wood; the bone was soft and pliable and offered no resistance to the saw. It is necessary to be familiar with the normal yellowish-gray color of the inner table in order that changes in it may be readily detected. Whenever blood is found between the inner table and the dura, careful search must be made not only in its vicinity but also on the opposite side for a fracture by *contrecoup*. In the examination of the dura mater note its thickness, the degree of distention, its color, which is normally gray and never very red, and the amount of blood contained within it. As all liquid naturally gravitates downward, those portions of the dura which cover the most dependent parts will be most distended, unless, as often happens, an injury of this membrane has allowed the fluid to escape.

The arteries lie between the two veins. The larger arteries usually contain more blood than the veins. The dura is supplied with but few capillaries and these rarely become inflamed.

In the examination of the outer surface of the dura mater (Fig. 133) note alterations in color and gloss. The latter is often lost in consequence of tumors, hemorrhage, hydrops, abscess, and other conditions that cause increase of intracranial pressure. Search for hemorrhages (which at times are profuse and depress the brain) and their points of origin, Pacchionian bodies (which must not be mistaken for tubercles), bulging tumors, and external pachymeningitis (ossified, purulent, syphilitic, or tuberculous), etc. The degree of tension due to fluid, etc., may be determined by puncturing or by pinching up the dura. Bone-dust from the sawing may resemble the Pacchionian bodies.

The brain may be exposed, but not dissected, before the heart is incised, as the quantity of blood in the cerebrum may be modified by venous oozing during the examination of the thorax. If the brain is to be injected, it is best not to remove the dura, as by its detachment usually some of the veins entering the longitudinal sinus are torn, and this permits the escape of the injecting fluid when under pressure. It has been shown that this operation can be performed without external disfigurement while the brain is *in situ* by forcing the fluid through a cannula introduced by way of the nostrils or the orbits.

The longitudinal sinus is opened throughout its entire length with a pair of probe-pointed scissors, and the condition and quantity of the contained blood are noted.

The dura is divided parallel with and slightly above the sawed edge of the skull, with a pair of blunt-pointed scissors, which may be introduced through a chance nick made by the saw or through an opening made with a knife for the purpose. The incision is carried completely around the skull except at the poles of its anteroposterior diameter, where it is necessary to sever the falx cerebri. The arachnoid surface of the two lateral flaps of the dura may be examined by reflecting them to one side. The character of the blood in the membranes of the brain and in its cortex, the fluid in the subarachnoid space, the character of the sulci and convolutions, and the presence of lymph are all to be noted.

To detach the falx grasp both folds of the frontal dura with the thumb and index-finger of the left hand, and with the right insinuate the blade of a knife along the outer face of the left fold of the dura to its attachment to the ethmoid bone. This is severed by turning the cutting edge of the blade inward towards the falx and detaching it along the line of its insertion from before backward, as near the crista

galli as possible without injury to the olfactory bulbs. As the knife reaches to the anterior genu of the corpus callosum, the index-finger may be gently introduced into the longitudinal fissure so that a view may be had of the portion to be cut. It is no unusual thing to leave behind a thin strip of the dura just above the corpus callosum, a mistake which may subsequently cause annoyance to the operator or injury to the brain during its removal.

The dura may now be drawn backward and cut off posteriorly or left *in situ* in order to protect the hands of the operator and the brain in its removal (Fig. 134 and Fig. 136). The portion of the pia mater dipping down to the genu and splenium of the corpus callosum may be detached with forceps, and that overlying the surface of the cerebrum with the fingers. The handling of this delicate membrane can be greatly facilitated by allowing a stream of water to flow gently over it during its removal. The pia is colorless when normal, but may be gray or grayish white when thickened, yellow when pus is present, or red from hyperæmia or hemorrhage.

The anterior extremities of the frontal lobes are gently raised with the bended tips of the fingers of the left hand, and any remaining shreds of dura are severed to prevent injury to the cerebral tissue in the frontal region or corpus callosum. With the handle of a scalpel the grayish olfactory bulbs are now shelled from the grooves in the cribriform plate of the ethmoid bone in which they lie, and the entire brain is gently turned outward while supported by the left hand. The various nerves (Fig. 140. The fourth trochlear is the smallest of all the nerves, the fifth being the largest.) and vessels are divided, as near as possible to their respective foramina, with a sharp, narrow-pointed scalpel, always cutting towards the bone. The ophthalmic artery and optic nerve are now severed close to the optic foramen, first on one side, then on the other. Next the dura enclosing the pituitary body is cut with a sharp knife near to the bone (*sella turcica*) at all points except posteriorly near the infundibulum, great care being taken not to injure the delicate hypophysis, which then may be shelled out and the remaining portion of the dura behind be excised with scissors. Or, the infundibulum may be cut, and the pituitary body removed as described on p. 244. The internal carotids, sometimes the seat of an embolus, are cut long, especially if the brain is to be injected. Next cut the common motor oculi, the trigeminal, external motor oculi, facial, auditory, hypoglossal, glossopharyngeal, and pneumogastric, and as the temporo-

sphenoidal lobe leaves the middle fossa of the skull, the tentorium cerebelli is divided with blunt-pointed scissors, or with a knife with a broad, flat back made especially for this purpose, along the superior border of the petrous portion of the temporal bone, preferably passing from the median line towards the sides. In making this incision care must be taken not to injure the cerebellum.

The brain mass being now supported on the left hand, cut the cord as low down as possible by a transverse incision. Pick's myelotome (Fig. 20) is a very convenient instrument for this purpose. Orth thrusts the knife through the centre of the cord and severs first one side and then the other. Any attachments of the spinal cord, medulla, and vertebral arteries can readily be loosened by introducing the forefinger into the cavity of the spinal column and through the foramen magnum. Of course, if the cord has already been removed, it remains only to cut the vertebral vessels.

The brain is now entirely free, but the cerebellum still remains in the posterior fossa, from which it is best removed by holding it firmly to the cerebrum with the fingers of the right hand and turning the brain first to one side and then to the other (Fig. 137). The brain, with its pia and arachnoid still attached, is now weighed. A towel previously rolled up into the form of a turban makes an excellent temporary resting-place for the inverted brain.

During this entire procedure, which has taken longer to describe than it does to perform, the secant has been searching the exposed parts for any lesions or abnormalities, as their presence may modify subsequent processes. Thus, a tumor of the brain penetrating the middle ear might cause a portion of the temporal bone to be removed attached to the brain.

Examine the external surface of the brain, the adherence of the pia-arachnoid being tested in several places, not forgetting the fourth ventricle, the circle of Willis, and the course of the middle cerebral artery lying in the fissure of Sylvius. With the latter the island of Reil and the retroinsular convolutions are also exposed. Should this membrane be adherent a portion of the cortex from which no attempt has been made to remove the pia-arachnoid should be saved for microscopic study.

SAWING OF BRAIN.—This method gives astonishingly good results, especially if the brain be soft, as after the body has been in water for some time. The sawing is done directly through the brain while mak-

ing the circular incision. Fig. 138 shows the smooth surface of the brain after this procedure, it having every appearance of having been cut with a knife. It will be noticed that in this instance the skullcap was unusually thick. Perpendicular and transverse incisions may be made while the brain is *in situ*, or it may be removed, and dissected in the usual manner.

REMOVAL OF THE PITUITARY BODY.—In the removal of the pituitary body after that of the brain, it will be found of advantage to make a transverse slit on both sides of the anterior and posterior clinoid processes. Then with the chisel a broad incision is made transversely on the dorsum of the sphenoid bone about three-eighths of an inch below the posterior clinoid process, *i.e.*, slightly lower than the bottom of the sella turcica. After these incisions have been made the small piece of bone is removed by pressure from above and the pituitary body may easily be shelled out in its entirety. (Fig. 139.)

QUICK, BUT NOT ACCURATE, METHODS.—Some operators do not even take the trouble to remove the brain from the skull, but merely make a number of transverse incisions across the cerebral structures. This method is only mentioned to be condemned, though it may diagnose a hemorrhage, a tumor, or an abscess.

In the Coroner's work it is often necessary to make a diagnosis between heart-disease and apoplexy, when, because of baldness of the individual or for lack of time, it is impracticable to open the head. In such cases I have found it feasible to trephine just above the ear and from this point tap the ventricles and other situations liable to be the seat of hemorrhage, using an instrument resembling an apple-corer to remove brain substance for examination, though enough clotted blood may be brought out attached to a long, thin brain-knife passed into the places where hemorrhage usually occurs—*i.e.*, the ventricles and the cerebellar lobes—for the purpose of establishing a probable diagnosis.

EXAMINATION OF THE BASE OF THE SKULL.—The base of the skull and its sinuses are next to be examined. Study the dura at its base for (1) inflammation resulting from fracture or caries, (2) tubercles, (3) gummata, (4) thrombosis of lateral sinus, (5) pachymeningitis and leptomenigitis, and (6) tumors. A fracture may be hid by the dura, but its situation will usually be shown by the presence of hemorrhage. The dura must be stripped off, though this often consumes considerable time, so that the surface of the bone may be exposed.



FIG. 139.—Removal of pituitary body.

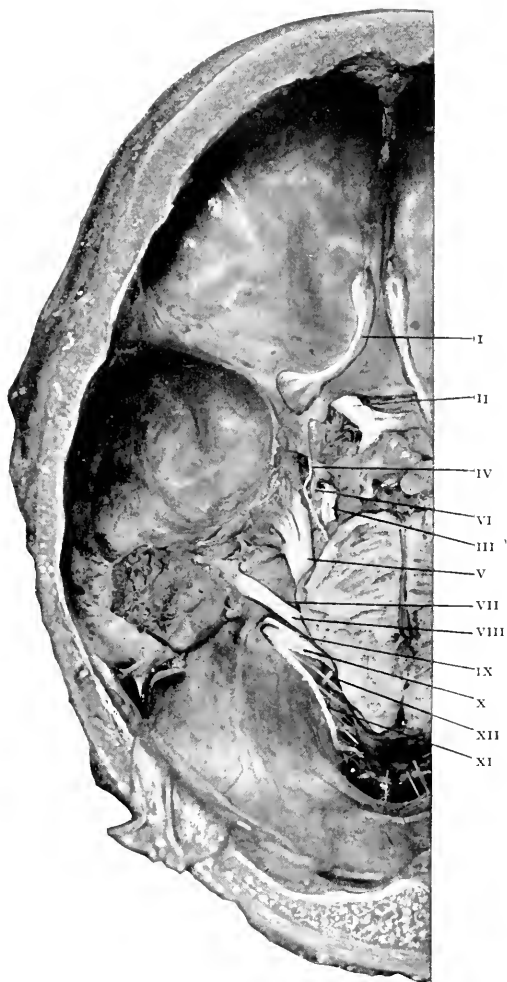


Fig. 140.—The twelve cranial nerves *in situ*, with the exception of the left olfactory nerve, which has been displaced in order to show the optic nerve.

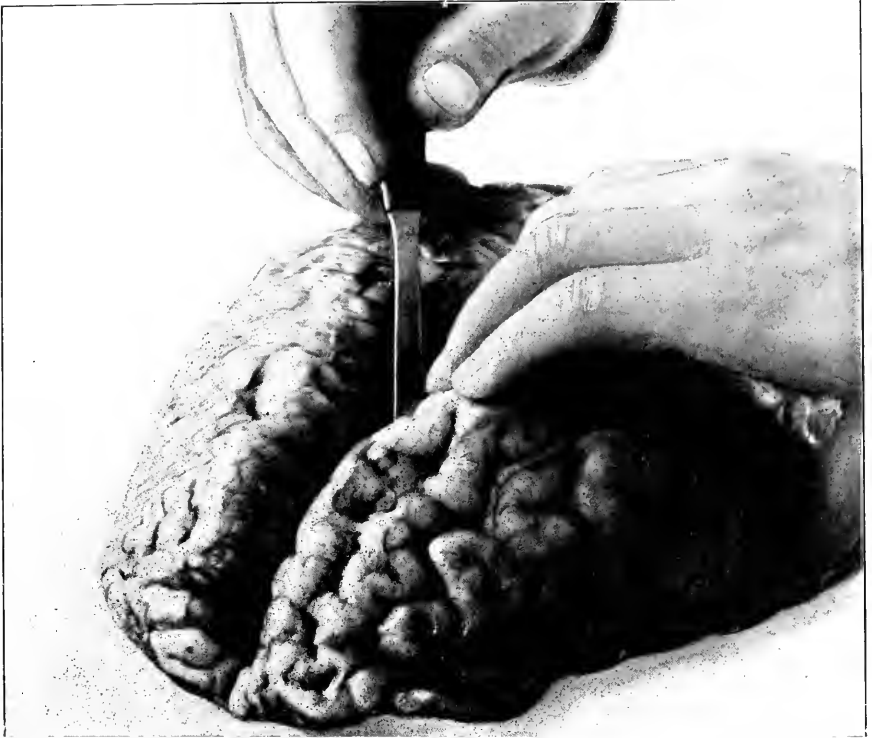


FIG. 141.—Dissection of the brain; commencement of initial incision. Better to have the thumb near the corpus callosum and the fingers over the convexity.

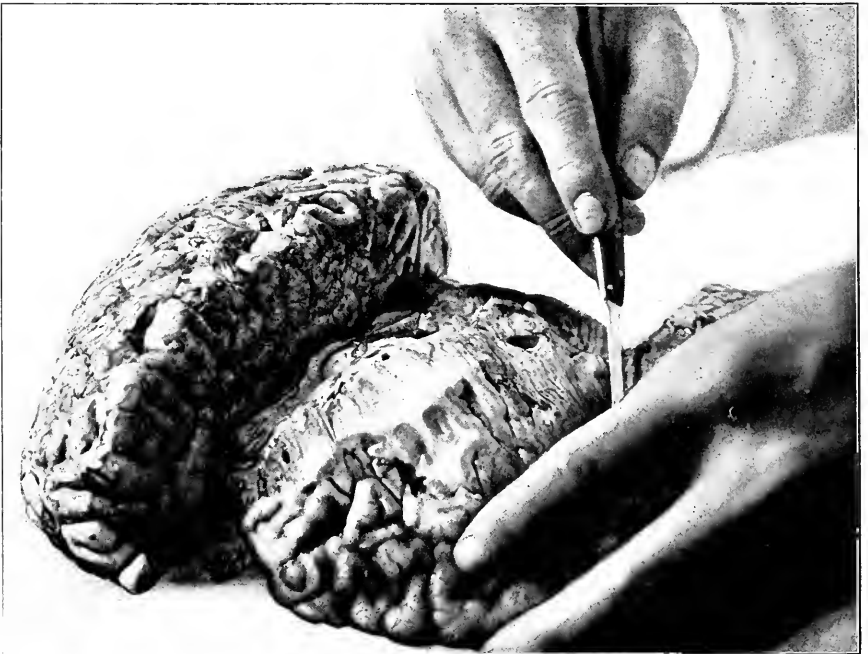


FIG. 142.—End of initial incision.

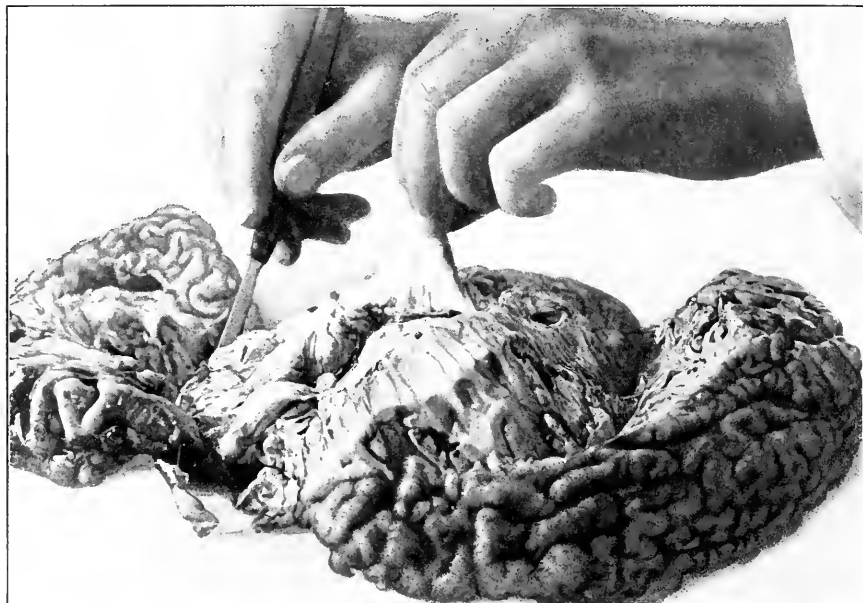


FIG. 143.—Exposure of the central portions of the brain.



FIG. 144.—Method of removing the cerebellar lobes from the pons Varolii and the medulla oblongata.

Unless this is done, a linear fracture—one near the foramen magnum, for example—might easily be overlooked. Special examinations should now be made of the orbit, internal ear, and nasopharyngeal cavities. The situation of the cranial nerves is seen in Fig. 140.

INTERNAL EXAMINATION OF THE BRAIN.

The brain may be sectioned either immediately upon its removal or after first being hardened, each method having its advantages. If an immediate diagnosis is required or colleagues are present to give unusual interest to a discussion of the findings, the sectioning will probably be done at once. If any hemorrhagic lesion is suspected, it is more conspicuous in the recent state, and a wholly unexpected bacteriologic investigation might be demanded by the revelations of the incisions. If none of these considerations prevails, the brain is hardened in a medium which will not interfere with any microscopic work that may be desired after the sectioning. Since hardening in certain fluids is necessary for certain stains and entirely precludes others, we must first of all decide what staining methods will be used before a choice of hardening fluids can be made. A two and one-half per cent. solution of bichromate of potassium or Müller's fluid will develop color contrasts between the white and gray matter and furnish material for Weigert and Golgi work, but the later methods for ganglion cells and neuroglia are precluded. Formalin is suitable for all special staining methods, including Nissl's, though here the best results are obtained when the tissues are hardened in alcohol.

The brain may be hardened entire in a ten per cent. solution of formalin in a week or ten days and be suited for general topographic work. For finer histologic methods the parts should be serially incised, the sections being not more than three millimetres thick and remaining *in situ*, or, if the material to be studied is not superficial, the brain may be incised according to the methods herein to be given and then hardened. The advantages of hardening the brain in most pathologic cases are so obvious that they do not require mention. It should always be done unless contraindicated, and when the fresh brain is sectioned and examined, the incisions should be so made that all the segments will fold together like the leaves of a book,—uninjured, undisturbed in their structural relationship, and fit for the most exhaustive microscopic examination.

Whether the brain is sectioned first or after hardening, the choice of a method will be somewhat determined by the situation of the lesion and the desire to preserve intact all its structural relations. Morbid changes in the cortex which we might wish to trace down through the internal capsule would be studied only with the greatest difficulty after sectioning by Meynert's method, whereas if the lesions were bulbar or situated anywhere in the brain-axis this method would be very advantageous, since it permits of examining the whole of the brain-axis by serial sections.

The centrum ovale is well studied by Pitres's method, but future microscopic investigation is impossible. The same is true of Nothnagel's method, and to examine lesions of the internal capsule we must have horizontal sections. For exposing suspected or unsuspected lesions, for gaining a good idea of the general condition of the brain, and for ease and rapidity of routine work, probably no method is more useful than that of Virchow. Unfortunately, it does not favor microscopic examination and therefore is rather sweepingly condemned by some authors.

Dejerine makes a special effort so to section the brain that it may be sufficiently exposed without in any way interfering with future investigation.

VIRCHOW'S METHOD.—A long, sharp knife should be used in the dissection, which should be kept clean and moist by frequent washing, so that the cut surfaces will be even and smooth. A dull knife tears the brain substance more or less, thus distorting the delicate structures.

The brain is placed on its base with its occipital lobes towards the operator. Laying the left hand upon the left hemisphere, with the thumb in the longitudinal fissure and the fingers upon the convexity, raise this hemisphere slightly and at the same time pull it away from the median line so as to expose the corpus callosum. Insert the point of a thin narrow knife into the roof of the lateral ventricle, which lies immediately below the corpus callosum, well forward and two or three millimetres externally to the median raphe of the corpus callosum (Fig. 141). Make a concave incision—concavity directed outward—through the roof back to the posterior cornu, being careful not to injure the floor of the lateral ventricle. Note the character and quantity of fluid present, which normally is perfectly clear and about three cubic centimetres in amount. Connect the two extremities of the first incision by a second and third incision meeting at an angle of 45 degrees just

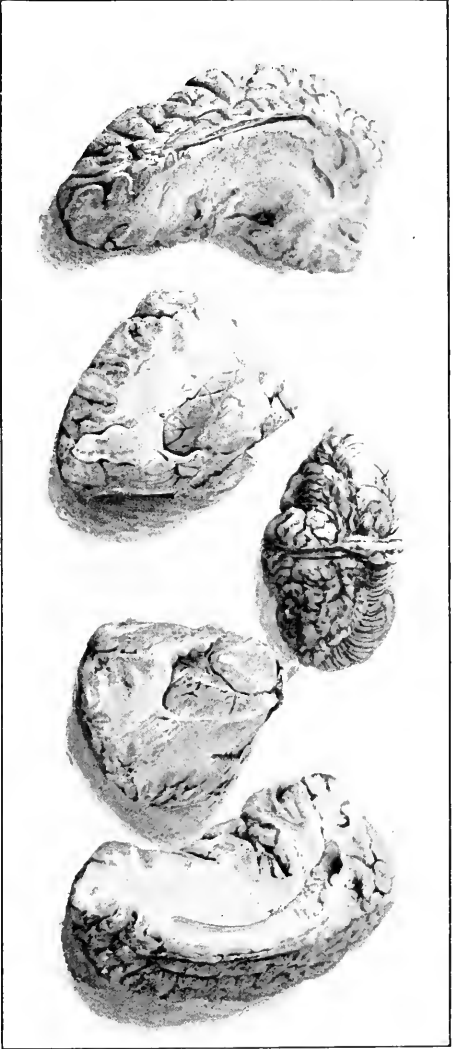


FIG. 145.—Segmented brain. The central portion has been divided into two parts. The cerebellum, pons Varolii, and medulla have been everted with the right and left cortical portions.



FIG. 146.—Method of sectioning the cerebellum.

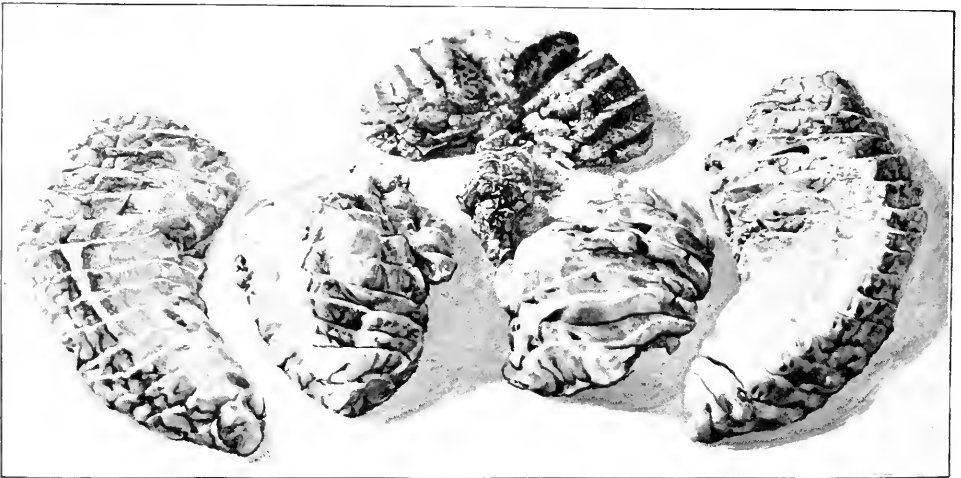


FIG. 147.—The whole brain after it has been sectioned.

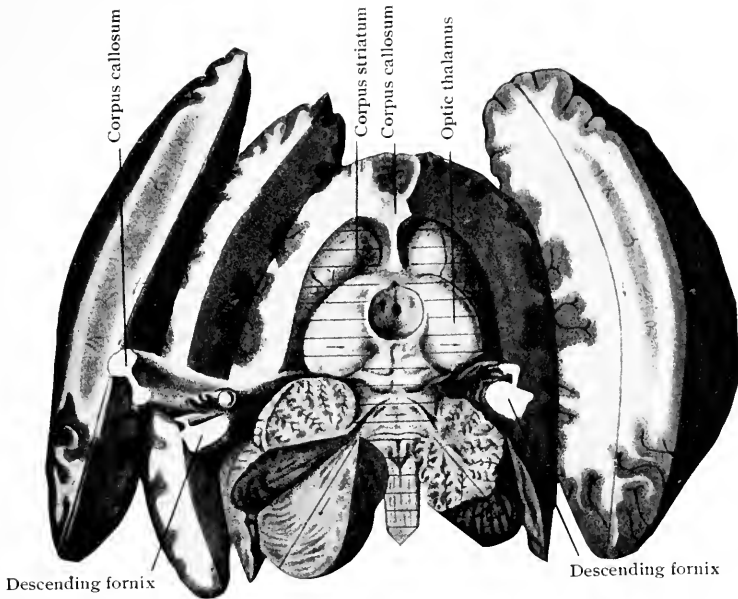


FIG. 148.—Section of the brain. The lines and arrows show the position and direction of the various incisions. (After Nauwerck.)

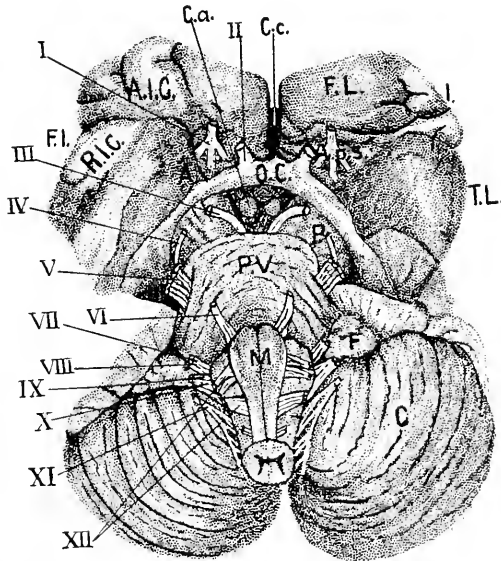


FIG. 149.—Basal ganglia, with cerebellum, pons Varolii, and medulla oblongata attached, in Meynert's method of dissecting the brain. The twelve cranial nerves are shown. *C*, cerebellum; *F*, flocculus; *M*, medulla; *P.V.*, pons Varolii; *T.L.*, temporal lobe; *F.L.*, frontal lobe; *P*, peduncles; *C.a.*, corpora albicantes; *C.c.*, central commissure; *R.I.C.*, retroinsular convolution; *O.C.*, optic commissure; *P.S.*, posterior roots of olfactory nerve; *I*, insula. (After Dejerine.)

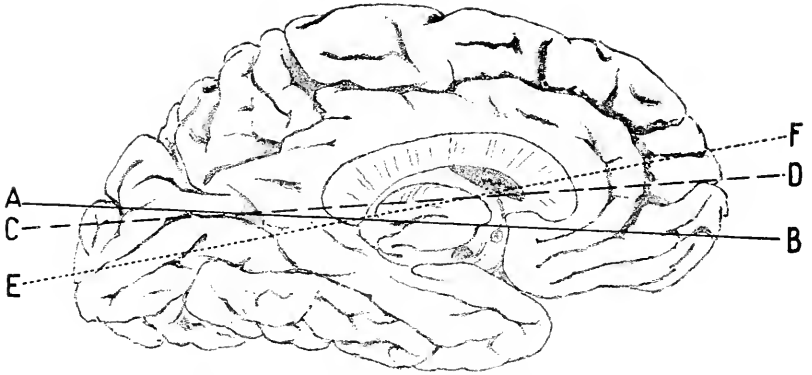


FIG. 150.—Sectioning of the brain. *AB*, incision practised by Flechsigs; *CD*, that of Brisaud; *EF*, that of Dejerine. The hemisphere to be incised is placed on its external surface, the occipital lobe towards the operator in case of the left hemisphere, and the frontal lobe for the right hemisphere. (After Dejerine.)

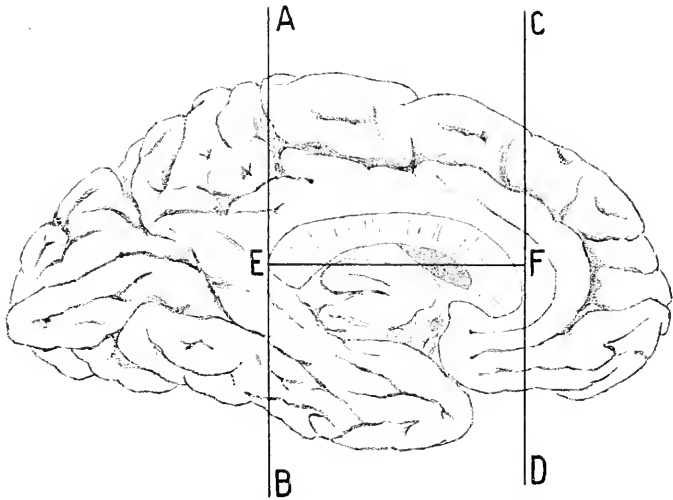


FIG. 151.—Incisions made by Dejerine in a case of cortical lesion previous to hardening.

outside the basal ganglia. In this manner the greater portion of the cerebral cortex on the left side will be removed away from the basal ganglia for future sectioning (Fig. 142). The right hemisphere may be turned half around and sectioned in the same way.

The knife is then introduced into the foramen of Monro and the anterior fornix is brought forward, exposing the vela interposita and the choroid plexuses, which with the body of the fornix are carried back, thus exposing the third ventricle (Fig. 143). The choroid plexus may be darkened by deposits of silver, and in the horse is a frequent seat of tumors. Then examine the corpus fimbriatum; the lyra; the anterior, posterior, and middle commissures; the corpora quadrigemina, the pineal body, and the commencement and lumen of the *iter a tertio ad quartum ventriculum*. The pineal gland is often infiltrated with salts, as may readily be determined after sectioning by rubbing a small portion of it between the thumb and index-finger. If it be desired to examine the fifth ventricle, an incision is made directly in the median line into the septum lucidum, parallel to the corpus callosum, the anterior fornix being elevated by the left hand and thus put on the stretch.

The crura are then severed by transverse incisions joining at about a right angle in the median line. The cerebellum, the medulla oblongata, and the pons Varolii are next to be removed. This may be done at the start, if preferred, reversing the order here given as to the other parts of the brain. After examining for dilated veins, tumors, and cysticerci, transverse incisions are made in the cerebellum on one side through the centre of the arbor vitæ, and then on the other side. The cerebellum may, however, be removed before these incisions are made by severing the medulla oblongata and the pons Varolii and dividing the cerebellar hemispheres in the median line into two parts. The pons, the medulla, and the commencement of the spinal cord may now be cut transversely by incisions one-fourth to three-eighths of an inch apart, and all pathologic changes carefully noted, but these portions are preferably hardened previous to examination, which is best accomplished by the preparation of serial sections. (Figs. 144 to 148, inclusive.)

Both Nauwerck and Orth, before making transverse sections of the pons and medulla, fold the sections of the brain together as you would the pages of a book in order that it may be turned. Then, pushing the fingers of the left hand under the pons and medulla, the transverse cuts may be made. In case of tumors or metastatic condi-

tions simpler methods may be used; thus, only one longitudinal or one transverse section may be made through the diseased as well as the healthy tissue, while the arachnoid is left intact.

MEYNERT'S METHOD, SLIGHTLY MODIFIED BY BLACKBURN.—The brain is placed with its base upward and the cerebellar end towards the operator. The cerebellum is elevated and the pia mater cut through above the corpora quadrigemina, around the crura, and along the inner margins of the temporal lobes until the middle cerebral arteries are reached. The Sylvian fissures are opened to their entire extent, the opercula are raised, and the insular lobes exposed to their limiting furrows.

The apices of the temporal lobes are now elevated, and, with the knife held nearly horizontal, their junction with the base is cut through until the anterior extremities of the descending cornua are opened. The knife is inserted in the descending horn, and the incision is carried backward as far as the posterior angle of the insula, or even some distance beyond it, severing some of the convolutions at the posterior extremity of the Sylvian fissure.

The next incision is made to separate the basal piece from the posterior extremities of the frontal lobes. It connects the anterior boundaries of the islands and opens the anterior horns of the ventricles. The incision may be a slightly curved, transverse one, connecting the anterior border of the islands; or, by a little care and a double crescentic cut, the exact boundaries of the convolutions may be followed.

The cerebellum is now raised, the knife entered at the posterior angle of the island, and the incision carried along the outer limiting furrow until it meets the cut previously made through the anterior border. Care must be taken to keep the knife in the angle between the roof of the ventricle and the basal ganglia, to avoid injuring the latter. The basal piece is now lifted until the anterior crura of the fornix and the septum lucidum may be severed, and the basal section thereby completed.

The basal piece thus separated includes the island of Reil, the basal ganglia, the crura, pons, medulla, and cerebellum. (Fig. 149.)

PITRES'S METHOD.—The lateral ventricles are exposed as in Virchow's method. The hemisphere lies on its under surface and a series of six transverse vertical sections are made parallel to the fissure of Rolando. These are called the prefrontal (five centimetres in front of

the Rolandic fissure), pediculofrontal (at the front of the frontal convolution), frontal (ascending frontal convolution), parietal (ascending parietal convolution), pediculoparietal (at the front of both parietal lobes), and occipital (one centimetre in front of the parieto-occipital fissure). Pitres's method is very useful for localizing lesions in the centrum ovale, but not at all adapted to studying the internal capsule or to subsequent microscopic work. The same is true of the closely similar method of Nothnagel. Flechsig's, Brissaud's, or Dejerine's primary incision may be made, and after studying the cut surfaces the two parts are replaced and Pitres's cuts added thereto.

The next method to be described, that of Dejerine, gives the best results of any of the methods now in vogue.

METHOD OF DEJERINE.¹—The brain is examined upon all its surfaces to see if there be any cortical lesion. The inferior surfaces of the crura are carefully inspected for secondary degenerations. The cerebrum is separated from the cerebellum by sectioning the pons horizontally in a plane directly parallel with the inferior surface of the hemispheres and passing just above the great root of the trifacial. Fig. 150 shows the direction of the incisions adopted for this purpose by Flechsig, Brissaud, and Dejerine. This divides the brain into two portions. The upper one contains the two hemispheres, the cerebral peduncles, and the superior portion of the pons, while the corpora quadrigemina is preserved intact by the obliquity of the incision. The lower portion contains the rest of the pons, the cerebellum, and the medulla. The surfaces of the section through the pons are carefully examined for degenerations in the pyramidal tracts, and the two hemispheres are separated after determining in which one the lesion is situated, which is often decided by the appearance of degenerations in the cut surfaces of the pons. While Dejerine regards this as important to determine, because the corpus callosum should be sectioned as close as possible to the normal hemispheres, and the incision should not pass through the interpeduncular space, but encroach at least a centimetre upon the sound peduncle and corresponding portion of the pons, other neuropathologists object to this mode of procedure as being apt to cause disfigurement of the parts.

The method of examining the hemispheres is determined by the situation of the lesion,—whether it is central or cortical. If central

¹ *Anatomie des centres nerveux*, 1895, p. 22.

the only degenerations that are of importance are those of the tracts of the internal capsule and in the region of the tegmentum (dorsal portion of the crus cerebri). Divide each hemisphere by a horizontal incision passing through the superior third of the optic thalamus, harden, prepare a drawing of the part, and section with a microtome.

If the lesion is cortical the brain is sectioned by (1) a vertical transverse incision (Fig. 151, *CD*) passing just posterior to the splenium of the corpus callosum, and (2) a vertical transverse incision (*AB*) just anterior to the knee of the corpus callosum. In this way the hemisphere is divided into three segments. The posterior segment is composed of the occipital lobe and part of the parietal. The anterior is the forepart of the frontal lobe. The central is the largest and contains the regions adjacent to the fissure of Rolando, the middle portion of the temporal convolutions, the posterior portion of the frontal convolutions, the basal ganglia, the cerebral peduncle, and the corresponding part of the pons. The anterior and posterior segments are hardened as they are, and the central segment also if the cortical lesion is extensive and deep so that the fluid can penetrate easily; if not, a horizontal section (*EF*) is made through the superior third of the optic thalamus. In either event the pieces are hardened and cut with a microtome, preferably of the Gudden type. The anterior and posterior segments are cut vertically transversely and numbered. The central segment or segments are incised horizontally. In this way not only can a cortical lesion be localized with great precision, but traces of degenerating fibres may be studied throughout their whole extent, which is not practicable by any other method.

HAMILTON'S METHOD.—Hamilton injects the vessels of the brain¹ as follows: The brain is freed from the dura, but not from the pia and arachnoid, weighed, and injected through the vessels at the base with Müller's fluid or any other hardening agent desired. It is well to have a round stoneware jar with a lid of sufficient size, three fair-sized cannulas, several feet of good rubber tubing of a calibre to receive the ends of the cannulas, and a three-tubed "distributer." A piece of the rubber tubing about eighteen inches long having been firmly tied on one end of a cannula, its other end is tied into an artery,—viz., one into each carotid and one into one of the vertebrales, the opposite vertebral being securely ligated. The brain, with its attached tubes, is

¹ *Text-book of Pathology*, 1889, vol. i, p. 56.

now placed in the jar, which is partly filled with the hardening fluid. The weight of the cannulas and tubes is taken off the vessels by suspending the tubes over the edge of the jar. Tie the other ends of the rubber tubes to the three arms of the distributor, and connect the common tube with the stopcock of a tank filled with the preservative fluid, which can be conveniently raised or lowered at will, and is now placed about four feet above the brain in the jar.

When certain that all attachments are secure, the stopcock is gradually opened, allowing the tubes to become filled and the fluid to percolate slowly through the brain. Care should be taken that the cannulas do not bend the arteries short upon themselves, thus occluding their lumina. The first fluid which passes through will be mixed with blood and should not be used again, but when it has become clear it may be used over and over. It usually runs through very quickly, and the tank should be refilled at least every day for the first week, and oftener if convenient. The brain should always be in an excess of the fluid and a vessel provided for the overflow. For refilling the tank it is best to draw some of the liquid out of the jar with a siphon, which will not disturb the brain or the position of the cannulas.

A week or two will suffice in urgent cases, but the longer the brain remains in the fluid the better will be the hardening. Some of my most beautiful specimens are those which were kept in Müller's fluid for five or six months. Haste and thoroughness are incompatible in this process. No padding should be used to keep the organ in position, the best and surest agent for this purpose being a plentiful excess of the liquid and an occasional change in its position.

If it seems unnecessary to inject the vessels, the following method may more easily be carried out and gives most excellent results: An open jar, bucket, or wash-basin is one-quarter filled with absorbent cotton, and Müller's fluid—to which one per cent. of formalin may be added with great benefit—is poured in until the vessel is about half full. The brain, after being weighed, is carefully placed in the centre of the vessel and more fluid is added until the organ is well covered, when it is placed in a refrigerator. If this be done, even though the arteries have not been injected or any incision made into the ventricles, there is no danger that the brain will decompose, even in summer. On the next day the position of the brain is altered and the fluid changed. The renewal of the fluid can best be accomplished with a siphon, only a part of it being removed at one time.

The fluid is changed again on the third day, then every other day for three times, twice a week for the next three weeks, and once a week for the final three weeks. Remember that the jar is uncovered, and this allows of the evaporation of the fluid and possible spoiling of the specimen. The brain can then be thoroughly washed and put in 80 per cent. alcohol, or the Müller fluid can after the fifth or sixth week be diluted with one-fifth alcohol, then with one-quarter, one-third, one-half, and finally three-quarters alcohol, where the brain can be kept for several months until it is transferred to the alcohol of 80 per cent. strength. Instead of Müller's fluid a 2.5 per cent. solution of bichromate of potassium may be employed. About two thousand cubic centimetres of a 10 per cent. formalin solution are used and changed every third day.

GIACOMINI'S METHOD.¹—This is well adapted for the macroscopic study of the brain, but, on account of the zinc chlorid used, the tissue is rendered unfit for microscopic work. If the specimen is a brain tumor, a small portion of it may be placed in a hardening fluid for microscopic study and the remainder then treated by this process.

The brain, in as fresh a state as possible, is put into the *Liquor zinci chloridi* (U. S. P.). It will be found to float at first and should be turned several times the first day. On the second day the pia and arachnoid, which until now have been useful in keeping the brain intact, are removed while the organ is under water or floating in the fluid; if allowed to remain longer, they become so adherent to the cortex as to be separated with difficulty and more or less damage to the cortical substance. The brain is left in the fluid for from six to ten days, then removed, well washed with water, and put in 95 per cent. alcohol for ten days or two weeks and next in glycerin for another ten days or more. After this it is placed in absorbent cotton and exposed to the air in a dark place free from dust. Any exudation should be carefully removed, and when no more appears (which may be in from several weeks to as many months) the surface is to be well coated with the best mastic varnish.

OTHER METHODS.—See page 377 for the preparation of brains with the object of preserving their natural coloration. Stroud² uses sodium acetate, 400; sodium chlorid, 350; formalin, 60; alcohol, ninety-five per cent., 1400; and water, 1600.

¹ *Gior. di r. Accad. di med. di Torino*, 1883.

² *Med. News*, December 9, 1905.

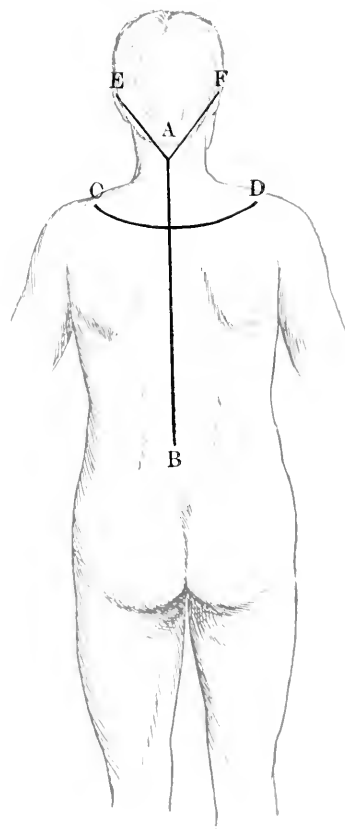


FIG. 152.—Lines for removing the spinal cord and the brain, the latter through a small triangular occipital incision. *AB*, initial incision for removal of the cord; *CD*, curved incision for the purpose of avoiding division of the skin above the dressed portion of the body; *EAF*, angular incision in the occipital bone through which to remove the brain without elsewhere opening the skull.

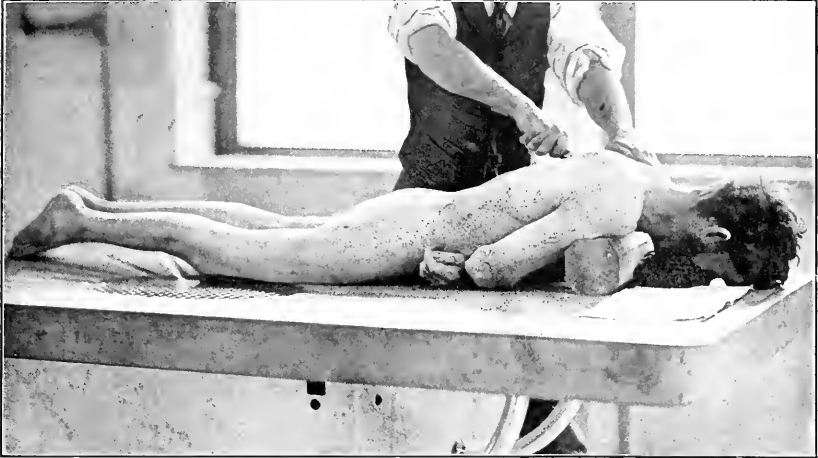

FIG. 153.—Position of the body in removal of the spinal cord. The primary incision is being made. Face protected by a sponge.



FIG. 154.—Removal of spinal cord. The primary incision has been made and the vertebral column freed from muscle, fascia, etc. The angle at which the saw should be held is well shown.



FIG. 155.—Removal of spinal cord. The sawing having been completed at a convenient point in the dorsal vertebra, the sawed bone is elevated with the fingers or, if strongly attached, with the forceps.

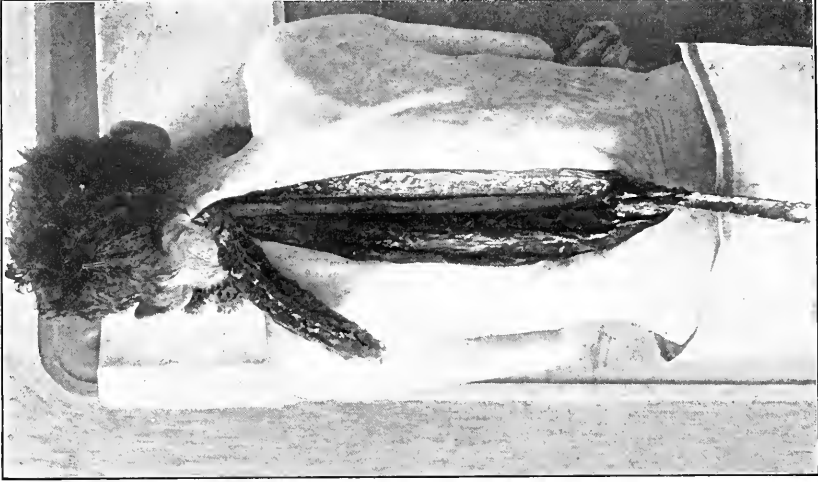


FIG. 156.—Removal of spinal cord. The spinal canal is well shown with the dura mater still intact. The sawed portions of bone both above and below are left attached.



FIG. 157.—Removal of spinal cord. The atlas and the axis are being severed with the costotome.




FIG. 158.—Removal of the spinal cord with its dura. The lower end is held with the left hand while the nerves are being severed. FIGS. 154 to 158, inclusive, are from photographs taken directly from above.



FIG. 159.—Opening of spinal cord.

CHAPTER XIV

THE SPINAL CANAL, THE SPINAL CORD, AND THE NERVES

THE spinal cord may be removed either anteriorly or posteriorly,—*i.e.*, by excising the bodies of the vertebræ through the thorax and abdomen freed from their viscera or by severing the laminae and spinous processes of the vertebræ through an incision posteriorly. The latter route is decidedly the more convenient and is used whenever possible. Generally it is best to remove the cord before the abdomen is opened, this being a cleaner operation, an important factor in private practice.

The cadaver is placed prone upon the table close to the side at which the operator stands, with the head hanging over the end or, better, with a block under the chest and neck and, if desired, one under the lumbar region. Beginning at the external occipital protuberance, an incision is carried along the centre of the back over the spinous processes to below the fourth lumbar vertebra, dividing all the tissues down to the bone. (Figs. 152, *A B*, and 153.) The incision is made low in order to allow for room for future manipulations, as the tissues here are thick and the future sawing is to be done in a hollow, as it were. The superficial and deep structures are then dissected from the bones, exposing the vertebral groove on either side of the spinous processes. Or, after incising the skin over the spinous processes, insert the knife, with its back downwards, at the lower end of the incision and cut upwards along the column, keeping the blade pressed against the spinous processes. In this way the fibrous attachments are cut close and the vertebral groove is clean and free from troublesome soft tissues. The soft parts should be very thoroughly removed, as they would interfere considerably with the subsequent sawing. This can be quite well done by zigzag scraping with a chisel or an old knife.

In cases of luxation, fracture, Pott's disease, etc., it may be desirable to remove portions of the vertebral column *en masse*. This can readily be done by the proper use of a saw after severing the intervertebral cartilages above and below the lesion. The space is then filled up in the restoration of the body by inserting a stick in the opening and pouring plaster upon it.

The canal is easily opened with Luer's rhachiotome, an adjustable, double-bladed saw devised for the purpose (Fig. 26). It does the work more quickly, but has the serious fault that it is liable to become impacted and injure the cord in its release. The same object may be accomplished with a single-bladed saw having curved ends (Fig. 22). The lamina should be sawed close to the transverse process, with the saw teeth held away from the spine at an angle of about thirty degrees (Fig. 154). Unless this direction is taken there is some danger that the canal will be missed or that the blade may enter it and the cord be injured. Orth calls attention to the fact that one can tell when sufficient sawing has been done by the mobility of the spinous processes. Other instruments which may be used are the double chisel of Esquirol, the knife-shaped chisel of Brunetti, and the rhachiotome and hammer of Amussat, the latter being much preferred in France to Luer's rhachiotome, which is not approved of. If the rhachiotome is used, as the seventh cervical vertebra is approached, both from above and below, the incisions are made more and more towards the side, as the canal is wider here, owing to the increased size of the cord at this spot. After the canal has been opened in the dorsal region with the saw, a pair of bone-nippers is used to pry up the portions of vertebra thus loosened, and the dura is exposed (Figs. 155 and 156). The sawing can then be continued in both directions until the entire canal is opened, except the atlas and axis, which had better be cut with bone-forceps (Fig. 157). The ligaments here, as the ligamentum nuchæ and the ligamenta flava, are very strong. In using either bone-forceps or pliers be very careful not to produce artefacts of the cord. The cord at the first dorsal vertebra is then tied with a string, so as to have the situation accurately determined, or the first dorsal nerve may be dissected out and left attached to the cord.

The spinal cord, covered with its membranes and at times considerable fat, may now be studied *in situ*, after which the dura and the spinal nerves are divided *below* the cauda equina. The dura being elevated with the fingers or forceps and pushed to one or the other side, the spinal nerves are cut, with a long, thin, narrow-pointed, sharp knife, close to their points of entrance into the intervertebral foramina. (Fig. 158.) The dura at the foramen magnum can best be severed from the bony margin above after the brain has been removed. The cord may be taken away with the brain attached if so desired. The spinal ganglia are situated outside the dural sac and

are best exposed by the anterior incision as practised by Hyrtl. The thirty-one pairs of nerves may be extracted with the cord by cutting away the articular processes and gently pulling the cord, by the dura, to the opposite side and severing the nerve as far in the foramen as possible. If the cord be removed first and the brain hung down over the table, there may occur a peculiar hemorrhagic infiltration of the loose tissues around the pons.

By making a median incision in the dura mater the cord is exposed, and can, of course, be removed. This procedure, however, is more liable to cause injury to the cord than the method given above.

After freeing all points of attachment the cord must be very gently transferred to the table or tray for further examination. Study the dura for (1) thickness, (2) color, (3) blood; the cerebrospinal fluid for (1) pus, (2) blood; and the pia for (1) expansion, (2) thickness, (3) contained blood, and (4) color. Gentle palpation may reveal areas of softening or sclerosis. The further manipulation of the part will depend upon the extent of the examination required. If the cord is to be preserved for future study, the dura is opened in the median line throughout its entire extent, the blade being inserted at the lower end, and transverse incisions about one inch apart down to the pia are made in the cord. It may be hardened at the same time and in the same jar as the brain by curling it around that organ; but it is better to suspend it by the dura, with a small weight attached, in a long jar, or it may be kept in such a jar lying upon its side. In summer the jar should be placed in the refrigerator.

If the examination is to be completed immediately, the cord is laid out on the table, with its anterior surface resting preferably on a towel or piece of cheese-cloth, and the dura opened throughout its entire length as already directed. Note is made of the conditions observed. Much valuable information can be obtained by the macroscopic examination, especially if a hand-glass be used and diagrams made at the time. Then, with a sharp, thin knife, which should be moistened with water after several incisions, transverse sections about an inch apart are made through the cord and membranes; the under surface of the dura, however, is left uncut, in order that the cord may be replaced in its entirety. A careful operator may hang the cord over the index-finger of the left hand, keeping it in place with the thumb, and make the incisions there, the dura being sufficient to protect the finger. (Fig. 159.) A microtome knife is admirably adapted for making the incisions. Areas of softening should not be incised, because of

the inevitable disturbance thus produced in the relations of component parts. Froriep's incision of the spinal cord, one long longitudinal incision throughout the entire extent of the cord, is severely criticised by Virchow. The place from which sections are removed for microscopic study may best be determined by the situation of the nearest nerve-roots. Coplin mounts the cord upon long strips of notched celluloid, one side of which is roughened for writing with lead pencil.

Where the avoidance of disfigurement above the parts covered by clothing is a matter of great importance, sufficient room for opening the cervical canal can be obtained by making a crescentic incision from the centre of one shoulder to the other, with the concavity towards the head, and dissecting up the skin. (Fig. 152, *C D*.)

Sometimes it is advantageous, especially in private cases, to open the canal by removing the vertebral bodies through the long anterior incision with the body resting on its back and elevated by a block placed under the back so as to render the vertebræ about to be cut as prominent as possible. Brunetti's chisels were devised for this purpose. After removal of the thoracic and abdominal viscera, including the psoas muscles, the pointed guard is inserted into the vertebral canal, and the instrument, held parallel with the long axis of the spinal column, is driven forward with a mallet, thus severing the pedicles and removing the bodies or anterior wall. By this method the spinal ganglia and nerves are rendered more easily accessible for study and subsequent removal. The remaining steps are about the same as those described for the posterior incision.

The following simple procedure for the removal of the anterior tibial nerve, anterior tibial artery and vein, and portions of the muscles is used at the Phipps Institute of Philadelphia:¹ An incision about two inches in length is made along the outer surface of the leg, over the upper end of the fibula. The skin-flap is dissected back to the crest of the tibia, and a long, thin knife is then inserted and a section made the length of the skin incision close to the anterior surface of the fibula as far as the tibia. Two transverse cuts in the direction of the bone are made at either end. The portion of the tissue removed will be found to be composed of muscle and a portion of the anterior tibial nerve, anterior tibial artery, and vein on its under surface. A wad of cotton is placed in the wound, to take the place of the muscle removed and to prevent deformity, and the skin incision is sewed up.

¹ D. J. McCARTHY, *Med. Notes and Queries*, February, 1906, p. 36.

CHAPTER XV

DISEASES OF THE BRAIN, SPINAL CORD, AND NERVES

THE study of neuropathology is an intricate but most interesting field of investigation. On the one hand, lesions such as syringomyelia and hemorrhage into the lateral ventricles are most easily recognized with the naked eye, while, on the other hand, the pathology of such common clinical manifestations of disease as delirium, neurasthenia, hysteria, neuralgia, vertigo, headache, and many varieties of insanity, is most obscure. Again, much that made the man, as sight, hearing, touch, smell, taste, speech, reflexes, thought, and the power to distinguish right from wrong, disappears with death.

There exists to-day the greatest lack of uniformity as to nomenclature in diseases of the brain and cord. Thus, progressive (central) muscular atrophy, chronic anterior poliomyelitis, amyotrophic lateral sclerosis, and progressive bulbar paralysis are clinically, and to a large extent pathologically, one and the same, the anterior roots being diseased and the anterolateral tracts affected; while Friedreich's *ataxia* is hereditary ataxia, and Friedreich's *disease* is paramyoclonus multiplex. In systemic diseases it is well to remember that both the motor and the sensory neurons are involved. An article by Barker in the *Journal of the American Medical Association* for March 31 and April 7, 1906, gives an excellent account of the present state of our knowledge concerning the neurons.

ACROMEGALY. — A chronic disease of nervous origin, occurring most frequently in adults, and characterized by an overgrowth of the bones, especially those of the face and extremities, by malnutrition, and by impairment of the senses. Morbid changes are to be found in the pituitary body (hypertrophy, colloid degeneration, tumors, etc.) and usually in the thyroid and thymus glands. There are marked hypertrophy of the bones of the face (especially the maxillæ) and osteophytic growths on the bones of the hands and feet, with exaggeration of the normal ridges and tubercles. The thorax is enlarged and kyphosis may be present. The sternum is thickened, lengthened, and widened, as are also the ribs and clavicles. There may be hypertrophy of the pharynx and larynx, leading to marked dyspnœa. In

one of my cases, Spiller¹ found a sarcoma of the pituitary body, which had arisen from an epilus; in another, all the glands of the body appeared to be hypertrophied. I have removed *post mortem* the pituitary body through the orbit. Under acromegaly may also be considered OSTEITIS DEFORMANS, an affection which causes softening and distortion of the long bones of the body; HYPERTROPHIC PULMONARY OSTEO-ARTHROPATHY, where there is antecedent lung disease and the bones of the skull are not involved; and LEONTIASIS OSSEA, an overgrowth of the bones of the cranium. In MICROMEALY atrophy is found in the place of the hypertrophy of acromegaly. FRAGILITAS OSSIUM (*osteogenesis imperfecta*) shows abnormal osseous development in which there is a marked tendency for the bones to bend and to break. In ACHONDROPLASIA the dwarfs measure from three to four feet in height, the extremities being much shortened in relation to the other parts of the body, due to a dystrophy of the epiphyseal cartilage. (Osler.) Gilford's diseases—ATELIOSIS, continuous youth, and PROGERIA, premature old age—are forms of infantilism.

ATAXIA, LOCOMOTOR (TABES DORSALIS; POSTERIOR SPINAL SCLEROSIS; DUCHENNE'S DISEASE).—A chronic disease of the nervous system, characterized by sclerosis of the cord and brain, and by incoördination, with motor, sensory, and trophic disturbances. (a) Male sex. (b) Adult life. (c) Syphilis. (d) Wet and cold. (e) Sexual excesses, etc. (1) *Spinal Cord*.—Externally the meninges are thickened and adherent. Posterior roots (spinal ganglia) are atrophic and of a grayish tint. Internally sclerosis of the cord begins in the posterior-root zone, involving the outer layers of posterior columns in the lumbar region. The sclerosis gradually extends inward, involving successively the columns of Burdach and Goll; when the process reaches the upper dorsal region, it is confined to the column of Goll. The cord presents a flattened appearance posteriorly, the sides being somewhat contracted. The diseased areas are firm, grayish or grayish red in color, and the whole cord is often firmer in consistency. Both motor and sensory neurons are involved. (2) *Brain*.—Changes, of less consequence than in the cord, may be sclerosis in restiform bodies, inferior peduncles of cerebellum, and certain cranial nerves,—the oculomotor, optic, and auditory. Atrophy, especially of the optic nerve, and hemiplegia may occur. Some recent writers now con-

¹ *Jr. Nerv. and Ment. Dis.*, January, 1898, p. 42.

sider paralytic dementia to be such a disease of the brain as locomotor ataxia is of the cord. (3) Peripheral nerves may show degeneration or even neuritis. (4) In later stages occur dermopathies and arthropathies,—*c.g.*, perforating ulcer of foot, herpes, Charcot's joint, etc. The essential lesion is a dystrophy attacking the peripheral sensory neuron. Erb¹ has found that out of a total of 1100 cases of tabes there was an unmistakable history of syphilis or chancre in 89.45 per cent., syphilitic antecedents were probable in all but 2.8 per cent., and even in the last syphilis is suspected by Erb. In 96 cases of tabes Lesser² found an aneurism in 18, and speaks of these processes as the quartan manifestations of syphilis. Recent efforts have been made to show that it is not the syphilis which causes this disease, but the mercury used in the treatment of this venereal affection. (Wolter.³)

CAISSON DISEASE.—A peculiar hemorrhagic affection, the result of a sudden reduction of atmospheric pressure, which occurs in bridge-builders, divers, etc., who, after working for hours under a pressure of two or three atmospheres, have suddenly returned to air of normal density. In fatal cases there is a marked destruction of nerve-tissue in the posterior columns and the posterior portions of the lateral columns, forming fatty detritus and compound granular cells. Free bubbles of nitrogen are said to exist in the circulatory system of those affected, and it is possible that their escape from the nervous system gives rise to the symptoms.⁴

CHOREA.—(I) *Acute Chorea; St. Vitus's Dance; Sydenham's Chorea*. Probably an infectious disease, occurring especially in early life in females, and characterized by involuntary muscular contractions of great irregularity. Most cases which come to the post-mortem table show ulcerative endocarditis with embolism of the cerebral vessels, vascular changes, and the so-called chorea bodies, which consist of round or oval structureless formations, varying in size from that of a neuroglia cell up to tenfold its diameter. There is also granular change in the chromophilic elements. The basal ganglia and the motor and pyramidal tracts are especially affected. The pigmentation sometimes seen is due to the arsenic administered for therapeutic purposes. (II) *Huntington's Chorea; Chronic Heredi-*

¹ *Berl. klin. Wchnschr.*, 1904, vol. xli, nos. 1, 2, 3, and 4.

² *L. c.*, no. 4, p. 80.

³ *St. Louis Courier of Medicine*, February, 1906.

⁴ HOCHÉ, *Berl. klin. Wchnschr.*, 1897.

tary Chorea. An hereditary disease appearing after the age of thirty, and consisting in motor, speech, and mental disturbances. This disease is a chronic meningo-encephalitis with atrophy of the convolutions (Facklan and Osler). (III) *Canine Chorea.*

COMPRESSION OF THE SPINAL CORD.—(a) Caries of the spine. (b) New growths. (c) Aneurism. (d) Parasites. (e) Distention of central canal by inflammatory liquid or blood. Changes appear first in the white matter, the fibres of which may within six hours swell up and disintegrate.

CONGENITAL ANOMALIES. — Craniioschisis, rhachioschisis, hydro-meningocele, encephalocele, myelomeningocele, hypoplasia of different parts, as of the cerebellum, micrencephaly, hydrocephalus, internal and external porencephaly, idiocy, cretinism, micromyelia, total absence of parts, anomalies of distribution, and many others.

CRETINISM.—In cretinism there is a low form of idiocy associated with anatomic changes in the thyroid gland, as absence, hypoplasia, atrophy, or goitre. It is endemic in certain localities, notably Switzerland. Heredity bears a causative relation. The condition usually appears at birth. The child is stunted and dwarfish in appearance. The trunk is large in proportion. The head is flat, the face broad and expressionless, the eyes dull and stupid, the nose flat and depressed, the lips thick, and the tongue large and usually protruding. The teeth are carious; the hair is thin, brittle, and harsh; the skin about the hair is dry and scurfy. The abdomen is prominent; the legs are short and thick, and the hands and feet are undeveloped. The skin is yellow, leathery, and rough.

EPILEPSY.—Considered as due to intravascular clotting of the cerebral vessels, with defective and unstable nerve-cells. The most important changes found in the nerve-cells are: (1) A form indicative of imperfect development. (2) Retention of subcortical nerve-cells. (3) Either an acute form of cell change, similar to that produced by ligature of the cerebral arteries in a dog, or (4) groups of darkly stained, shrunken cells, representing a more chronic change. Changes in the vascular system: (5) Large numbers of blood-plates in the blood. (6) Different forms of intravascular clotting, probably in large measure derived from amalgamation of the blood-plates, but to some extent also probably due to destruction of red blood-corpuses. (7) Small cortical hemorrhages, which in some cases can be traced to rupture of a vessel blocked up by the beforementioned

clot. (Turner.¹) In *Jacksonian* or *cortical epilepsy* the convulsions are localized. Starr, in two thousand cases, found one hundred and ninety-two with maldevelopment of the brain.

ERYTHROMELALGIA.—In this condition there is arteriosclerotic thickening of the blood-vessels with diminution of their lumen (obliterative arteritis) and some involvement of the peripheral nerves.

HEMIPLEGIA.—It may follow: (1) Traumatic lesions of the brain and cord; (2) meningeal lesions due to hemorrhage, inflammation, syphilis, and tuberculosis; (3) cerebral lesions due to hemorrhage, softening, tumors, abscesses, and sclerosis; (4) cerebrospinal lesions of tabes, multiple sclerosis, and general paralysis of the insane. It may be due originally to: (1) Intoxication by uræmia, diabetes, alcohol, lead, mercury, and some carbon compounds; (2) infections from pneumonia, malaria, typhoid fever, puerperal fever, eruptive fevers, diphtheria, influenza, syphilis, and tuberculosis; (3) it marks some cases of chorea, hysteria, and paralysis agitans. (Church.)

HÆMATOMYELIA.—Hemorrhage into the cord. (a) Traumatism. (b) Exposure. (c) Convulsions. (d) Tumor. (e) Syringomyelia. (f) Myelitis. (g) The cord is usually enlarged, occasionally lacerated. The blood is generally confined to the gray matter, but may escape beneath the membranes.

HEREDITARY ATAXIA (FRIEDREICH'S ATAXIA).—A form of ataxic paraplegia occurring in several members of the same family, especially in the young children. (a) More frequent in males than in females. (b) Cord involvement occurs first and is most marked. (c) There is a gliosis of the dorsal column of the spinal cord, due to developmental errors. (d) Talipes equinus occurs in both feet. (e) Lateral curvature is common. In the hereditary cerebellar ataxia of Marie and Nonne the cerebellum is first involved. Atrophy of the cerebellum has been found; in some cases no microscopic changes were discovered but atrophy of the cells of Purkinje.

HERPES ZOSTER.—An acute hemorrhagic inflammation of the dorsal (posterior) root ganglia. The axis-cylinders are degenerated and there is actual destruction of some of the ganglionic cells. In the peripheral nerves even sclerosis may be produced.

HYDROCEPHALUS.—This condition may be congenital or acquired; acute or chronic; within the ventricles or subdural (external hydroceph-

¹ *Brit. Med. Jr.*, March 3, 1906, p. 496.

alus). The amount of the fluid may reach into the gallons; its characteristics being those of normal cerebrospinal fluid. Lead poisoning is a recognized cause, and the blue line may be found on the gums.

INFANTILE PARALYSIS (ACUTE ANTERIOR POLIOMYELITIS; ATROPHIC SPINAL PARALYSIS; ESSENTIAL PARALYSIS OF CHILDREN).—This juvenile disease is quite probably of infectious origin, and is the one which gives in later life such numerous opportunities for the surgeon and the instrument maker to make useful a shrunken limb. (1) There occurs a destruction of ganglion-cells in the anterior gray horns of the spinal cord. (2) The seat of the lesion is in the part of the spinal cord supplied by the anterior median branch of the anterior spinal artery. (3) Cervical or lumbar portions of the cord are most often affected. (4) In the early stages the lesion is an acute hemorrhagic myelitis, with rapid local destruction in part or whole of the large ganglion-cells and degeneration of their fibres, and eventually of the muscles depending on them for innervation.

INFLAMMATION.—Any portion of the membranes of brain and cord or of these organs themselves may show the effects of inflammation, and certain organisms or their toxins brought by the blood seem to have a direct action upon especial portions of the nervous system. (I) In *External Pachymeningitis* the outer surface of the dura becomes infected as a secondary condition, as from a fracture or a middle-ear disease. (II) In *Acute Cerebrospinal Leptomeningitis* the pia and arachnoid of the brain and spinal cord are affected, the choroid plexus often being involved. Causes: (a) Acute infectious fevers. (b) Injury or disease of the skull. (c) Extension of disease from nose, ear, or Eustachian tube. (d) Pyæmia. The organisms most commonly found are the *Meningococcus*, the *Pneumococcus*, the tubercle bacillus, the *Diplococcus intracellularis*, and the cocci of inflammation; more rarely, the bacilli of influenza and of typhoid, the colon bacillus, and the *Gonococcus*. Classification.—(a) Simple or traumatic. (b) Purulent. (c) Tuberculous. (1) In simple or purulent meningitis the membranes are thickened, the blood-vessels are dilated, and there is more or less exudation, which may be serous, serofibrinous, or purulent. The exudation may be so extensive as to cover up the convolutions. The inflammatory process is most marked in the basilar portions. It may be unilateral or bilateral. In the former the condition is due to extension from neighboring parts. (2) The tuberculous form of the

disease is usually cortical as well as basilar. It begins as a miliary tuberculosis, and in the early stages exudate is not extensive. The ventricles also may be involved and present considerable distention and softening, hence the name given to this condition, of acute hydrocephalus; they seldom suffer in other forms of the disease. Cytodiagnosis may be possible. See also p. 352. (III) In *Meningo-encephalitis* (*Chronic Diffuse* or *Deep Chronic Leptomeningitis*) there is chronic inflammation of the pia mater. The membranes of the brain are thickened and opaque and more or less extensively adherent to the cortex, which is torn on attempting to remove them. The convolutions of the brain are atrophied, especially in the frontal and parietal regions. The gray matter may be obscurely outlined. The white matter is firm in consistency. The ventricles are dilated and the ependymæ granular; frequently there are areas of hemorrhage or softening associated with chronic arteriosclerosis. There is an increase in the cerebrospinal fluid. Usually sclerosis of the posterior columns, with involvement of the lateral, is found. There may be an extraordinary development in the lymph connective system of the brain, with a parallel degeneration and disappearance of the nerve-elements and the axis-cylinders, and finally shrinking and extreme atrophy of the parts involved. (IV) *Abscess*.—There may be a circumscribed collection of pus in or upon the brain substance, with or without a distinct pyogenic membrane. The micro-organisms most usually concerned are the *Staphylococcus pyogenes*, *Streptococcus*, *Oidium albicans*, *Diplococcus pneumoniae*, *Gonococcus*, *Bacterium coli commune*, of tuberculosis and influenza, and of typhoid, cerebrospinal, and other infectious fevers. The introduction of the organism by traumatism should always be most carefully searched for, while extension of the disease from the middle ear or mastoid cells and cranial bones, or septic emboli from distant foci,—*e.g.*, abscess of the liver, ulcerative endocarditis, putrid bronchitis, localized bone-disease, etc.—must be borne in mind. *Classification*.—(a) Primary (rare) or secondary (common). (b) Single (from extension) or multiple (metastatic). (c) Large (size of a walnut or an orange) or minute (then usually multiple). *Seats*.—(a) Cerebrum, usually in the temporosphenoidal lobe (most common). (b) Cerebellum, especially in middle-ear disease. (1) Acute abscesses, usually about blood-vessels; are minute, with no definite wall; contain pus mixed with reddish *débris* and softened brain matter. (2) Chronic abscesses may be superficial or

deep; have a pyogenic membrane, which develops in from three to five weeks; pus often has a greenish tint and an acid reaction, and may have a peculiar odor depending on micro-organisms. (V) *Acute Cerebrospinal Meningitis (Spotted Fever)*, see p. 310. (VI) In *Acute Myelitis* the cord is swollen and soft and the pia injected. On incision a diffuent fluid may escape. The distinction between gray and white matter is often lost. Hemorrhages are frequent. Histologically, the nerve-fibres are swollen, the axis-cylinders beaded, myelin droplets abundant, and corpora amylacea may be seen. The ganglion-cells are swollen, irregular in outline, and exceedingly granular and vacuolated. In the removal of the cord in these cases great care must be taken not to produce artefacts.

INSANITY.—See such works as those of Church and Peterson (1905); Bianchi and Macdonald (1906); and Kraepelin and Johnstone (1906).

LOCOMOTOR ATAXIA.—See ATAXIA, LOCOMOTOR.

NEURITIS may be localized to one nerve or be general, and is caused by: (1) Injury; (2) Exposure; (3) Poisons, as lead, mercury, phosphorus, arsenic, alcohol, coal gas, carbon disulphid, ether anaesthesia, etc.; (4) Infections, such as diphtheritic, puerperal, septicaemic, influenzal, gonorrhœal, typhoid, malarial, beriberic, etc. Transverse white lines on the finger-nails are said by Aldrich to be an important sign of acute arsenical neuritis. Landrey's paralysis is really a form of infectious neuritis. All or any of the component parts of the nerve may be involved, and the neuritis be of the perineural, interstitial, or parenchymatous type. The medullary substance, axis-cylinders, and myelin may be affected. The nerve shows the cardinal symptoms of inflammation, the infiltration, redness, and swelling being capable of demonstration *post mortem*. The study of nerve regeneration has recently thrown some light upon the changes found in neuritis. The cortical centres, nuclei, trunks, and peripheral portions of the cranial nerves should be studied. Thus, when there has been paralysis of the vocal cords, the vagus and the bulbar portion of the accessory nerve should be investigated.

PACHYMENINGITIS. — See INFLAMMATION and VASCULAR CHANGES.

PARALYSIS AGITANS (PARKINSON'S DISEASE).—It is suggested by Berkeley¹ that this disease is due to a disease of the parathyroids.

¹ *Med. News*, December 2, 1905.

POLIOMYELITIS, CHRONIC ANTERIOR.—Slow degeneration of cells in the anterior horns and sometimes in the nuclei of the motor cranial nerves gives rise to bulbar symptoms. The degeneration begins generally in the lower cervical and upper dorsal nerves, with increased neuroglia. The muscles innervated by these nerves atrophy. There is a slight degeneration of the pyramidal tracts towards the brain or perhaps from cortical cells downwards. This condition is termed amyotrophic lateral sclerosis. In chronic anterior poliomyelitis there may be degeneration of the ganglionic cells of the anterior horns only or of the upper motor neuron as well, when the symptoms become identical with the disease known as progressive muscular atrophy. The latter disease, where the degeneration affects chiefly the lower neurons, is more common than amyotrophic lateral sclerosis, in which both neurons are attacked. Both occur the more frequently in males and between the ages of thirty and fifty. Lead poisoning is a certain cause. Exposure, infectious diseases, rheumatism, and syphilis are assigned causes. For acute anterior poliomyelitis, see **INFANTILE PARALYSIS**, p. 262.

RAYNAUD'S DISEASE.—A form of vasomotor neurosis causing local syncope, cyanosis, and symmetrical gangrene, affecting especially the fingers and toes, caused by spasm and constriction of the small blood-vessels.

SCLEROSIS.—In sclerosis of the brain and cord the connective tissue and neuroglia are either affected singly or conjointly. Osler considers the degenerative, inflammatory, and developmental forms, and makes anatomically the following varieties: miliary, diffuse, tuberous, and multiple (insular; disseminated) sclerosis. In the latter form, *Sclérose en plaques*, small, usually sharply defined, sclerotic areas, of a steel-gray color, are widely distributed throughout the brain and cord, being especially abundant about the ventricles, the central canal, and the basal ganglia. Microscopically there is a marked increase of neuroglia, the medulla of the nerves is destroyed, and the axis-cylinders persist. Cholesterin crystals and other forms of degenerative changes are seen. In *Primary Lateral Sclerosis* (spastic paralysis of adults) there is a systemic degeneration of the pyramidal tract. For *Posterior Spinal Sclerosis*, see **ATAXIA, LOCOMOTOR**, p. 258. There is an interesting form of posterior sclerosis caused by ergot. Putnam has described a primary combined form of sclerosis. The posterior columns are first and most involved. The lateral columns, the crossed pyramidal

tracts, particularly, are also affected. Other columns may be involved. The anterior horns may be diseased, and softening of the cord, with cavity production, may occur.

SPASTIC PARALYSIS.—(I) *Of Adults*.—There is a systemic degeneration of the pyramidal tracts, but without muscular atrophy or sensory disturbance. (II) *Of Children (Little's Disease; Spastic Diplegia; Birth Palsies)*.—Here the condition is usually due to a meningeal hemorrhage of the brain induced at the time of labor, though Marie suggests as its etiology the maldevelopment of the pyramidal tracts. Hemiplegia in children is especially due to sclerosis, porencephalus, atrophy, embolism, thrombosis, and hemorrhage. In atrophy and sclerosis a group of convolutions, an entire lobe, or even a whole hemisphere may be involved. The affected gyri are firm, hard, and atrophied, contrasting sharply with the normal tissue. They may be uniform in appearance or there may be nodular projections. In porencephalon there is loss of substance, with the formation of cavities or cysts at the surface of the brain.

SYRINGOMYELIA.—Syringomyelia is a chronic affection of the spinal cord characterized by the pathologic formation of cavities in its gray matter. The cavity formation is secondary. Causes: (a) Embryologic malformations; then often associated with spina bifida and hydrocephalus and properly called hydromyelia. (b) A gliosis. (c) Traumatism. (d) Development of embryonal neuroglial tissue in which hemorrhage or degeneration takes place with the formation of cavities. (1) The central canal becomes enlarged or new cavities extend into the gray matter of the anterior, or more frequently the posterior horns. The cavity, which at times contains a bloody or gelatinous fluid, is most often situated in the cervical and thoracic portions of the cord. (2) On transverse section the cavity may be oval, circular, or narrow and fissure-like, or it may present the appearance of two or more cavities independent of each other or intercommunicating. (3) The cavity usually contains a colorless liquid, but occasionally a yellow or brown gelatinous substance, or blood and the products of its degeneration may be present. The white matter of the cord in moderate cases is unaffected, but where the cavity is large and pressure from the sclerotic tissue has become great, the white matter is in its turn involved, being crowded to the periphery and more or less unable to carry on its functions.

VON RECKLINGHAUSEN'S DISEASE.—This is a general fibrosis of the peripheral nervous system. Nuthall and Billington¹ report the necropsy of a case.

SYPHILIS OF THE BRAIN.—See p. 337.

TUBERCULOSIS OF THE BRAIN.—See p. 352.

TUMORS OF THE BRAIN AND CORD.—Tumors and cysts of the brain are of common occurrence and of the greatest variety, growing from membranes, periosteum, or bone. Tumors of the brain which grow from the bone are sarcoma, carcinoma (usually secondary), osteoma, and gumma; from the meninges are sarcoma, carcinoma, fibroma, solitary tubercle, and gumma; from the blood-vessels, gumma and aneurism; in the brain substance, glioma, sarcoma, metastatic and primary carcinoma, cysticerci, of which I have had one case² in which the clinical diagnosis of hydrophobia had been made, and echinococci. Glioma, gumma, and sarcoma are most frequent in the adult; solitary tubercle in the child. A tumor at the base of the brain is probably a gumma or sarcoma; in the brain substance, a glioma. A sarcoma grows rapidly and a glioma slowly. (Jacobs.) The remnants of the neural canal over the coccyx may give rise to a glioma, later giving metastases. (Mallory.) A fatal hemorrhage may take place suddenly into gliomatous tissue. Carcinoma of the vertebral column may give rise to the so-called paraplegia dolorosa. Carcinoma exerts a toxic influence upon the nervous system, especially when of the ulcerative type. Acervuloma, endothelioma, cholesteatoma, and cerebroma, a heterotopic tumor in which a portion of the gray matter embryologically becomes occluded on the white substance of the brain, also occur.

VASCULAR CHANGES.—The effects of the blood upon the brain and cord, whether normal, but in increased or deficient quantities and pressure, or abnormal, is most varied. Bier's treatment of certain affections by passive hyperæmia and one of the theories explaining sleep, are examples of the importance of this line of study upon normal physiology and therapeutics. Again, Meyer³ considers that a narcotic acts upon the lecithin—a fat-like substance—contained in the brain-cells of the sensory portion of the cerebrum, as his experiences have shown that the narcotic effect of an anæsthetic is as the quotient of its power of dissolving fats divided by its own solubility in water.

¹ *Lancet*, December 27, 1902, p. 1751.

² *Phila. Med. Jr.*, 1899, vol. iii, p. 111.

³ *Med. Notes and Queries*, December, 1905, p. 164.

(I) *Hyperæmia of the Brain*, when *active*, shows a congested cerebrum, distended blood-vessels, and petechial hemorrhages. On section the gray substance contrasts very markedly with the white. In *passive* congestion the veins of the cortex are distended; the gray matter has a deeper color and its vessels are full. The gray matter shows distention of the smaller veins, which on section allow their contents to exude as drops of blood of various sizes. Excessive passive hyperæmia may result in cerebral œdema. (II) When the brain or cord is temporarily or permanently deprived of part of its blood-supply, a condition of *anæmia* exists, which may be due to: (a) Mechanical obstruction to the circulation,—*e.g.*, valvular heart-lesions, thrombosis, embolism, or ligation of a vessel. (b) Hemorrhage. *Classification.*—(a) General or local. (b) Acute, subacute, or chronic. (c) Partial or complete. The membranes are pale; small arteries over the gyri are empty, though large veins are full. The brain substance is anæmic, the surface moist, few puncta vasculosa are seen, and the cerebrospinal fluid is increased. (III) *Aneurism of Cerebral Arteries.*—*Classification.*—(a) Single or multiple. (b) Large or minute. *Seats.*—(a) Most frequent in branches of the middle cerebral artery, especially those of anterior perforated spaces. (b) May be cortical. The aneurisms are usually very small, varying in size from that of a pea to a cherry-stone (seldom larger), multiple, and may resemble bunches of grapes. If hemorrhage occurs in basal aneurisms, the internal capsule and basal ganglia are injured, the lesion usually being extensive. On the cortex the result of hemorrhage is much less grave. The fatty degeneration of the media is the first change in the vessel. The importance of arteriosclerosis is doubtful. They have been regarded as herniæ of the intima. (IV) In *Cerebral Hemorrhage* the most common artery to rupture is the lenticulostriate (60 per cent.). The amount of blood poured out will depend upon the calibre of the vessel ruptured and upon the blood pressure. The bulging of the hemisphere containing the hemorrhage and the flattening of the convolution often makes the diagnosis easy. Cerebral softening or encephalomalacia is due to the shutting off of the blood-supply to the affected area. Early the area is whitish; subsequently upon the return of the blood the condition of red softening is produced. *Classification.*—(a) Basilar. (b) Cortical. In basilar hemorrhage section of the brain substance frequently shows miliary aneurisms, which are seen as small dark bodies along the course of the blood-vessels pene-

trating the anterior perforated spaces. Aneurism of a branch of the circle of Willis may be found. Endarteritis and periarteritis are found in the cerebral vessels.* At the seat of a recent hemorrhage the brain has a dark-red, softened appearance, the tissue being reduced to a coagulated or pulpy mass of detritus. The blood may later on be absorbed, leaving a cyst or pigmented scar. In the cyst may be found hæmatoidin or hæmatin. Secondary softening may cause systemic diseases. When the hemorrhage has been extensive, the remainder of the brain is anæmic. The gyri are more or less flattened, from extravasated blood, and the sulci are indistinct. Hemorrhages are most common near the corpus striatum towards the outer section of the lenticular nucleus. They may be small and limited to the lenticular body and internal capsule or may break into the lateral ventricle. Ventricular hemorrhage is rare. It is usually bilateral. Meningeal hemorrhage is usually caused by fracture of the skull or rupture of a blood-vessel. The hemorrhage may be small or large. It may be above or below the dura or between the pia and the arachnoid. In internal hemorrhagic pachymeningitis the condition is a chronic one, successive organized layers of blood from small hemorrhages and fibrin being deposited on the inner surface of the dura. I have found them especially in alcoholics. The hemorrhage may be primary into the fourth ventricle. For a discussion as to whether or not a hemorrhage of the brain is due to violence or disease, see p. 452. (V) *Hemorrhage into the Spinal Membranes.*—Extrameningeal hemorrhage may be extensive without compression of the cord. Rupture of an aneurism into the spinal canal may produce profuse and rapidly fatal loss of blood. There may be little demonstrable morbid change. Intrameningeal hemorrhage usually occurs in scattered areas as the result of acute infectious fevers. More extensive hemorrhages result from epilepsy, tetanus, and strychnine poisoning. Occasionally hemorrhage into the spinal meninges may ascend to the brain. The blood may be absorbed from a cyst, leaving a pigmented scar.

CHAPTER XVI

EXAMINATION OF THE NASOPHARYNX, EYES, AND EARS

EXAMINATION OF THE NASOPHARYNX.

IN order to expose to view the upper air-passages, nasal, pharyngeal, laryngeal, and accessory cavities, epiglottis, etc., Harke's¹ method has come into general use. If the procedure is properly carried out, the parts when returned to their normal position present no noticeable deformity, though during the examination such a result would seem almost impossible.

HARKE'S METHOD.—The brain having been removed and the examination of the skull completed, the anterior skin flap is dissected away from the frontal bone down to the root of the nose, while the posterior flap is dissected away some distance below the foramen magnum. It is not necessary that the primary incision of the scalp behind the ears be made lower than the mastoid process on each side. Next, directly in the median line, the skull is cleft with a small saw into two lateral portions. For the sake of convenience the saw markings may be divided into two sets (Fig. 160), the first starting from the front in the frontal bone, extending down to the nasal bone, and continuing to the foramen magnum (*AB*), and the other starting at the occipital bone and extending to the foramen magnum (*CD*). The atlas and axis are sawed through if much room be desired. The sawed portions are now separated by means of a chisel and hammer, any portions of mucous membrane that may appear being severed with a knife or scissors. By means of strong lateral traction the two segments may be pulled apart, and the entire region down to the vocal cords will thus be exposed. It is usual to saw a little to one side or the other so as not to injure the nasal septum, thus entering into one or the other of the nasal chambers. The walls of the accessory cavities are readily cut away with strong scissors, and a plain view is obtained of the maxillary sinuses as well as the frontal, sphenoid, and ethmoid. Even the epiglottis and vocal cords can be examined by this method (Fig. 161). In order to view the parts better, light may be thrown in by means of a mirror. Upon the com-

¹ *Berl. klin. Wchnschr.*, 1892, no. 30, p. 742; *Virchow's Archiv*, 1891, vol. cxxv, p. 410. *Beiträge zur Pathologie und Therapie der oberen Athmungswege*, Wiesbaden, 1895.

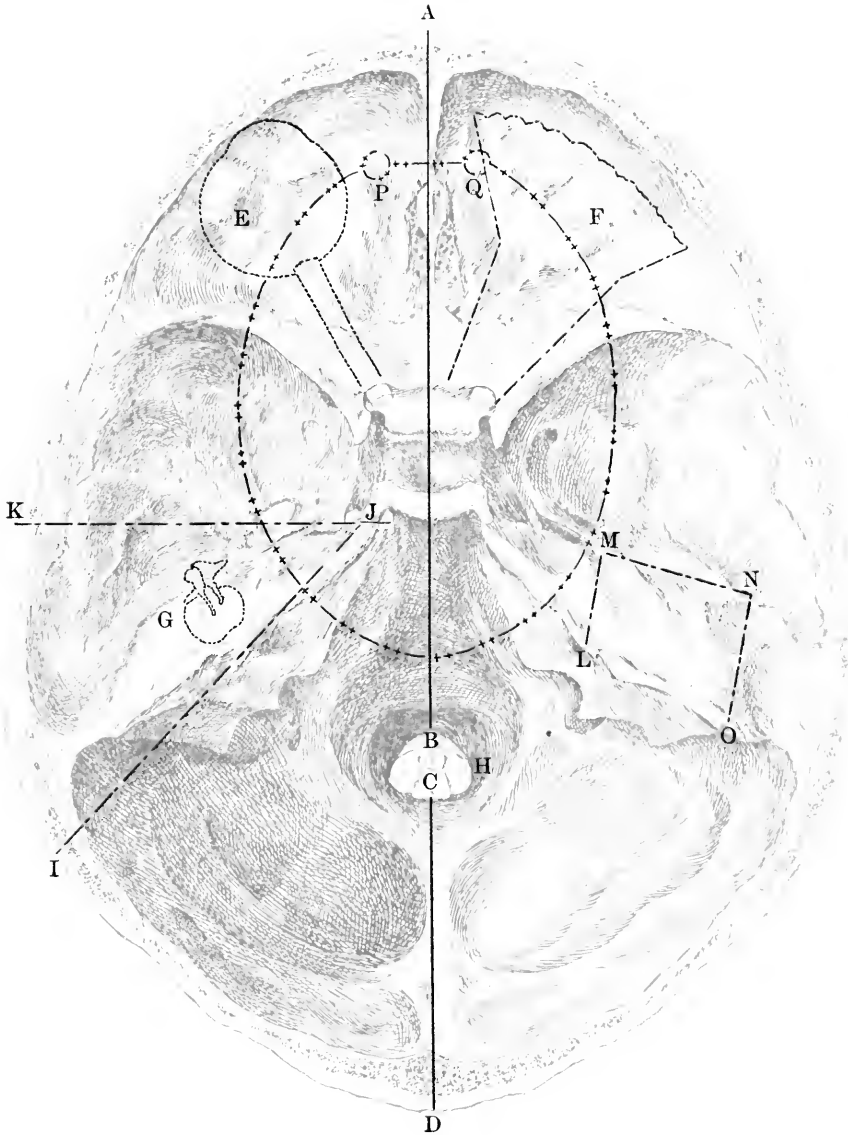


FIG. 160.—Method of examining nasopharynx, eyes, and ears. The sawing for opening the nasopharynx is done in the median line from the frontal bone, *A*, to the anterior portion of the foramen magnum, *B*, and from the occipital bone, *D*, to the posterior portion of the foramen magnum, *C*. The sawing can best be accomplished by standing on the table directly over the head, the finger-saw being especially useful at the beginning and the end of the operation. *E* and *F*, lines of incisions for the removal of the eyes; *G*, situation of the ear-ossicles; *KJI* and *LMNO*, lines for removal of the ear-ossicles; *P* and *Q*, drill-holes for saw-markings in the oval method of examining the nasopharynx.



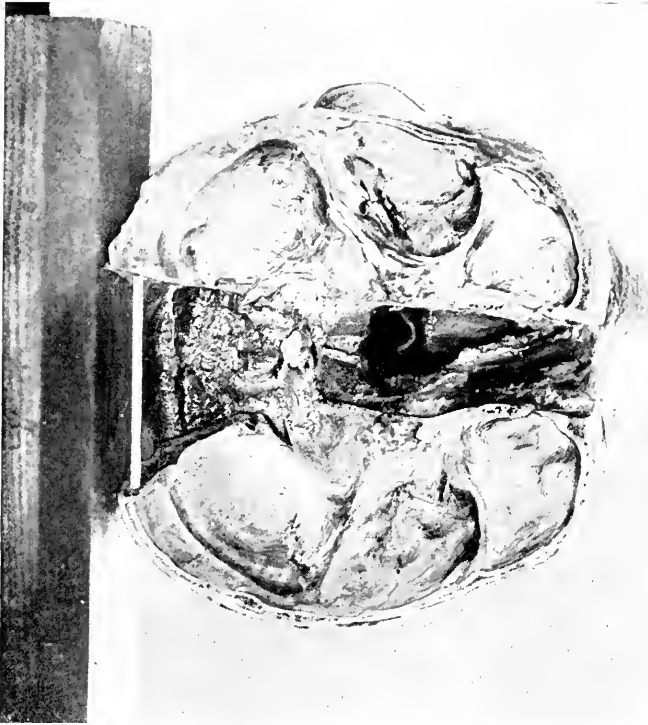


FIG. 161.—Harke's method of examining the nasopharynx. Appearance of the parts after the sawing has been completed and the lateral halves have been pried apart. The tip of the epiglottis is plainly seen in the photograph. A mirror may be used to illuminate these parts in order to bring them more perfectly into view.

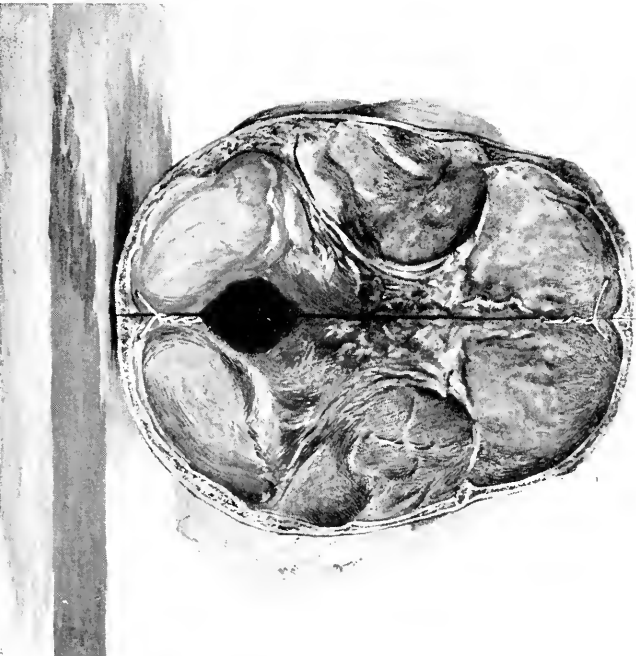


FIG. 162.—Appearance of the parts after wiring of the lateral halves in Harke's method of examining the nasopharynx. Removal of a triangular portion of the occipital bone.

pletion of the examination, the two lateral halves are brought into juxtaposition and wired, as will be seen by reference to Fig. 162.

Another method is to drill holes just in front of the sphenoid and a little behind and to the right and left of the crista galli, and then with a saw or a chisel make an ovoid incision extending almost to the foramen magnum, and remove the portion of bone which hides the nasopharyngeal cavities. (Fig. 160, *P Q*.) Nasal obstruction may cause deformities of the upper jaw, teeth, and palate.¹

EXAMINATION OF THE EYES.

For this purpose a triangular piece of the orbital plate of the frontal bone is broken through with a hammer or chisel, care being taken not to injure the optic nerve in the optic foramen, the remaining portion of the eye and the nerve being well protected. (Fig. 160, *E* and *F*.) The direction of the nerve can be determined by observing the situation of its exposed portion, and the chiselling done a small distance on either side of its normal position. The pieces of bone are removed with the nippers and the optic nerve is carefully dissected out, its cut end being held with the fingers or forceps. The capsule of Tenon and the fat are removed, and the entire eye is excised or, if this is not permitted, an incision is made in the sclerotica posterior to the conjunctival attachment. This requires a very sharp knife, as the tissue is extremely tough. A circular incision is made around the entire eye, and the fundus is exposed. A piece of dark cloth or cotton dipped in ink is placed in the remaining portion of the eye in order to hide any disfigurement, and the cavity is packed with cotton. In those cases where permission is given to remove the eyes, this is done as in enucleation.

If only a macroscopic examination of the retina and other structures is desired, the retina may be floated out in normal salt solution and then separated from the choroid. If the retina is to be fixed for microscopic examination, the incision should be as nearly equatorial as possible and the fundus placed immediately in Orth's or Müller's fluid or ten per cent. formalin, or fixed by exposing for three minutes to the fumes from a one per cent. osmic acid solution heated just to the boiling point. The eye is then put for twelve hours into Lindsay Johnson's mixture:

Potassium bichromate, two and one-half per cent.....	70 parts.
Osmic acid, two per cent.....	10 parts.
Platinic chlorid, one per cent.....	15 parts.
Acetic or formic acid (to be added just before using)....	5 parts.

¹ COLLIER, *Lancet*, October 18, 1902, p. 1038.

The gloss of the cornea disappears as soon as death comes on. After twenty-four or thirty hours, and often earlier, the bulbus softens and the cornea and retina become dull. The conjunctiva is now removed more easily from the cornea, and the sclera which is not covered by lids becomes brownish black and dry. (Orth.) According to Runge, several days after death a diffuse redness occurs in the transparent media of the eyes of a foetus that has died *in utero*. The redness affects first the cornea and then the lens,—extending from without inward,—in this way indicating approximately the date of death.

The position of the eye may be altered. Exophthalmos, or protrusion of the eye, may be caused by a retrobulbar tumor, œdema, hypertrophy of fat, collection of blood from hemorrhages, emphysema, inflammatory exudates, Basedow's disease, etc. Enophthalmos, or retraction of the eye, may take place in atrophy of the fat, loss of liquid, as in cholera, deformity from scars, etc. The consistency of the eye varies, being increased in glaucoma and diminished in certain forms of degeneration. Frontal empyema may occur.

EXAMINATION OF THE EARS.

A fair idea of the condition of the middle ear may be obtained simply by chipping away the roof with a chisel or snipping it off with bone-forceps, but if a closer inspection is desired the petrous portion of the temporal bone and the mastoid process had better be removed together.

Extend the incision from its original point back of the ear and along the anterior border of the trapezius about half-way down the neck. Reflect the flaps with their soft tissues so as to leave the bone clear. Begin at the apex of the petrous portion of the temporal bone and with a chisel laid flat break through the petrobasilar suture to the jugular foramen, and chisel or saw through the skull on a line from the jugular process of the occipital to a point about five centimetres posterior to the base of the mastoid process. Anteriorly chisel or saw through the skull on a line from the apex passing posterior to the spinous process of the sphenoid; or between the foramen ovale and the foramen spinosum and well anterior to the external meatus, just cutting off the root of the zygoma.

Woodhead¹ uses the following method:

“The temporal bone, with its petrous portion containing the internal ear, may be taken out and examined after removal of the brain,

¹ *Practical Pathology*, 1892, p. 28.

by stripping off the dura mater from the base, dissecting off the skin and muscle, detaching the external ear from the bone, and disarticulating the jaw; then, taking the margins of the temporal bone as the base of a pyramid, the apex of which is a little beyond the inner extremity of the petrous portion, two saw-cuts are carried almost vertically downwards so as to bound the pyramid, and then with a bone-chisel and mallet the whole temporal bone may be removed, after which it may be softened in a decalcifying fluid; or the internal ear may be dissected out with a small saw, a pair of sharp, well-fitting bone-forceps, and a sharp gouge and chisel. The internal ear or tympanic cavity and mastoid cells may also be opened up with the aid of the above instruments."

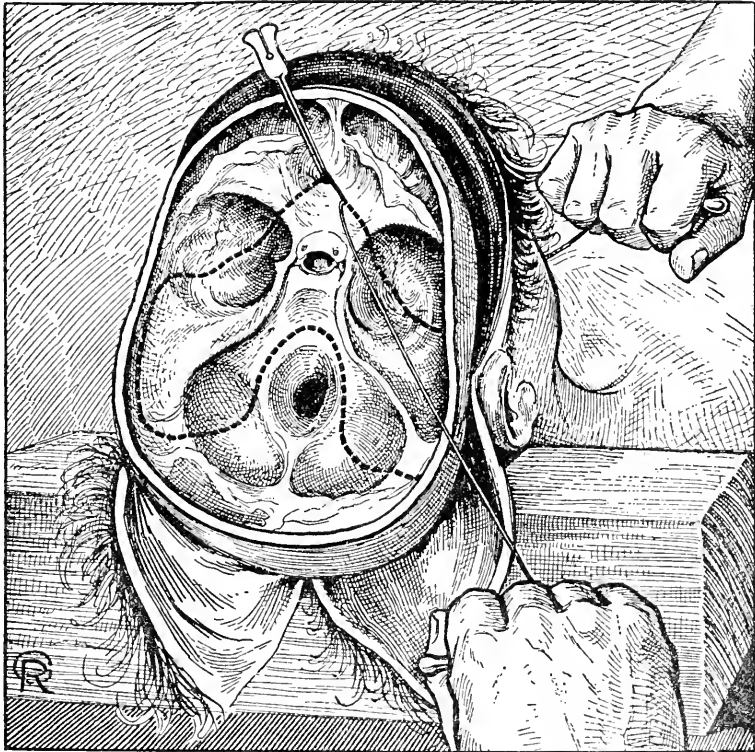

FIG. 163.—Wire-saw used in removing the auditory apparatus, the lower jaw having first been removed. (After Letulle.)

By sawing or chiselling as in Fig. 160, *K J I* or *L M N O*, the ear-ossicles and internal ear may readily be reached. The method of using the wire-saw is seen by referring to Fig. 163. In this illustration is also shown what is known as the T incision, which consists in

making a second incision at right angles to the one across the vertex of the skull, thus passing through the occipital protuberance. Or it may be considered as a continuation of the median incision of the back in the removal of the spinal cord to the incision going across the skull. The flaps thus produced are then dissected away from the underlying part, and salivary glands, exocranial sinus, mastoid process, articulation of the jaw, intercarotid bodies, etc., examined with ease. A study of fifty-four mixed tumors of the salivary glands has recently been made by Wood.¹ The parotid gland may be the seat of primary tuberculosis. Salivary calculi are sometimes found. Robery, in a paper read in 1904 before the *Chicago Medical Society*, gives an excellent bibliography of this subject. Tumefaction of the parotid gland, with or without suppuration, cœliac or splanchnic (Sclocum) parotitis, may occur subsequently to an abdominal or pelvic operation.

¹*Ann. Surg.*, 1904, January, p. 57, and February, p. 207.

CHAPTER XVII

BONES AND JOINTS¹

A COMPLETE autopsy ends with a careful inspection of such portions of the osseous system as may need to be investigated and have not come under observation in those parts of the body already studied. Unfortunately, a thorough examination of the bones and joints cannot always be attempted on account of the unavoidable disfigurement it entails. However, by ingenuity in technic and skill in restoration of the body even the removal of large portions of the skeleton may be successfully concealed. The X-rays have done much in recent years to facilitate the study of both normal and abnormal osseous structures, and may often be employed to great advantage at the post-mortem, as in showing the exact location of a bullet. The time required for exposing the photographic plate to the Röntgen rays seems to be longer than in the examination of the living subject.

ARTHRITIS.—Inflammation in a joint begins either in the synovial membrane or in the bone, and affects all the structures of the joint (panarthrititis) and, often secondarily, surrounding parts (periarthrititis). It may arise from trauma, infection, as a sequel of pyæmia, erysipelas, gout, gonorrhœa, tuberculosis, syphilis, scarlatina, dysentery, typhoid fever, pneumonia, or measles, or as secondary to bone disease. It may be gouty, purulent, ulcerative, ankylosing, infective, syphilitic, tuberculous, etc. Lipomatous, fibrous, and cartilaginous growths may occur in a joint. Rice-bodies probably arise from hyaline portions of the synovial membrane.

Acute arthritis consists in inflammation of the synovial membranes and fringes, at times with hemorrhagic extravasations, and distention of the capsule by effusion, in which float flakes of fibrin. The soft parts around the joint are swollen. The serous and serofibrinous forms usually terminate in resolution, without marked changes. The fibrinous form frequently results in the formation of more or less extensive adhesions. Empyema of a joint, arthropyosis, being generally associated with osteomyelitis due to metastasis from other foci, occurs usually in the knee, involving later many other joints. The synovial

¹ Based on the text-books of Ziegler and Green.

membrane and the articular ligaments become dark red in color, swollen and infiltrated, and covered with pus; later the cartilage and lastly the bone (molecular necrosis) are attacked, often causing disarticulation of the ends of the bones. Perforation may be primary or secondary. A purulent effusion, remaining a long time without serious destruction, is called catarrhal synovitis.

Chronic Inflammations.—Chronic articular dropsy (hydrarthrosis) is a serous or serofibrinous inflammation, usually seen in the knee, wrist, or elbow. The synovial membrane is thickened, indurated, and may have patches of fatty degeneration. In the knee the patella may be lifted and the bursæ distended by a thick or thin or gelatinous secretion, and the synovial membrane may protrude through the fibrous bands of the capsule. The synovial tufts become large and projecting; the joint-cartilages degenerate and proliferate. Adhesions or destruction of the joint may follow.

Chronic purulent arthritis is usually associated with tuberculosis or is due to extension from adjoining parts. The capsular ligaments and synovial membranes are infiltrated and covered with fibropurulent deposits; the cartilages are cloudy, fibrillated, or necrotic, the marrow suppurating, and the joint filled with pus or numerous abscesses forming around the joint. Ankylosis or dense, fibrous adhesions are found in cured cases.

Chronic, dry, ulcerative arthritis occurs in old age, accompanying neuropathic disorders, or as a sequel to rheumatism. It consists in a proliferation of the synovial membrane, forming fringes, and in sclerotic thickening of capsule and ligaments. Fibrillation and cleavage of the cartilages, with patches of calcareous, amyloid, or fibroid degeneration, may occur. The denuded bone of the articulating surfaces may ulcerate or become sclerotic and waste, the capsule becoming so large that dislocations may occur. In the senile form the hip is usually affected, but the shoulder, elbow, phalangeal joints, and the patella of the knee may be involved. In tabes dislocations are very common in knee, shoulder, and elbow.

Arthritis deformans, chronic gout, or rheumatoid arthritis, is a chronic disease of the joints, characterized by degenerative changes in the cartilages and synovial membranes, by periarticular formation of bone, and by great deformity (Osler). It is often associated with infectious diseases, as gonorrhœa, gout, and rheumatism. In all forms the articular surfaces are hyperplastic and softened. Later, absorption

takes place, the ends of the bones becoming eburnated and polished; the head of the femur has entirely disappeared; generally it becomes conical, flat, or broad. The bone marrow liquefies, forming cysts; subchondral cysts and deep-seated bone cavities occur. At the edges, where the friction is less, irregular nodules (osteophytes) develop and calcify. Capsules, synovial membranes, fringes, and ligaments thicken and become infiltrated with lime salts. There is always a complete absence of uric acid. Great deformity, not infrequently ankylosis and dislocation, occurs. There is often marked atrophy of both bones and muscles. Arborescent lipomata are found. The smaller joints of the hands and feet are usually first affected, the fingers being deflected to the ulnar side. In severe cases all the joints may be more or less involved. In old people the disease is apt to attack the hip, knee, shoulder, or spine. *Spondylitis deformans* is due to the formation of osseous bridges between the vertebræ. Heberden's nodosities, a form of the disease, consist of small nodes or tubercles about the dorsum of the phalanges; this form very rarely affects large joints, as the knee.

Gouty arthritis is the deposition of urates in the articular structures, usually in the metatarsophalangeal joint of the great toe (podagra) or a finger-joint (cheiragra). The periosteum, tendons, ligaments, and skin are more or less inflamed. The joint contains a clear fluid, with crystals of sodium urate, sodium chlorid, calcium carbonate, and calcium phosphate; hippuric acid and other uric-acid compounds. Chalky, mortar-like, nodular masses, tophi, are found in the matrix of cartilage and ligaments. In old cases these are also found in the bone, periosteum, tendons, and bursæ. Fibrillation and erosion of the cartilages cause abscess-like cavities, which may open externally.

Gonorrhæal arthritis occurs in one knee-joint, between the third and the sixth week of the disease. It has also been seen in an ankle and hip. There is a fibrous metaplasia, also a fibrous or osseous ankylosis. Ulceration of the cartilage, bone, and capsular tissue may occur, as a rule, with a purulent effusion.

Rheumatic arthritis occurs in several joints at one time, generally in the hip, shoulder, and jaw. It begins as a hyperæmia of the synovial membranes, with an increase of fluid, followed by thickening and elongation of the ligaments and later by absorption or ossification of the interarticular cartilages, which become rough, fibrillated, and often converted into a tough, felted mass. Finally, there are induration and eburnation of the bony extremities. It may involve joints in succes-

sion, and, in rare cases, all the joints. It always causes ankylosis, by fibrous adhesions of the ligaments and bony deposits in and around the joint.

Chronic ankylosing arthritis is the most common anatomic feature of chronic rheumatism, and is due to a vascularization and fibrous metamorphosis of the articular cartilages, with coherence of the opposed cartilages.

Spinal or neurogenous arthritis, usually associated with tabes dorsalis, syringomyelia, degeneration of the anterior horns of the gray matter, arising from section of spinal nerves, consists in a rapid destruction of the articular ends of bones, thickening and ulcerative destruction of synovial membranes and ligaments, and a serous effusion into the joint, with swelling of the surrounding tissue and spontaneous dislocation.

Syphilitic and tuberculous arthritis are described elsewhere. I have had one case of *pneumococcal arthritis* of the knee, with streaky hyperæmia of the skin, boggy swelling, purulent infiltration, and hemorrhagic effusion. *Toxic arthritis*, due to alcohol, occurs, usually in small joints, and always associated with enlarged liver, spleen, and lymphatic glands. (Quinquaud's sign.)

Degenerations generally occur in the cartilage of a joint. After hemorrhage into a joint, hæmatoidin is often found as crystalline and amorphous masses in the superficial cells. Ochronosis produces diffuse brown patches in cartilages, due to saturation of the matrix with some unknown coloring matter. Mucoïd degeneration of the matrix produces a turbid fibrillar appearance, which may go on to complete disintegration, and is often associated with fatty change in the cells. Fatty degeneration, a translucent gray material, appears, in senile softening, associated with calcification; and in chronic inflammatory disease. It attacks mainly the costal cartilages, but may occur in margins of the articular cartilages, and in places where the matrix is already in a process of fibrillation and degeneration. Hyaline and amyloid degenerations occur in the capsules and cartilage-cells. Amyloid degeneration may also affect the matrix.

ΑΤΡΟΦΗ.—Acquired or true atrophy is: (1) eccentric, the bone being normal in size, but on section showing great increase in the cavities and in the amount of the cancellous tissue, and decrease in the compact tissue; (2) concentric, the bone being slender and the external compact tissue showing local defects (osteoporosis), or being exces-

sively thin and brittle (osteopsathyrosis, fragilitas ossium). The medullary canal is always contracted.

Atrophy may follow trauma, such as fracture, luxation, or epiphyseal injury, and disuse, as seen in old stumps and unset fractures. Pressure often thins the bones markedly. In hydrocephalus the internal surface of the skull may be rough, or the inner table may be entirely absorbed. The Pacchionian bodies often make deep pits in the temporal bones. The vertebra, sternum, and other bones may be found deeply eroded and perforated by aneurisms and tumors; even scars may cause atrophy of the bone upon which they make pressure. Tumors of the marrow, periostitis, and osteomyelitis also cause atrophy of the bone by their pressure. A peculiar type of atrophy is seen in the aged, affecting those bones with only a slight muscular covering, as parietal, maxillary, and pelvic bones. The external table of the skull may be entirely resorbed. Perforation of the entire thickness has occurred, bony deposits being often found at the same time on the inner table. The bone is rough, dull, and lustreless, with shallow erosions, not uniform in shape or position. Nervous diseases (neuropathic and neuroparalytic), infantile paralysis, inflammation, rickets, and many other pathologic conditions are often associated with osseous atrophy.

CHONDRITIS.—This affection is often a sequela of severe arthritis; it usually occurs in articular cartilages, which become turbid and disintegrate. Erosions, caries, and more or less extensive necrosis are not uncommon. Hypertrophic proliferation, general or local, may occur with any productive inflammation of the cartilage or fibrous tissue of a joint. It is common in arthritis deformans and tuberculous arthritis. In cartilage it is nodose or tuberculous, while in the capsule or synovial membrane it appears as a diffuse thickening or as a papillary excrescence. Loose bodies, usually found in the knee, elbow, and wrist, rarely in the hip, shoulder, elbow, or ankle, may be single or numerous, a knee with 1047 of these bodies having been reported. These may be entirely free or attached by a slender stalk. They may be composed of fibrin, the remains of hemorrhage into the joint, or may be a proliferation of the synovial or fatty tufts, pieces of bone or cartilage detached by violence, foreign bodies which have penetrated the bone, loosened nodular masses, cartilaginous, osteomatous, fibrous, lipomatous, or lipoma-arborescent, or displaced semilunar cartilages. Bodies, often faceted, are usually oval, lenticular, or devious in outline.

They are associated with arthritis deformans and rheumatoid arthritis, and in many cases appear without signs of previous inflammation.

Dislocations of the semilunar cartilages are due generally to separation of the anterior attachment of the cartilage from the tibia, which may be torn transversely through the edge of the meniscus or split longitudinally. A central tear has also been described. Cartilages, infrapatellar pad, and ligamentum alare are usually thickened. The displacement is inward, towards the centre of the joint, so that the leg cannot be extended.

FRACTURES AND DISLOCATIONS.—Fractures, the most common injuries to bones, are either complete or incomplete. A certain amount of repair callus will be found in all cases. Contiguous bones, as tibia and fibula, may coalesce during repair and lead to a synostosis. In cases with great displacement, with soft parts between the fragments, with existing debility or other unfavorable conditions, there may be no union, or simply a firm, fibrous adhesion (syndesmosis), or a false joint (pseudarthrosis). Compound fractures, affording a favorable opportunity for the introduction of pyogenic organisms, are often associated with caries, necrosis, or osteomyelitis.

Diastasis, a pathologic separation of the epiphysis from the diaphysis, occurs usually as a sequela of accident or ulceration, the epiphysis being pushed off by the resulting granulations. It is most common in the upper part of the femur, in the lower portion of the humerus, and in the tibia. In rare cases the dislocation may take place between the manubrium and the gladiolus, or the head of the femur may be found loose in the acetabulum.

Congenital dislocation of hip, single or double, is associated with softening of ligaments, effusion, fungous synovitis, hydrarthrosis, caries, arthritis, and arrest of development. The acetabulum is narrowed, elongated, less concave than normal, and occasionally filled with fat, connective tissue, or exostoses. The head of the femur is flattened, but larger than the acetabulum; it lies on the dorsum of the ilium or obturator foramen; the neck may be wanting; or it may be atrophied. If the patient has walked, there is usually a depression of the ilium and some lordosis. The gluteal muscles are contracted, the unused muscles atrophied, and the pelvis is contracted above and expanded below. Congenital luxation of the sternum has been reported. If acquired dislocations with rupture of the capsule, tendons, ligaments, muscles, and other structures around the joint be not reduced, the

muscles and ligaments may atrophy, the synovial fluid be destroyed, and the bone be partially absorbed, or the bones may unite by firm, fibrous, cartilaginous, or bony adhesions (ankylosis). This may also follow non-use of a part, articular disease, trauma, phlegmonous erysipelas, burns, or as a sequela of tuberculous, gonorrhœal, gouty, rheumatic, syphilitic, neurotic, or puerperal affections. A form of ankylosis of the spine is sometimes seen in typhoid fever. Congenital ankylosis of the entire skeleton has occurred. False ankylosis is due to bands of cicatricial tissue, adhesions of the ligaments and capsule, or organization of inflammatory deposits.

INJURIES.—Cuts, gunshot wounds, and stabs may result in acute inflammation, effusion of blood, empyema, ulceration of articular capsule, necrosis of cartilage and bone, or a more or less complete disorganization of the entire joint. Septicæmia and pyæmia may supervene. Crushing injuries to joints almost always end in abscess, usually associated with bony or cartilaginous fragments, which remain as foreign bodies in the joint.

MARROW.—The marrow in children is soft, bright red in color, and rich in cells and blood-vessels. In middle life there is an increase in fatty tissue, giving a yellow or yellow-red color of oily lustre, while in old age it atrophies, becoming gelatinous, with clear, mucinous fluid, and there is a diminution of fat and a decrease in the number of cells present. This atrophy may follow chronic emphysema, phthisis, chronic disease of the kidney, or starvation. Lymphoid marrow is gray red or dark red, according to the amount of blood it contains. In pernicious anæmia the marrow of the long bones resembles raspberry jelly, while in leukæmia it has a flesh-pink to a gray-yellow color, like that of pus. Fatty degeneration occurs in the cells and capillaries of the marrow, sometimes with necrotic foci, in cases of typhoid, typhus, and relapsing fever.

In osteomyelitis there is often a purulent inflammation, frequently complicated by transformation of the marrow into a vivid red, tough, fibrinous material, and with effusion into the cavity of a joint. Necrotic changes in the bone follow. Hypertrophy of the marrow-cells is seen in oligæmia, leukæmia, chronic pulmonary tuberculosis, chronic suppurative osteitis, cancerous cachexia, typhoid fever, croupous pneumonia, septic affections, acute endocarditis, and smallpox; while hypertrophy of the fatty tissue occurs in cases of general atrophy of the skeleton, sometimes involving the entire bone.

NECROSIS.—Necrosis arises as the result of shutting off of the blood-supply. It follows infective embolus, injury, poisoning, as from phosphorus, and as a sequela of scrofula and the infective fevers. Caries, necrosis superficialis, or erosion is, as a rule, circumscribed, but may be diffuse or phagedenic. It occurs in the cancellous extremities of a bone, usually in the tibia, femur, humerus, phalanges, skull, lower jaw, clavicle, and ulna, and affects the joints secondarily. It is always associated with periostitis, osteitis, or osteomyelitis. It is generally dry and anæmic, but in cases of sudden onset may be moist. The bone is ulcerated or worm-eaten in appearance, with numerous hollows or cavities. It is porous, very fragile, and of a dirty-yellow, dark-gray, or brown color. The surrounding bone is usually indurated and hard, except in strumous cases, where it is converted into a mass of fungous granulations. The compact substance is softer and the marrow splenified. Dead bone may be thrown off as an exfoliation or as a sequestrum. Panaricium, or felon, is one of the most common forms of periosteal necrosis, the digital skin having been injured or infected. Diffuse necrosis, necrosis centralis, usually attacks the shaft. There may be caries of the superficial bone with a narrow channel leading down to a focus, or an abscess in the centre (chronic sinuous abscess), or it may be entirely internal. Abscesses are most common in the articular extremities, but may occur anywhere. Swelling of the skin and periosteum always accompanies necrosis. The periosteum may retain its vitality, producing a sheath of new bone around the sequestrum, the involucrum, through which holes (cloacæ) form for the discharge of dead bone or pus; or the sequestrum may be surrounded by old bone or by exudate from the inflamed periosteum, the pus making its way through the thickened periosteum and discharging on the surface through several fistulæ or sinuses. Phosphorus necrosis, a purulent periostitis, attacks especially the jaw-bone, rarely the other bones of the face. At first there is a slight periosteal inflammation, then proliferation with formation of new bone, the maxilla becoming thick and sclerotic; later, suppuration leads to necrosis and exfoliation, at times destroying the entire bone. The infective granulomata, tuberculosis, syphilis, leprosy, glanders, and actinomyces, produce chronic inflammations with deposition of osteophytes. The resulting necrosis is described under these diseases.

ORTHOPÆDIC DEFORMITIES.—Genu valgum (knock-knee), a unilateral or bilateral displacement at the knee-joint, occurs in cases of

rickets or in men who have lived laborious lives. The external articular surface of the tibia or femur is retarded in its growth or depressed, so that these bones form with each other an obtuse angle. This may be associated with separation of the epiphysis, caries of the external condyle of the femur, or arthritis deformans.

Club-hand, hallux valgus, club-foot, talipes varus, talipes valgus, talipes equinus, talipes calcaneus, talipes cavus, and talipes planus are, as a rule, due to perverted development of tendons.

Contractures are associated with poliomyelitis, caries of the spine, and trauma of the cord or peripheral nerves. They are the result of fixation of a joint in a deformed position, the character depending upon the group of muscles paralyzed. Dupuytren contracture is a scar-like contraction with fingers flexed, due to trauma, rheumatism, or gout, affecting the palmar fascia. Small, hard, nodular fibromas are found along the course of the contraction. Late in the disease the skin is affected.

Spinal curvatures are associated with pleural effusion, large tumors, unilateral contraction of the thorax, cirrhosis of the lungs, oblique fixation of the pelvis, rickets, tuberculosis, weakness of the muscles, occupation, etc. According to Bradford and Lovett, scoliosis, or lateral curvature, is most common in the thoracic region, usually to the right, with compensatory curve, in the lumbar region, to the left. Kyphosis may be a rotated lateral deviation or a result of disease, as tuberculosis. It forms a posterior protrusion of the vertebral spines; if due to rotation, it is usually to the convex side. The vertebræ become wedge-shaped. Ossification of the ligaments is at times found. Lordosis is always associated as a compensatory curve. Synostosis, or ossification in a situation not normally ossified until advanced life, causes a marked deformity, especially of the pelvis, shortening in the base of the skull, craniostenosis, microcephalia, etc., and depressions of the bridge of the nose.

OSTEITIS is almost invariably associated with periostitis. It may follow trauma, such as fracture, amputation, and gunshot wounds; or infections, as pyæmia, scarlatina, measles, typhoid and relapsing fever, dysentery, smallpox, mumps, gonorrhœa, and acute articular rheumatism. Four forms of osteitis exist: (1) Rarefying (osteoporosis), a chronic form associated with wounds, syphilis, or tuberculosis, which consists in resorption of the spongy bone, with the formation of cavernous excavations. (2) Osteosclerosis, a reparative reaction, occurs in

the same diseases and consists in the eburnation of the entire bone. (3) Osteo-arthropathy (hyperplastic osteitis), associated with chronic tuberculous lung diseases, involves the terminal phalanges, which are swollen like drum-sticks, with their articular ends irregularly thickened; it is also seen in rhachitis, osteomalacia, and osteitis deformans. (4) Osteitis caseosa is always tuberculous. Purulent osteitis may follow typhoid, scarlatina, measles, and pyæmia, and is usually due to a secondary staphylococcic or streptococcic infection. It arises spontaneously in the femur and tibia; it is in almost every case associated with osteomyelitis, and at times with gangrene.

In *osteitis deformans* we have an inflammatory disease of old age, consisting in a wide-spread absorption of the bone and the deposition of new bone. It may be limited to the femur, cranial bones, or spine, or involve the greater part of the skeleton. The resorption is marked in the cancellous and cortical regions, where the osseous trabeculæ may be replaced by gelatinous or fibrous tissue. This softening allows the long bones to bend at abrupt angles and gives rise to many deformities, of which kyphosis is the most frequent. Cysts are often found. The deposition of new bone, which is especially seen in the skull, starts from the periosteum and from the marrow, causing thickenings of the bone.

OSTEOMALACIA.—Osteomalacia (*mollities ossium*) is a rare disease, occurring especially in pregnancy, and is characterized by a rapid and general resorption of the inorganic salts, advancing from the centre outward and including all except a thin layer next to the periosteum. The marrow is increased and splenified, or replaced by a dark, semifluid material. On section, the spaces contain a reddish, gelatinous mass, which later becomes yellow and fatty. Cysts containing a clear, turbid, or hemorrhagic fluid have been seen in the interior of the bones. The bones are very light, bend and break readily, or may even be cut with a knife. Fractures are commonly multiple, occur spontaneously or from very slight injury, and tend to repair, even in the active stage of the disease, the callus, however, remaining free from bone salts. At first the disease is limited to the pelvis; later the entire skeleton may be involved. In the so-called non-puerperal form the disease starts in the spongy bones of the vertebræ and thorax, extending to the extremities and finally even to the cranium. The sacrum is pushed downward by the weight of the body and the acetabula upward and inward by the femora, producing a characteristic pelvic

deformity. The disease is associated with general cachexia and often with pneumonia.

PERIOSTITIS.—The normal periosteum presents a yellowish-gray color, while in suppuration it is distinctly yellow. It may be raised or inflamed by traumatism, perforation of compound fracture, abscesses, tumors, infectious granulomata, or extension of inflammation from neighboring structures. Blood under the periosteum, particularly near the epiphysis, is seen in children with Barlow's disease. Simple acute inflammation, usually local, produces a reddening, a thickening, and a greater adherence of the periosteum to the bone. Suppurative periostitis, generally associated with osteomyelitis, affects growing bones, and is rare after the union of the epiphyses. The exudate, or the hemorrhage beneath the periosteum, rapidly separates the membrane from the bone, causing stretching, occlusion, or thrombosis of the blood-vessels passing into the bone; hence necrosis of the superficial osseous layers results. Pyæmia and infective fat embolism may occur before the abscess is opened. A diffuse form, attacking the long bones in those presenting a strumous diathesis, often ends in a rapid suppuration.

Fibrinous, ossifying, or productive inflammation follows chronic inflammation of the joints, syphilis, rickets, and tuberculosis, and results in osteoses, or bony thickenings. The periosteum is hardened, and a projecting node is formed beneath it, which may become fibrous or calcified (periostitis ossificans). This calcification begins as a vertical process at the surface of the bone, at first distinguishable from the old tissue, but later blended with it. In syphilis the subperiosteal nodes show a marked tendency to suppurate, and in rare cases suppuration occurs, but due to other causes, producing a malignant purulent periostitis. Typhoid bacilli have been recovered from these cases. Albuminous periostitis, a mild inflammation with a ropy, albuminous exudate, is found only in the bones of the young. Tuberculous periostitis also occurs, most often in young patients, and has more or less sharply defined granulomatous foci, containing tubercles which become caseous and soften, and give rise to peripheral caries, sacculated cold abscesses, consecutive abscesses, sinuses, or fistulous tracts. The caseous nodes are surrounded by a zone of induration and granulations, which may be so luxuriant that they form mushroom-like excrescences over the external orifice of the sinus. Simultaneous with increase of the caries there are proliferation of the periosteum and the formation of con-

siderable new bone. This is usually absent in the cranial bones, where resorption alone more often occurs.

RHACHITIS.—Rhachitis, or rickets, is a constitutional disease of childhood, characterized by alterations in the conversion of cartilage into imperfect osseous structure. Congenital rickets is rare, the so-called fetal rickets being merely a disturbance of growth closely resembling myxœdema. Rhachitic changes affect both the periosteal and medullary aspects of the long bones, especially between the shaft and the epiphysis, where a soft and irregular zone of proliferation, five or ten millimetres thick, is found. The bony tissue is softer and more vascular than normal; the marrow, wider and darker in color. The periosteum strips off easily, revealing a spongy tissue which looks like decalcified bone. Large osteoid formations occur under the periosteum at the insertions of the tendons and aponeuroses. The shafts of the long bones are usually bent and shortened and the short bones flattened. The cranial bones are thin and atrophied at the sites of pressure (craniotabes); the frontal and parietal bones often have flattened swellings, and the fontanelles remain so large that the head suggests hydrocephalus. A swelling may occur around the hip, simulating coxalgia. Associated with the bone lesions are anemia, enlarged spleen, changes in the liver, muscular atrophy, and catarrhal inflammation of the mucous membranes, especially of the intestines and respiratory tract. The lungs and heart often present changes due to the deformity of the chest. Dentition is delayed. After the active stage of the disease the bones become very hard, heavy, and deformed.

TENDONS, SHEATHS, AND BURSÆ.—Acute tenosynovitis, simple or hæmatogenous, results from wounds, bruises, strains, or excessive exercise. *Gonococci*, *Pneumococci*, or pus cocci infect the tendons usually of the dorsum of the hand, producing a purulent exudate, which shows a marked tendency to burrow between the sheath and the tendon, sometimes for considerable distances. In the dry form deposits of fibrin are found upon the inner surfaces of the sheath, giving rise to a rubbing or creaking sensation. The tendon is cloudy and swollen, the intervascular substance often suppurating or necrotic. Chronic tenosynovitis is generally gouty or rheumatic or the result of healing wounds. Calcareous deposits or gouty urates are particularly common in this form, and may cause necrosis, inflammation, or the formation of new fibrous tissue. Tuberculous tenosynovitis occurs in the walls of the sheath, with exudation. In advanced stages there may be

fungous granulations on the tendon. The tubercle bacillus may be found in arborescent lipoma, a papillomatous, fatty outgrowth of the synovial lining, it being a debated question as to whether or not this organism causes the lesion. Hygroma or ganglion, due to chronic irritation, is a cystic mass which contains rice-like bodies in a serous fluid beneath the sheath of the tendon.

Acute bursitis, acute hygroma, is a fluctuating tumor with serous, serofibrinous, or purulent exudate, the result of injury or hæmatogenous infection. The walls are generally thin, but may be greatly thickened. In the chronic form, hygroma, hydrochs bursarum, or housemaid's knee, the contents, in the early stages, are mucilaginous and viscid; later, thin and limpid. Loose bodies are frequently found in these cysts. Tubercles may develop in the walls of the sac, associated with serous effusion, or the walls may become thickened and permeated by fungous granulomatous masses which may undergo caseous degeneration. A ganglion is a round, oval, or lobulate cyst, varying in size from that of a pea to a pigeon's egg, and containing a reddish-yellow, crystalline jelly or colloid material, probably the result of a recurring slight injury. It appears on the dorsal aspect of the intercarpal joints.

TUMORS, CYSTS, PARASITES, ETC.—True osseous tumors occur, which may be primary or secondary, myelogenous or periosteal. Osteoma, exostosis, osteophytes, and enostosis are found, the latter arising from the periosteum or cartilage, during the period of growth at the diaphyses of the long bones. Two kinds of *osteoma* are seen,—the cancellous, or spongy, and the compact osteoma. On the skull they are usually small, round, conical, or mushroom-shaped. *Chondromata* usually arise from congenital, malplaced islands of cartilaginous tissue, though often not until late in life, and are found especially in the hands and feet of children and young adults, sometimes producing marked and grotesque deformities. They are nodose or tuberous excrescences which, especially on the scapulæ, long bones, or ribs, reach considerable size. They may soften and form bone cysts. The myelogenous are at first covered with a shell of bone. Cartilaginous *exostoses* start from the epiphysis, as long or rounded bony projections, the apex or a greater part of their surface being covered with cartilage. These new growths undergo fatty, calcareous, and mucoid degeneration. *Lipomata* and *angiomata* are rare. *Fibromata*, nodular and highly vascular growths, occur on the facial and cranial bones and

in the buccal and nasal cavities. A more rare tumor is the encapsulated *myxoma*, which arises simultaneously in the periosteum and marrow, the myelogenous form having no capsule and destroying the bone rapidly. Both varieties give rise to cysts, single or multiple. The *sarcoma* is the most common primary tumor, and the cells comprising it may be round, spindle-shaped, or giant-celled. It is often telangiectatic. The myelogenous sarcoma, usually occurring in the epiphysis of the tibia, humerus, etc., is, even until it reaches considerable size, covered with a bony shell, which may fracture spontaneously. On section, a milky fluid may exude. Periosteal sarcomata occur anywhere and are generally mixed tumors. A special variety, chloroma, green and yellow in color, is seen in the facial and cranial bones. *Carcinoma* is always secondary and is usually due to direct extension; it is seen in the skull, sternum, and ribs, where it forms either a circumscribed node or diffuse infiltration and is always accompanied by lacunar resorption.

Cysts arise from lacunar atrophy, osteomalacia, disintegration, or excessive resorption. They are common on the alveolar processes of the upper or lower jaw, associated with enlarged and tortuous veins, and on the clavicle, usually connected with some solid tumor. A turbid or hemorrhagic fluid exudes on section.¹

The *Echinococcus* is the most common parasite. It occurs in the long, pelvic, cranial, and vertebral bones as a single sac or as internal or external daughter cysts. There are always associated some resorption and atrophy of the affected bone, and there may be distention, inflation, or spontaneous fracture. *Cysticercus* is very rare.

Aneurisms are generally anastomotic, but primary aneurism may occur, usually in the cancellated tissue of the head of the tibia, associated with absorption of the compact bone and periosteum. *Hæmatomata* are occasionally produced by hemorrhage following trauma or rupture of a softening tumor.

¹ For a description of the benign dentigerous cysts of bones see BLOODGOOD, *Jr. Amer. Med. Assoc.*, Oct. 15, 1904; of pelvic deformities, BREUS and KOLISKO, *Path. Beckenformen*, 1904; and of "poker back" (spondylosis), *Fortschr. a. d. Gebiete der X-Strahlen*, 1904, vol. vii.

CHAPTER XVIII

POST-MORTEM EXAMINATIONS OF THE NEW-BORN ¹

THE post-mortem examination of a child may be performed in a similar manner to that of an adult. The thoracic and abdominal organs of a babe when exposed to view are well shown in Fig. 164. That several hundred years ago the dissection of the fetal structures was well understood, is seen by reference to Fig. 165.

In performing a postmortem on a child it is sometimes advantageous to remove the viscera *en masse*, scissors being largely used for this purpose in place of the knife, even to the cutting of the clavicles in their central part. In France evisceration is done quite frequently in the adult, and has the advantage of saving time by permitting the removal of the spinal cord while the thoracic and abdominal organs are being examined both from behind and in front. To practise evisceration the trachea and œsophagus are twice tied as high up as practicable, divided between the ligatures, and the lower portion then elevated with the free hand. All the posterior attachments are cut as close as possible to the vertebral column until the diaphragm is reached. The cervical and thoracic organs are then brought out of the body and laid over the costal margin opposite the side upon which the operator next works. The diaphragm is now excised laterally and posteriorly, adhesions being severed with the knife as before. It is well to pull from below upon the liver, stomach, and spleen, so that these organs will not be injured by the manipulations. The crura being cut loose, the diaphragm is free. The posterior peritoneum having been already incised by the removal of the diaphragm, the kidneys are readily found from above, and when removed the psoas muscles come prominently into view. The common iliac vessels, round ligaments, etc., are next incised. Two ligatures are now applied to the rectum, which is then divided between them. When everything which holds the abdominal organs in place has been loosened with the hand, the organs of both the thorax and the abdomen can be readily removed, leaving only the bladder and organs of generation *in situ*;

¹ For weights and measurements, see Chapter XXIV.

these may be excised later, in the same manner as that described for the adult on page 17; or, by means of the incisions there given, removed while still attached to the other abdominal viscera. The cervico-thoracic abdominal cavity is then to be carefully inspected.

The body of a child thus disembowelled can be kept for a long time, especially if the thoracic and abdominal cavities are packed with a mixture of equal parts of bran and salt to which a little white arsenic has been added. The cadaver may then advantageously be surrounded with cotton and a circular bandage applied to the chest and thorax. Parental consent to the performance of an autopsy may sometimes be obtained by thus giving assurance of the preservation of the body.

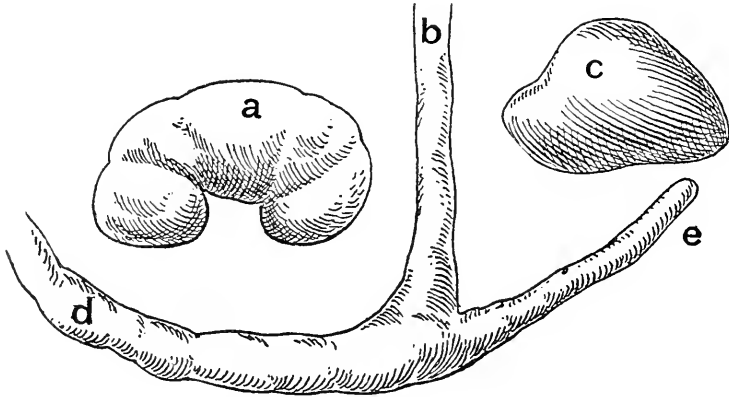


FIG. 166.—Actual and relative size of, *a*, the kidney; *b*, small intestine; *c*, spleen; *d*, large intestine; and *e*, appendix, in a full-term child. The manner in which the appendix comes off is also well seen.

In the babe there will at once be noticed the large size of the appendix, and the manner in which it forms its connection with the caput coli. Fig. 166 shows the relative size of the appendix in its relation to the kidney and spleen. The liver and the adrenals appear abnormally large in proportion to the other organs. The perpendicular situation of the stomach is to be noted, it being more difficult to distinguish the greater and lesser curvatures than in the adult. The dissection of the cardiac plexus should always be made after diphtheria and other contagious diseases attended with cardiac failure. This examination also includes the pneumogastrics and the cervical sympathetics. Wrisberg's ganglion (Fig. 74) is found by looking carefully in the region of the arch of the aorta, the right branch of the pulmonary artery, and the ductus Botalli. (Fig. 167.) Walckhoff believes that the

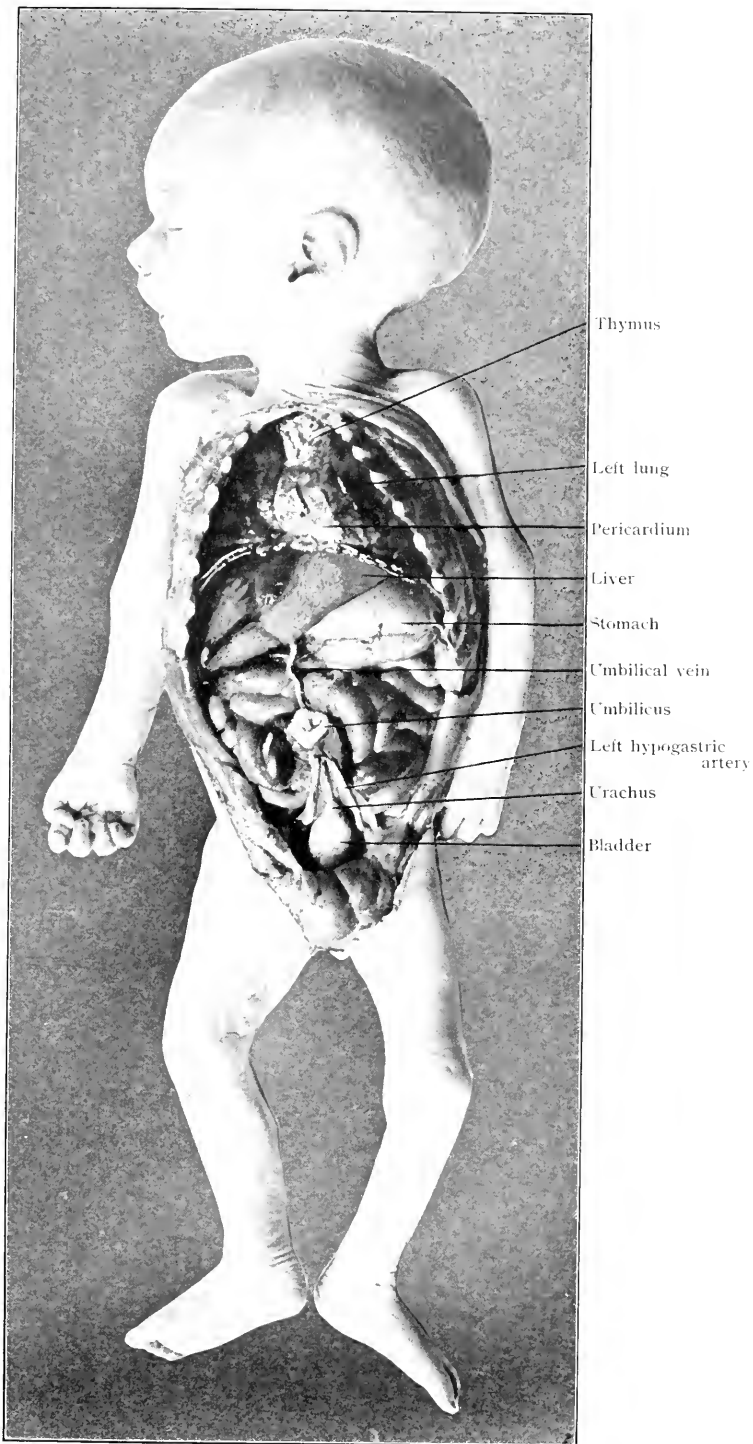


FIG. 164.—Post-mortem examination of new born babe.

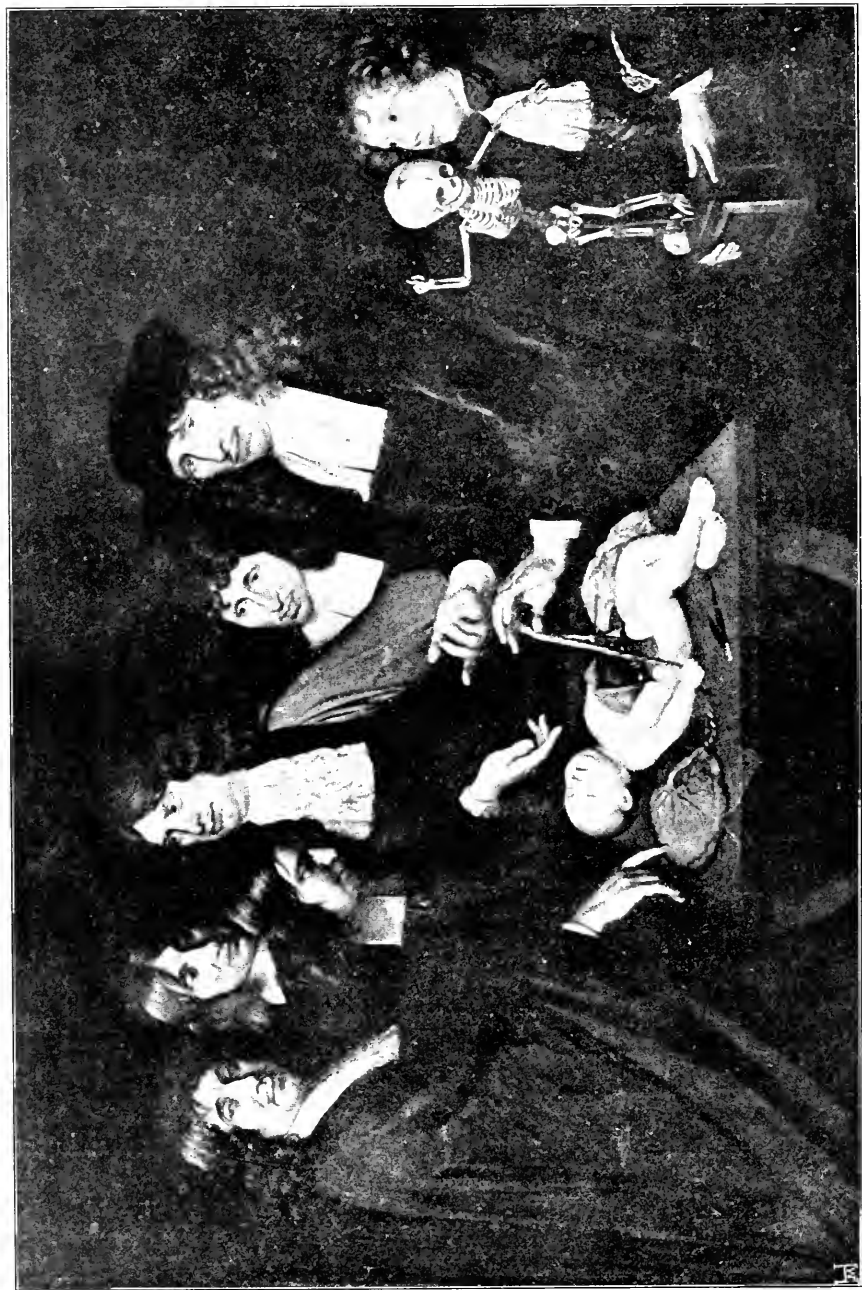

FIG. 165.—The anatomist, Dr. Frederik Ruysch, and his son, on the right, with a fetal skeleton. From a painting by Johan van Neck, Amsterdam, 1683.

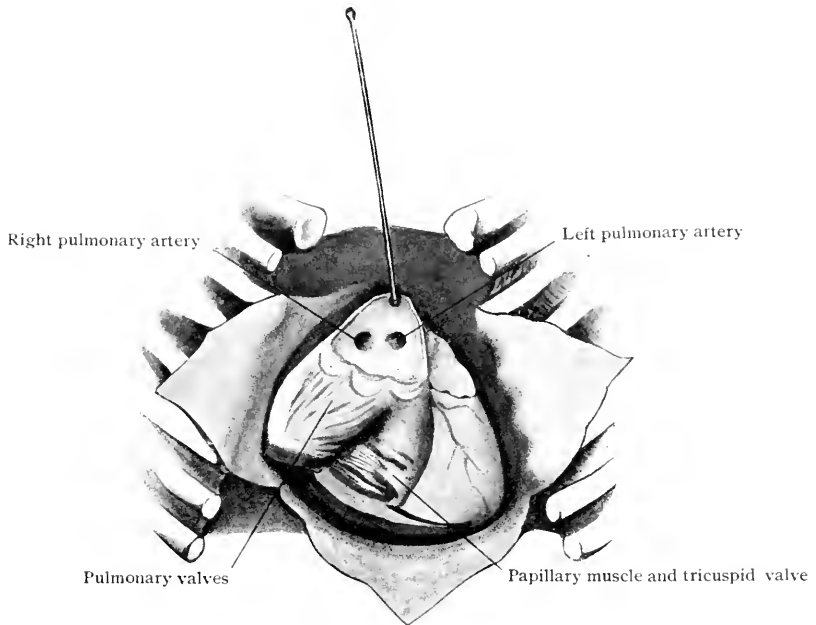


FIG. 167.—Examination of the ductus arteriosus. The sound is represented as introduced into the ductus arteriosus Botalli; this duct usually closes about the fourth day after birth. Congenital aneurisms sometimes occur here, and one of the theories of the formation of aneurisms of the aorta is based upon weakness at this spot. (After Nauwerck.)

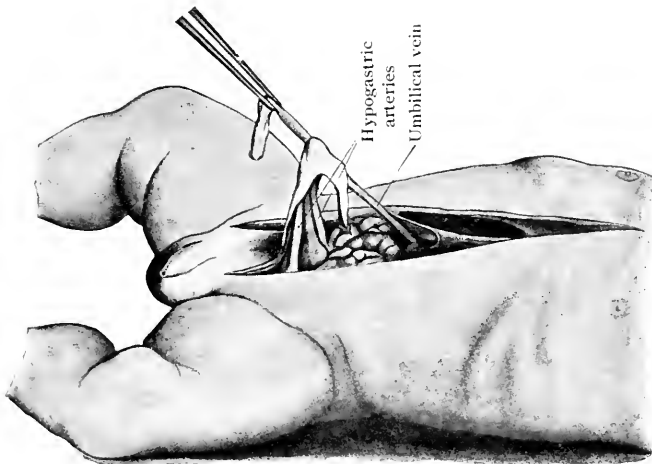


FIG. 168.—Examination of the umbilical vessels. (After Nauwerck.)

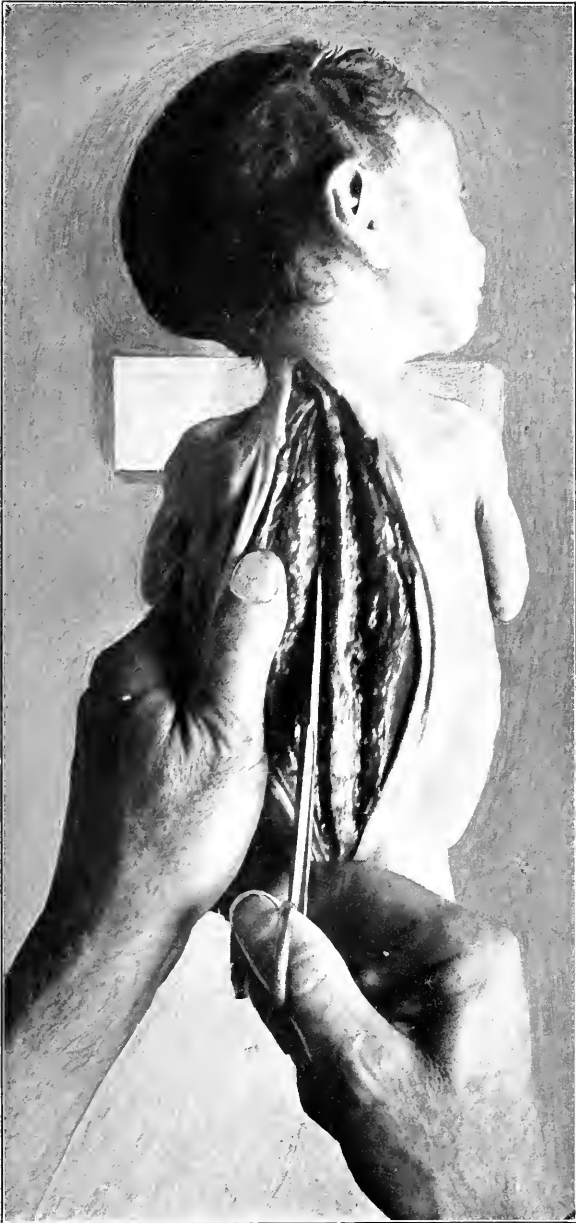

FIG. 169.—Removal of the spinal cord of a child.

expansion of the lungs changes the position of the heart to such an extent that the arterial canal is at once twisted, thus stopping the circulation through it. The unexpanded lungs are of firm consistence, do not crepitate, and do not cover the anterior surface of the heart. The color is a brownish slate. The expanded lungs are of light rose tint, somewhat blood-stained, except where the bluish spots of fetal atelectasis persist. The methods of examining the umbilical vessels are readily seen by referring to Figs. 164, 165, and 168. Study with care the point of insertion of the gelatin of Wharton to the circular fold of the skin at the umbilicus in a new-born babe. The fontanelles and the cranial sutures should be most carefully studied, as the mechanism which admits of such compression during labor is most wonderful.

The removal of the child's brain is more difficult than that of an adult, because, first, it is much softer, and, second, the dura is normally adherent to the cranium. But it is easier in one respect,—the bones and sutures are not ossified. In a new-born child the brain is so soft that its removal without injury is almost impossible. In such cases it is advisable to lay the body for a short time on ice sprinkled with salt, in order that the brain may become firmer by the consequent lowering of the temperature. By another method—and it is the one from which I have obtained the best results—the child is placed in a large basin or tub containing a strong solution of common salt (about half a bucketful to four or five times this amount of water) and held steady by an assistant while the brain is removed by operating beneath the surface of the liquid. As brine of the above strength has a specific gravity slightly greater than that of the cerebral substance, it affords a more general and even support in the subsequent manipulation, thus lessening the liability of damage in the removal of the brain.

The method in detail is as follows: The scalp is incised across the vertex and the flaps are turned forward and backward as in the adult. With scissors having well-rounded points the sutures and dura are cut through well down to the base of the skull. The five flaps thus formed are pulled outward and, if necessary, cut partly across their base with strong scissors. While the brain is being removed the body should preferably be held in the salt solution. Begin by removing the falx cerebri and longitudinal sinus, then the frontal lobes, olfactory bulbs, etc., in the usual order. When the tentorium and falx are cut through, the brain can be pushed out into the solution, where it will float. If it be desired to harden the brain, it is well to place a jar of

Müller's or other hardening fluid in the brine and under the brain as it floats therein, care being taken in the transfer to allow as little as possible of the salt solution to enter the jar, though the fluid should immediately afterwards be changed for a fresh supply.

From the body of a baby the spinal cord may be removed with scissors alone, as the parts are easily cut through. The lines for the incisions through the skin and the vertebræ are made in the same manner as in the adult, but neither knife nor saw is required, the scissors being strong enough to penetrate easily the soft bony structures of the vertebral column in a child under fifteen months of age. (Fig. 169.) In babes the spinal cord is relatively much firmer than the brain.

In autopsies on babes suspected of being the victims of hereditary syphilis it is often important to look for the fatty changes produced by that disease at the junction of the cartilage and the bone in the femur. For this purpose a longitudinal incision is made directly over the head of the os femoris and the soft parts are dissected until the bone is reached. The ligaments are then incised and the head is disarticulated. The shaft is held by the left hand securely wrapped in a towel while a perpendicular incision through the cartilaginous head is made down to the bone; should this be much ossified, the incision may be continued with a saw. After sawing for about two inches, a knife is introduced and one segment is broken off. The presence of a yellowish area of fatty degeneration, more conspicuous in the osseous portion than in the cartilage, shows an interference in the nutrition of the part, quite characteristic of hereditary syphilis. (Figs. 170 and 171.)

The centre of ossification of the lower epiphysis of the femur is present at the end of the ninth lunar month of intra-uterine life. In over seven hundred full-term infants examined by Vibert and Liman it was found to be absent in only sixteen cases. To determine the presence or absence of Béclard's sign (presence of the centre of ossification in the femur) the knee is forcibly flexed, and a transverse incision made below the patella, thus exposing the knee-joint. The lower end of the femur (epiphyseal cartilage) is then cut in thin sections perpendicular to the axis of the bone until the greatest diameter of the femoral osseous centre is found, which in a child at term will measure from a half to five millimetres across, its red color affording a striking contrast to the gray cartilage. (Fig. 172.) This area resists putrefactive changes. The ossific centre of the tarsal cuboid bone is still more reliable in determining maturity, as this

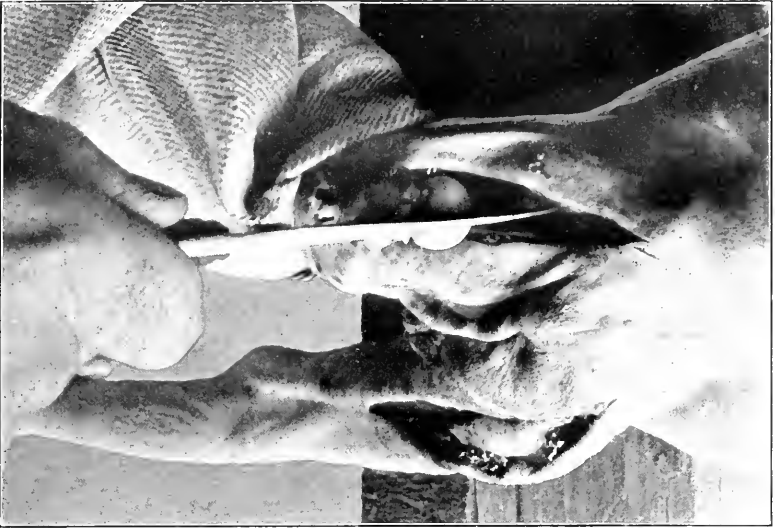

FIG. 170.—Method of examining for syphilitic osteochondritis of the femur. The initial skin incision is seen over the femur on the right side; in the left limb the bone has been disarticulated. The left hand, holding the bone, is well wrapped in a towel. The longitudinal incision is made with a strong cartilage-knife. Usually this is sufficient even to cut the bone; if not, a small saw may be used.

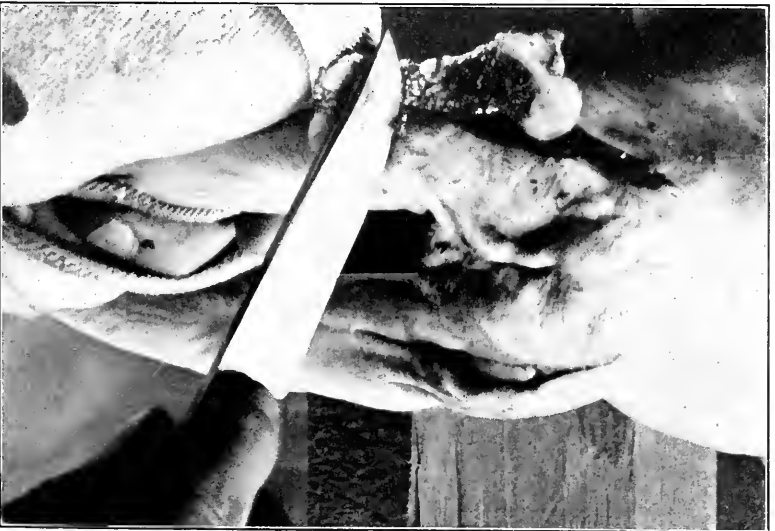

FIG. 171.—Examination for syphilitic osteochondritis of the femur. After the sawing is completed, one portion of the cut bone is bent back and the osteochondral line is well shown. In the illustration the line of junction between the bone and cartilage is normal; were syphilitis present, it would be zigzag.

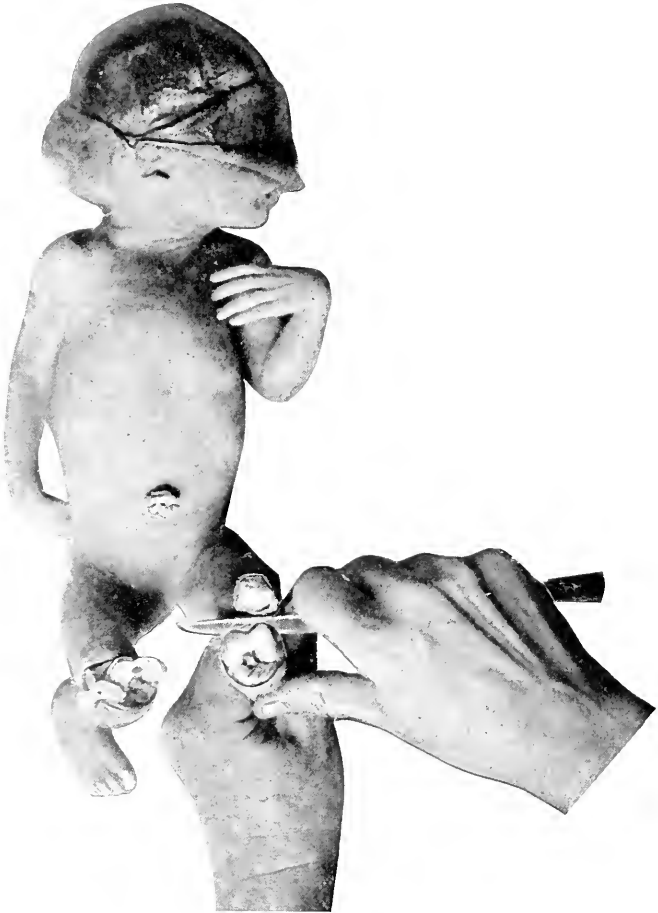

FIG. 172.—Method of exposing Bédard's centre.

centre appears at the last month of fetal life. Another sign of importance in a full-term child is the presence of eight separate small dental compartments in the inferior maxillary bone, four on each side of the median line, and a large space towards the ramus which has not yet had the partitions divided off, though an attempt at their formation may often be seen. To determine if the child be viable the osseous centre of the os calcis should be examined, as this is first found between the one hundred and ninety-sixth and the two hundred and tenth day of fetal life.

After a careful study of the urine of the new-born, Sabrazès¹ concludes that the secretion of the fetal kidneys possesses hæmolytic properties and is poor in chlorids and phosphates. Some authorities find no phosphates until after two complete days of extra-uterine existence. In the renal tubules are found during the first week of life considerable quantities of precipitated sodium urates, causing in the pyramids yellowish-white lines which converge towards the apex of the papillæ. These are supposed to prove that the infant was born alive. If a child was born before term, meconium is found in the small intestine alone, but if born at term, it is found in the large intestine. The kidneys are lobular, as in ruminants.

The latest investigations lead to the conclusion that puerperal eclampsia, in which there is laking of the blood-corpuscles and a tendency to the formation of thrombi and emboli, arises from a defective excretory power of the mother, usually referable to the kidneys, but that the actual toxin is a fetal product, the added stress of which upon the defective eliminating powers of the mother precipitates the eclamptic attack. A placental theory for the etiology of eclampsia has also been advanced. The liver of the mother shows congestion and infarction, and degenerations predominate. Raubitschek² believes that the secretion (*Hexenmilch*) frequently found in the mammary glands of the new-born is the result of a necrosis and the separation of epithelial cells in the acini and ducts of these glands, which are thus shown to be at this stage analogous to the sebaceous glands. The secretion of colostrum immediately preceding lactation in the puerperium is of similar origin.

The greenish color of the large intestine of a new-born babe is due to meconium, which is composed of cholesterin, crystals of sulphate

¹ *Hebd. des sciences méd.*, October 5, 1902.

² *Z. f. Heilkunde*, vol. xxv, no. 1, p. 16; abs., *Amer. Med.*, March 26, 1904.

of lime, shed epithelium, biliverdin corpuscles, and a highly refractive granular *débris*.

Blummer¹ considers the status lymphaticus to be a definite pathologic entity, probably associated with, if not due to, a condition of intermittent lymphotoxæmia, and at times capable of playing an important *rôle* in sudden death, fatal anæsthesia, and infection. In some cases sudden death is undoubtedly mechanical and due to asphyxia caused by the enlarged thymus pressing on the trachea.

The following two examples of the many which have come under my personal observation show the necessity of constant vigilance on the part of the practising physician in order that he may draw correct conclusions from the pathologic data presented to his view. Two days after its birth a babe came upon the post-mortem table of one of the hospitals with which I was connected some years ago. The autopsy revealed a completely imperforate rectum, the anus likewise being imperforate. The physician in charge had ordered immediately after birth that a glycerin suppository should be administered morning and evening. The nurse reported each time upon the hospital records the carrying out of the order!² In 1896 there came by train to Philadelphia a hard-working colored woman who was about five months pregnant. Feeling her labor pains coming on she took a cab at the Broad Street Station, and was driven to one of our large hospitals, where she was duly delivered of a dead child. The cabman returned to his post, seeking more work. Upon being again employed a five-months' colored fœtus was found on the floor of the carriage. At the Coroner's inquest the mother swore that she was unaware of the fact that she had given birth to the child while in the carriage and that no abortion had been performed upon her person. She considered the premature labor as being due to hard work. At the hospital the placenta had not been critically examined, the existence, therefore, of a twin pregnancy not being established at the time of the delivery of the dead fœtus.³

¹ *Johns Hopkins Bulletin*, October, 1903.

² CATTELL, *Annals of Gynec. and Pædiatry*, September, 1893, p. 759.

³ CATTELL, *Int. Med. Mag.*, February, 1897, p. 80.

CHAPTER XIX

RESTRICTED POST-MORTEM EXAMINATIONS

IN case permission to open the thorax is refused, the diaphragm may be severed from its anterior attachments, and the lungs, the heart, and even the tongue and adjacent parts may be removed *en masse* through an abdominal incision or a laparotomy wound.

Should the avoidance of visible mutilation be imperative, it is possible to examine and, if necessary, to remove both the abdominal and thoracic viscera through the rectum or perineum in males or through these parts and the vagina in females. In the male this procedure is performed in the following manner:¹

The body is placed on the back, with the buttocks very near the end of the table and the thighs widely separated and flexed upon the body. The scrotum is then well drawn up, and an incision is made from the perineoscrotal junction to the margin of the anus and down to the bulb. The knife is carried around this and through the subjacent tissue to the pelvic fascia underlying the vesicorectal pouch, without injuring the bladder or rectum. The left arm being bared to the shoulder, the hand is introduced through the incision, and gradually forced up between the parietal peritoneum and the rectus muscles to the diaphragm. The peritoneum may be opened, but the intestines will invest the hand like a tightly fitting glove and make the manipulation more difficult. If unable to perforate the diaphragm with the fingers, a scalpel may be carried up, with the blade flat against the index-finger, and a nick made in the muscle, the knife being then withdrawn and the opening enlarged with the fingers. The lungs may be examined by palpation, any adhesions broken up, and the organs dragged into the abdominal cavity, the roots being severed with a knife, after which they may be removed. The heart can be examined in a similar manner, except that, before it can be moved very far, scissors or a knife will be necessary to sever the large vessels. The kidneys, adrenals, spleen, stomach, etc., may be removed in this manner, but the liver must generally be divided into its lobes in order to get it through the incision. The organs are examined in the usual manner and returned to the body; some wads of oakum may then be pushed into the abdominal cavity and the perineal incision very carefully closed by hidden sutures.

¹ H. A. KELLY, *Medical News*, June 30, 1883.

It is also possible to make the examination through the rectum, but the sphincter is left dilated and gaping, presenting a much more conspicuous and unsightly appearance than the perineal incision.

This method is most difficult of accomplishment when the operator's arm measures more than ten or eleven inches around the biceps, especially in subjects of only average size. The work is very arduous, because of the strained and cramped position which the hand and arm must assume in order to pass the promontory of the sacrum. Coplin suggests the use of the photographer's thimble in tearing the tissues within the abdominal cavity.

Access to the interior of the trunk may readily be had from the dorsum by making a longitudinal incision to one side of the spinal column and sawing the ribs close to their vertebral attachments. When the examination is made through the vagina, an oval incision such as is described on page 194 may be made, or a vaginal hysterectomy may first be performed (Figs. 106 to 114, inclusive).

The brain may be removed almost intact (in two or three pieces) by making a transverse four-inch incision across the fifth cervical vertebra, dissecting up the soft tissues, and cutting a V-shaped segment out of the occipital bone by introducing a saw through the foramen magnum and sawing towards the ears and then across transversely. (Fig. 152, *E A F.*) A rapid, but not scientific, method of diagnosing hemorrhage, which also permits of the removal of the brain in small pieces, is referred to on p. 204.

An examination of the bones of the face is sometimes desirable, but the circumstances and conditions under which it may be required are so variable that the method must be left entirely to the judgment of the operator. Disfigurement is so readily noticed that nothing further than a superficial examination should be attempted without the permission of those interested. The simplest and most unobjectionable method of procedure is to introduce the knife through an incision previously made from the ear to the neck and dissect subcutaneously the tissue investing the bony structures. If the bones of the face are to be removed, it may be necessary to make a transverse incision, the point of election being the furrow between the inferior maxilla and the neck.

If the oral cavity must be examined through the orifice of the mouth after rigor mortis has set in, the rigidity may be overcome by placing towels soaked with hot water over the muscles of the jaw. Such appli-

cations repeated for about five minutes usually suffice. Do not use a chisel to pry the jaws apart, as is sometimes recommended, because of the danger of breaking the teeth or knocking them out. As the rigidity rarely returns, it is advisable at the end of the examination to close the mouth with a few sutures through the mucous membrane of the upper and lower lips.

The nasal cavity may be exposed and examined by detaching with a knife the upper lip from the maxilla from within and then removing with a saw such portions of the superior jaw-bone as will afford room for inspection of the parts under consideration (Figs. 173 and 174). By the removal of the eye the pituitary body, Gasserian ganglion, etc., are rendered easily accessible. Indeed, it is surprising what extensive dissections may be made in the region of the face and neck in the ways just mentioned, thus affording an opportunity for thorough digital examination of areas not open to ocular inspection.

CHAPTER XX

RESTORATION AND PRESERVATION OF THE BODY

WHEN the examination has been completed, the cavities of the body should be thoroughly sponged out, all blood and other fluids removed, and bleeding vessels tied to prevent leakage. The organs should then, as nearly as possible, be returned to their respective positions, and the cavities filled with dry bran, absorbent cotton, sawdust, sea-weed, or shavings, in sufficient quantity to restore the original contour of the body, covering the abdominal contents with old cloth or papers to protect the under surface of the seam. The brain is generally put into the abdominal or thoracic cavity, owing to the great difficulty in returning it to the skull. If several postmortems be made at the same time and place, care should be taken to return the organs to the proper body, nor should a cadaver be used as a convenient receptacle for the disposal of specimens which are no longer of any use. In the case of a child a small bag may be packed with sand or sawdust so as to assume the shape of the brain and placed inside the calvarium; the brain itself, after dissection, is placed in the abdominal or thoracic cavity. It is unwise, however, to permit any member of the family to witness this procedure.

In all private cases it is important to secure the skullcap in position, to prevent the unsightly disfigurement produced when it slips after the scalp has been sutured. A number of efficient methods have been devised, but the one selected usually depends upon circumstances or upon ingenuity. The fossæ of the skull as well as the calvarium may be filled with plaster of Paris, and while the plaster is still soft a short, stout stick of wood is pushed through into the foramen magnum, the upper end extending to the skullcap, which is then adjusted. When the plaster hardens, the calvarium is well fastened in good position. If in removing the skullcap the precaution is taken to crack at least a part of the inner table with the chisel and hammer, projecting pieces of bone are usually left, which interlock and hold the calvaria snugly in position when it is replaced.¹ If the edges of the temporalis have not been too badly lacerated, sutures may be passed through the muscle and fascia

¹ MALLORY and WRIGHT, *Pathological Technique*.

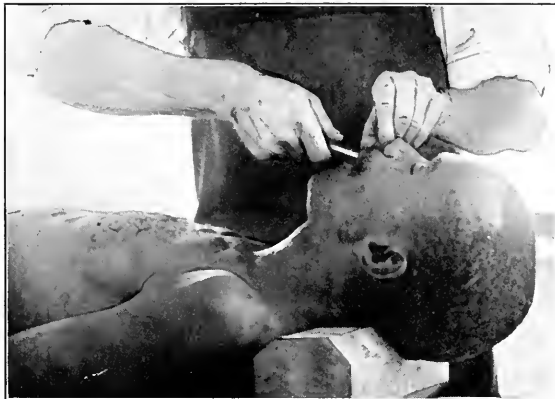

FIG. 173.—Method of examining nasal cavities, antrum of Highmore, etc. By means of a knife the uppermost mucous membrane between the lip and the superior maxilla is incised, the upper lip being elevated with the left hand during the incision. Vertical sawing is now done in the median line, and the tooth extracted at the point where the lateral sawing is to take place. The bone-forceps readily bring the desired portion of bone away, or it can be loosened by means of a chisel.

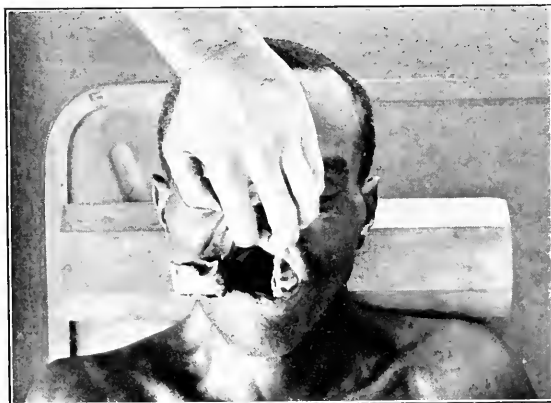

FIG. 174.—Appearance of the part after removal of a portion of the superior maxilla for the purpose of examining the nasal cavities, antrum of Highmore, etc.

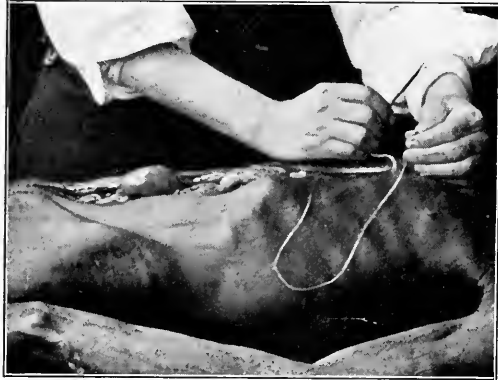


FIG. 175.—Method of sewing up the body.

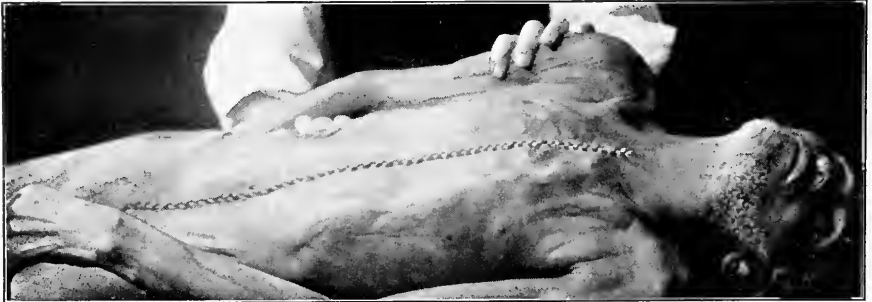

FIG. 176.—Appearance of body after it has been sewed with base-ball stitch. The sewing has been done from above downward, and there is no puckering at the point of starting.

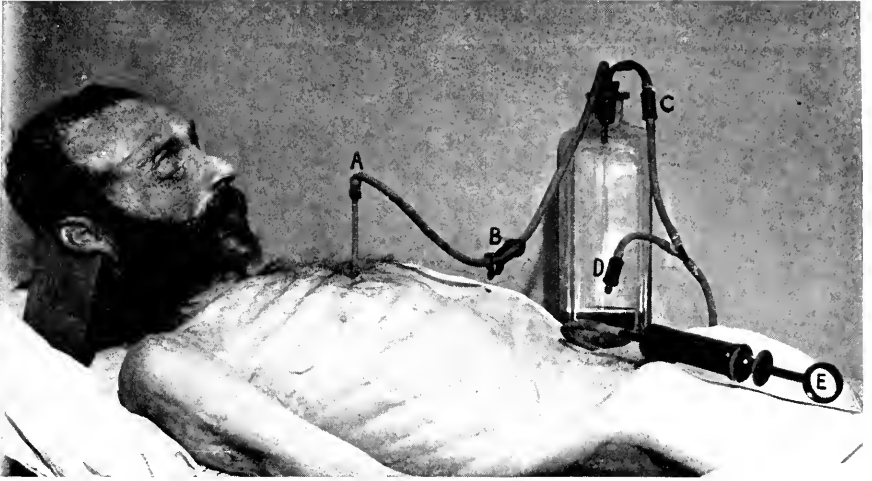


FIG. 179.—Method of withdrawing blood from a body previous to its injection with an embalming fluid. *A*, trocar inserted into left auricle of the heart; *B*, stop-cock; *C* exhaust valve; *D*, outlet valve for air; *E*, syringe. The valve *D* is used when fluid is to be pumped into the body.

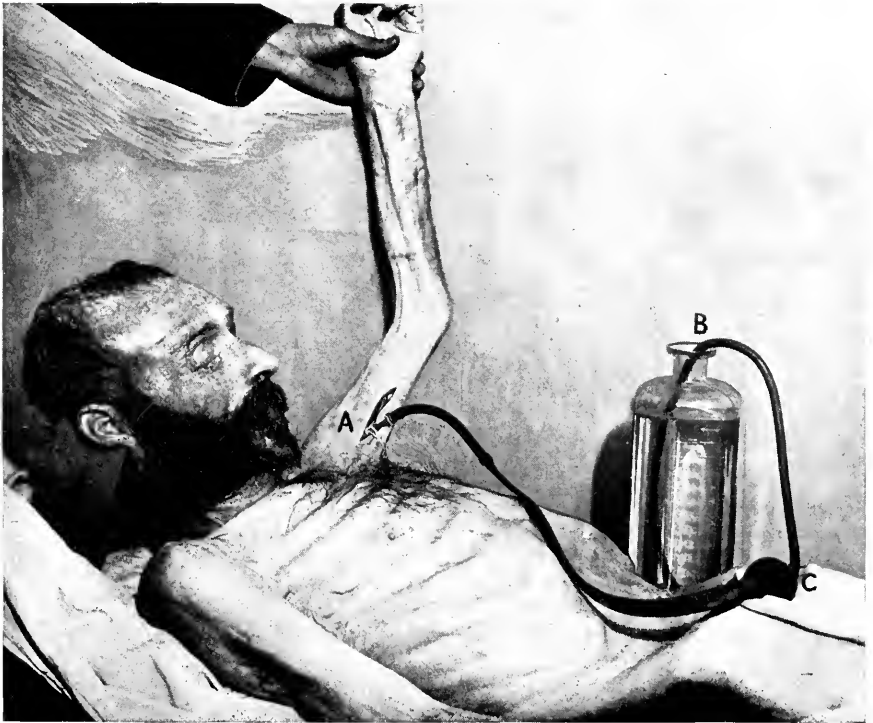

FIG. 180.—Injection of body with embalming fluid. *A*, cannula inserted into brachial artery; *B*, tube going down to bottom of bottle containing embalming fluid; *C*, hand-bulb and valve, by the use of which the fluid is forced through the arterial circulation.



FIG. 181.—Refrigerating room. *A*, recording thermometer and middle tier of shelving; *B* and *D*, tiers of shelving; *C*, brine tank; *E*, pipes of refrigeration apparatus.

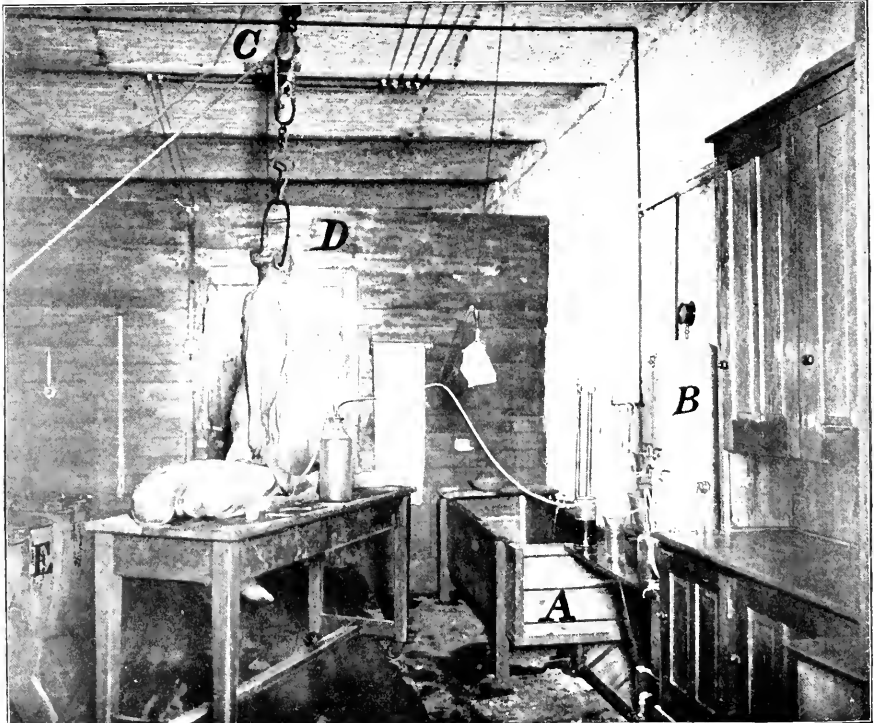


FIG. 182.—Preparation of bodies after removal from refrigerating room. *A*, bath; *B*, air-condenser and injecting apparatus; *C*, pulley suspension apparatus; *D*, exterior of refrigerator box; *E*, odorless excavator barrels.

with very satisfactory results. Small holes may be drilled in the skull and sutures passed through them, or a wide staple (or double-pointed carpet-tack) may be used for the same purpose. Another method is to drive a small wire pin, or a wire nail with its head cut off, about half an inch long, half-way into the diploë of the skull and insert the other end in a hole, made to correspond, in the calvarium. Two of these pins should be enough. Still another method is that described by Slee.¹ The posterior line of sawing, instead of stopping at the angle, is continued an inch or more into the temporal bone; a piece of ordinary roller

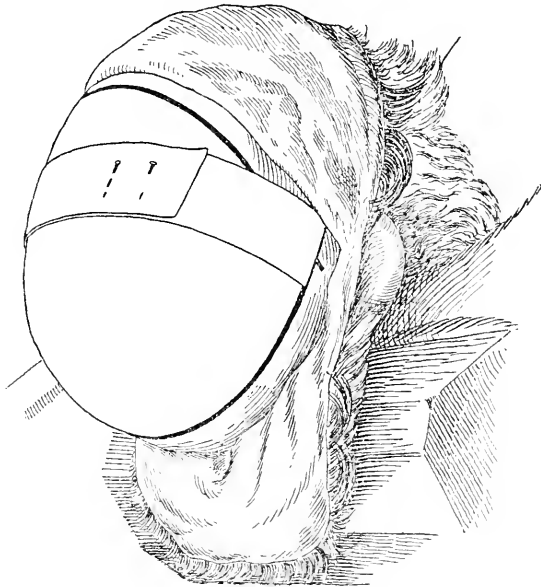


FIG. 177.—Slee's method of fixing the skullcap.

bandage is then stretched across the skull and inserted in the saw-cut; the calvarium is replaced, the ends of the bandage are brought together over the vault and securely sewed, pinned, or tied (Fig. 177). A ready and efficient method of my own for fixing the skullcap is to make in two or three places on the thickest portions of the skull vertical pencil-marks across the line of sawing and extending an inch above and below it, saw these for three-quarters of an inch or so, and into each pair of saw-cuts insert the ends of a thin, double-wedge-shaped piece of iron or steel so made that it will be tightly pushed into place when the skullcap

¹ *Medical News*, December 31, 1892, p. 737.

is affixed. Any portion projecting beyond the bone is hammered down. For another method see Fig. 178.

If the vault of the cranium is to be retained by the physician and a substitute cannot be found, take a square piece of pasteboard about three millimetres thick (thinner for children) and soak it in warm water for a quarter of an hour, or until it is soft enough to be easily moulded over the skullcap. Having done this, cut the pasteboard parallel to the edges of the saw-cuts and overriding them from

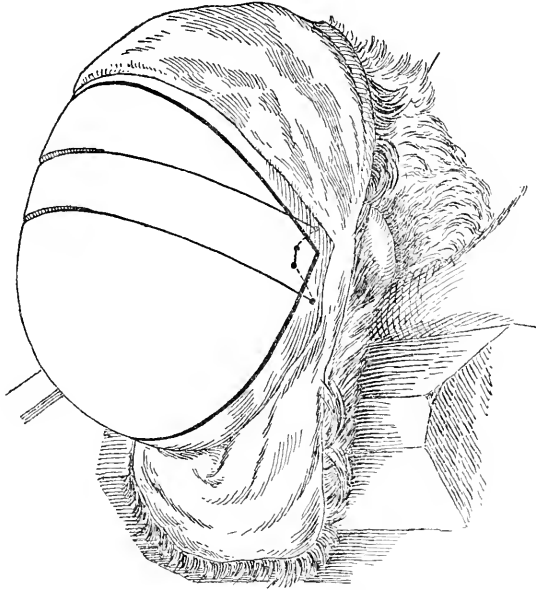


FIG. 178.—Author's method of holding skullcap in place. Four holes are drilled in the bones on each side, two to the right and left of the angle in the temporal bone and two in the skullcap just above the angle. Saw-cuts to hold the wire or string are made in the vertex, the string being thrust in and out of the openings and tied at any convenient spot.

ten to fifteen millimetres. Then fill the skull cavity with wadding or plaster of Paris. Remove the pasteboard from the skullcap just as soon as it becomes so dry that when it is applied to the base of the skull the edges will adapt themselves to the border thereof. With a knife the edges of the pasteboard are cut obliquely, any folds which are formed therein are incised along their crests, one edge is tucked in under the other, and the surface smoothed by the use of the knife. Strong twine is bound twice around and the pasteboard thus securely fastened to the base of the skull. The temporal muscle is drawn up-

ward and the skinflaps stitched as is next described. (Nauwerck.)

The skullcap being secured, the scalp is replaced and sutured with glover's or base-ball stitches,—*i.e.*, those made by repeatedly passing the needle from within outward. By careful use of black or dark thread the incision may be so neatly closed as to escape even fairly close inspection. It sometimes happens that by stretching the skin becomes baggy. Should such be the case, a small portion of the hairy scalp parallel to the original incision across the vertex may be removed previous to the sewing.

After the organs are returned, the sternum should be supported by paper, or, still better, by old linen. Bran and fine sawdust are very useful to fill in with, as they absorb the moisture. Oakum makes the sewing difficult. If the organs have been removed through the vagina or rectum, these outlets should be doubly sewed, some absorbent material having first been introduced to prevent leakage.

A round stick or a piece of gas-pipe may be placed in the spinal canal after the removal of the cord, with the upper end pushed through the foramen magnum, especially if any of the vertebræ have been taken away, and plaster of Paris may be poured in until the cavity is well filled. An old cloth or some paper is then placed on top and the whole sewed together. The line of the incision may be covered with a strip of adhesive plaster. As in Gersuny's method for the correction of deformities, paraffin at a temperature of about 55° C. may be injected into the body in large quantities and before cooling be moulded into the proper shape.

The abdominal incision is closed by sewing from the pubes to the sternum, passing the stitches from within outward, about three-eighths of an inch from the cut edges and about half an inch apart, alternating on the two sides so that each needle-hole on one side will be midway between two on the opposite side. The twine should be about half a millimetre thick. Both ends of the suture should be securely tied. For the closing stitch it is well to cut the thread near the needle, withdraw one end, and tie in a surgeon's knot. Roughly estimated, the thread required is twice the length of the incision to be closed. Carefully crowd in any extruding fascia and avoid puckering of the part. (Figs. 175 and 176.)

If the mouth has been opened, or any of the tongue removed with the structures of the neck, the lips may be held together by a few sutures passed through the oral mucous membrane.

If any portions of bone have been excised, their place may be supplied by using a properly shaped piece of wood, which is held in position with sutures, wire, or strong cord, or by plaster of Paris.

Finally, the body should be very carefully cleaned and returned to the place and position in which it was found. Politics as they obtain in some places make the Coroner's physician even clean up the mortuary after sewing up the body!

The characteristic "post-mortem odor" is very persistent and defies all kinds of soap. It usually results from handling the intestines, and can best be removed by washing the hands with aromatic spirit of ammonia or, in the absence of that, by rubbing them with dry mustard and then washing with soap and water, or, still better, with some of the newer liquid antiseptic soaps. Ammonia or the aromatic spirit thereof will remove iodine stains, while carbol-fuchsin and other aniline stains yield to a weak solution of sodium hypobromite.

EMBALMED AND FROZEN BODIES.—Embalming may interfere with the work of the pathologist, the bacteriologist, and the toxicologist. Fortunately, the old zinc, mercurial, and arsenical combinations have been very largely superseded by formalin, a much more desirable preparation, although it may irritate the eyes, deaden the sensibility of the finger tips, and even produce an eczema of the hands of the obducent. Arterial embalming is at present more used by undertakers than any other method of preserving the body after death. It is customary among many undertakers first to aspirate the heart and remove as much blood as possible (Fig. 179), though this procedure is no longer of such importance as formerly, owing to the improvement in the preservative powers of the embalming fluids now in use. Removal of the contents of stomach and intestines is also sometimes practised and materially aids the preservation. One of the superficial arteries is then opened, as the femoral, carotid, radial, or brachial, and at least two quarts of fluid slowly injected into the vessel. (Fig. 180.)

Next in importance is cavity embalming or injection of preserving fluid into the three body cavities. In the abdomen, the instrument is thrust, preferably, through the umbilicus, so that the wound of entrance will not be conspicuous, and efforts are then made to puncture the heart, lungs, intestines, liver, and other abdominal organs. The gas escapes, any blood exuding is withdrawn, and the fluid is afterwards injected, the stream being directed towards the liver. Some

embalmers urge avoidance of any injury to enclosed viscera, and remove the contents *per rectum*.

The disadvantages of this method are: first, in cases of abortion with peritonitis there may be considerable difficulty in determining whether the openings were made before or after death; secondly, such punctures may also complicate matters by opening up abscess-cavities, cysts, aneurisms, etc.; and thirdly, in cases of poisoning, besides allowing the stomach contents to escape, the fluid may contain the same substance as that which caused death. Even when formalin has been employed, as in the recent Haines case in New Jersey, the syringe may have been previously used for injecting an arsenical preparation.

The thorax is best filled by injecting the fluid through a long curved trocar passed down through an opening in the trachea. The fluid should first fill both lungs, and afterwards the trocar should be pushed down so that the point pierces the pleura, and these cavities are then to be filled with fluid. The brain cavity is best filled by passing a needle up the nose, breaking the cribriform plate, and then injecting the cerebrospinal cavities and the sinuses. Any excess of fluid passes through the jugular vein to thoracic organs. These methods, though preserving the nervous tissue, are not as efficient as the arterial embalming for the preservation of the body and are apt to discolor or cause swelling around the face. The trocar may be passed through the inner canthus of the eyes by the sphenoidal fissure, or through the foramen magnum, thence injecting the brain and cephalic cavity. Fluid may also be previously introduced by lumbar puncture.¹

Nauwerck employs: an injection-syringe having a capacity of five hundred cubic centimetres; long cannulæ of different calibers, with pear-shaped ends and with stopcocks or, preferably, with double stopcocks; strong twine; scalpels, scissors, forceps, grooved director, hæmostats, an aneurism-needle, and ordinary needles; basins and buckets; several packages of absorbent cotton; cloths and sponges; and ten litres of a one per cent. aqueous solution of corrosive sublimate, which may be kept in one-litre bottles. His method of embalming is begun by exposing the lower part of the abdominal aorta and the two iliac arteries. Two ligatures are placed beneath the aorta, about two finger-breadths apart, and the aorta is obliquely

¹ ONUF, *Med. Record*, July 9, 1904.

incised to allow the entrance of the cannula, which is secured by tying the distal ligature over it. The injection into the upper part of the body is then begun carefully and slowly, pausing occasionally when the counter-pressure becomes too great. About three litres are injected, more or less, depending upon the appearance of swelling of the face, seen first about the eyes and chin. The cannula is removed, both proximal and distal ligatures are tied, and the aorta is cut through. In like manner a litre of the solution is injected into each leg through the common iliac artery. A cannula with a double stopcock can be used to inject both the upper and lower parts of the body at the same time. The mesentery is ligated, and the intestines, from the beginning of the jejunum to the end of the sigmoid flexure, are removed, opened, washed out, and put in a one per cent. solution of bichlorid of mercury, and later replaced in the abdominal cavity, wrapped in sublimated cotton, or, where practicable, disposed of by cremation. The stomach, duodenum, and rectum are cleaned out with sublimate solution and packed with sublimated cotton. The bladder, vagina, external ear, and nose are similarly treated. The abdominal cavity is carefully wiped with a cloth wrung out of the bichlorid solution and dried, and the abdominal incision is sewed. The surface of the body, with the exception of the hair, is also wiped with the solution and dried. If this method fails, Nauwerck injects the preserving fluid into the carotid and axillary arteries.

Hewson¹ recommends the following injection for the preservation of human bodies for the dissecting-room:

R Sodium arsenate	2 kilogrammes.
Potassium nitrate	1 kilogramme.
Carbolic acid	150 cubic centimetres.
Boiling water.....	7850 cubic centimetres.
Boil until complete solution, then add	
Glycerin	2000 cubic centimetres.
Formalin (40 per cent. solution).....	100 to 150 cubic centimetres.
Thymol, as much as will go into solution, a piece the size of the end of the thumb being sufficient for a carboy of solution.	

About two and one-half gallons of this fluid are introduced into an artery—say the common carotid—by gravity, openings having previously been made in the toes or in several of the veins if they be distended with blood. After injection the body is thoroughly greased,

¹ *Phila. Med. Jr.*, October 27, 1900; *Amer. Med.*, February 27, 1904.

covered with paper, bandaged, and placed in cold storage until wanted for dissection. Mall embalms with carbolic acid, wood alcohol, and ultramarine blue.

Frozen bodies should not be thawed hastily by the addition of warm objects, but should be allowed to remain in a warm room for some twelve hours previous to the post-mortem examination. Figs. 181 and 182 show the refrigeration room of the Medical Department of the University of Pennsylvania, planned by Dr. Holmes. The vaults of the University of Wisconsin, designed by Professor Miller, are the most recent of their kind, narrow brine tanks extending from the floor to the ceiling. At the Paris morgue the bodies are frozen at -12° C. to -14° C. immediately upon their arrival; at the end of one day they are placed in a separate apartment having a temperature of -4° C., so as to facilitate their thawing for a postmortem in fifteen to twenty hours. (Letulle.)

DEATH MASK.—In the making of a death mask about five pounds each of plaster of Paris and of modelling clay are employed. Nearly all of the clay is rolled out until it reaches thirty inches in length. The head is placed perpendicular to the body upon an old pillow, and then the face and any hairy portions which are to be included in the mask are thoroughly anointed with olive oil or liquid vaselin. Crumpled towels or pieces of paper are now arranged so that when the potter's clay is entwined around the head it will be supported and prevent the liquid plaster of Paris from escaping. Any openings are now filled in with the remainder of the potter's clay, and the interior of the potter's clay anointed with olive oil. Two quarts of water are placed in a bowl and the plaster of Paris is slowly added, the whole being constantly stirred with a large spoon until of a gruel-like consistency, then more of the plaster of Paris is added until it begins to thicken, when it is immediately poured into the hollow cavity to secure the mould of the face. If the plaster of Paris is good it will set in about twenty minutes; the potter's clay is removed, and the cast can be lifted in a single piece from the face. It is then carefully packed in cotton, removed to the laboratory, coated with mastic varnish, and oiled. A plaster-of-Paris cast is now made of the mould in a similar manner, or the mould itself may be sent to an Italian worker in plaster, usually to be found in a city of any size.

CHAPTER XXI

DISEASES DUE TO PARASITES ¹

The number of diseases known to be due to pathogenic vegetable and animal parasites is constantly on the increase, the recent study of tropical conditions by schools of medicine especially established for this purpose and the elucidation of problems arising from the digging of the Panama Canal and the governing of the new outlying possessions of the United States having added much to our knowledge on this subject. The morbid lesions which are produced by these agencies are varied, though rarely characteristic, and require considerable bacteriologic and histologic training for their study and proper interpretation. If contagious diseases are to be stamped out, less attention than at present must be paid by our Boards of Health to politics and more consideration be given to those affections contracted from the lower animals and distributed by the agency of mosquitoes, flies, fleas, ticks, cockroaches, bedbugs, etc. Any form of disinfection which fails to rid a room of such creatures must now be considered as ineffective. The outbreak of yellow fever in the South during 1905, has called attention to the drift of public opinion in wishing to increase in severe epidemics, extending over a large area of territory, the power of the United States Marine Hospital Service over that of the State and local health authorities.

ACTINOMYCOSIS is a chronic infectious disease, occurring most frequently in horned cattle (as "lumpy-jaw" or "wooden tongue"), but found also in man. The exciting cause, the *Streptothrix actinomyces* (the ray-fungus, so called from the peculiar radiate grouping of the filaments with their bulbous extremities), is found in the pus and the newly formed granulation tissue in the form of yellowish opaque granules,—called "sulphur balls,"—which measure from one-half a millimetre to two millimetres in diameter. When these granules are crushed and placed under the microscope, they present the appearance

¹ For additional data pertaining to the pathogenic micro-organisms, see Chapter XXIII, p. 386, entitled "Bacteriologic Investigations."

so beautifully depicted by Lebert in his *Atlas* (1856). A ready method of examining the fungus is to collect a tube of pus expressed or curetted from an abscess. Incline the tube and let the fibrin coagulate; pick off the granules with a platinum rod, place them on a slide with a drop of picrocarmin solution, and after a minute or two apply a cover-glass, and examine microscopically. The fungus assumes under these conditions a bright yellow color.¹ The semi-translucent forms are the most difficult to recognize. The organism may grow outside of the body, and under certain circumstances be inoculated into animals. Infection usually takes place from food, generally through a wound or abrasion of the mucous membrane, as through the medium of carious teeth. In one case reported, the patient had been long accustomed to pick his teeth with a straw. In another instance, a young woman had acquired the habit of chewing hay while playing golf; in the latter case the first sign of the disease, which was eventually fatal, was in the alveolar process. The characteristic primary lesion is a small nodule resembling an anatomic wart. Later there occurs proliferation of cells, especially of the polymorphonuclear variety, into the surrounding fatty tissue, followed by suppuration. The abscesses are at first multiple, spherical, and discrete; in time they coalesce and give a reticulated and honey-combed appearance to the part affected. The destruction of tissue is often excessive, and metastases may occur. According to Bevan,² of Chicago, the internal administration of copper sulphate is much more efficacious than that of potassium iodid.

Lesions, classified according to mode of infection, which may possibly be hæmatogenous: ³—

I. Actinomycosis of HEAD and NECK, with infection from the mouth and pharynx. (1) The JAW is often affected; caries and necrosis of the maxilla may result. (2) The TONGUE is frequently involved. (3) The BRAIN has been the primary seat of the disease.

II. Actinomycosis of the THORAX, with infection through the respiratory tract. The lesions are usually unilateral. (1) Chronic *bronchitis*. (2) Miliary nodules in the LUNGS, formed by masses of fungi surrounded by granulation tissue. These may fuse, suppurate, and finally become cavities. (3) *Bronchopneumonia*. (4)

¹ *Presse médicale*, 1903, vol. xxvii, p. 654.

² *Jr. Amer. Med. Assoc.*, November 11, 1905.

³ *Chicago Surgical Society*, December 5, 1904.

Heart-emboli, or localized *parenchymatous myocarditis*. (5) Extension to vertebræ, ribs, and sternum, resulting in peripheral caries and necrosis.

III. Actinomycosis of the ABDOMEN, with infection practically always through the alimentary canal, though possibly, in rare instances, through the female genital organs. (1) The STOMACH has been the seat of multiple abscesses which burrowed along the diaphragm. (2) The CÆCUM may be involved in a fibrinous and ulcerative inflammation. (3) The ANO-RECTUM, (4) the LIVER, (5) the VERMIFORM APPENDIX, and (6) the OVARY have been the primary seats of the disease. (7) The SPLEEN may be attacked, but this is rare, and always leads to purulent inflammation.

It is more than probable that the pale form of *Madura foot* (mycetoma) may be due to a species of actinomycosis, the black variety being assigned by some to another variety of mould. Various varieties of *Streptothrix*, *Cladothrix*, and *Leptothrix* have been described as causing diseases of the lungs, throat, vagina, etc.

ANTHRAX is an acute, infectious, contagious disease, having for its characteristic lesion a pustule, caused by the *Bacillus anthracis*. Sheep and goats are especially predisposed, though the Angora sheep is apparently immune. In man the disease is contracted in certain occupations, as wool-sorting, tanning, etc., and by the ingestion of the flesh or milk of an infected animal. The micro-organism is rod-shaped, from two to twenty-five microns in length, non-motile (thus distinguished from the similarly shaped but motile *Bacillus subtilis*), often united, and growing with great rapidity. Characteristic cultures may be made on gelatin plates at ordinary temperatures. The bacillus is easily killed, but the spores are very resistant. For many successive years Ziegler was able to produce anthrax in mice by inoculations from similarly prepared pieces of dry catgut which contained the spores. The bacilli are found in the capillaries of the liver, the kidneys, and the lungs, in the blood, and in the pustules. Both active and passive immunization will confer artificial immunity. Serum therapy is, however, more effective in animals than in man.

In a case which the writer had the opportunity of studying with the late Dr. Thomas G. Morton, the pustule was on the palm of the hand. The disease was probably contracted from a bone fertilizer, while the woman was working with a trowel in her flower-garden. A specimen purchased from the same shop at which she had secured the fertilizer,

however, failed to show the presence of the *Bacillus anthracis* upon careful and independent search by Drs. Peckham and Ravenel.

Two sets of lesions are found, depending upon the method of invasion,—whether by the skin or by the mucous membranes:—

I. *External Anthrax*.—(a) *Malignant pustule*. At the site of inoculation there appears a papule which rapidly becomes a vesicle; later a brown eschar is formed, surrounded by small vesicles and an extensive area of brawny induration. The neighboring lymphatics are swollen and hard. (b) *Malignant anthrax œdema*, an extensive œdema affecting the eyelids, the head, the arms, and often the entire upper extremity. It may terminate in gangrene, enteritis, peritonitis, or endocarditis.

II. *Internal Anthrax*.—With this form there is always rapid post-mortem decomposition. Very soon after death the upper extremities, both anteriorly and posteriorly, become dark purple, the nails are blackish blue, and dark chocolate-colored fluids issue from the mouth and nose. (A) THORAX. The cellular tissues of the upper part of the chest are emphysematous and crackle on pressure. On opening the thorax these tissues are often found infiltrated with blood and a gelatinous effusion. (1) The PLEURÆ may contain much serum. (2) The LUNGS are engorged with dark-colored blood. Some portions are œdematous; others harder than when normal, and of a darker red color. (3) The BRONCHIAL GLANDS are swollen, hemorrhagic, and friable. (4) The PERICARDIAL FLUID may be increased to six or eight ounces. The CARDIAC MUSCLE is dark colored, soft, and flabby; the heart may be empty, or may contain dark, semi-fluid blood in all its cavities. The lining membranes of the heart and the larger blood-vessels are stained a color varying from cherry-red to dark chocolate, according to the time that has elapsed since death. (5) The SEROUS MEMBRANES throughout show extravasations of blood; the blood itself being only very slightly coagulated. (B) ABDOMEN. (1) The SMALL INTESTINE and the upper part of the LARGE INTESTINE show lesions consisting of dark brownish-red infiltrated spots (phlegmonous inflammation) about the size of a dime, with a greenish or grayish slough in the centre, which are composed mainly of anthrax bacilli situated chiefly in the lumen of the blood-vessels (Strümpell). There is œdema of all the layers of the gut-wall; the mesenteric nodes are swollen. The peritoneal cavity contains considerable serum, which is frequently blood-stained; or there may be gelatinous œdema. Hemor-

rhages appear in the serous membrane. (2) The LIVER shows less change than any other organ; it may even seem normal to the eye, but microscopically the cells will usually show some form of degeneration. (3) The SPLEEN may be enlarged, swollen, and soft, or normal in size and appearance. (4) The parenchyma of the KIDNEY is gorged with dark blood, and hemorrhages appear in the capsule. (C) Extravasations of blood are discovered between the meninges of the BRAIN and SPINAL CORD, and sometimes small infarcts are found. The capillaries are engorged. (D) *Retropharyngeal abscesses* may be of this origin.

BERIBERI (KAKKE) is an infectious epidemic disease of tropical and subtropical countries, characterized clinically by muscular pains and weakness, disseminated neuritis, cardiac failure, and anasarca, which generally affects the upper extremities, and anatomically by an inflammation of the pyloric end of the stomach, and the duodenum. Little regarding its origin is definitely known. Various micro-organisms have been suggested, Wright considering the organism to belong to the diphtheria group. Overcrowding, a fish diet, and the drinking of arsenical waters seem to predispose to the disease. The stools should be disinfected. Two extreme types of the disease are recognized:—I. The *oedematous* form. II. The *paralytic* or *dry* form.

Lesions.—(A) The axis cylinders and medullary sheaths of the PERIPHERAL NERVES appear to be the seat of a special lesion, which is essentially a parenchymatous neuritis. The nerves are usually swollen and hemorrhagic, but at times appear normal. (B) Atrophy may appear in the STRIATED MUSCLES, in which case they are dry and shining; or the affected muscles, including the heart, are pale, flabby, and fatty. Dangerfield's *Béri-béri* (1905) is the most important recent work on this subject.

CEREBROSPINAL MENINGITIS—EPIDEMIC FORM (SPOTTED FEVER) is an acute infectious disease characterized by an exudative inflammation of the pia mater of the brain and spinal cord. The *Diplococcus intracellularis meningitidis* of Weichselbaum (*Meningococcus*) has been demonstrated in most cases to hold a causative relation to the disease, being possibly introduced into the system by the bedbug, though the nasal route would seem equally probable. During an epidemic, domestic animals, as the goat, should be watched for signs of the disease. The organism may be found in the fluid removed by lumbar puncture, by which method the disease may usually

be distinguished from the tuberculous variety of meningitis, though along with other observers I have found the two conditions associated together. In two fatal cases examined by me there was a history of a fall, though no signs of traumatism were to be found at the autopsy.

Lesions.—(A) In cases where death occurs early, as it sometimes does within twenty-four hours, the meninges of the CENTRAL NERVOUS SYSTEM may show to the naked eye no change save a moderate serous infiltration. In more protracted cases there is a suppurative inflammation, chiefly in the pia mater, with varying amounts of serum, fibrin, and pus. The CEREBRAL CORTEX may be compressed and the convolutions flattened by an accumulation of exudate over the convexity of the brain, in the ventricles, or at the base, the last condition being the most common. In the membranes of the cord, also, the exudate is greatest in amount posteriorly. Minute hemorrhages may be present in the meninges and in the nerve substance of the brain and cord. The CRANIAL NERVES, especially the second, fifth, seventh, and eighth, and the roots of the spinal nerves, are often involved in the inflammatory process. (B) *Pneumonia* is a frequent complication. (C) The NOSE and THROAT may be inflamed, and purulent inflammation of the labyrinth of the EAR may cause deafness. (D) The OPTIC PAPPILLA may be inflamed or atrophied. (E) The SKIN and MUCOUS MEMBRANES may show petechiæ. (F) The VOLUNTARY MUSCLES are apt to undergo hyaline and granular degeneration. (G) The JOINTS may be the seat of abscesses. (H) The PARENCHYMATOUS ORGANS show cloudy swelling, which may go on to fatty degeneration.

CHICKENPOX.—See VARICELLA.

CHOLERA ASIATICA is an acute infectious disease originating in Eastern countries, and is characterized by a profound inflammation of the bowel due to the presence of the exciting cause, a spirochæta, the *Comma bacillus* of Koch, which is a motile, screw-shaped micro-organism, about half the length of a tubercle bacillus, but thicker. (Plate V, no. 5.) It grows readily on artificial media. The bacilli are found in large numbers in the rice-water stools, but rarely in the vomit. The body is thin and shrunken; muscular twitchings are common immediately after death, and the temperature may be elevated. Rigor mortis sets in early and is marked; the extremities are flexed, the fists closed, and the abdomen scaphoid. There is cyanosis of the skin.

Lesions.—I. The ABDOMINAL ORGANS are dry and the PERITONEUM is sticky. (A) The STOMACH may be distended with gas, and superficial hemorrhages may be found in the mucosa. (B) Lesions of the INTESTINES are not characteristic of very acute cases, but the bowel contains large quantities of "rice-water." In more protracted cases the intestine presents a mottled appearance, some areas being hyperæmic and some anæmic, while other places are hypertrophic and ulcerated. The inflammation is well marked in the Peyer's patches. The serous membrane is of a rosy-red color and the blood-vessels are prominent. The large bowel is contracted and empty. An excellent illustration of this condition, taken in 1892 during the cholera epidemic at Hamburg, is to be found in Kast and Rumpel's *Pathologisch-anatomische Tafeln*. Cholera again visited this port in 1905. (C) The MESENTERIC GLANDS are swollen, soft, and of a reddish color. (D) The LIVER shows cloudy swelling, with minute areas of necrosis. (E) The SPLEEN is usually normal, but may be softened. (F) The KIDNEYS are swollen, of a violet hue, and show the changes of acute diffuse nephritis. (G) The CÆLIAC GANGLION is hyperæmic, or even hemorrhagic (Rokitansky). (H) The UTERINE MUCOSA in adult women usually shows hemorrhagic infarcts. II. THORACIC ORGANS. (A) The HEART is flabby; its left side empty as a rule; its right usually distended with tarry blood. (B) The LUNGS are collapsed and show marked congestion at their bases. Pneumonia and pleurisy may be present, and abscesses are not uncommon. There is a decided tendency to the formation of diphtheritic exudate on mucous membranes, particularly in the throat, colon, and genitalia. *Suppurative parotitis* may occur.

CROUPOUS PNEUMONIA.—See PNEUMONIA.

DENGUE is an acute infectious disease, prevalent in our Southern States, and generally known as "break-bone fever."

Lesions.—(a) The JOINTS, large and small, become red and swollen. (b) A cutaneous rash is common, but has no distinctive character. (c) General enlargement of the LYMPHATIC GLANDS is frequent. The disease rarely being fatal, few or no detailed observations regarding the pathologic anatomy are available.

DIPHTHERIA is an acute, infectious, contagious disease, caused by the *Klebs-Löffler bacillus*, and characterized by the formation of a false membrane and by a profound toxæmia. The bacillus is a non-

motile micro-organism (Plate V, no. 6) which, when grown on blood-serum, assumes a great variety of shapes. It is easily cultivated on albuminous media in from twelve to sixteen hours, and is fairly resistant, living for months under favorable conditions. Steam, certain poisons, and many other organisms produce a similar membrane, as the spirillum and fusiform bacillus of Vincent's angina,¹ and the identity of this bacillus with the pseudobacillus of diphtheria, the bacillus of scleroderma, and the organisms of ozæna, noma, etc., is believed by many, but the subject is still *sub judice*. As a rule the micro-organisms do not penetrate below the submucosa at the site of the lesion, but in rare or malignant cases they may be found in the blood, the bladder, and the internal organs. The fact that they are frequently present in the throats of well persons is of great interest. The toxin of the bacillus causes ordinary diphtheria, and to the toxon (another poisonous product, having less affinity for antitoxin than the toxin) is due the marasmus and paresis which sometimes follows. A lethal dose of diphtherial poison is one that is fatal in four or five days to a guinea-pig weighing 250 grammes. (Ehrlich.) Normal poison is a solution containing 100 fatal doses of the diphtherial poison per cubic centimetre (v. Behring), and an immunity-unit (I.-E. of German literature) is equivalent to one cubic centimetre of antitoxin capable of neutralizing one cubic centimetre of the normal poison.²

Lesions.—(a) The false membrane consists of a fibrinous exudate involving the epithelial cells, the whole undergoing coagulation necrosis. It begins early as a slightly raised, opaque, whitish-yellow spot on the mucous membrane, and usually grows rapidly, becoming thicker, of a grayish or greenish hue, and so firmly adherent to the underlying tissues that its removal in the early stages leaves a raw bleeding surface. Later it becomes soft, shreddy, and more easily detached. The diphtheritic patches may become hemorrhagic, the blood infiltrating both the submucous layer and the pseudomembrane, which is then a dirty brown or grayish green. When the submucosa and the surrounding connective tissues become markedly infiltrated the inflammation is said to be phlegmonous. (1) In the NOSE, the diphtheritic membrane, though often slight in extent, may entirely block up the nasopharynx. The inflammation may extend to the accessory sinuses,

¹ *Lancet*, May 13, 1905.

² See OPPENHEIMER, *Toxine and Antitoxine*, Jena, 1904, for a full account of this interesting subject.

the middle ear, or the membranes of the brain. (2) In the PHARYNX, the exudate is usually first seen on the tonsils. It is liable to extend into the mouth, the œsophagus, and even the stomach. Retropharyngeal abscess may result. (3) In the LARYNX, the amount of exudate is often very great. It may entirely occlude the air-passages and extend to the lungs and bronchial tubes, even to those of the third and fourth dimensions, but as it extends it becomes softer and thinner. In this form the pharynx may be entirely free from membrane. (4) *Cutaneous diphtheria* is somewhat less common and the membrane is seldom extensive. It is apt to occur about wounds. (5) Growths may occur on various other mucous membranes, as the CONJUNCTIVA, the VAGINA, in exstrophy of the BLADDER; and also in the EXTERNAL AUDITORY MEATUS. Paralysis may follow diphtheria of the genitalia, even though they alone be affected. (b) LYMPHATIC GLANDS of the neck and often the SALIVARY GLANDS are markedly inflamed, swollen, and softened. (c) *Bronchopneumonia* is apt to occur, small atelectatic areas of the lung being surrounded by zones of inflammation. Should the diphtheritic membrane become gangrenous the process is especially liable to extend to the lung. In such cases Klebs-Löffler bacilli are usually not found, but cocci of various kinds are present. (d) *Endocarditis* and *pericarditis* are extremely rare, but parenchymatous and fatty degenerations of the muscle-fibres are comparatively common. The serous membrane often shows ecchymoses. (e) The KIDNEYS always show more or less diffuse inflammation, which may be hemorrhagic, and albuminuria is the rule. (f) A peripheral parenchymatous *neuritis* is not infrequent. (g) An *enteritis nodularis* is described by Orth, in which the follicles and Peyer's patches are markedly swollen and hyperæmic. Fungoid growths in the œsophagus sometimes occur.

DYSENTERY is an infectious disease endemic in warm countries and sporadic or epidemic in temperate regions; it is characterized by specific ulcerative lesions of the large intestine. The exciting cause of the disease has been much discussed. In certain cases, especially when acute, the short motile bacillus of Chantemesse,¹ an organism resembling both the typhoid bacillus and the colon bacillus, seems to have

¹ Commonly spoken of as the bacillus of SHIGA, although described by CHANTEMESSE and WIDAL in 1888. (*Presse méd.*, July 23, 1902.) For late information on the bacteriology of dysentery, see vol. i of *Studies for the Rockefeller Institute*; and KNOX, *Jr. Amer. Med. Assoc.*, July 18, 1903, and December 17, 1904.

an etiologic significance. Summer diarrhœa of children has also recently been shown to be due to the same organism. The diagnosis may at times be made by the agglutinative reaction. In other cases, especially where chronic, and where abscesses develop, the *Amœba dysentericæ* (the name suggested by Councilman as more distinctive than *Amœba coli* of Lösch) is undoubtedly the exciting cause. This protozoön is found in the glairy, bloody dejecta of dysenteric patients, and also in the contents of complicating abscesses of the liver. Infection is through food and drink, and, some believe, through the air.

Lesions.—(A) The LARGE INTESTINE, especially the flexures and the valvulæ conniventes, is the seat of the characteristic lesion. On the mucosa are seen sharply defined, projecting nodular thickenings of various sizes, in which are cavities filled with a gelatinous pus and communicating with the surface of the mucous membrane by small openings. A number of such ulcers may communicate, forming larger cavities or long sinuous tracts, which undermine the mucosa. They are situated chiefly on the folds of the mucous membrane, and lie transversely to the long axis of the colon. They usually extend through the submucous coat only, but sometimes the muscular coats also become necrotic, and sloughs of tissue are found in the stools. The gelatinous material, consisting of large round swollen cells, red corpuscles, pus-cells, and amœbæ, may be wiped from the surface, leaving the floor of the ulcer clean. The mucous membrane in the neighborhood of the lesion is intensely hyperæmic; the blood-vessels may be thrombosed, interstitial hemorrhages resulting. The intestinal lymph-nodes may be swollen and hyperæmic. In the gangrenous form, destruction is extensive. In more or less chronic cases, the surface of the intestine is of a pale rosy or slate color; the ulcers, in various stages of development, are discrete, with thickened callous edges. The necrotic process may become circumscribed, and the formation of granulation tissue, becoming fibrous, may result in the formation of a bluish pigmented scar. (B) The LIVER may be normal, but in chronic dysentery it is often atrophied, and in acute cases it may be congested and dark red, or sometimes of a dark or pale yellow color. In the gangrenous form, the liver is usually much enlarged, soft, friable, and of a dark color, with numerous small abscesses, probably resulting from microbic embolism, disposed among the capillaries. The true dysenteric abscesses, more common in the non-gangrenous acute and chronic forms, vary in size, and are situated chiefly in the right lobe

of the liver, near the surface, usually directly beneath the capsule, which is slightly thickened at these points. They contain a translucent, viscid fluid, composed of a few pus-cells, red corpuscles, broken-down liver-cells, a quantity of granular fatty matter, and numerous active amœbæ, and have no definite limiting membrane. The solitary large tropical abscess is rarely to be found in acute dysentery. It is more common in subacute or chronic cases terminating in recovery. Usually situated in the right lobe, it is occasionally found in the middle, or in the epigastric lobes of the organ. The contents, which may amount to six pints, are a homogeneous liquid, cream, reddish-yellow, or dark chocolate color—the so-called anchovy sauce—and composed of the same elements as the liquid in the smaller abscesses described above. Such an abscess may rupture externally, or into the lungs, stomach, or intestinal canal. (C) The LUNGS may be the seat of congestion and hypostatic pneumonia. If an hepatic abscess bursts into the lung, secondary abscesses should always be searched for. (D) The KIDNEYS and SPLEEN are usually normal in acute cases, but there may be some congestion and cloudy swelling. In chronic cases they are somewhat atrophied. (E) The BODY appears emaciated after a protracted case. The tissues are bloodless and the muscles are atrophied. There may be œdema of the lower extremities. (F) See also p. 185.

ERYSIPELAS is an acute contagious disease caused by the *Streptococcus* or *Diplococcus erysipelatis*, and is characterized by an inflammation of the skin, which spreads over the surface and may extend to the deeper parts. The micro-organisms gain entrance through a wound or abrasion, and may be found *post mortem* in the lymph-spaces and the zone of spreading inflammation. Most authorities consider the organism identical with the *Streptococcus pyogenes*. The writer is familiar with a case in which a wound received from operating on a case of empyema gave rise to erysipelas.

Lesions.—(A) SKIN. (1) *Erysipelas simplex*. In uncomplicated forms little more than an inflamed œdema is seen. In severe cases the face and scalp are enormously swollen, the eyes are closed, the lips œdematous, and the ears thickened. Blebs and vesicles often appear on the eyelids, ears, and forehead. (2) *Erysipelas ambulans* is that type of the disease characterized by a rapid spreading from one part to another, or by disappearance from one part and appearance elsewhere. (3) *Erysipelas phlegmonosum*. The fluid contents of the

vesicles may become purulent, and thus are formed small cutaneous abscesses about the cheeks, forehead, and neck. Large quantities of pus may accumulate beneath the scalp. The inflammation may extend to the intermuscular fascia, and is then likely to be gangrenous, particularly when following hemorrhagic contusions. This form, besides being the cause of acute purulent œdema, may result in emphysematous inflammation from associated gas-producing germs. (B) The CERVICAL LYMPH GLANDS are enlarged, but this is masked by the œdema. (C) The LUNGS often contain infarcts, usually septic in character. Pleurisy is relatively common. (D) In cases which end fatally, *endocarditis ulcerosa* is particularly frequent, and *septic pericarditis* comparatively so. (E) The KIDNEYS may show septic infarcts. True nephritis is rare, though albuminuria is quite constant. (F) The SPLEEN may be the seat of septic infarction. (G) The LIVER may undergo acute atrophy. (H) *Septicæmia* is not rare.

FOOT-AND-MOUTH DISEASE (STOMATITIS APHTHOSA EPIZOÏTICA) is an acute contagious disease occurring most frequently in cattle and sheep, but found also in persons, who contract it from diseased animals, or through the milk of cows with infected udders. Löffler and Frosch consider it to be due to an organism so minute that it passes through the finest filters and is invisible with the best of our present microscopes. Some recent cases in man have been reported from Rhode Island and Connecticut.

Lesions.—(A) On the LIPS, CHEEKS, or PHARYNGEAL MUCOUS MEMBRANE the characteristic lesion begins as a small vesicle, at first clear, but later grayish. It may also be found on the UDDERS and on the FEET, usually appearing after the eruption in the mouth. When the vesicle reaches a diameter of from one and a half to two centimetres it bursts, leaving a shallow ulcer, with oval, circular, or irregular edges. The affected mucous membranes are inflamed, swollen, and œdematous, and there is a considerable exudate. A colored illustration of the bovine tongue and hoof lesion is seen in Kitt's *Atlas der Thierkrankheiten* (1896). (B) The PARENCHYMATOUS ORGANS show œdema, hemorrhagic infiltrations, and fatty changes.

FRAMBŒSIA (YAWS) is a contagious tropical disease of the skin, presumably of microbial origin, having an indefinite period of incubation and characterized by the presence of dirty or bright red raspberry-like tubercles.

Lesions.—The cutaneous eruption begins as a papule, usually at the site of an old wound. In a few days the papules are scattered over the body; they rapidly enlarge and become tubercles, which are generally circular in shape, and vary in size from that of a pin's head to a small apple. The EPIDERMIS splits or cracks, exposing a raw granulating surface, which rarely ulcerates. A secondary eruption occurs, which is fungoid, monomorphous, and asymmetrical. There are no recorded lesions of the MUCOUS MEMBRANES, the VISCERA, the EYE, or the NERVOUS SYSTEM. Frambœsia is by some supposed to be a modified form of syphilis, and a spirillum has been found which will require further study to classify it.

GLANDERS (EQUINIA) is essentially a chronic necrotic alteration due to the *Corynebacterium mallei*,¹ especially affecting the nasal mucous membranes (glanders proper) and the skin and subcutaneous tissues in the form of nodules (farcy): it occurs most frequently in horses and asses, but may be transmitted to man, as by accidental laboratory inoculation and by hostlers washing themselves with a sponge previously used upon an animal affected with this disease. Mallein (or morvin), which is prepared like tuberculin, contains an endotoxin, having distinct diagnostic, but practically no therapeutic uses. Stalls in which affected animals have been quartered should, after the removal of the carcass, be thoroughly cleansed, disinfected, and then whitewashed. Two forms of the disease are recognized:—

I. *Glanders.*—(A) The mucous membrane of the NOSE and UPPER RESPIRATORY TRACT is most frequently affected. The characteristic lesion is a node or tubercle, which is at first spherical, later becomes flattened, and then breaks down, presenting more or less extensive ulcerations which tend to run together and thus give the part a honey-combed appearance. The mucous membrane is swollen, of a purplish or dark red color, and there is considerable exudate from the ulcerating surfaces. The floor of the ulcers is covered with yellow necrotic tissue. Such ulcers are frequent about the TURBINATED BONES. Chronic glanders usually occurs in the nose, and is often taken for chronic coryza. (B) The LUNGS may become involved by extension, the most prominent lesion being a catarrhal pneumonia, in which the diseased areas show a marked tendency to break down, with the forma-

¹ For a description of this micro-organism, see p. 386.

tion of abscesses, though calcification sometimes takes place.¹ (C) An eruption of papules, which soon become pustular, frequently appears upon the FACE and about the JOINTS. Caseous nodes and patches of suppuration are sometimes found in the PERIOSTEUM and the SYNOVIAL MEMBRANES. (D) The CERVICAL GLANDS are usually much enlarged. (E) The GASTROCNEMII sometimes contain a dirty yellow, pasty mass of pus, probably due to glanders.

II. *Farcy*.—(a) The *acute form* is of the nature of a phlegmonous inflammation at the point of inoculation. The process may be very extensive, leading to rapid suppuration of the surrounding parts, and subcutaneous enlargements ("farcy buds") along the course of the lymphatics. Metastasis to the surrounding tissues is common, accompanied by the formation of abscesses in the muscles. (b) In *chronic farcy*, localized tumors are found in the skin, the subcutaneous tissue, and the muscles. These tumors result in abscesses, and may form deep ulcers.

GLANDULAR FEVER is an acute infectious disease of childhood, occurring between the ages of one and ten years, and bacterial in origin. It is rarely fatal.

Lesions.—(A) Marked enlargement and softening of the CERVICAL LYMPHATIC GLANDS is characteristic. Suppuration seldom occurs, and the adjacent skin and mucous membrane show no marked changes. (B) The THROAT may be congested and the TONSILS are usually swollen. (C) The SPLEEN, LIVER, and even the MESENTERIC GLANDS are at times enlarged; and in some cases the AXILLARY and INGUINAL GLANDS are involved.

GONORRŒA is a specific infectious disease, characterized by an exudative inflammation, and due to the presence of the *Gonococcus* of Neisser (1879). (Plate V, no. 1.)

Lesions.—(a) In *general infection* the organism has been found in the blood, which after death may be fluid or semi-fluid, and tarry-black in color. (b) *Local infection* produces in the male *urethritis*, *periurethral abscesses*, *prostatitis*, *proctitis*, etc., while in the female may be found *vaginitis*, *endocervicitis*, inflammation of the Bartholinian glands, *metritis*, *salpingitis*, *ovaritis*, *peritonitis*, *cystitis*, *pyelitis*, etc. (c) *Arthritis* (gonorrhœal rheumatism) may occur; it is a synovitis which rarely becomes purulent. The inflammation is acute,

¹ CATTELL, *Trans. Phila. Path. Soc.*, 1893-95, vol. xvii, p. 253.

periarticular, affects several joints, and extends along the sheaths of the tendons. (*d*) *Conjunctivitis* is not rare. It occurs most frequently in the new-born, leads to thickening and ulceration of the conjunctivæ, and may give rise later on to various forms of internal infection. Erosions or entire destruction of the cornea may result. The skin of the lids may be destroyed. *Iritis* sometimes occurs. (*e*) An acute form of single or ulcerative *endocarditis* occurs, from which pure cultures of the *Gonococcus* have been made. At times, *pericarditis* and *myocarditis* have been reported, and rarely *pleurisy*. All these lesions show a marked tendency to suppurative change.

HYDROPHOBIA (LYSSA, RABIES) is an acute disease communicated only by direct inoculation, the toxins of which by their action on the higher nervous centres produce the characteristic convulsions. Negri,¹ of the University of Pavia, has described certain bodies found in the brain, spinal cord, and ganglia of animals dead of hydrophobia. He believes, and his work has been confirmed by other Italian investigators, that these bodies are parasites, probably protozoa, and that they have an etiologic relation to hydrophobia, though he admits that this has not been proved. Other investigators describe a bacillus as the cause of rabies. Pasteur treatment may now be had throughout the civilized world, it having been found practicable to convey the inoculating material a long distance.

When a dog that is supposed to be mad has bitten a human being, the animal should not be killed at once, but should be permitted to live and kept under close observation until sufficient time has elapsed to permit unmistakable signs of rabies to develop, if such be present. The dog is then killed and its body sent to a competent bacteriologist for microscopic study and inoculation experiments on rabbits. While the recent so-called rapid method of diagnosing rabies is not absolutely characteristic of the disease, it affords a most valuable early means of tentative diagnosis, to be confirmed or disproved by subsequent animal inoculation. The method employed is that of Babès, van Gehuchten, and Nélis, and is as follows:² Several intervertebral ganglia or a portion of the bulb are put at once into absolute alcohol, in which they are left for twenty-four hours. They are then transferred for one hour to a mixture of absolute alcohol and chloroform,

¹ *Zeitschr. f. Hyg. u. Inf. Krank.*, vol. xlv, no. 3.

² RAVENEL and MCCARTHY, *Proc. Path. Soc. Phila.*, 1901, p. 93.

next put for one hour into pure chloroform, then for one hour into a mixture of chloroform and paraffin, and lastly for an hour into pure paraffin. The sections are put in the oven for a few minutes, then passed through xylol, absolute alcohol, and ninety per cent. alcohol, after which they are stained for five minutes in methylen blue, according to Nissl's formula, differentiated in ninety per cent. alcohol, dehydrated in absolute alcohol, and cleared in essence of cajuput and xylol. Other methods of preparing the tissues may be used, such as rapid fixation with ten per cent. formalin, subsequent freezing, and staining with hæmatoxylin and eosin. The microscopic changes are chromatolytic and capsular. The "rabie tubercle" of Babès consists in the pericellular accumulations of the embryonal cells described by Kolesnikoff. The prolongations of the cells of the bulbar nuclei are shortened, the nuclei are altered or even obliterated, and the nerve-cells are invaded by the embryonal cells and small corpuscular elements. Atrophy, invasion, and destruction of the nerve-cells of the intervertebral and plexiform ganglia of the pneumogastric take place by cells newly formed from the capsule, which appear between the cell body and its endothelial capsule; in advanced cases the field even resembles an alveolar sarcoma.

Lesions.—(A) The CEREBROSPINAL SYSTEM shows congestion of the blood-vessels, and minute hemorrhages, most numerous in the medulla. (B) The PHARYNX, LARYNX, TRACHEA, larger BRONCHI, LUNGS, ŒSOPHAGUS, and STOMACH show the mucous membrane congested, and not infrequently covered with blood-stained mucus. (C) The virus has been shown by experiments to exist abundantly in the SPINAL CORD, BRAIN, and PERIPHERAL NERVES, but it has not been found in the LIVER, SPLEEN, and KIDNEYS.

INFLUENZA (GRIPPE) is an acute contagious epidemic disease, due to a bacillus, discovered by Pfeiffer in 1892, and is characterized by abrupt onset, great depression, and many sequelæ. The *Bacillus influenzae* is found especially in the nasal and bronchial secretions, but may be present in discharges from the conjunctiva, ear, etc. It is one of the smallest organisms known, non-motile, aërobic, and stains well with Löffler's methylen blue. On culture media it grows best in the presence of hæmoglobin, and of certain other organisms (symbiosis). It shows polar staining by one to ten solution of carbol fuchsin.

Lesions.—I. *Respiratory form.*—An acute inflammation of the mucous membrane of the UPPER RESPIRATORY TRACT and the BRON-

CHIAL TUBES takes place. Lobular pneumonia is common, and is probably due to a mixed infection. Pleurisy is more rare, but may occur and lead to empyema. Tuberculosis is apt to be exaggerated by an attack of influenza; and diffuse bronchiectasis has followed it. In some epidemics, accumulations of pus in the nasopharynx are exceedingly common.

II. *Gastro-intestinal form*.—The inflammation extends to the mucous membrane of the STOMACH and INTESTINES. It is seldom of a severe type. The SPLEEN is usually enlarged. The recent large number of cases of appendicitis is attributed by some to the widespread prevalence of this disorder.

III. *Nervous form*.—Mild degrees of *meningitis* and *encephalitis* are not uncommon. Abscesses of the brain have occurred in severe acute cases.

Complications.—(a) Acute *diffuse nephritis* is quite frequent. (b) *Orchitis*. (c) *Endocarditis*, *pericarditis*, and *thrombosis* have been reported. (d) Occasionally *purpura* and *herpes* are seen. (e) *Iritis* and *catarrhal conjunctivitis* may occur.

In an autopsy on a child dying from meningitis following the gripe, Dr. Kneass in 1895 isolated for me the influenza bacillus.

LEPROSY is a chronic infectious disease due to the leprosy bacillus, and is characterized by the formation of nodes or nodules, and by degenerative changes in the nerves. The *Mycobacterium lepræ* morphologically resembles the bacillus of tuberculosis. It stains more readily, however, is more easily decolorized, and is present in far greater numbers in the lesions which it causes. Van Houtum¹ claims to have cultivated this organism successfully, while several investigators have recently given promising reports of the discovery of a curative serum. The organisms have been found in mosquitoes and fleas. That leprosy may be cured, so far at least as to check the advance of the lesions, is now an established fact. Hutchinson claims that the disease is contracted from fish.

Lesions.—I. *Tubercular form*.—(A) The primary lesion is found most frequently in the skin of the FACE, and on the surfaces of the KNEES, the ELBOWS, the HANDS, and the FEET. It starts as a small red spot in the corium, which may become pigmented or colorless, and which either disappears or gives rise to the formation of inflammatory

¹ *Journal of Pathology and Bacteriology*, September, 1902, p. 260.

nodules, somewhat soft in consistency, and of a brownish-red color, resembling a strawberry. This form of the disease is apt to be exceedingly chronic, the surrounding tissues showing marked fibroid changes. The tubercles at times become swollen through fatty disintegration. Extensive ulceration is common, and pigment-spots often occur on the face. (B) The CONJUNCTIVÆ and other mucous membranes, particularly of the NOSE, the CORNEA, and the LARYNX, may be similarly involved. (C) The LYMPH GLANDS are hard, swollen, and yellow. (D) *Nephritis* occurs. (E) The LIVER, SPLEEN, and TESTES show hyperplasia of the connective tissue.

II. *Anæsthetic form*.—(A) The PERIPHERAL NERVES are gradually involved by the leprous process, which first causes a perineuritis, then obliteration of nerve-tissue, and necrosis and ulceration. Extensive loss of substance occurs, as of fingers, toes, or even of limbs. There is great loss of hair, and the face often becomes markedly deformed by the ravages of the disease. (B) The involvement of the LARYNX, or aspiration pneumonia, often causes death. (C) The infection of the SPLEEN is shown by the presence of large ovoid mononuclear cells, usually vacuolated and containing many of the bacilli. (D) The BONE-MARROW is often the seat of granulomatous foci containing bacilli. Ulceration of the soft parts and necrosis and osteomyelitis of the underlying bone may occur.

MALTA FEVER (MEDITERRANEAN or UNDULANT FEVER) is a chronic disease, resembling in its clinical course typhoid fever and malaria; it occurs most frequently in the Mediterranean region. It is due to the *Micrococcus melitensis*, which organism may be isolated from the urine and the blood. It would seem to be introduced into man, at times, by goat's milk. Young and previously healthy adults who are unacclimated are most frequently attacked, and British garrisons suffer seriously from the disease. It occurs in our new possessions, and soldiers and sailors returning home may bring the affection with them. The agglutinative reaction can be obtained with the micrococcus and the blood of a patient affected with the disease.

Lesions.—The visceral changes are those common to all infectious diseases exhibiting high temperature. (A) The SMALL INTESTINE is usually anæmic except in the upper part, where it may be intensely congested. The MESENTERIC GLANDS show little change. (B) The SPLEEN is much enlarged and is dark in color; its pulp is soft and friable, and sections show an increase in the lymphoid elements. The

average weight in such case is eighteen ounces. The micrococci are found in large numbers in the organ. (C) The LIVER is congested, and its surface on section is pigmented. (D) The KIDNEYS are usually congested, and may be slightly hemorrhagic.

Sequelæ.—Swelling of the joints, *anæmia*, *orchitis*, and *neuralgia*.

MEASLES (MORBILLI, RUBEOLA) is a markedly contagious disease, attended with a skin eruption and with catarrh of the mucous membranes. It is due to a micro-organism, the identity of which is not yet definitely settled. Lesage, Canon and Pielicke, Czajkowski, and others have described organisms as causes of the disease. This affection, as well as scarlet fever and German measles, must be distinguished from Duke's fourth disease, which has characteristics common to all three disorders, and from erythema infectiosum, recently brought to our attention anew by Shaw. There has been recently described a so-called "fifth disease."

Lesions, chiefly those of its complications and sequelæ.—(A) The SKIN, especially about the face, may be swollen and slightly œdematous, and may show the remains of the characteristic rash, especially in the hemorrhagic type. Desquamation, when present, is in the form of fine branny scales. (B) The LUNGS show evidence of bronchitis, and almost invariably lesions of bronchopneumonia, with areas of collapse; less frequently lobar pneumonia may be found. The BRONCHIAL GLANDS are swollen. Pleurisy is less common. (C) The GASTRO-INTESTINAL MUCOSA is usually hyperæmic. Peyer's patches are frequently swollen, sometimes markedly so. Colitis may occur. (D) Severe *stomatitis*, *cancrem oris*, ulcerative *vulvitis*, or gangrene of the genitalia may develop in debilitated infants. (E) *Laryngitis*, severe *angina*, *diphtheria*, and *rheumatism* sometimes complicate measles.¹ (F) In the MIDDLE EAR catarrhal inflammation, which may go on to abscess formation and perforation, is not uncommon.

Sequelæ.—(a) *Tuberculosis*, either caseous or miliary, is the most important of the sequelæ. (b) Severe forms of *conjunctivitis* and ulcer of the cornea are not uncommon. (c) Cloudy swelling of the organs. (d) *Nephritis* and *arthritis* are exceedingly rare. (e) *Disseminated sclerosis* is rare.

MUMPS (PAROTITIS) is an acute, infectious, contagious disease, probably due to a diplococcus or a diplobacillus, and characterized by

¹ *Medical Record*, June 17, 1902.

a marked cellular infiltration of the parotid glands, with metastases to the OVARIES and MAMMARY GLANDS in females, and to the TESTICLES in males. It occurs chiefly in childhood or adolescence. Adults or very young infants are seldom attacked. Uncomplicated mumps is rarely fatal.

Lesions.—(A) The PAROTID GLANDS are markedly enlarged, but have no tendency to suppurate or to become fibroid. (B) *Orchitis* occurs before puberty, but rarely. In such cases a mucopurulent discharge is often seen in the urethra. Atrophy and imperfect development may follow. (C) *Vulvovaginitis* may occur in girls, and cases of resulting atresia of the vagina have been reported.

Complications.—*Meningitis*, acute mania, *endocarditis*, *gangrene*, and *optic atrophy* are the most important. *Arthritis* and chronic hypertrophy of the affected glands have occurred.

PARATYPHOID FEVER.—See p. 181.

PERTUSSIS (WHOOPIING-COUGH) is an infectious disease characterized by a convulsive cough ending in a long inspiration, often followed by spasmodic expirations. Koplik believes the disease to be due to a small bacillus.

Lesions, which are, however, not characteristic.—(A) Catarrhal inflammation of the entire RESPIRATORY TRACT is often found. The bronchial glands are enlarged. (B) The EYES may be injected, or there may be distinct ecchymosis. (C) On the FOREHEAD petechiæ may appear. (D) *Anæmia* is common. (E) An ulcer under the TONGUE is often found.

Complications.—The most important are *subdural hemorrhage*, pulmonary *emphysema*, *pneumothorax*, and *bronchopneumonia*, which is usually tuberculous.

PLAGUE¹ is an acute, infectious, contagious, epidemic disease, due to the *Bacillus pestis*. It occurs usually in the Far East, where in India alone one million persons are now dying annually from the disease, but is at present (1906) widely distributed over the earth's surface. In the East a heavy rat mortality is the precursor of the disease. The epizootic arises at the season of the year when young rats are most numerous, which being bitten by fleas, especially the

¹ The bacteriology, morbid anatomy, histopathology, and literature of plague are well considered in Herzog's article issued by the U. S. Government, Dept. of the Interior, Manila, October, 1904, and in Simpson's work (1905), Cambridge. Both volumes are illustrated.

Pulex chcopis, infected with the bacillus, give rise to the disease. Cats show a septicæmic form of plague.¹ The bacillus was discovered independently by Kitasato and Yersin. It is a short rod with rounded ends, and is found in the blood, glands, viscera, fæces, and urine.

Plague is characterized by marked glandular enlargements which tend to suppuration, and by a general septic condition, hemorrhage, and carbuncles. Plague must be distinguished from puerperal fever, septicæmia, pyæmia, smallpox, influenza, cerebrospinal meningitis, diphtheria, erysipelas, measles, gonorrhœa, syphilis, mumps, malaria, scrofulous glands, Hodgkin's disease, etc. In a case (1901) of a Philadelphia Chinaman suspected of having the plague, the writer found almost complete occlusion of the prepuce, with a discharge containing the *Gonococcus*, and in the suppurating bubo a fat diplobacillus which did not stain by Gram's method.

Lesions.—I. At the point of inoculation, which is usually on the lower limbs, there may appear a small spot (*plague corpuscle*) which soon becomes a vesicle and then a pustule. II. In the *bubonic form*, the **INGUINAL GLANDS** become swollen following the primary inoculation, succeeded in order by swelling of the **AXILLARY**, **CERVICAL**, **POPLITEAL**, and other **GLANDS** in the body. The diseased glands swell rapidly and are at first tense and firm to the touch, but soon undergo a suppurative change; in rare cases gangrene ensues. It is the **PERIGLANDULAR TISSUE** that becomes œdematous and undergoes septic inflammation. Hossack found no buboes in thirty per cent. of his cases in Calcutta in 1900. III. In the *carbuncular form*, carbuncles may develop in the skin of the **LEGS**, **LIPS**, and **BACK**. Subcutaneous hemorrhages are very common, and hemorrhages may also occur in the **MUCOUS MEMBRANES**. IV. In the *meningeal form*, the **CENTRAL NERVOUS SYSTEM**, especially the brain, is deeply congested. The cerebral substance may become softened, and the **BLOOD-VESSELS**, especially the veins, are engorged. V. In the *pneumonic form*, the **LUNGS** are deeply congested, especially posteriorly, and are at times the primary seat of the disease. VI. In the *septic form*, the **PERICARDIUM** contains an excess of blood-stained fluid. The right **HEART** is dilated with black, imperfectly coagulated blood, and the whole venous system is engorged. The **HEART-MUSCLE** is pale and somewhat softened. VII. In the *intestinal form*, the **STOMACH** and **SMALL**

¹ *Lancet*, April 22, 1905.

INTESTINE contain blood or blood-stained fluid. There may be ulceration, but the Peyer's patches are not affected. The SPLEEN is greatly enlarged in all cases. VIII. The dorsum of the TONGUE is coated, but the edges, the tip, and often the median raphe remain pink and clean, sometimes, however, becoming red and dry. (Hossack.)

PNEUMONIA (PNEUMONITIS), except when qualified by a proper descriptive adjective, is an indefinite term applied to various inflammations of the lung tissue, the organisms especially concerned being the *Diplococcus pneumoniae* of Fränkel, the *Bacillus pneumoniae* of Friedländer, the *B. tuberculosis*, *Actinomyces*, *B. influenzae*, *B. pestis*, *Corynebacterium diphtheriae*, *B. typhosus*, *B. coli communis*, *Micrococcus catarrhalis*, *Streptococcus pyogenes*, *Staphylococcus pyogenes*, and the virus of syphilis. A special pneumonia commission in America is trying at the present time to elucidate some of the most difficult problems of pathology by a painstaking study of pneumonia.

Croupous (lobar or acute) pneumonia is an infectious and mildly contagious general disease occurring with a sudden onset, in which solidification of pulmonary tissue takes place as a localizing lesion. Osler considers the mortality to be one in four persons affected. It is due in most cases to the *Diplococcus pneumoniae* (*Pneumococcus*), less frequently to the *Bacillus pneumoniae* and *Aspergillus bronchialis*, and is characterized by an exudative inflammation of the whole or part of one or both lungs, the right lower lobe being most frequently affected, and by a more or less profound toxæmia. Males are more frequently affected than females. The *Pneumococcus*, shown by Sternberg to be normally present in a large proportion of healthy persons in mouth, nose, and pharynx, readily demonstrated in cover-glass preparations stained by Gram's method, is found in the bronchial secretions and in sections of the affected lung, in pairs surrounded by a lanceolate capsule. For differentiating from streptococci it should be grown on agar plates containing blood. Mice have recently been considered as one of the sources of this disease.

Lesions.—(A) LUNGS. The pathologic findings show three distinct stages: (1) The stage of *engorgement*, which lasts about twenty-four hours. The lungs are heavier, firmer, more solid, and redder than normal. They still crepitate, though not so distinctly as does healthy tissue. The cut section exudes a frothy serum, and will partially float. (2) The stage of *red hepatisation*, which lasts from one to four days. The affected lobe (or lobes) is larger, heavier, and firmer

than normal, and is of a deep red color. It is airless, does not collapse on exposure to the atmosphere, and excised portions sink in water. If such a lung be examined several days after its removal from the body, the appearance is changed by autolysis to that of the third stage, or even signs of apparent resolution may present themselves. On section the lung is dry, reddish brown, and exceedingly friable. Careful inspection shows that the cut surface is distinctly granular, due to fibrinous plugs in the smaller bronchi and blood-vessels, which are lighter in color than the intensely red tissue, and which can be scraped off with a knife, together with a reddish viscid serum. Such fibrinous masses may extend into the larger tubes and thus form perfect casts. The bronchi may contain a mucous secretion tinged with blood, or more rarely the tenacious mucus so characteristic of pneumonic sputum. The microscope reveals in the alveolar meshes fibrinous threads, epithelial cells which have undergone hyaline and necrotic changes, leucocytes, red blood-cells, micro-organisms, etc. Sections taken from the central portion of the lung show more cellular elements, while those from the surface are richer in fibrin, showing that the infection probably takes place from the bronchi. The pleural surface of the lung is covered with a more or less extensive layer of fibrin,—the so-called bread-and-butter pleurisy,—which forms a false membrane that contrasts markedly with the smooth shiny appearance of the unaffected portions of the lung. The surface may retain the impressions of the ribs. In this connection it is well to remember that there is a pneumonic form of plague and of several other infectious fevers. (3) In the stage of *gray hepatization* the color varies from a reddish brown to a grayish white, grayish yellow, or greenish tint. The surface is more moist, the exudate more turbid, the granules less distinct, and the pulmonary tissue still more friable. The exudate is softened, and the *Pneumococcus* is usually no longer to be demonstrated. The cell-elements are disintegrated and prepared for absorption. Gray and red hepatization may coexist in the same lobe, giving a mottled appearance to the cut surface. The process may terminate in (1) liquefaction, absorption, and resolution; (2) suppuration, the lung being then an airless, firm, regular gray or red mass; abscesses should always be examined for the tubercle bacillus; (3) gangrene; (4) fibroid changes or carnification.¹ (B) The BRONCHIAL GLANDS are swollen, soft, and hemor-

¹For comparison of the lung changes in croupous and catarrhal pneumonia, see p. 157.

rhagic, and there may be œdema of the mediastinal tissues. (C) The overlying PLEURA is inflamed, with more or less extensive exudate, which may be serous, fibrinous, or more rarely purulent. (D) The HEART shows the left cavities nearly or quite empty, the right distended with firm, tenacious coagula. Pericarditis is not infrequent with left-sided pneumonia, and is most common in children. Endocarditis is more common, and may be malignant and associated with meningitis. Myocarditis is rare. (E) The SPLEEN is enlarged in many cases. (F) The KIDNEYS and LIVER show cloudy swelling or acute parenchymatous changes. The hepatic veins are often engorged.

Complications.—*Otitis media, conjunctivitis, and arthritis* are not unusual in children. Severe and often fatal *toxæmia* may develop with a comparatively slight lesion in the lung. *Orchitis, purulent synovitis, jaundice, croupous gastritis, colitis, meningitis, endocarditis, empyema, and peritonitis* may also occur.

PYÆMIA and SEPTICÆMIA are systemic hæmatogenous infections characterized by the distribution of pyogenic organisms and their toxins. The occurrence of thrombosis, followed by the separation of infectious emboli and by abscess formation in various parts of the body, are the distinctive features of pyæmia. The organisms gain entrance to the circulation from any infected wound; the point of introduction may, however, be quite undetermined. The post-mortem appearances vary, as there may even be absence of gross lesions.

Lesions.—Rapid post-mortem decomposition is the rule. Congestion of all the organs, passive hemorrhages, and enlargement of the SPLEEN and of the INTESTINAL LYMPH GLANDS may occur. Purulent inflammation of serous membranes, and of the tissues about joints, is sometimes found.

RELAPSING FEVER is an acute epidemic contagious disease due to the *Spirochæta obermeieri*, and is characterized by paroxysms of fever followed by remissions and relapses. The disease disappeared in 1869 to reappear in 1905. The specific organisms, which may reach 40 microns in length, are exceedingly motile, and are found in the blood only during the paroxysms of fever, retreating later to the spleen and other blood-making organs. Transmission would seem to take place especially by the bite of the bedbug, in which insect the organisms may remain alive for several weeks. Monkeys are capable of inoculation with the disease. The organisms are rarely found *post mortem*. Geese, chickens, and cattle at times have a somewhat similar affection.

Lesions, which are not characteristic or constant.—(A) The SKIN and TISSUES are frequently jaundiced. (B) The SPLEEN, if death occurs during the paroxysm, is large and soft, and the pulp is purple. At times it may appear variegated on section, due to the areas of necrosis and fatty degeneration. Infarcts are not uncommon. The follicles are enlarged and often obliterated, though they may be gray or whitish yellow in color. (C) The HEART is flabby, of a pale dirty-gray color, and very friable. (D) The LIVER is more acutely enlarged in this than in any other infectious fever. Its color is a uniform gray-red. Fatty degeneration may be marked. (E) The KIDNEYS may retain their normal weight. The renal parenchyma is soft and flabby; the cortical substance is increased and shows cloudy swelling. Hemorrhagic spots or lines radiating to the pyramids are often observed. (F) The LUNGS may be the seat of pneumonic infiltration, bronchitis, or bronchiectasis. (G) The STOMACH and BILE DUCTS show catarrhal inflammation. (H) Hyperplasia of the BONE-MARROW has been found.

Complications.—*Pneumonia* is frequent. Rupture of the spleen, *nephritis* and *hæmaturia*, and in certain epidemics *ophthalmia*, may occur. Abortion usually takes place. (Osler.)

RHEUMATISM is a disease which occurs subsequent to exposure, or to indiscretions in diet, and has been variously regarded as due to a *Diplococcus rheumaticus* (London Pathological Society), attenuated cultures of *Staphylococcus aureus*, and a bacillus.

I. *Acute form*.—*Lesions*.—(A) The affected joints are swollen, tense to the touch, and somewhat hyperæmic. The fluid in the JOINT is turbid, and contains albumin, leucocytes, and a few flakes of fibrin, but rarely pus. There may be slight erosion of the cartilages. (B) On the FINGERS, HANDS, and WRISTS are found rheumatic nodules, varying in size from a small shot to a large pea. They may also occur about the ELBOWS, KNEES, spines of the VERTEBRÆ, and SCAPULÆ.

Sequelæ and complications.—(a) *Endocarditis* occurs in about sixty per cent. of all cases. The verrucose variety is most common, and the mitral valve is most often involved. (b) *Pericarditis* may occur, with or without endocarditis. It may be fibrinous, serofibrinous, or, in children, purulent. (c) *Myocarditis* occurs most frequently in association with endopericarditis. It leads to weakening and dilatation of the heart-muscle, and is the most common cause of sudden death in rheumatic fever. (d) *Pleurisy* and *pneumonia* occur in about ten

per cent. of all cases. (*c*) *Meningitis* is extremely rare. (*f*) *Purpura* may be present. (*g*) *Anæmia* is one of the most common sequelæ. (*h*) *Iritis*, *tonsillitis*, *pharyngitis*, and *nephritis* occur.

II. *Chronic form*.—*Lesions*.—(*A*) The SYNOVIAL MEMBRANES are injected. There is usually not much effusion. The capsules, ligaments, and sheaths of the TENDONS are thickened. There may be erosion of the cartilages. As a result of these changes, the JOINTS are often deformed and ankylosis may occur. (*B*) Atrophy of the MUSCLES, especially about the joints, frequently follows. (*C*) Valvular lesions of the HEART, due to sclerotic changes, are of common occurrence.

RUBELLA (RÖTHELN, GERMAN MEASLES) is an infectious disease usually attacking adults, and rarely fatal in uncomplicated cases.

Lesions.—(*A*) The rash on the SKIN is the only distinctive lesion, and this may fade entirely after death. The skin may be slightly stained after the eruption. (*B*) LYMPH GLANDS are usually swollen, especially those of the neck.

Complications.—*Pneumonia* and *colitis* occur, but rarely.

SCARLET FEVER is an acute infectious disease, characterized by a more or less severe angina, a scarlet punctate rash, and febrile symptoms. The majority of cases occur before the tenth year, although adults are not exempt. F. B. Mallory¹ describes a protozoön found during the disease in the epithelial cells of the skin, tongue, and superficial lymph-vessels, and the spaces of the corium. It has never been found alone, but always associated with streptococci. Cocci are frequently found in the throat lesions and in the blood. Class, of Chicago, claims to have isolated a specific coccus, which has also been described by Baginsky.

Lesions.—(*A*) *Rigor mortis* is usually well marked, and decomposition may set in early and develop with exceptional rapidity, cadaveric lividity usually appearing before death. (*B*) The BLOOD is dark in color, thin, and coagulates imperfectly. The vessel walls are usually stained. (*C*) The SKIN rarely shows after death a trace of the rash, except in the hemorrhagic form. (*D*) In the THROAT follicular tonsillitis, diphtheritic membrane, or suppuration may be present. Punctate hemorrhages, especially about the MOUTH, are always observed. (*E*) In the GASTRO-INTESTINAL TRACT catarrhal inflammation of the

¹ MALLORY, *Jr. Med. Research*, 1904, vol. x.

mucous membrane is not uncommon. The follicles of the small intestine are swollen, red, and may even be hemorrhagic. (F) Intense lymphadenitis with much inflammatory œdema is found in the NECK in severe cases. This may lead to suppuration or even gangrene, and, in rare cases, to ulceration of the carotid artery and fatal hemorrhage. (G) The KIDNEY lesions are most important. Acute diffuse nephritis is present in a majority of cases. It is frequently of the glomerular type and may be hemorrhagic. This lesion is not infrequently followed by the changes observed in chronic parenchymatous nephritis. The toxin seems to act especially and quickly on the epithelial cells of the kidney. In one of my cases, death in convulsions occurred twenty-four hours after the onset of vomiting, and without the appearance of any rash. The diagnosis was confirmed by the fact that a sister was subsequently attacked by the disease. (H) *Endocarditis*, which may be either simple or malignant, is not infrequent. *Pericarditis* and *myocardial* changes are less common. (I) The SPLEEN is often enlarged, and shows the changes which characterize acute splenic tumor. (J) Hemorrhages into the subserous tissues beneath the PERICARDIUM, ENDOCARDIUM, and PLEURA are quite frequent. There is more or less cloudy swelling of all the organs.

Complications.—(a) *Nephritis* is the most important. The urine is small in quantity, has a high specific gravity, is cloudy, and is of a dark blood-color. It contains a large amount of albumin, free blood, and epithelial cells, with hyaline and epithelial tube-casts. Œdema may be slight or marked; in a few cases œdema of the glottis has caused sudden death. (b) Heart complications are next in importance. There may be *endocarditis*, *pericarditis*, or *myocarditis*. (c) *Catarrhal pneumonia*, more rarely *croupous pneumonia*, or *pleurisy* may occur. (d) Middle-ear involvement may lead to *thrombosis* of the lateral sinus, *meningitis*, abscess of the brain, or *necrosis* of the middle ear *en masse*. (e) *Adenitis* may result, involving most frequently the glands of the neck. There may be great destruction and loss of tissue. *Retropharyngeal abscess* is not uncommon. (f) *Arthritis* of a rheumatic type, or more closely resembling the gonorrhœal variety, may be found. In the latter affection, only one joint is involved and suppuration may supervene. (g) *Gangrene* of the legs, and *noma* have followed scarlet fever.

SCLERODERMA is an acute or chronic disease due to an organism of the type of the *Bacillus pneumoniae* and like the one found in *ozæna*,

and is characterized by a localized or general indurated or "hide-bound" condition of the skin.

Lesions.—(a) In the *circumscribed form*, hard and inelastic patches, varying in size, and of a waxy or dead-white appearance, are found on the skin. (b) In the *diffuse form*, which usually occurs on the face or extremities, a diffuse, brawny induration gradually develops. The skin becomes firm, hard, and so closely united to the subcutaneous tissue that it cannot be picked up or pinched. It is commonly glossy, drier than normal, and unusually smooth. The color may be natural.

SMALLPOX is an acute infectious febrile disease, distinguished by a peculiar odor and a characteristic eruption which is at first papular, then becomes vesicular, and finally pustulate. It is seen most often among the improperly vaccinated in over-crowded districts during fall and winter. Councilman has announced (1903) the presence of a protozoön¹ in the skin lesion at the papular stage of the disease, thus confirming the work of Guarnieri with the *Cytorrhycles variolæ*. This discovery has been confirmed by Calkins (1904) and others, but is not yet fully accepted. *Streptococci* are always found in the pustules, and this infection may be severe. Stokes² thinks that the primary infection in smallpox takes place in the lungs, probably by inhalation. The serious and fatal lesions are, however, usually due to secondary infection by the *Streptococcus pyogenes* from the skin and respiratory tract, and to this are due the visceral changes, such as thrombosis, local necrosis, and the various pulmonary lesions. The physician should always vaccinate himself both before and after making an autopsy on a smallpox case. Frazer³ reports a case of oyster poisoning which closely simulated smallpox in its rash and its general symptoms. During the Civil War croton oil was at times rubbed on the skin to produce a rash simulating smallpox.

Lesions.—(A) The SKIN is the seat of a rash which appears first on the forehead and wrists as shot-like papules, progressing to umbilicated vesicles, pustules, and crusts. The epidermis of the hands and

¹ See ZIEGLER'S *General Pathology*, translation by CATTELL, 1895, p. 39: "It is not impossible that other infectious diseases—for instance, smallpox—are caused by parasites that belong among the protozoa." Councilman's latest paper on this subject is to be found in *Amer. Med.*, October 21, 1905.

² *Johns Hopkins Bull.*, August, 1903.

³ *Medical Record*, September 2, 1902.

feet may be shed entire. The skin may be plum-colored, and the face swollen. (B) On the MUCOUS MEMBRANES from the mouth to the rectum the rash may also be found, but on account of the moisture the pocks are not quite so characteristic in these situations as upon the skin. (C) The LARYNX, TRACHEA, and BRONCHI show in some cases deep ulcerations. In the larynx a fibrinous exudate is almost always found, and at times œdema; and necrosis of the cartilages may follow. (D) Swelling of the Peyer's patches is not uncommon. (E) The VAGINA may show the eruption. The SPLEEN as a rule is markedly enlarged, but it may be small, very dark, and firm. (F) The LIVER shows evidence of parenchymatous inflammation and fatty degeneration, and there may be small areas of necrosis. (G) The HEART is flabby and pale. The myocardium shows cloudy swelling and fatty degeneration; it is often dark brown in color, and may be firm to the touch. The cavities contain little or no clotted blood, and the arterial trunks are nearly empty. (H) KIDNEY lesions are not common. There may be cloudy swelling and areas of focal necrosis. The PELVIS may be blocked with dark clots which sometimes extend into the URETERS. (I) In pregnant women *abortion* almost invariably occurs. In some cases the fœtus shows evidence of the disease, in others none; and cases have been reported where the fœtus had lesions while the mother had no evidence of illness.¹ (J) In *black smallpox*, the hemorrhagic form of the disease, there may be found hemorrhages on all the mucous and serous membranes, and in the joints, the parenchyma of organs, the connective tissue and nerve-sheaths, and sometimes in the bone-marrow and muscles. Death in such cases may take place quickly.

Complications.—(a) True *nephritis* is rare, but *albuminuria* is frequent. (b) The ARTERIES, BONES, CONJUNCTIVA, and MIDDLE EAR commonly show purulent changes. (c) *Myocarditis*, *endocarditis*, and *pericarditis* are comparatively common.

SPRUE (PSILOSI) is a chronic remittent thrush-like inflammation of the whole or a part of the mucous membrane of the alimentary canal, associated with suppression of or interference with the glandular functions of the organs of digestion. It occurs principally in persons residing, or who have resided, in tropical or subtropical climates. Apparently nothing is known of its origin. In most cases reported rigor mortis was absent, or appeared late.

¹ *La Riforma Medica*, March 14, 1902.

Lesions.—(A) The THORACIC ORGANS, the ABDOMINAL VISCERA, and the tissues generally are found to be much wasted, giving the body a mummified appearance. (B) *Anæmia* is always marked. (C) The mucous membrane of the TONGUE, MOUTH, and ŒSOPHAGUS is bare, inflamed, and eroded. (D) The BOWEL is exceedingly thin, and on opening it a thick layer of dirty-gray viscid and tenacious mucus is seen. The villi and glands are eroded, missing, or may be dilated and filled with mucous material. On removing this mucus, areas of congestion, ulceration, pigmentation, or thickening may be found. The MESENTERIC GLANDS are generally enlarged.

SYPHILIS is a chronic contagious disease, due to the *Treponema pallidum* (*Spirochæta pallida*), and acquired by direct inoculation, or by inheritance. Lustgarten (1884) and van Niessen have each described organisms, the former having probably found the smegma bacillus. Schüller defends a former announcement¹ of the discovery of a protozoön-like parasite in syphilis. Schaudinn and Hoffmann² describe a spirochæta present in syphilitic lesions, and in the blood, which Metschnikoff has confirmed by discovering it in experimental syphilis of the ape. In this country, presence of an organism has been confirmed by many investigators. It has been found in the urine of a patient with active secondary manifestations and in the liver of a new-born syphilitic babe.

Lesions.—I. *Acquired form.*—(a) Primary stage. (1) The *hard* or *Hunterian chancre* is the initial lesion, beginning at the site of inoculation as a small red papule, usually situated at the junction of the skin and mucous membrane. It gradually enlarges and breaks in the centre, leaving a small ulcer with indurated edges and base. Microscopically the field consists of the usual signs of chronic inflammatory tissue,—epithelioid cells, giant-cells, cellular infiltration of the connective tissue, filling of the lymph spaces with round cells, etc. Chancre may, though rarely, appear on different parts of the body at the same time, when it is known as *chancre à distance*. Anthony³ has observed a patient who had a chancre of the penis, of the tongue, and of the

¹ *Centralblatt f. Bakteriologie*, 1902, vol. xxvii, nos. 5-9.

² *Deut. med. Wchnschr.*, 1905, vol. xxxi, no. 18. This protozoön is called by VULLEMIN of the genus *Spironema* and by STILES and PFENDER *Microspironema*. There is an excellent illustration of this organism in the *N. Y. Med. Jr.*, March 24, 1906.

³ *Jr. Amer. Med. Assoc.*, June 6, 1903.

finger at the same time. The chancre runs a self-limited course and heals, leaving a scar which may be found *post mortem*. That syphilis may be cured is shown by undoubted cases of second infection. The soft chancre (*ulcus molle*) is due to a bacillus described by Ducrey in 1889, Zomasczewski¹ having performed on his own person the necessary inoculation for experimental effect on the tongue. This organism resembles that of plague, and does not give rise to systemic infection.

(2) *Lymphatic enlargement*, especially of the glands of the groin, neck, and elbow, follows the primary inoculation. When *chancre à distance* occurs, only the glands in connection with one of the lesions are enlarged.

(b) Secondary stage. (1) A reddish-brown or copper-colored *cutaneous rash* occurs in about 30 days. It is polymorphous, varying in form from an erythema to a pustular eruption, and is symmetrically distributed, appearing most frequently on the chest, abdomen, and flexor surfaces of the arms. (2) The *mucous patch* is a softened and macerated, slightly elevated area of epithelium on the mucous membranes or on the moist regions of the skin; it is most frequently seen in the mouth, the throat, and about the anus. It is of irregular shape, and does not discharge pus. (3) The hair of the SCALP is decidedly thin. (4) On the TONSILS and LARYNX ulcers may occur. In the larynx there is erythema; on the cords or ventricular bands occur symmetrical, recess-like, whitish ulcers, superficial or deep, with raised edges. (5) About the VULVA and ANUS warts may be found. (6) *Iritis*, *choroiditis*, and *keratitis* are common. *Retinitis* is rare. (7) The FINGER-NAILS may be diseased, forming dry or moist onychia. *Dactylitis* is common. (8) Both the BONE and the PERIOSTEUM may be affected, causing hyperostosis, usually of the TIBIA, SKULL, HARD PALATE, and ULNA; or they may manifest themselves as inflammatory changes in the MEDULLA, with marked tendency to the formation of new bone. (9) In the JOINTS there may be serous or serofibrinous inflammation, with thickened capsules, proliferation of synovial fringes, and fibrillation and erosion of the cartilages.

(c) Tertiary stage. (1) *Cutaneous affections* are less symmetrical, and show a tendency to ulcerate and destroy the deeper layers of the skin, leaving scars. *Rupia* may develop. (2) The *gumma* is the characteristic lesion, and consists of a cheesy node surrounded by

¹ *Zeitschr. f. Hyg.*, 1903, vol. xlii.

connective tissue or smaller mass of proliferating epithelial cells, which tend to undergo coagulation necrosis at the centre. (*a*) *Hard gummata* develop in the internal organs and mucous membranes. They most frequently terminate in cicatrization, forming stellate scars which often cause marked deformities. (*β*) *Soft gummata* are found in bone, skin, etc. They tend to break down and ulcerate, leaving chronic indolent sores, often serpiginous. Prolonged suppuration leads to amyloid degeneration of organs. This is especially true as a result of rectal syphilis in women.

The above changes, as well as general, but irregularly situated fibroid patches of degeneration, are to be looked for *post mortem* in the various organs and tissues, as follows:—

(*a*) *Syphilis of the Central Nervous System*.—(1) *Gummata* are usually multiple, varying in size from a pea to a walnut. In the cerebrum they occur along the sulci. They appear also in the meninges, associated with thickening of these membranes. Heubner describes two forms: (*a*) grayish or grayish-red in color; on section moist, and exuding a small amount of juice; (*β*) quite hard and dry, with distinct outline; on section cheesy, and looking not unlike tubercular growths; they may undergo cystic degeneration. (2) *Gummatous arteritis* and *sclerosis* of both arteries and nerve-tissue may exist. (3) There may be softening due to obstruction of the vessels from pressure or from endarteritis. (4) *Tabes dorsalis* and *dementia paralytica* are late (parasymphilitic) manifestations of degeneration of nerve-tissue. At Philadelphia, in 1898, a man was condemned to death for killing a person in cold blood. A commission of experts pronounced him sane. The man committed suicide by hanging, and I found at the postmortem numerous gummata of the brain, situated especially in the right temporal and frontal regions.

(*b*) *Syphilis of the Circulatory System*.—(1) *Gummata* are rare. (2) Fibrosis of the HEART-MUSCLE is common, and amyloid degeneration has been noted. Sclerosis of the VALVES (especially the aortic valve) and warty endocarditis are common. (3) *Arteriosclerosis*, *atheroma*, *aneurism*, and *endarteritis obliterans* occur frequently.

(*c*) *Syphilis of the Gastro-intestinal Tract*.—The lesions in this situation may be chancre, ulcers, localized fibrous patches, gummata, or miliary nodules. (1) There is a sclerous glossitis or leucoplasia present, which by some is supposed to be characteristic of syphilis. (2) The ŒSOPHAGUS is rarely affected. Ulceration or stenosis may be

present. (3) The PHARYNX may be the seat of ulcers, phlegmonous inflammations, or abscesses. (4) The SMALL INTESTINE and the CÆCUM often show ulcerations. (5) The RECTUM is not infrequently the seat of cicatricial contraction, most commonly seen in women. Mucous patches or condylomatous masses may be seen about the anus.

(d) *Syphilis of the Kidneys*.—(1) *Gummata* are not infrequent. (2) *Acute nephritis* may occur, but *chronic interstitial nephritis* is more common. This is localized and is caused by overgrowth of fibrous tissue, the shrinking of which results in marked irregularity of the surface of the kidney. It is sometimes hard to distinguish it from old infarcts, but the color, which in syphilis is gray and in infarcts is brown, is a rather good point of differentiation.

(e) *Syphilis of the Liver*.—(1) *Gummata* may be small pale-grayish nodules, or larger nodules yellowish in color. Usually they are multiple (miliary). Although they may be present in any part of the organ, the most common situation is at the junction of the right and left lobes. Great deformity results from healing and contraction. (2) In *diffuse syphilitic hepatitis* there is a marked fibrous change, the organ being hard, firm, and resistant, and divisible into twenty or more lobules. The disease usually begins with perihepatitis, which frequently causes adhesions to the surrounding structures. With contraction of the fibrous tissue, great deformities of the liver become manifest. Capillary bile ducts may be present in abundance in the cirrhotic portion.

(f) *Syphilis of the Testis*.—(1) Gummatus growths usually involve the EPIDIDYMIS, which becomes a hard mass, from the size of a bean to that of a walnut. It affects the head of the epididymis more commonly than the body. (2) In *interstitial orchitis* the progress of the disease is slow. The testis is larger than when normal, and is distinctly harder to the touch. The overlying skin is not adherent, and there is no tendency to suppuration.

(g) *Syphilis of the Respiratory Tract*.—(1) *Gummata* may appear towards the base of the EPIGLOTTIS. These break down, producing deep flask-shaped ulcerations, which may heal by connective tissue that shrinks and produces stenosis. Islands of connective tissue commonly appear between the cicatrices, and form inflammatory excrescences. The neighboring cartilages may show symmetrical necrotic changes. Diffuse infiltration of mucous membranes may occur. A fatal termination may result, due to perforation of an artery. (2) The BRONCHI may be stenosed or obliterated. (3) In the LUNGS,

gummata may vary in size from a pea to a goose's egg; they are usually limited to one lung, and generally to the middle portion, near the hilum. They are grayish-yellow in color, and are embedded in connective tissue. They may dry up and calcify. The parts around them are hard and brawny, and of a glossy lustre. There may be a fibrinous interstitial pneumonia, usually bilateral and diffuse, in which the lesions are hard, large, and pale or dark grayish-red in color. The middle of the right lung or the apex of either lung is the part most frequently involved. The pleura is thickened and adherent. Some of the cases described as being of syphilitic origin are nothing more or less than a chronic interstitial tuberculous pneumonia.

(h) *Syphilis of Bone*.—*Gummata* appear; they are usually periosteal but may be medullary. If peripherally situated, they are often multiple and of varying size. The affected area may be dense and brimstone-colored, or necrotic with a fat gummy mass. Recent periosteal gummata are flat swellings of elastic consistence, and on section have a gelatinous texture. They are always accompanied by resorption of bone. Osteomyelitic gummata occur frequently in the phalanges (dactylitis), and in the diploë of the skull. They form foci that are gelatinous or fibrogelatinous and dirty-yellow in color, or puriform. They may cause well-marked caries and necrosis, which in the skull sometimes lead to perforation, and in other cases to caseous and fibroid changes, not only in tissues surrounding the gummata but also in the tumor itself. *Anæmia* is marked, and the skin looks muddy. *Parotitis* may occur.

II. *Congenital form*.—(a) The primary stage is not seen. (b) Secondary stage. At birth the infant may be apparently healthy. It may develop no symptoms for several weeks or months, or well-marked lesions may be noted at once. (1) The wasted and aged appearance is conspicuous, and as the child grows, assymetry and poor development are noted, especially in the teeth, which are wedge-shaped and the cutting edge notched (Hutchinson's teeth). (2) *Pemphigus* may occur on hands and feet. (3) The LIPS may be ulcerated, and the MOUTH and ANUS fissured. (4) Inflammation of the mucous membrane of the NOSE, with papillary infiltration, is present, and necrosis of bone, resulting in the broken-nose deformity, may occur. Goundou, a rare tropical affection of the negro race, which is characterized by tumors of the nasal bones, is supposed by some writers to be a congenital syphilitic osteitis. (5) Lesions of the JOINTS are rare.

(6) The SPLEEN and LIVER are enlarged, and may be the seat of parenchymatous rather than gummatous infiltrations. (7) Lesions of the LUNGS. (*a*) *White pneumonia*, in which the affected lung is heavy and airless, presenting on section a grayish-white appearance. The lungs are distended and bear the imprint of the ribs; they are dense, friable, smooth, and opaque. (*β*) *Miliary gummata*, which are small in size, grayish in color and firm in texture, and are more or less symmetrically distributed through the lungs. (8) *Acute iritis* is not infrequent. (9) When dentition occurs, the teeth are wedge-shaped, and the cutting edges notched (Hutchinson's teeth). (10) Lesions of the BONES. (*a*) In the SKULL, craniotabes (wasting at the sites of decubitus) is common in very young children. Incrustations known as "Parrot's nodes" are seen about the anterior fontanelle. (*β*) Long bones, the TIBIA, FIBULA, and RADIUS, usually show characteristic changes, and the epiphyses may be separated and enlarged. Parrot's nodes occur also in the tibia and the humerus. When the tibia is affected, it often grows more rapidly than the fibula, thus throwing the foot into the position of valgus. The total length of the limbs may be increased. The bones may become brittle from caries, or very heavy from eburnation. Later, about the sixth year, the tibia may become the seat of a chronic gummatous periostitis, leading to great thickening of the bones, and often to swellings, forming the sabre-blade deformity. Disfiguring scars always remain. (*γ*) *Dactylitis* is not uncommon. The process may be localized to the border zone between epiphysis and diaphysis; this zone has a ragged edge and a yellowish color, and becomes hard like mortar. (*c*) The tertiary stage in the congenital form is marked by noticeably fewer lesions than in the acquired form. (1) The chief lesion of the EYE is an interstitial keratitis affecting both eyes, which usually does not appear until near adolescence or adult life. (2) If the EAR be affected, deafness, of labyrinthine origin, often occurs.

TETANUS is an infectious disease due to the *Bacillus tetani*, and is characterized by tonic convulsions with clonic exacerbations. The bacilli multiply at the site of the wound, which is usually of a penetrating character, and do not invade the blood or organs, except very late in the course of the disease. The toxin acts destructively, especially on the nervous system. Four hundred and fifteen cases of Fourth of July tetanus are reported as occurring in 1903.¹ The mortality was

¹ *Jr. Amer. Med. Assoc.*, August 29, 1903.

about ninety-five per cent. As a result of recent investigations Dr. David H. Dolley¹ concludes: "There is abundant evidence from clinical observations and animal experiments that the wads of certain blank cartridges contain the *Bacillus tetani*." A number of cases of tetanus following vaccination were reported in 1903, the virus in one instance having been prepared by a Board of Health.

Finlay found the bacillus abundant in the wick used for tying the umbilical cord, an explanation of the etiology of *tetanus neonatorum*.

Lesions, of which none is characteristic, are: (A) The condition of the WOUND depends upon the kind and extent of the injury. In tetanus neonatorum the umbilicus may be the original seat of inoculation and be inflamed. (B) The CENTRAL NERVOUS SYSTEM shows intense congestion, with perivascular exudations and granular changes in the nerve-cells. Some investigators have found swellings and areas of disintegration in the gray matter of the cord, with exudation of a finely granular material and of disintegrated blood. The spinal ganglia should always be saved for microscopic study. (C) The RECTUS MUSCLE has been found ruptured as the result of a spasm. (D) *Heart-failure* or *asphyxia* may cause death.

THRUSH is a disease due to the *Oidium albicans* or thrush fungus, which shows many variations upon cultivation, and is closely allied to *Blastomyces*. Thrush is most commonly seen in children; in adults, in those who have died of chronic tuberculosis, diabetes, and other cachexias.

Lesions.—(A) The MOUTH, TONGUE, CHEEKS, etc., are more or less densely covered with minute slightly raised white spots, which are quite firm and adherent to the mucous membrane, but which may be scraped off, leaving the mucosa intact. Microscopic examination of the scrapings shows the characteristic fungus. (B) The ŒSOPHAGUS is occasionally invaded, the fungus growing to such an extent as seriously to obstruct its lumen. (C) The STOMACH and CÆCUM are at times affected. (D) Systemic infection may occur, and the organisms may grow into blood-vessels.

TUBERCULOSIS is an infectious disease incited by the tubercle bacillus, discovered by Koch² in 1882, and is characterized by an exudative and productive inflammation in which the typical morphologic feature in reacting to this irritant consists in the formation

¹ *Jr. Amer. Med. Assoc.*, February 11, 1904.

² *Berl. klin. Wchenschr.*, April 10, 1882.

of small nodular bodies called tubercles, which later conglomerate and undergo cheesy degeneration. The tubercle of Laennec when first formed is a grayish and translucent spheroidal body, in size from a microscopic object to that of a pea. It is composed of a collection of leucocytes attracted to the spot by the positive chemotactic action of the bacilli, of larger (so-called epithelioid) cells, and of a few giant-cells. It is a non-vascular formation, showing little tendency to form new blood-vessels. By the fusion and extension of many such miliary tubercles, larger nodules are formed. As the toxic products of bacterial growth accumulate, this new-formed tissue, as well as the old tissue of the infected area, undergoes coagulation necrosis, the process appearing first in the centre and extending outwards until the entire nodule is converted into an opaque granular or structureless mass. Fatty degeneration accompanies the necrosis, and the process is called caseation. Such a cheesy mass may soften and thus form the so-called cold abscess, the contents of which consist mainly of broken-down tuberculous tissue, fatty *débris*, and water; there is no definite limiting membrane. The contents of such an abscess are usually sterile, though supposed by von Schrön to be made up largely of the phthisiogenic organism described by him. If secondary infection of the mass by pyogenic organisms occurs, suppuration and the formation of a true abscess results. In this case a true inflammatory limiting membrane will form as a result of reaction to the pyogenic infection, or calcification of the mass may take place, with arrest of the process. Instead of caseation, a secondary inflammatory reaction may take place in tissue surrounding the area affected, which is thus encapsulated, and then by gradual pressure and absorption is removed and replaced by a hard fibrous scar. When the affected area is small, the blood-supply is good, and the patient is under favorable conditions, resolution may occur. It is estimated by careful observers that seventy-five per cent. or more of all persons who die after the age of forty years in places where tuberculosis is prevalent show some form of previous tuberculosis in their lungs, pulmonary glands, or elsewhere in the body.

Koch's assertions, made before the International Congress on Tuberculosis at London in 1901, that human tuberculosis differs from bovine and cannot be transmitted to cattle, and that man does not, except in the rarest instances, contract tuberculosis from the cow, have been vigorously combated by the British Royal Commission

and by many independent workers. Even Kossel, of Germany, announced, as the result of his special investigation, supposed to have been undertaken at the suggestion of Koch himself, at the International Congress on Tuberculosis, held in Paris, October 2-7, 1905, that (1) bacteriological examination of the tuberculous lesions of man, cattle, and swine enables us to distinguish two types of tubercle bacillus, which may be provisionally designated as "human" and "bovine." (2) Bovine tuberculosis, so wide-spread, is exclusively due to infection by the bacillus of the bovine type.¹ (3) Swine are susceptible in high degree to bacilli of the bovine type; to a less degree to bacilli of the human type. (4) Tuberculosis in man is due chiefly to infection by the tubercle bacillus of the human type, which is transmissible from man to man. (5) Tuberculous lesions may be produced in man by the tubercle bacillus of the bovine type. (6) The transmission of tubercle bacilli of bovine type to man may occur through food products derived from tuberculous animals, chiefly through the milk of cows with tuberculosis of the udder. (7) The role played by infection from animal sources in the spread of human tuberculosis is small compared with the danger from phthysical persons. These investigations sustain the stand taken by Mazÿck P. Ravenel in London in 1901, and have confirmed Theobald Smith's work done in 1898. At the 1905 Congress, von Behring made an important announcement of a new cure for tuberculosis, which is based upon a cellular, and not upon a humoral or antitoxic, immunity. He derives a substance from the tubercle bacilli, tentatively termed TC, which when modified by cellular activity, is spoken of as TX. That cattle may be immunized against tuberculosis seems to be a settled fact, and von Behring believes that TC when freed from other substances exercises a specific action on the cells, especially on those of a lymphoid nature. Now, if this TC could be supplied to the organism, and the work of preparing it thus be saved, a passive immunization would be secured in place of an active one. Experiment evidence leads him to believe that three groups of substances derived from the tubercle bacillus may be distinguished: (1) A fermentative, catalytic substance, soluble in water, which is called TV, and represents the toxic factor of

¹The writer has been struck with the freedom from endemic tuberculosis in those districts of Switzerland and of this country in which fresh cow's milk is not used. See *Lancet*, May 26, 1906, for Koch's Nobel lecture upon tuberculosis.

Koch's tuberculin; a gramme in the dried state being more powerfully toxic than a whole litre of Koch's tuberculin. (2) A globulin, called TGL, which is soluble in a ten per cent. solution of sodium chlorid. This is also toxic. (3) There are a number of non-toxic substances, which are soluble in such agents as alcohol, ether, and chloroform. If the bacillus be deprived of these groups of bodies it may retain its shape and still stain as does the tubercle bacillus. It is this "rest bacillus" from which von Behring, by a secret process, though promising to supply the preparation to laboratory workers, obtains a substance that is capable of absorption by the lymphoid cells of certain of the experimental animals. TC is capable of producing the tubercles, and if one reads the later articles by von Schrön it will be seen that this writer believes that the tubercle bacillus itself is the agent which produces the tubercle, while it is the phthiogenic organism which causes the caseation and subsequent softening.

Lesions.—I. RESPIRATORY TRACT. (A) LARYNX. The lesions may be primary or secondary, usually the latter, and may manifest themselves as either miliary or ulcerative tuberculosis. In early cases the epithelium is intact, the tubercle starting in the mucosa or the submucosa, which are pale and thick. The ARYTENOIDS are swollen, and small shallow ulcers with pale eroded bases and irregular walls eventually develop in the arytenoid space. Necrosis of the cartilage rings is not uncommon.

(B) LUNGS. (a) *Acute infection.* (1) In *acute miliary tuberculosis* the lesions are usually present in both lungs. They are frequently so small and transparent that they may be overlooked on macroscopic examination; they are more numerous on the pleural surface, and are often as readily felt as seen. At other times they are aggregated in localized spots, or may even become diffuse. In the latter case the lung is increased in size and weight; is firm in consistency; assumes a darker shade of red; and crepitates. The pulmonary vessels having been opened with scissors, miliary tubercles are often seen in the veins, but seldom in the arteries, even though the infection has been brought about through the circulation. Such tubercles may, however, be localized near an old caseous mass, the lymphatic system then being the transmitter. Local spots of emphysema are seen if the condition is not very acute. The tubercles may be peribronchial, perivascular, or in the parenchyma. There is a chronic miliary tuberculosis which presents a combination of lesions

of both acute miliary tuberculosis and phthisis, and is the connecting link between the two. The bronchial glands are usually enlarged and caseous. (2) *Phthisis florida (acute phthisis)* may show itself as bronchopneumonic tubercles, lobar pneumonic tubercles, or a combination of both. In children the central portion of the lung is peculiarly apt to be affected. The formation of consolidation and cavities presents a varied appearance. One lobe only, or more or less of the whole lung, may be affected. The organ is heavy; the implicated portions do not collapse, and are firm and airless. The pleura is covered with a thin exudate. On section the condition may resemble red or gray hepatization or an irregular intermediate stage between the two. In other instances the lung presents a mottled appearance, some areas being intensely congested, others exhibiting a characteristic pale-gray gelatinous exudate; others still, caseous degeneration and, not infrequently, cavity formation. The lung may be honey-combed with innumerable small cavities. Softening sometimes occurs immediately below the pleura, leading to necrosis and pneumothorax. Areas of pulmonary tissue affected with croupous pneumonia, from which the patient may have succumbed, are often seen. Such lungs readily caseate and produce ulcerative excavations of considerable size. (b) *Chronic infection.* (1) In *ulcerative tuberculosis* the apex is involved (according to Kidd) five hundred times to one involvement of the base. The lesions are varied. There may be caseous nodules, which are grayish, white, or yellow in color; cavities may exist, which, in more acute cases, have walls made up of soft caseous masses; or, in the more chronic cases, these walls are replaced by pyogenic membranes of greater or less density, and at times are covered with granulations. They are dry or more or less purulent. Frequently trabeculae are seen in the walls; these are the blood-vessels, branches of the pulmonary artery, which have resisted the tuberculous process. The arteries sometimes become aneurismal, and their rupture may be followed by hemorrhage severe enough to cause death. Frequently they are contracted and empty, due to a previous endarteritis or thrombosis. Pneumonic areas and evidences of chronic bronchitis and fibrosis are seen; the bronchi may be thickened, the lumina of the smaller ones being obliterated and the larger tubes showing caseous deposits in the submucous and fibrous coats. Some thickening of the pleura is constant. This may be merely an acutely inflamed spot rubbing against a corresponding area

on the parietal pleura, or it may be tightly adherent to it. Not infrequently perforation causes a pyopneumothorax. Enlarged bronchial glands, which are caseous and often pigmented, are found. (2) In *fibroid phthisis* the organ is permeated with interstitial overgrowth, which may appear independently as dense pigmented strands in the apices, with cretaceous nodules or dry caseous material in the centre, the interstitial change being most prominent in some cases, and the tuberculous process being slightly more marked in others. The unaffected portions of the lung are largely emphysematous, and pigmentation is considerable.

II. ALIMENTARY TRACT. The disease may be primary in the mucous membranes, as from the eating of infected food, or secondary, as from disease of the lungs, or, rarely, through extension from the peritoneum. (A) MOUTH. (a) *Primary tuberculosis* is usually miliary. The tonsils and uvula are more often thus affected than was formerly supposed. There may be ulceration, or a miliary infiltration usually associated with hypertrophy. (b) *Secondary tuberculosis*, consequent upon tuberculosis of the face, larynx, or lungs, attacks the tongue, lips, or cheeks, or the hard and soft palate. It may be miliary or caseous. The salivary glands are very rarely affected, but the pharynx is often covered with an eruption of miliary granules.

(B) ŒSOPHAGUS. (a) *Primary tuberculosis* is very rare. (b) *Secondary tuberculosis*, through extension from the lungs or larynx, is comparatively common. The lesions may be miliary, caseous, or ulcerative.

(C) STOMACH. This is rarely the seat of the disease. I have had one case of primary gastric tuberculosis in a young child. When it occurs it may lead to perforation of this viscus.

(D) INTESTINES. The lesions occur in the ILEUM, COLON, RECTUM, and ANUS. The most frequent seat of the disease is the ileum just above the ileocecal valve, as it is here that a stasis of the intestinal contents occurs and a favorable opportunity is given for the growth of the tubercle bacillus. Small, firm, gray nodules develop, which soon soften and become yellow in the centre, generally starting in a solitary and agminated gland. If cut into at this stage, pus does not exude as in an ordinary abscess, but a thick caseous material may be pressed out. The mucous membrane finally breaks down, and the cheesy material is erupted. There remains an irregular ulcer with a

swollen cheesy base, having hard yellow spots and thickened edges (the primary tuberculous ulcer of Rokitansky), which soon combines with others and enlarges irregularly (the secondary tuberculous ulcer of Rokitansky). Miliary tubercles in the form of small gray nodules now appear at the base and edges of the ulcer and in its immediate vicinity. The longer axis of the ulcer is usually at right angles to the intestine, and it may extend around the bowel.¹ Hemorrhages may occur, particularly at the edges. The submucosa and muscularis are usually involved, and colonies of young tubercles may be scattered over the serous membrane. Perforation is rare, though gangrene may occur in a very rapidly developing ulcer. Healing sometimes takes place, and there may be solitary or multiple areas of cicatricial tissue. Stenosis of the bowel may occur. Pericæcal abscess and appendicitis may be tuberculous in origin. *Fistula in ano* is quite common, and hemorrhoids are a frequent complication.

III. LIVER. The liver is always involved in general tuberculosis. It is pale in color, often fatty, and presents miliary tubercles or caseous masses which may break down into numerous small abscesses, especially about the smaller bile ducts. There may be slight increase in the connective tissues, leading to tubercular cirrhosis.

IV. SPLEEN. (a) In *acute infection* the organ is increased in size, firm in consistency, deeply congested, and on section presents a greater or less number of symmetrically distributed, small, grayish, semi-translucent bodies, slightly raised above the surface and firmly adherent. This condition is seldom a primary lesion, but is common as a secondary infection. (b) In the *chronic form* caseous tuberculosis is attended by a variable number of irregularly distributed cheesy nodules or diffuse areas of caseation. These may be as small as a pea or as large as a walnut or larger. They not infrequently break down and form abscesses through pyogenic infection. (c) *Tuberculous perisplenitis* frequently occurs as an extension from peritonitis.

V. The GENITO-URINARY SYSTEM is most often affected in males from twenty to forty years of age.

(A) KIDNEYS. (a) *Acute miliary infection* is not infrequent, and may be primary or secondary. The disease is most marked in the cortex. It may be limited to the areas which are supplied by a

¹ See Table of Differences between Typhoid and Tuberculous Ulcers, p. 354.

single blood-vessel. The miliary tubercles may be seen in a row in the direction of the vasa interlobularia. Necrosis and caseation rapidly follow. One or both organs may be affected, but at autopsy both are found to be enlarged. (b) In the *chronic form*, not infrequently one kidney may be completely destroyed and converted into a series of cysts, which contain a cheesy substance; lime salts may be deposited in their walls. This form of the disease frequently starts at the apices of the pyramids. The walls of the pelvis may be thickened and cheesy, and the mucous membrane may be converted into a necrotic ulcerating mass. The ureters may be thickened, caseous, or ulcerated.

(B) BLADDER. The infection is nearly always secondary, particularly to tuberculosis in the pelvis of the kidney. The bladder is small, shrunken, thickened, and surrounded by sclerosed tissue. Lenticular ulcers, surrounded by a zone of inflammation, are commonly found situated at the trigone or the fundus. The URETERS are also involved, being dilated and ulcerated. The involvement of the ureters, as of the PROSTATE and the VESICULÆ SEMINALES, is rarely primary. To find tubercle bacilli in the urine, repeated centrifugation with a 5 per cent. sodium hydrate solution should be employed, the precipitate being stained in the usual manner for showing these organisms. Care must be taken not to get the smegma bacillus; it is therefore advisable that the urine be collected with the strictest precautions.

(C) TESTES. Infection may occur before the second year. It may be secondary to peritoneal tuberculosis. At times the greater part of the testis is destroyed, its stroma being replaced by a softened or still firm caseous deposit. It may be associated with syphilis.

(D) OVARIES, FALLOPIAN TUBES, and UTERUS. The disease is usually bilateral. The tubes are enlarged, the walls are thickened and infiltrated, and the contents are cheesy. Adhesion to the neighboring organs is always found. The ovary may be affected secondarily, and the affection may extend to the uterus and vagina.

VI. CIRCULATORY SYSTEM. (A) The HEART will show hypertrophy when the lungs are affected, resulting from the increased pulmonary resistance. Tubercles may be seen in the ENDOCARDIUM, the PERICARDIUM, and the MYOCARDIUM.

(B) VESSELS. Primary tuberculosis of the larger vessels is unknown; secondary lesions are not infrequently found if carefully

searched for. In the lungs, brain, and other organs the smaller arteries are usually involved in an acute infiltration which leads to thrombosis. Tubercles may develop in the walls of the vessels, particularly in the muscularis, and undergo softening, resulting in hemorrhage or in a wide-spread distribution of the tuberculous infection.

VII. SEROUS MEMBRANES. (A) PERITONEUM. (a) *Miliary form*. On opening the abdominal cavity the membrane seems to be covered to a greater or less extent with miliary tubercles, which are present in the MESENTERY and the OMENTUM also. Frequently the gray nodules follow the distribution of the blood-vessels. The peritoneum does not possess its normal shining surface, but is usually pale, somewhat sticky, and lustreless. Often there is little or no inflammatory exudate, although petechial hemorrhages are common. In many cases there is an effusion of straw-colored or bloody fluid which may amount to a litre or more. It contains a considerable amount of albumin and some cells. The exudate is rarely purulent. (b) *Chronic diffuse form*. The ABDOMINAL VISCERA and PERITONEUM are bound together by tough firm membranous bands of organized exudate, and the PERITONEAL CAVITY is obliterated. The exudate is purulent, seropurulent, and at times sacculated. The INTESTINAL COILS may be shortened and contracted, while the MESENTERIES and OMENTUM are enormously thickened. The capsules of the LIVER and SPLEEN may undergo extreme thickening, varying from a few millimetres to several centimetres. The organs are rough and irregular in outline. (c) *Ulcerative form*. There is a formation of caseous masses, which vary in size from a pea to a marble, and which tend to run together and break down, forming more or less extensive ulcerating surfaces. Adhesions of a serofibrinous or seropurulent character are formed. The new tissues are apt to become pigmented and of a gray or almost black color. The intestinal walls are very friable. Fistulæ, opening at various points, are not infrequent.

(B) PLEURA. (a) The *acute form* is usually accompanied by a serofibrinous effusion, which may become purulent, or it may be a proliferative inflammation, leading to thickenings and extensive adhesions. (b) The *chronic form* is characterized by exudation, by the formation of cheesy masses, and by a tendency to suppuration.

VIII. BONES. Lesions of the bones are very common. The tuberculous process starts more frequently in the bone itself than in the periosteum, though exceptions occur in the RIBS, the VERTEBRÆ, and the PHALANGES. In the *miliary form*, the tubercles are first seen in the marrow of the DIAPHYSIS. The process starts with a group of tubercles surrounded by granulation tissue, a grayish-red zone, which may become fibrous and thus limit the process. In this outer zone the trabeculæ become thicker at the expense of the spaces; while in the centre the former are undergoing absorption, the process constituting rarefying osteitis. Extension takes place by the formation of additional tubercles, varying in size from a pea to a hazel-nut, containing necrotic trabeculæ, and tending to run together and to shut off the blood-supply. They quickly undergo a cheesy change. These areas of caseation may separate as sequestra, which are usually small, but sometimes attain the size of a walnut; a whole epiphysis (such as the head of the femur) may thus be detached. The trabeculæ of the sequestra are thickened, showing that a chronic inflammation was present before the separation occurred. The sequestra may be soft and crumbling, or they may be calcified. When the PERIOSTEUM is first affected, there is rapid enlargement, due to the formation of tubercles appearing in spots, or extending over a large area. Erosion of the bone follows, and is usually succeeded in turn by an abscess, on cutting into which there is found œdematous fibroid tissue containing tubercles, granulation tissue with tubercles less typical, and a layer chiefly of epithelioid cells, which gradually becomes more and more caseous. In the larger LONG BONES the process usually begins in the periosteum, at the articular extremity. In the small long bones and in the short spongy bones it usually involves all of the bone. In the SPINAL COLUMN the deformity known as kyphosis results from the softening and collapse of the bodies of the vertebræ. The disease occurs most often in the dorsal vertebræ, then in the cervical, and less frequently in the lumbar and sacral. Extension of the process to the neighboring tissues may cause perforation externally, the cold abscesses discharging their softened, cheesy contents on the back at the side of the spinal column, into the throat, as retropharyngeal abscess; at the crest of the ilium; or the so-called pus, burrowing by gravity, may form the psoas abscess.

IX. JOINTS. Orth describes tuberculous arthritis as follows: There is marked doughy and inelastic swelling of the joint and the

tissue surrounding it. In the periarticular region the tissue has a white, pale, smooth, and glistening appearance (tumor albus), and it may contain fistulæ with granulations on their walls. In the joint itself there may be little or no exudate. If present, the exudate is a serous or purulent effusion and contains rice-like bodies. The synovial membranes are pulpy or gelatinous, and are covered with granulations which may be so exuberant as to cover the whole joint cavity; they are studded with tubercles. The bone in the neighborhood may have undergone caries (osteoporosis) and the probe can be easily pushed in for considerable distances. Sequestra may be found. The cartilage is only secondarily involved. It undergoes caries and softening when lifted off by granulations from the synovial membrane. Fibrous structures become brawny and fascicular; caseous nodes and cold abscesses are produced, which rupture and form fistulous tracts, or sinuses. Tubercle bacilli are present. Tuberculosis may affect a large joint, destroying entirely the cartilage and the capsule, and even the head of the bone. The socket is widened, the bone in the neighborhood becomes carious and eroded, and dislocations may occur. This is most common in the hip-joint (coxalgia), or in the knee-joint (tumor albus).

X. LYMPHATIC GLANDS. Those most often involved are the cervical chain, and the disease extends in the direction opposite to that of the lymphatic stream (Treves). The bronchial and mesenteric glands are also frequently affected, the latter constituting *tabes mesenterica*. (a) *Chronic form*. The affected glands are hard, with overgrowth of connective tissue, yellowish white in color, and non-adherent; they show little tendency to break down and suppurate. The disease seems to be localized. (b) *Subacute form*. The glands are less dense, are grayish white in color, tend to become adherent, and to soften and suppurate. There is less connective tissue, and tubercle bacilli are more abundant. When tuberculous lymphatic glands are associated with phthisis, they are sometimes found to have opened into a BRONCHUS and caused the disease. This is particularly common in children, and especially when the middle and lower lobes are involved. Perforation may also occur into the OESOPHAGUS, AORTA, and PERICARDIUM. Generalized adenitis occurs rarely. Localized adenitis is often associated with purulent otitis media, chronic nasopharyngeal catarrh, eczema of the scalp, conjunctivitis, and keratitis.

XI. MAMMARY GLAND. The infection occurs usually in women of strumous temperament, between the fortieth and sixtieth years, and is usually associated with lymphatic enlargement, tuberculosis of bone, or other involvement in the neighborhood. The seat of predilection is the gland-duct. Induration is at first small, and the nodules increase in size very slowly. The nipple may be retracted. The skin over the gland becomes riddled with sinuses having indurated edges.

XII. BRAIN and CORD. (a) *Acute miliary tuberculosis*. This is usually secondary to tuberculosis of the lungs, bronchial glands, or bones. The miliary tubercles occur most frequently in the pia and arachnoid of the CEREBELLUM, next in the CEREBRUM, then in the PONS. They follow the direction of the blood-vessels, and are apt to lead to obliteration of the vessels and thus cause necrotic softening of the nervous tissue. Serous, seropurulent, or serofibrinous exudate is also present. This acute process may result in acute inflammation of the MENINGES, principally the pia and arachnoid. It is spoken of usually as acute hydrocephalus. This is most pronounced towards the base of the brain and occurs most frequently in children. I have twice found tubercle bacilli in fluid removed by Quincke's lumbar puncture. (b) *Chronic meningo-encephalitis*. The membranes at the base of the brain are most often involved, next in frequency the OPTIC CHIASM, the SYLVIAN FISSURE, and the INTERPEDUNCULAR SPACE. The membranes are thickened, firmly adherent, and are covered with a fibrinous purulent exudate. The convolutions are flattened and the sulci are obliterated. The cerebral substance is more or less œdematous. The lateral ventricles are dilated and contain a turbid fluid. (c) *Tuberculous tumors* of the brain. Solitary tubercles are found most often about the cerebellum. As a rule they are attached to the meninges, often to the pia mater. The tubercles vary in size from a pea to a small orange. They are grayish yellow in color, caseous, and are usually firm and hard, but the centre may be semi-fluid. They may be surrounded by submiliary tubercles, but are, as a rule, surrounded by a soft translucent tissue. They may calcify. Cerebral softening from pressure is not uncommon.

XIII. SKIN. (a) For a description of *anatomical warts*, see page 51. (b) *Lupus vulgaris* is a cutaneous form of tuberculosis, the lesion of which begins as a small nodule, reddish brown in color and of soft consistence. These nodules vary in size from a pin-head

to a cherry, and quickly break down and ulcerate. The ulcers are more or less rounded and have a red base covered with granulations. The intervening tissues show diffuse infiltration and fibrous hyperplasia. Warty excrescences may develop in the epidermis or in the floor of the ulcers. The FACE is the most common seat of the disease, which follows the lymphatic channels.

TYPHOID FEVER is an acute infectious disease due to the *Bacterium typhosum*,¹ and is characterized by definite endothelial proliferation and subsequent necrosis of the intestinal lymph-follicles (Peyer's patches), mesenteric lymph-glands, spleen, bone-marrow,² and perivascular lymph spaces. The organism is found, early in the disease, in the intestinal and mesenteric lymph-nodes, and in the spleen, from which organ it has been obtained during life by puncture for diagnostic purposes. Later it may be found in the blood, in typhoid spots, in the urine, and in abscesses of the testicles, joints, etc.

The Widal test and the diazo-reaction may be determined *post mortem*. Ficker³ recommends the use of fluid containing dead typhoid bacilli from a culture of known origin and virulence; these are agglutinated by the serum from the typhoid case. Ruediger⁴ prepares the fluid by killing the typhoid cultures with one per cent. formalin and adding four cubic centimetres of this to one cubic centimetre of the one-to-ten formalized blood under examination. Make a control test.

Lesions.—(A) **INTESTINES.** The lesions are most marked in the lower ILEUM, but may exist in the CÆCUM, APPENDIX, and COLON; rarely in the JEJUNUM, the primary infection rendering secondary infection more easy. During the first week there is intense catarrhal inflammation of the mucous membrane and some epithelial desquamation, with moderate or more intense swelling of the lymph-follicles. These are red or reddish gray in color and of a rather soft consistency. In a mild case, resolution may take place at this stage, and the nodes may return to their normal condition. In severe infections, the swelling increases and towards the third week softening of the patches with ulcerations takes place.

¹ For an account of this organism, see p. 386.

² LONGCOPE, Phila. Path. Soc., December, 1904.

³ *Berl. klin. Wchnschr.*, November 9, 1903, p. 1021.

⁴ *Journal of Infectious Diseases*, 1904, vol. i, p. 236.

The differentiation of *typhoid* and *tuberculous ulcers* is important, and may be tabulated as follows: ¹—

TYPHOID ULCERS.

1. Direction often longitudinal, involving the Peyer's patches, which are larger in size, actual amount of surface affected greater. Extension takes place laterally or in depth.
2. Edges are undermined, ragged, thin, vascular, and composed of reddish mucosa and submucosa, and this fringe may readily be floated out on water.
3. Floor of the ulcer is smooth and vascular.
4. Peritoneal surface opposite the ulcer is usually unaltered, but occasionally it is inflamed and thickened. Mesentery unaltered; glands enlarged, pink, and softened, and hyperplasia develops early.
5. Perforation is more common, both by separation of slough and by direct extension in depth of the ulcerative process. Fæces may escape through such a small perforation and peritonitis result; or hemorrhage may follow. Extension takes place either laterally or in depth.
6. Healing is by granulation, the thin edges falling on to and uniting with the granulating floor of the ulcer.
7. A smooth cicatrix (often depressed), pale, anæmic, or pigmented, and covered by a layer of epithelium, but no gland-tissue, is left. The ulcer seldom breaks out afresh, relapses being due to the involvement of adenoid patches previously little damaged.
8. Typhoid bacilli are found in the ulcers. Widal test positive.
9. Other lesions of typhoid, with the clinical history of the case, are to be considered.

TUBERCULOUS ULCERS.

1. Direction (frequently) transverse or round. This distinction is not so characteristic as is sometimes held. Extension usually takes place laterally. The ulcers are smaller, and may be very numerous.
2. Edges are not undermined, but thick, prominent, nodulated, terraced, or sloping; pale or red; composed of tissue infiltrated with tuberculous nodules.
3. Floor is nodular, irregular, thickened, vascular, with pale or yellow points or areas, and shows outlying tubercles.
4. Peritoneum is thickened; there are small yellow or gray points opposite the floor of the ulcer, following the encircling lines of lymphatics. Mesentery thickened at its attachment to the bowel; glands enlarged, firm, and gelatinous on section, or caseous.
5. Perforation, peritonitis, and hemorrhage are all rare. Extension usually takes place laterally.
6. Healing is very rare.
7. The ulcer leaves a puckered, deeply pigmented cicatrix, in which are gray or white nodules. It often breaks out afresh. Stricture not uncommon.
8. The presence of tubercle bacilli is easily demonstrated at time of autopsy. Widal test negative.
9. Evidence of tuberculosis elsewhere, especially in the lungs, can usually be found.

¹ After WOODHEAD, *Practical Pathology*, 3d edition, p. 455.

(B) The SPLEEN is enlarged, softened, and hyperplastic, and infarcts are not uncommon. (C) The HEART, LIVER, and KIDNEYS not uncommonly show cloudy swelling. (D) The reaction in the MUSCLES has been referred to on page 92.

Complications.—(A) INTESTINES. Necrosis and suppuration may occur as extensions. The MESENTERIC GLANDS may suppurate. A MECKEL'S DIVERTICULUM may become perforated or strangulated, and thus cause death, as in one of my cases.¹ Rupture of the rectum has been found *post mortem*. (B) LIVER. Hepatitis with great enlargement has been reported not infrequently. Miliary abscesses may occur. (C) KIDNEY. Acute nephritis may occur; cystitis also is found. (D) *Orchitis* occurs, but rarely. (E) RESPIRATORY TRACT. Dryness of the mucous membranes, erosion of epithelium, suppuration of the nasal septum, and cicatricial adhesions may occur. Suppuration of the NASAL ACCESSORY SINUSES is not infrequent. The LARYNX may show ulcerations, usually on the posterior wall. Diphtheritic inflammation of LARYNX and PHARYNX is sometimes found. Bronchitis, pleurisy, and hypostatic or catarrhal pneumonia are not unusual. Abscess and gangrene of the LUNGS have been reported. (F) *Phlebitis* is very common. (G) *Pericarditis* and *endocarditis* may occur. (H) Bleeding of the skin, *gangrene*, and *purpura* are found. An eruption sometimes occurs over the buttocks and malleoli. (I) The VOLUNTARY MUSCLES may show waxy degeneration and hemorrhages. (J) BONES and JOINTS. Periostitis may occur, according to Elliott and Washburn most frequently in the TIBIA. They report also cases of felon in the INDEX FINGERS. Others have reported affections of the RIBS, COSTAL CARTILAGES, and STERNUM. Arthritis may occur. Typhoid spine is a painful complication, causing at times marked curvatures.

BACTERIA OF THE TYPHOID GROUP CAUSING DISEASE.—The *Bacterium coli commune* is constantly present in the INTESTINE of man, and is a frequent invader of the internal organs, especially when intestinal lesions are present. The *lesions* which in certain cases are without doubt due to this bacillus are, (a) *cystitis* and *pyelonephritis*; (b) inflammation of the BILIARY PASSAGES; the organisms have been found in the centre of gall-stones; (c) *peritonitis*; (d) *appendicitis*; (e) in some cases of a general infection resembling

¹ *Philadelphia Hospital Reports*, 1893, vol. ii, p. 140.

typhoid fever, this bacillus has been obtained in pure culture from the blood. Among other conditions which have in certain cases been attributed to it are, *puerperal infections*, *endocarditis*, *meningitis*, *tropical abscess* of the liver, *bronchopneumonia*, *putrid bronchitis*, *cholera infantum*, and *dysentery*.

For an account of the lesions due to the paratyphoid, see p. 181.

TYPHUS FEVER is an infectious disease, characterized by a sudden onset, a macular rash, nervous symptoms, and a cyclic course ending in crisis. No micro-organism has as yet been demonstrated as the cause of typhus fever, though several have been described as having been isolated from those affected with this disease.

Lesions.—No characteristic lesions are found *post mortem*, and the anatomic changes are simply those produced by severe fever. (A) The BLOOD is dark and fluid. (B) The entire BODY tends to rapid putrefaction. (C) The VOLUNTARY MUSCLES may undergo waxy and granular degeneration. (D) The BRAIN and MENINGES are congested. (E) The mucous membranes of the MOUTH and the RESPIRATORY TRACT may show catarrhal inflammation. (F) The HEART-MUSCLE may be soft and flabby, and the ENDOCARDIUM, as well as the lining of the great vessels, may be stained bright red. (G) The organs may undergo *parenchymatous degeneration*.

VARICELLA (CHICKEN-POX) is an acute contagious disease of childhood, characterized by a papular and vesicular rash; its cause is unknown. The disease is rarely fatal and is therefore not often seen *post mortem*.

Lesions.—(a) The chief lesion is a *cutaneous rash*, consisting of raised red papules which in a few hours become vesicular, and in four days are converted into mahogany-brown crusts. Chicken-pox may appear coincident with smallpox. In tuberculous patients, gangrene may occur about the vesicles. (b) *Nephritis* is the only other lesion found.

VACCINIA is a local disease due to inoculation with the virus of cow-pox; it is characterized by a single lesion like that of smallpox, with slight constitutional disturbances. In rare instances, the pock may recur at irregular intervals, or may become generalized; generalization usually occurs the eighth day, on the back and wrists. Vaccinia is seldom fatal, except with children. *American Medicine* (1902) reports a case of generalized vaccinia, due very largely to scratching, by which fresh inoculations were made. The pitting is as marked as in smallpox.

YELLOW FEVER is an infectious tropical disease, due to an unidentified organism, the only known natural way of transmission being by a variety of mosquito, the *Stegomyia fasciata*. The formerly much discussed *Bacillus X* of Sternberg and the *Bacillus icteroides* of Sanarelli, sometimes considered to be identical, are no longer thought to be the cause of yellow fever. The interesting work done by Reed, Carroll, and Agramonte, in Havana, showing the true etiologic significance of the mosquito in this affection, is one of the most important contributions to medical science during the past decade, and renders them well worthy of the Nobel prize.

Lesions.—(A) The SKIN is more or less jaundiced, and is sometimes ecchymotic. (B) The BLOOD is tarry in consistency. (C) The STOMACH and INTESTINES may be hyperæmic, or may show a catarrhal or at times hemorrhagic inflammation. The stomach contains a tarry fluid. (D) The LIVER and HEART show high-grade fatty degeneration, with areas of necrosis. (E) The KIDNEYS show diffuse nephritis with necrotic areas.

PATHOGENIC ANIMAL PARASITES.

I. PEDICULI. The *Pediculus capitis* marks a condition most frequent in children. The female louse measures from one and eight-tenths millimetres to two millimetres in length; the male is somewhat smaller. In copulation the male lies beneath the female. The color of the parasite varies directly with the color of the skin of the infected person. The ova are grayish glistening specks, each enclosed in a membrane; they are attached firmly at an acute angle to the shaft of a hair not far from its root, the opening through which the parasite escapes being turned away from the scalp. The animals cause considerable irritation and arouse a pustular eczematous eruption. In severe cases the hair on the back of the head may be found matted with soft yellow crusts, while the scalp is covered with moist red granulations. The POSTERIOR CERVICAL LYMPHATIC GLANDS are enlarged, and may first call attention to this affection. The *Pediculus pubis* is smaller than the *Pediculus capitis*, and is somewhat triangular in shape. It infests regions where the hair is short, such as the AXILLARY, PUBIC, and PERIOCCULAR regions. The parasite may be found at the root of the hair, its head buried in the follicle. An eczematous eruption results from the irritation. The *Pediculus corporis (vestimenti)* is the largest of these parasites, and differs slightly

from those described above. It lives in the clothing when not in search of food on the body. By its constant irritation it causes *dermatitis*, and if present for a long time, pigmentation and thickening of the skin.

II. The *Cimex lectularius* (common bedbug) produces an inflammatory and somewhat hemorrhagic papule which disappears promptly. They probably transmit many diseases, as cerebrospinal meningitis, relapsing fever, tuberculosis, etc.

III. *Pulex irritans* (the common flea) produces an erythematous spot with a minute central hemorrhagic point. An irritable wheal-like lesion may result. The *Pulex penetrans* (the sand-flea or jigger) is common in tropical and subtropical countries. It is smaller than the common flea. The pregnant female burrows under the SKIN, especially about the toes, and produces a pustular swelling which may ulcerate. The *Pulex cheopsis* may transmit plague.

IV. The bite of *Ornithodoros savignyi*, a tick, is the cause of eight cases of fever, none of which was fatal, reported by Ross and Milne.¹

V. The *Sarcoptes (Acarus) scabiei* (itch-mite) is a pearly white arachnid, the female being about .45 millimetres long and .35 millimetres broad; the male is about one-half this size. The female parasites only are found in the SKIN, chiefly where it is moist, as in the webs of the fingers and toes, the flexor surfaces of the wrists, about the mammæ in the female, and on the shaft of the penis in the male. The burrows are the characteristic lesion; they are thread-like formations, tortuous or straight, dotted, slightly elevated, and blackish, and from one-eighth to one-half inch in length. They are made by the impregnated female, which penetrates the epidermis obliquely to the rete, depositing as it goes excrement as well as ten or fifteen ova. Eczema, which may mask the burrow formation, develops as a consequence of the irritation.

VI. The *Demodex folliculorum*, a species of acarus, is a worm-like body, .3 millimetres to .4 millimetres long. It is found in the HAIR-FOLLICLES in the skin disease called *comedo*, which is characterized by the formation of yellowish or blackish elevations of the size of a pin-head, corresponding to the gland-orifices. Some deny the etiologic significance of the parasite to this disease.

¹ *Brit. Med. Jour.*, November 26, 1904, p. 1453.

VII. The *Pentastoma tænitoides* is a worm-like ascarid, the male of which is from eighteen to twenty millimetres long, while the female varies between seventy and one hundred and thirty millimetres. The larvæ are five millimetres long. The larval form occurs encysted in the LIVER, and the adult form is found in the FRONTAL SINUSES of dogs and wolves. *P. constrictum* also occurs.

VIII. The most important of the parasitic infusoria are, (1) *Cercomonas intestinalis*, which is found in fæces of *diarrhœa*, *cholera*, and *typhoid fever*; (2) *Trichomonas vaginalis*, which occurs in the secretion of the VAGINA, in the URINE, and in the SPUTUM; and (3) *Paramecium (Balantidium) coli*, found in the fæces of *diarrhœa* and the sputa from abscess of the lung. It has been known since 1857 that this oval-shaped ciliated infusorion, which measures about one millimetre in length, may cause intestinal infection in man. The disease is also present in swine and in the orang-outang.

MYIASIS.—A condition caused by the larvæ of certain flesh-flies, of the common house-fly, or of the bot-flies of oxen or sheep. The ova of these flies may be deposited in the nostrils, ears, or conjunctiva, in open wounds, or even in the vagina during the puerperium, and there develop into larvæ, which live on the mucous membrane of the part. They may even destroy bone-cartilage and muscle.

CESTODES (TAPEWORMS).—I. The *Tænia solium* is introduced into the human DIGESTIVE TRACT by the ingestion of so-called "measly" pork, which contains the embryo, the pig being the intermediate host. In the mature form the worm may be twelve feet or even more in length, and several may infest the intestines at one time. It is composed of numerous segments about one-third inch long and averaging one-fourth inch in width. The head is very minute, no larger than that of a pin, and bears four suckers; in front is a rostellum, and at the base of this is a double row of hooklets. The genital pore is marginal, and leads to a linear uterus. The worm is hermaphroditic. When mature, thousands of ova are passed by the rectum. The embryo has six hooklets. It penetrates the walls of the stomach and burrows into the tissues of the animal that has swallowed it. The *Cysticercus cellulosæ*, the larval form of the *Tænia solium*, is found in the MUSCLES, BRAIN, CORD, PERITONEUM, or almost any other tissue of the affected animal. The surrounding capsule is frequently calcified.

II. The *Tænia saginata* is introduced into the human DIGESTIVE

TRACT by the ingestion of raw beef, the ox being the intermediate host. It is larger, longer, and of more frequent occurrence in this country than the *Tania solium*. The head is nearly square, and measures more than two millimetres in breadth, but has no hooklets. The segments are larger than those of the *Tania solium*. The reproductive organs are on the ventral aspects of the segments, in the median lines.

III. The *Bothriocephalus latus* is the largest and longest of the flatworms, being in the mature state twenty-five feet or more in length; it may have over 4000 segments. It has no hooklets, but is furnished with slit-like fossæ on the head, which act as suckers. The genital pore is central. The embryo has six hooks and ciliated prolongations. This parasite may occur in dogs and cats.

IV. The *Tania flavopunctata* is very rare. It is about sixteen centimetres long.

V. The *Tania echinococcus* is a very small, thread-like tapeworm, being from three to six millimetres in length and having only three segments. The last segment contains the generative organs and genital opening. It is thrown off when the ova are ripe, and may be found in the fæces. The head has four suckers, a rostellum, and a double row of hooklets. The embryos (scolices) are found in the ox, hog, sheep, and horse, and in man. *Echinococcus disease* is found most frequently in those countries, as Iceland, Northern Europe, and Australia, where the dog in which the worm takes growth lives in intimate association with man;¹ it is characterized by the formation of endogenous or exogenous multilocular cysts in various portions of the body, most commonly in the LIVER, but also in the LUNG and PLEURA, the INTESTINAL TRACT, the KIDNEY, the BLADDER, the GENITALIA, the BRAIN, etc. The embryo, freed from the cyst by digestion in the stomach, burrows through the intestinal wall and is carried to the various organs; it then loses its hooklets and is gradually converted into a cyst (hydatid) having two walls, of which the external is laminated, and the internal is granular or parenchymatous, containing blood-vessels and muscle-fibres. The interior is filled with a clear non-albuminous fluid, of specific gravity 1.005–1.009, usually containing sugar and hooklets. From irritation of the

¹ According to Senn the worm is not found in Eskimo dogs and Arctic hares (*Jr. Amer. Med. Assoc.*, November 25, 1905).

surrounding tissues a fibrous capsule generally develops on the outside. The cysts vary in size from that of a small pea to that of a child's head. From the inner (parenchymatous) layer may develop brood capsules, which in their turn produce numerous scolices. The cysts grow slowly, and when the embryo dies, the whole may become calcified. Sometimes the cysts suppurate; occasionally they rupture into the adjacent structures.

VI. Other tapeworms, as the *Tænia pisiformis*, *Tænia nana*, *Tænia cucumerina*, *Bothriocephalus mansoni*, and *Tænia madagascariensis*, are very rare except in the tropics.

In the making of many autopsies it is surprising how few tæniæ are found in the intestinal tract. My experience comprises but two cases. One of these was that of a man who committed suicide with opium. Two *Tæniæ saginata* were found, the head of the first one being firmly attached beneath a fold of one of the valvulæ conniventes, high up in the jejunum, and the other, five or six feet further down the intestine, the segments of both worms then continuing on down to near the ileocæcal valve.

NEMATODES (ROUND WORMS).—I. The *Ascaris lumbricoides* is a cylindrical worm with both ends pointed; the head ends in three lips. The female is from ten to sixteen inches in length, the male considerably smaller. It is brownish yellow, reddish, or white in color. It may be found in great numbers in the INTESTINAL CANAL, and has been known to wander into the stomach, and exceptionally into the MOUTH, NOSE, BRONCHI, GALL-PASSAGES, PERITONEAL CAVITY, etc. This is especially apt to be the case after death.

II. The *Oxyuris vermicularis* (*Seat-worm*) is a very small round worm, about 10 mm. long. The eggs are oval, are about 0.05 mm. long, and are produced in great numbers. These worms are very common in children, occurring in the CÆCUM, COLON, and RECTUM. In very severe cases they may be found in any part of the ALIMENTARY TRACT and in the VAGINA and BLADDER. A pustular eruption around the anus is often produced.

III. The *Trichina spiralis* is a dangerous and common parasite, ingested by man in insufficiently cooked pork, the muscle of the diseased pig containing the embryo in encysted form. The embryonic capsule is dissolved in the STOMACH and the embryos thus set free grow and multiply rapidly. The tiny worms find their way through the walls of the gut to various parts of the body. They enter the

STRIATED MUSCLES, disintegrate the substance, and coil within the sarcolemma, there becoming surrounded by a capsule which subsequently calcifies. Resulting lesions may be *acute catarrhal enteritis*, *œdema*, *bronchopneumonia*, and *fatty degeneration of the liver*. The lymphatic glands, blood, and marrow may contain eosinophiles in great numbers during life, but after death these are diminished or absent. In severe cases, these cells accumulate in the lungs until the collection resembles a small abscess.

IV. The *Ankylostomum duodenale* (*Uncinaria duodenalis*; in America, the *Uncinaria Americana*) lives in the upper part of the INTESTINES, but is seldom found below the duodenum. The female is the larger, and varies from ten to sixteen millimetres in length. At the anterior portion of its head are hooklets, with which it attaches itself to the intestinal walls. It is frequently associated with *Egyptian chlorosis*. Stiles and Harris have recently called attention to the wide distribution of *uncinariasis* in the South; which disease may be readily recognized by finding the ova in the fæces. At autopsy, *catarrhal gastro-enteritis* with hemorrhagic spots is found. Adult worms, from 1 to 1000 in number, may be found in the duodenum, with their heads buried in the mucosa. The subcutaneous tissue is œdematous, and there is effusion into serous sacs. Calmette¹ has infected young dogs with the human and the canine ankylostoma by way of the skin, while Claude A. Smith has shown experimentally that infected dirt rubbed on the healthy skin of the hand is capable of causing inoculation, the disease subsequently being cured by thymol.

V. The embryo of the *Filaria sanguinis hominis* is a round worm, one seventy-fifth to one one-hundredth of an inch long, enclosed in a delicate sheath. It circulates freely in the blood, but only at night. The adult parasite is located in the lymphatic vessels, and owing to the obstruction and local irritation which its presence produces it may give rise to *chylous ascites*, *lymphangiectasis*, *œdema*, abscesses, and perhaps *elephantiasis*. The worm is introduced into the body by the mosquito.

VI. The *Trichocephalus dispar* (*Whip-worm*), a small worm, thick at one end and thread-like at the other, is found in the LARGE INTESTINE, COLON, and CÆCUM. It is a frequent cause of *anæmia*.

¹ *Bull. de l'acad. de méd.*, 1905, vol. lxi, no. 12.

VII. The *Rhabdonema intestinale* is a minute slender worm, measuring two millimetres by six one-hundredths of a millimetre. The female has a string of five or six ellipsoidal eggs, each measuring one one-hundredth by thirty-four one-thousandths of a millimetre.

VIII. The *Strongylus subtilis* is found only in Egypt, and is not important.

TREMATODES (FLUKES).—These worms are lanceolate in shape, quite flat, and possess a distinct head and neck. They are three-fourths of an inch long and about half an inch broad. The color is dull brown. The *Distoma* is the most common genus found in man.

I. The *Distoma hæmatobium* (*Blood-fluke*) has two suckers, one near the mouth and the other near the ventral portion of the body. The female has a grooved channel posteriorly for the reception of the male. This parasite is found chiefly in the PORTAL SYSTEM and in the veins of the BLADDER. The ova are found in the urine; they are elongated ovoid bodies, sharply pointed at one extremity, and containing black pigment, and can easily be seen with a low power of the microscope.

II. The *Distoma hepaticum* (*Liver-fluke*) is ingested in the form of ova attached to waterplants, and infests the upper INTESTINE, the BILE DUCTS, the GALL-BLADDER, and the LIVER. It causes the "liver-rot" in sheep.

III. The *Paragonimus Westermanii* causes *parasitic hæmoptysis*, which now occurs in America as well as in Asia. The eggs are found in the sputum, and the fluke measures from eight to sixteen millimetres in length by four to eight millimetres in breadth.

IV. The *Distoma ophthalmobium* and the *Distoma ringeri* have been described as occurring in the EYE and the LUNG.

V. The *Schistosoma Cattoi*, or *S. japonicum*, is a new form of blood-fluke discovered by Catto.¹ The post-mortem examination of a Chinaman from Fukien Province, who died of cholera after a three days' illness, showed a large amount of adipose tissue throughout the body, an enlarged liver and spleen, a thickening of the walls of the gall-bladder, indications of repeated attacks of peritonitis, and a thickening of the intestinal walls which increased towards the lower portion of bowel until the rectal walls were three-fourths of an inch

¹ *Jr. Amer. Med. Assoc.*, February 4, 1905.

thick. The stomach, pancreas, suprarenals, kidneys, heart, lungs, and the mucous membrane of the bladder were not involved. On section, a number of adult trematodes were found in the blood-vessels of the mesocolon, the filariform embryo and ova were present in the mucosa and villi of the large intestine, and numerous small oval bodies having a smooth stout capsule were discovered in the liver and the mesenteric lymph glands. These were identical with the ova found in the uterus of the female. This new blood parasite resembles the *Schistosoma hamatobium* in a general way, but differs from it in an apparent preference for the arterial instead of the venous channels as a habitat, and in its selection of the alimentary tract instead of the urinary system as the avenue of escape for the ova. A second case has been described by Henry G. Beyer in *American Medicine* for September 30, 1905.

AMŒBÆ COLI are considered on page 315.

HÆMATOZOA.

MALARIA.¹—This widely distributed and much studied infectious disease is due to a hæmatozoön, the *Plasmodium malariae*, and is transmitted to man by the *Anophelina* mosquito. The disease is characterized by a chill followed by fever, and by a period of remission. Schilling² reports a case of tertian fever occurring eight and one-half months after the patient had left Africa, and two and one-half years after his last attack, although no opportunity of becoming reinfected existed in the meantime. Negroes may have the malarial parasites in their blood without showing any symptoms of the disease. According to Celli, the eggs of the *Anopheles claviger*, at a temperature of 20°–25° C. develop in about one month into insects, which in another thirty days lay eggs. The æstivo-autumnal parasites, at a temperature of 30° C., undergo their entire development, including the formation of sporozoits, in about one week.

Lesions.—(a) In *acute malarial fever*, which may be quotidian, tertian, or quartan, uncomplicated cases are rarely fatal. The BLOOD shows disintegration of the red corpuscles, and an accumulation of

¹Laveran's earliest works are: *Nature parasitaire des accidents de l'impaludisme*, Paris, 1881; *Traité des fièvres palustres*, 1884. An excellent diagram showing the cycle of development of this parasite will be found on page 259 of GREEN'S *Pathology and Morbid Anatomy* (1905).

²*Deut. med. Wchschr.*, March 5, 1903.

pigment is thereby formed. The SPLEEN is enlarged, dark in color, and may show pigmentary deposits. (b) In *pernicious malaria* the blood contains enormous numbers of the parasites, though at the postmortem most careful search may fail to reveal Laveran's organism. The RED CORPUSCLES are in all stages of destruction, and the serum is tinged with hæmoglobin. Hydræmia is marked. The SPLEEN is moderately enlarged. The pulp is soft, chocolate-colored, and turbid, containing large numbers of red corpuscles and parasites and a greatly increased amount of pigment. The LIVER is swollen and presents areas of focal necrosis and capillary thrombosis. The GASTRO-INTESTINAL MUCOUS MEMBRANE is congested; the capillaries may contain numerous hæmatozoa, and thrombosis may cause ulcerations of the mucosa. Pigmentary deposits are also common. The KIDNEYS present a more or less parenchymatous change, with only moderate pigmentation. The BRAIN may show thrombosis (due to the parasites), with secondary softening of the surrounding tissue. There may be advanced fatty degeneration of the HEART. (c) In *chronic malarial cachexia* the BLOOD presents all the characteristics of an advanced anæmia, the disease often being distinguishable from pernicious anæmia only by the presence of the parasite, and by icterus. The SPLEEN is greatly enlarged, weighing in certain cases from seven to ten pounds, and is firm and resistant to the knife. The capsule is thickened, and the parenchyma is brownish or slate-colored, with areas of pigmentation. The KIDNEYS are enlarged, and of a grayish-red color. The PERITONEUM is thickened, opaque, and of a deep slate color; and the GASTRIC and INTESTINAL MUCOUS MEMBRANES have sometimes the same hue. The gray matter of the BRAIN is of a deep reddish-gray color, or in very chronic cases, a chocolate brown. The MENINGES are congested. (d) In the *æstivo-autumnal* form, cirrhosis of the LIVER is sometimes found. Very extensive pigmentation may occur. Pneumonia is believed to be common. Rupture of the capsule of the enlarged SPLEEN may occur, followed by hemorrhage into the PERITONEUM, and even by peritonitis. Moderate albuminuria is frequent; acute nephritis may follow long-continued or repeated infection.

PSOROSPERMIASIS is a condition produced by the presence of oval transparent bodies belonging to the *Coccidia*, to which class the malarial organism also belongs.

Lesions.—I. *Internal form.* (A) The LIVER may be enlarged,

and may contain caseous foci surrounded by areas of congestion. In the majority of cases it has been found to contain the organisms. (B) Upon the PERITONEUM, OMENTUM, and PERICARDIUM have been found whitish growths resembling tubercles, and containing the coccidia. (C) In the SPLEEN, KIDNEYS, and URETERS similar masses have been found.

II. *Cutaneous form.* The lesions closely resemble those of tuberculosis of the skin. The organisms are found in *Paget's disease* of the nipple, and by some are believed to be its cause. In some cases of *molluscum contagiosum*, they are also present. The cutaneous disease is always associated with internal lesions.

A case has been reported in which at autopsy nodules were found in the LUNGS, ADRENALS, TESTICLES, and SPLEEN, on the surface of the LIVER, and on the PLEURÆ. Great numbers of the sporozoa were found in the lesions. Successful inoculations have been made into rabbits and dogs.

TRYPANOSOMA.—Four animal diseases, nagana, surra, *mal de caderas*, and dourine,¹ are caused by varieties of trypanosomes. Recently Nepveu, Dutton, and others have found these parasites in man, and the sleeping sickness and the so-called trypanosoma fever (different stages of the same disease) are due to the entrance into the blood and cerebrospinal fluids of *Trypanosoma gambiense*. These organisms are transmitted to human beings by tsetse flies (*Glossina palpalis*). Monkeys, dogs, cows, horses, and rats are also susceptible to certain species. *Trypanosoma Lewisi* infests the rat and is transmitted by fleas and lice. *T. Evansi*, *T. Brucci*, and *Equinum equiperdum* attack horses, and the *T. disea* infests birds. The tsetse fly carries the human parasite and the *T. Brucci*. These parasites are fusiform flagellated protozoa, several times larger than a blood-corpuscle. Along one margin an undulating membrane extends from the centrosome to the anterior end of the body, where it becomes a true flagellum. The parasite is non-sexual, reproducing by longitudinal division. It lives in the blood serum and attacks the red cells. The tsetse fly can carry the infection from sick to healthy up to forty-eight hours after having fed. Artificial cultivation to the hundredth generation of the *T. Lewisi* from the rat has been made lately by

¹ An historical account of this disease, by Koch, will be found in the *Lancet*, November 26, 1904.

McNeal and Novy,¹ and the first strictly pure cultures of the pathogenic animal parasite have thus been obtained. The agglutination reaction occurs under proper conditions. Coplin² showed these organisms from rats caught in the Philadelphia Hospital, and also a slide of the lungs evidencing pneumonic changes. Ehrlich and Shiga, experimenting with the organism, found that the stain trypan red was able to destroy the trypanosomes in mice and to protect them against relapses; the stain was equally effective when given by the stomach. The skin is well reddened in eight minutes and reaches a maximum color in twelve hours, and the tint remains for from six to eight weeks, longer in the internal organs. This stain has little or no effect on rats, guinea-pigs, or dogs.³

The Leishman-Donovan bodies were first found in the spleen. These parasites are by no means uncommon in the tropics, and are situated intracellularly in large mononuclear macrophages. Rogers has recently announced that trypanosomes develop upon culture of these bodies. Other observers still oppose this view, and believe the Leishman-Donovan bodies to be an entirely new genus of hæmatozoa, to infection with which may be attributed the so-called "Dumdum fever" and the Delhi boil of India, and the "Kala-azar" of Assam. The bodies have been found in blood obtained by splenopuncture *intra vitam*, as well as *post mortem* from the spleen, liver, kidneys, mesenteric glands, walls of intestinal ulcers, and skin lesions. It has been suggested that the splenomegalies seen in this country may be due to infection with this parasite.

¹ VAUGHAN'S *Dedication Volume of Medical Research*, 1903.

² *Phila. Path. Soc.*, December 10, 1903.

³ *Berl. klin. Wchnschr.*, March 28, 1904, p. 239; April 4, 1904, p. 362.

CHAPTER XXII

THE PREPARATION OF TISSUES FOR MICROSCOPIC AND MACROSCOPIC OBSERVATION ¹

METHOD OF EXAMINING SCRAPINGS AT THE AUTOPSY.—Scrapings from fresh tissue are best collected by a sterilized platinum scoop, or they may be secured by scraping the tissue with a small scalpel. The material thus collected is to be at once transferred to a slide containing a small amount of the physiologic sodium-chlorid solution, prepared in the strength of 0.9 per cent. for warm-blooded animals and 0.6 per cent. for cold-blooded ones. A much better solution for this purpose, and one that should be kept ready for use in all laboratories, is sterile blood-serum or hydrocelic or ascitic fluid, which may be preserved until wanted for use in the special form of pipette described in the next chapter, upon "Bacteriologic Investigations." Fluids rich in cellular matter are best diluted with one or the other of the above-mentioned solutions. Those poor in cells are first to be centrifugated; this is especially true in case an examination be desired of the apparently normal pericardial or cerebrospinal fluids. The hanging drop is an excellent means for the examination of such a mixture by the microscope. If the apparatus for this procedure is not at hand, the cover-glass may be raised by four or five small drops of sealing-wax so as to prevent pressure, or small pieces of a broken cover-glass may be so arranged as evenly to support the cover-glass. This is then surrounded by a ring of vaselin to prevent evaporation. An ingenious method of supporting the slide is described by Arnold,² in which elder-pith prepared in the form of rings supports the cover-glass, this porous

¹ Based on the works of LEE, *The Microtome's Vade Mecum*; MALLORY and WRIGHT, *Pathological Technique*; APÁTHY, *Die Mikrotechnik der thierischen Morphologie*; FISCHER, *Fixirung, Färbung, und Bau des Protoplasmas*; SZYMONOWICZ, *Lehrbuch der Histologie*; STÖHR, *Text-book of Histology*; BÖHM and von DAVIDOFF, *Text-Book of Histology*; *Lehrbuch der Klinischen Untersuchungsmethoden*; *Die Encyclopädie der mikroskopischen Technik*, 1903; and SCHMORL, *Die pathologisch-histologischen Untersuchungsmethoden*, 1905. The ultraviolet microscope, which reveals particles with a linear diameter of 0.000001 millimetre, has already rendered valuable service in the securing of excellent photomicrographs.

² *Archiv. f. wissenschaftl. Mikrosk.*, vol. lii (quoted by SCHMORL).

material permitting the introduction of the stain through it from without. The materials especially employed for staining are neutral red, 0.01 to 0.1 per cent., and methylen blue dissolved in a 0.75 per cent. sodium-chlorid solution; or 0.1 per cent. methylen green, Löffler's methylen blue, or a weak solution of acid fuchsin may be employed. Other agents—such as Lugol's solution, one-per-cent. osmic acid, and acetic acid—are also most useful. Bismarck brown and Van Gieson's stain are much to be desired when photomicrographs are to be taken, as the brown color is capable of giving good plates without the application of colored screens, as is necessary with many of the staining reagents. Solid tissues are teased in the physiologic salt solution, or for the purpose of quick maceration are mixed with a freshly prepared solution of sodium hydrate in the proportion of one to three. A trypsin preparation, such as pancreatin, may be employed to study artificial digestion, keratin, neurokeratin, and reticular fibrils alone remaining after the action of the trypsin.

The method of preparing dry films is given on page 384. Jenner's fluid is most useful in the staining of such preparations. It is prepared as follows: 0.5 gramme of the eosinate of methylen blue is dissolved in 100 cubic centimetres of *absolute* methyl alcohol. A few drops of this stain are placed on the *fixed* or *unfixed* specimen, and allowed to act for from thirty seconds to two minutes. The slide is then washed several times in water.

The Giemsa stain, so much spoken of in the staining of the *Treponema pallidum* of syphilis, may be purchased in the shops, or may be prepared as follows: Azur II eosin, 3.0 grammes; azur II, 0.8 gramme. These are thoroughly dried over sulphuric acid in an exsiccator and then *finely* powdered, preferably by passing through a silk sieve. The mixture is then dissolved in pure glycerin, 250 grammes, at a temperature of 60° C., and methyl alcohol, 250 grammes, heated to the same degree, is then added. The mixture is then put aside for twenty-four hours at room temperature, and then filtered. In practice the stain is used when diluted with water (one drop to one cubic centimetre of water), or with water rendered alkaline by a few drops of 0.01 per cent. solution of potassium carbonate. The film is best fixed in pure methyl alcohol, and staining takes place in from ten to fifteen minutes. The film is then washed in water and mounted in the usual way. Another method of staining this parasite is by silver nitrate, as in Golgi's method.

METHOD OF PREPARING FROZEN SECTIONS.—There is nothing which adds so much interest to a postmortem as the immediate preparation of frozen sections. This takes but ten or fifteen minutes and may be carried on by an assistant during the performance of the autopsy, and the slides may then be compared at once with the gross morbid lesion. Before the Philadelphia Pathological Society, on December 10, 1896, the author gave a demonstration of tissues prepared by ethyl and methyl chlorid as the freezing agent, and this method is to be recommended for those who do not have the more elaborate apparatus necessary for the preparation of tissues by carbon dioxid or ether. The one objection is the cost of this method, which should not, however, be over six or seven cents for each slide prepared. If there be plenty of time, the pieces of tissue under examination are fixed and hardened in Orth's fluid for three hours. At the end of this period they are removed and thoroughly washed in running water for several hours. Alcohol is gradually added until they are finally placed in absolute alcohol. The tissues are then washed in water and immersed in a solution of acacia and sugar, prepared as follows: Boil 28.5 grammes of lump sugar in 30 cubic centimetres of water, and when cool add 1 cubic centimetre of formalin. A mucilage of gum acacia, 1 part, and formalin (1 per cent.), 50 parts, is prepared without the aid of heat. Equal parts of these two solutions are mixed as needed, and diluted with water. The stronger the solution the more slowly will it freeze, but the less harm will it do to the tissues. This procedure takes twenty-four hours. If a quick method be desired, pieces of tissue 2 by 4 by 4 millimetres are placed in the formo-acacia fluid. They remain in the solution for ten minutes. If time presses, or in the event of an operation with the patient anæsthetized, this step may be omitted. The pieces of fresh tissue are at once frozen in this solution, or in one of dextrin, in the paraffin-holder of a microtome. A small stream of ethyl chlorid or methyl chlorid, or preferably a mixture of the two, is played from above directly upon the specimen at a distance of about one foot. The tube is moved from place to place until the specimen is firmly attached to its base of support. It is interesting to watch the freezing process start from the edges and proceed towards the centre until the whole is coated with ice. Such crystals are extremely small and delicate and do not injure the tissues as in some other of the freezing methods; then, too, these chlorids possess definite fixing properties apparently not possessed

by carbon dioxid, though to a certain degree found in ether. Thirty seconds to a minute is usually sufficient to freeze the specimen. Such sections are at once transferred to a one per cent. sodium-chlorid solution, the heat of the finger being employed to melt the section if it become frozen to the knife. Any stain may next be employed. Sudan III gives good results, especially in tissues containing fat. Dr. Lewis B. Wilson¹ recommends that they be stained for from ten to twenty seconds by constant movement in a neutral polychrome-methylen blue solution. They are next washed in one per cent. sodium chlorid and mounted in the glucose solution. Wederhake² puts the fresh frozen section, without rinsing, in tincture of iodine (2 to 5 drops in twenty cubic centimetres of water). The section is then transferred at once to a twenty per cent. dilution of a stain made by dissolving crocein scarlet 7 B in 10 cubic centimetres of 70 per cent. alcohol until the alcohol will not dissolve any more. It does not take up much. After from one-half to three or five minutes in the stain, the specimen, still held on the spatula, is rinsed and soaked in water for a minute or two—five minutes would probably dissolve out all the stain. The specimen is then allowed to slide off the spatula into a drop of glycerin on the object glass, when it is ready for the microscope after being covered with a cover-glass. If the specimen is already fixed, it has to be soaked for two hours in forty per cent. formalin, and then rinsed in water for two hours, after which the technic is the same as for fresh specimens. If the results are not satisfactory, or to control them, the stain can be washed away with diluted ammonia and any other stain then used.

PRESERVATION OF TISSUES FOR MICROSCOPIC STUDY AND THE CHOICE OF THE FIXING AGENT.—When tissues are to be preserved for microscopic study, the method of fixing and hardening them should be decided upon at the time of their removal from the body. The object to be attained by fixation and hardening is permanently to solidify the structural elements of a part as nearly as possible in their original form and situation and thus prevent both shrinkage and expansion. All our present methods, however, fail to give an accurate picture of the living cell, and not enough attention is now paid to the microscopic examination of fresh scrapings removed during the per-

¹ *Jr. Amer. Med. Assoc.*, December 2, 1905.

² *Centralbl. f. Gynäk.*, vol. xxix, no. 25.

formance of the autopsy, when cloudy swelling, dropsical changes, and mucoid degeneration may be studied at their best. The use of as perfectly fresh tissues as possible for microscopic study is essential, for many structural details disappear upon molecular death. Fortunately, this does not occur until several hours after molar death, so that it is often possible to obtain tissues to all intents and purposes still living. Special attention should be paid to those tissues which have been stained or hardened by reagents introduced during life into the body under examination; experimental staining of living tissue affords a most inviting field of original investigation.

The wrapping of tissues in paper or cloth for transporting them to a distance is to be regarded only as a last resort. When this is done, pieces of sufficient size to insure preservation of their interior intact are enveloped in an abundant supply of clean cotton (antiseptic gauze causes markings on them), moistened very slightly with a 1-1000 bichlorid solution, which will act as a preservative, prevent the subsequent adherence of the cover to the specimen, and thoroughly protect it from pressure; these segments are cut down to a proper size before they are put into the fixing agent in the laboratory.

Bottles containing the more common fixatives should be ready, and as soon as the tissues are exposed and described,—before the part becomes distorted, fluids escape, or surfaces dry,—they should be cut with a clean, sharp knife into pieces of not over one-fourth to three-eighths inch in thickness. I sometimes cut the pieces in different shapes, each piece representing an organ or part, and always use the same shape for the same part. Sections of organs should include their characteristic structures,—cortex, capsule, hilum, endocardium, etc. Sections of tumors should be taken from the centre, where degenerative changes are most marked, and from the growing peripheral margin, if possible including some normal tissue; this is of especial importance in the case of malignant tumors. Mucous and serous membranes are pinned out on cork with hedgehog bristles or other non-corroding substance (as horn, or wood that will give no stain when soaked in the preservative fluid to be used), with their secreting surfaces uppermost. Muscle-fibres are best preserved by being tightly stretched upon and tied at the ends of a piece of wood. The segments of tissue, without being touched by either fingers or forceps, are lifted on the blade of the scalpel and dropped immediately into a bottle containing an amount of fixing fluid far in excess of their bulk. Of

energetic fixatives, such as Flemming's or Hermann's, about fifteen times the volume of the object introduced will suffice, while of milder fluids, like the bichromate of potassium or picric acid solutions, twenty to fifty times such volume may be employed with advantage. As the method of staining to be employed is not always known, it is wise to harden portions of important tissue in alcohol, corrosive sublimate, formalin, and osmic acid.

If the different tissues are distinguishable macroscopically, they may be placed in the same jar; if not, separate bottles are better. Tags may be attached, the writing being done with a lead-pencil, so as not to be acted upon by the usual preservatives. The jars are labelled with the date, the number or name of the autopsy, and the fixative used. It is often of importance to add the exact locality from which the pieces have been removed and the plane on which they are to be cut when placed in the microtome.

The fluid should always be changed after it becomes turbid; or in the case of alcohol or formalin, preferably after three hours, whether it is turbid or not. If the specimens are to be sent away, they should not go until the fluid remains clear; if the time necessary for transportation exceeds that of the proper action of the fixative, they should be worked up to 80 per cent. alcohol by thorough washing in water for several hours, and then in successive strengths of alcohol, 33 $\frac{1}{3}$, 50, 70 per cent., and shipped in that fluid, carefully protected by being surrounded with absorbent cotton.

The choice of a fixing agent is determined by the nature of the object to be preserved and the purpose for which the investigation is undertaken. Certain fixing agents, such as osmic acid, chromic acid, potassium bichromate, and corrosive sublimate solutions, seem to form a chemic union with the cell contents and so produce an extremely durable insolubility. Others, such as picric acid and nitric acid, harden well, but form such unstable compounds that the fixation is easily removed by washing in water and must be preserved by placing the specimens in alcohol. It is evident that any solvent action by the reagent—*e.g.*, the action of alcohol on fat and that of acetic acid on protoplasm—lessens their practical value. The characteristics of different pathologic conditions are better brought out in some fixatives than in others. Thus, fatty degenerations are well preserved by an osmic acid, bichromate, or formalin solution; œdematous and parenchymatous changes, by corrosive sublimate; fibrin, hemorrhagic

conditions, and bacterial invasions, by absolute alcohol. Moreover, different tissues require different treatment: the fixation of a lymph-node is quite a different matter from that of a retina. Then the purpose for which the examination is made will largely influence the choice. If it be simply a question of general diagnosis, Orth's fluid and alcohol will answer every purpose; by the use of alcohol we can preserve the specific staining properties of micro-organisms and hæmoglobin and various important chemic reactions, and by the use of Orth's fluid colloid and mucoid material retain their transparency, fat is preserved, etc.

If we undertake the investigation of pathologic processes and the comparison of abnormal with normal cellular anatomy, then special fixatives must be used. Full descriptions of such methods will be found in the books of reference mentioned at the beginning of this chapter.

OPTICAL DIFFERENTIATION.—Some agents in producing insolubility effect another change which is equally valuable and which is known as optical differentiation. The various cell structures respond differently to the fixative. Their indices of refraction are altered; some are raised, some lowered, and marked contrasts in refractive properties are developed throughout the cell. In this way structures become visible that were before unseen. Bichromate of potassium stiffens very equably, with neither shrinkage nor expansion, but has no power of optical differentiation; while osmic acid possesses this in a high degree. Since observation with the microscope is directly dependent upon differences in refraction, it is evident that this is a most valuable property of a fixative.

PENETRATION.—The ability to reach all points of the tissue at the same time is another important characteristic of a fixing agent and one clearly connected with securing optical differentiation. Osmic acid has but little penetration. If pieces placed in its solutions are too thick or remain therein too long, the superficial layers become overexposed, the indices of refraction are all equally raised, and differentiation disappears. This is true not only of cells in mass, but also of intracellular structures. Prompt and uniform action, the sharp fixation of tissues at the precise moment, insures good optical differentiation; on the other hand, slow, unequal action results in loss of definition.

Formulas of some of the many solutions useful for preparing tissues for microscopic study will be found upon the next page.

MÜLLER'S FLUID.

Bichromate of potassium 2.5 grammes.
Sodium sulphate..... 1. gramme.
Water 100. c.c.

Formerly the most used of all such solutions. Now largely replaced by, or used with, formalin.

FLEMMING'S SOLUTION.

Chromic acid, 1 per cent..... 45 c.c.
Osmic acid, 2 per cent..... 12 c.c.
Glacial acetic acid..... 3 c.c.

Prepare just before using. Small pieces of tissue are hardened in from several hours to two days. Nuclear figures are especially brought out. Saffranin is a good stain afterwards.

ALTMANN'S SOLUTION.

Osmic acid, 2 per cent.,
Potassium bichromate, 5 per cent.

Mix equal parts as needed. Wash thoroughly and place in alcohol.

ERLICK'S SOLUTION.

Potassium bichromate... 2.5 grammes.
Copper sulphate... 0.5 to 1. gramme.
Water 100. c.c.

An extremely good and cheap solution for hardening voluminous objects. It is used as a fixative for Freud's gold stain for nerve-fibres.

CARNOY'S FLUID.

Glacial acetic acid..... 1 part.
Absolute alcohol..... 6 parts.
Chloroform..... 3 parts.

Leave pieces in from fifteen to thirty minutes; transfer to absolute alcohol; avoid aqueous liquids.

ORTH'S FLUID.

Potassium bichromate..... 2.5 parts.
Sodium sulphate..... 1. part.
Water 100. parts.
Formalin; add before using 10. c.c.

After hardening the tissues are to be thoroughly washed in running water.

ZENKER'S FLUID.

Corrosive sublimate... 5. grammes.
Potassium bichromate.. 2.5 grammes.
Sodium sulphate..... 1. gramme.
Water 100. c.c.

Dissolve by heat and add before using 5 c.c. of acetic acid. Tissues remain here for twenty-four hours and are next washed in running water for a similar period of time, and then transferred to 35-70-95 per cent. alcohol.

HERMANN'S SOLUTION.

Platinic chlorid, 1 per cent... 15 parts.
Glacial acetic acid..... 1 part.
Osmic acid, 2 per cent..... 2-4 parts.

One of the best hardening and fixing solutions known.

LINDSAY JOHNSON'S MIXTURE.

Potassium bichromate, 2.5 per
cent. 70 parts.
Osmic acid, 2 per cent..... 10 parts.
Platinic chlorid, 1 per cent.... 15 parts.
Acetic or formic acid 5 parts.

Add the acetic or formic acid just before using. A fine fixative for delicate objects, such as a retina. Leave objects in for two hours. Wash in running water. Harden in alcohol.

GILSON'S SOLUTION.

Absolute alcohol..... 1 part.
Glacial acetic acid..... 1 part.
Chloroform..... 1 part.
Corrosive sublimate to saturation.

For Golgi's slow method the tissues are hardened in two per cent. bichromate solution. For his quick method, use osmic acid, 1 per cent., 1 part, and bichromate of potassium, 3.5 per cent., 4 parts. For Nissl, employ absolute alcohol. *Do not use* bichromate of potassium. For Marchi use Müller's fluid. For Weigert's fibrin method harden in alcohol, corrosive sublimate, formalin, Orth, or Müller. For Weigert's nerve stain use five per cent. formalin. For Mallory's stain, ten per cent. formalin in a saturated aqueous solution of picric acid.

DECALCIFICATION.—In my hands the following, of the many methods recommended, has given good results: Nitric acid, five per cent. by weight, to which may be directly added an equal part of saturated potassium-alum solution, or five parts of ten per cent. formalin to one of five per cent. nitric acid.

Thomas's method is to harden in alcohol; then decalcify in alcohol, five parts, and nitric acid, one part (add carefully), changing the fluid frequently. When decalcified—three to four weeks for small objects—transfer to different alcohol until it is no longer acid. Delicate bones, such as those of the ear, can best be mounted in celloidin and then decalcified.

PREPARATION OF TISSUES FOR MICROSCOPIC STUDY.—In the celloidin method use different strengths of ethyl alcohol until absolute alcohol is reached, then transfer in turn to equal parts absolute alcohol and ether; thin celloidin; and thick celloidin. The paraffin method is given on page 320. A rapid method of preparing paraffin sections is that described by Henke and Heller.¹ The tissues are placed in twenty-five volumes of pure acetone, which substance boils at 56°C., for thirty minutes to one and one-half hours, depending on their size. They are then transferred to melted paraffin at a temperature of 52° C. to 56° C. for an hour or so, and then embedded. If time permits, the tissues are to be first hardened in formalin.

PRESERVATION OF MACROSCOPIC SPECIMENS.—If for any reason it be desirable to keep specimens for a short time (up to seven to ten days), as for class demonstrations, they should be kept moist by being wrapped in cloths wet with five per cent. formalin solution, covered with wax paper, and placed on ice in a covered slop-pail or ice-cream freezer.

GENERAL CONSIDERATIONS.—*Washing*.—If alcohol be used as the preserving solution, blood and other impurities may be removed by a thorough washing with water. In other cases the parts should be carefully sponged with the preservative to be employed.

Cavities should be distended with tow or absorbent cotton. The lungs should be placed in a jar and the jar filled by pouring the fluid through the trachea. Mucous and serous membranes should be protected from the distortion caused by shrinkage by being pinned out on cork or on wood which will impart no color on soaking. A more elegant method is to sew the membranes over the edges of frames

¹ *Zentralbl. f. allg. Path.*, vol. xvi, p. 3.

made of glass rods. The secreting surfaces of these membranes should always be uppermost.

Compression of any part of the specimen should be avoided by the use of a soft cushion of absorbent cotton placed in the bottom of the jar. Jars made especially for museum preparations are preferable, but if necessary they may be replaced by such as are used by grocers and druggists for candy, etc.

Preserving Fluids.—Alcohol is a convenient and efficient agent. It preserves form relationships very well, as in tumors, typhoid ulcers, invagination of the intestine, etc.; but it destroys all contrasts in a pathologic organ, such as a diseased lung or kidney, and makes recognition of the lesion very difficult. It bleaches the tissues and causes much shrinkage, so that natural appearances are not retained. The specimen is to be washed in water, then immersed in 60 per cent. alcohol (which is changed every day until it remains clear), and finally kept in 80 per cent. alcohol. To preserve the natural appearance of tissues, formalin followed by alcohol is used, and the specimen is finally placed in glycerin solution containing some salt of acetic acid, usually potassium. Formalin converts the hæmoglobin into methæmoglobin and a brown color is developed; alcohol changes the methæmoglobin into a red pigment, so that the flesh-color is restored. The tissues are so thoroughly hardened that they may be kept in the glycerin solution without being thereby softened. The principles involved are simple, but their application requires experience and ingenuity. All tissues do not respond equally to the treatment, and to retain some color peculiar to a certain pathologic condition—such as prevails in icterus, for example—requires careful management. There are various formulæ and different methods of applying them, but the two following are perhaps as simple and useful as any. It must always be remembered that if the tissues are placed in too strong formalin, or remain too long even in a weak solution, the alcohol will fail to transform the brown or gray pigment back into red.

1. Place the fresh organ or a segment as large as the hand for from twenty-four to forty-eight hours in one of the following solutions.

Kaiserling fluid:

Formalin	200 c.c.
Water	1000 c.c.
Potassium nitrate.....	15 grammes.
Potassium acetate.....	30 grammes.

Melnikow-Raswedenkow :

Formalin	10. parts.
Sodium acetate.....	3. parts.
Potassium chlorate.....	0.5 part.
Distilled water.....	100. parts.

It is well to wrap the specimen in wadding and pour the fluid over it. The wadding protects the organ from distortion due to compression. If the organs are very thick, incise them or inject the blood-vessels, ureters, etc., with the fluid. This should be done very gently, in order not to wash out the blood. As formalin is injurious to the respiratory tract and the skin, it is well when using it to wear rubber gloves and to keep the jars covered.

2. After two days place the specimen in 60 per cent. alcohol, first removing the wadding. Two or three days later change to 80 per cent. alcohol, then to 90 or 93 per cent.

3. The specimen is finally placed in the preserving fluid :

Glycerin	400 grammes.
Potassium acetate.....	200 grammes.
Water	2000 grammes.

The solutions may be used several times, but a fresh preserving fluid is better, and it is even advisable to change it occasionally.

Pick adds at once to the formalin solution 5 per cent. of Carlsbad salts, which prevents the formation of acid hæmatin, while Marpmann uses fluorsodium both in the formalin solution and in the glycerin. The use of ten parts of an 0.8 per cent. salt solution with one part of the 40 volume strength formalin is also recommended.

Another method of preserving the natural color of specimens is as follows:¹ One-half of the capacity of a metal box is filled with a concentrated solution of ammonium sulphate, an excess of the crystals being left at the bottom of the tank. Above the crystals is arranged a grating upon which the specimens to be acted upon are placed. At the bottom of the box is a small opening through which carbon dioxid or ordinary illuminating gas is constantly passed, thus permitting it to bubble up through the fluid in the box. Another tube at the top of the box is fitted with a burner so as to burn off the escaping illuminating gas. The specimens which remain in the solution under the action of the carbonic-acid gas and ammonium sulphate for from

¹ CLAUDIUS, *Virchow's Arch.*, 1903, vol. clxxiv, no. 1, p. 103.

forty-eight to seventy-two hours retain their color for a long while, if preserved in this solution.

After the tissues have been prepared for preservation, it is often desirable to embed them in gelatin. For this purpose Watters¹ prepares the gelatin solution by dissolving 100 grammes each of gelatin and potassium acetate in 200 cubic centimetres of glycerin and 1000 cubic centimetres of water. After standing for twenty-four hours the mixture is rendered acid by acetic acid and clarified by heating with the white of an egg. It is then filtered and formalin or thymol added. Very attractive mounts may be made in suitable cases by using Petri dishes for the containers.

Littlejohn² recommends that fresh specimens or those preserved by any well-known method be kept in glass jars made air-tight by sealing their covers with gold size and putty. The one objection to this method is the vapor which collects in the jars. To avoid this the preparations are soaked for several weeks in glycerin and water and afterwards placed on wool to which some formalin glycerin is added. Perfectly washed stomachs from cases of poisoning, such as carbolic acid and the corrosive acids, require no preservative whatever, and when thus prepared retain their natural coloring for years.

The August 13, 1904, issue of the *Journal of the American Medical Association* contains two excellent articles on the permanent preservation of specimens, one being by Coplin, on "The Permanent Preservation of Anatomic, Embryologic, Pathologic, and Bacteriologic Specimens," and the other by Herring, on "Clay Modelling in the Study of Anatomy."

INJECTED SPECIMENS.—Most beautiful and permanent specimens may be made by injecting various colored materials, such preparations giving especial opportunity for the study of the arterial and venous circulation. Thus, in the case of the liver, if the cystic duct, portal vein, hepatic artery, and hepatic veins be injected with four different colored solutions, the distribution of the various vessels may be shown to perfection. The microscopic study of these cases may be made later on. The writer has a fine specimen in his cabinet of the *Trichina spiralis* in the tongue of a cat in which the arterial circulation has been injected with carmin. Entwining capillaries surrounding the capsule are well brought out. If a warm injecting fluid be desired,

¹ *Medical Notes and Queries*, June, 1905, p. 81.

² *Journal of Pathology and Bacteriology*, September, 1902, p. 369.

that of Robin may be recommended. It consists of gelatin one part and seven to ten parts of water, heated on a water-bath, to which two per cent. of chloral hydrate is added to prevent the formation of mould. Any dye may be used to color this solution. For a red color take thirty-one centigrammes of carmin, moistened with water, and then dissolved in five or six drops of ammonia; fifteen grammes of glycerin are then added. This is then mixed with fifteen grammes of glycerin to which eight to ten drops of concentrated acetic acid have been added and the whole diluted with

Glycerin	15.0	grammes.
Alcohol	7.5	grammes.
Distilled water	22.5	grammes.

Fischer injects milk and hardens in

Formalin	75	parts.
Concentrated acetic acid	15	parts.
Water	1000	parts.

Frozen sections are prepared and stained with Sudan III or Scharlach R.

1. Sulphate of iron.....	0.62	part.
Distilled water.....	30.00	parts.
2. Red potassium ferrocyanid.....	2.00	parts.
Distilled water.....	30.00	parts.

Slowly mix and shake, then when of an opalescent blue color, add

3. Distilled water.....	60.00	parts.
Glycerin.....	30.00	parts.
Alcohol.....	30.00	parts.

Beale's Prussian blue may be used, and is prepared as follows:

Glycerin.....	32.0	parts.
Alcohol (50 per cent.).....	32.0	parts.
Potassium ferrocyanid.....	0.75	part.
Tinct. of perchlorid of iron.....	4.0	parts.
Distilled water.....	128.0	parts.

A practical article on the fixation of tissues by injection into the arteries is that by Myers, in the *Johns Hopkins Hospital Bulletin*, February, 1905, p. 66.

THE JOHNS HOPKINS MODIFICATION OF SCHULTZE'S CLEARING METHOD.¹—In making the injection into an embryo or part under

¹ EBEN C. HILL, *Johns Hopkins Hospital Bulletin*, April, 1906, p. 111.

investigation, commercial India ink is diluted to one-third of its strength, the injections of small embryos being carried on in warm water with the membranes still intact. Thus, in a study of the lymphatics of the small intestine the injecting fluid is inserted in the thoracic duct and into the mesentery; for the respiratory tract, the trachea is employed; for the bile capillaries of the liver, the stomach; for the uriniferous tubules of the kidney and the Wolffian body, the urinary bladder is employed; and for the venous or arterial circulation of the placenta, the umbilical arteries or vein. After the injections have been completed all unnecessary tissues surrounding the parts under investigation are removed and the specimens are placed in an abundant supply of 95 per cent. alcohol until they have become completely shrivelled. This will take from three to seven days, depending upon their size. After the specimens have become sufficiently shrivelled they are immersed in a one per cent. potassium-hydroxid solution until they appear transparent, which will be in from four to forty-eight hours. From this medium they are transferred to twenty per cent. glycerin, in which clearing continues and a certain amount of hardening occurs, rendering the tissues firm enough to permit of dissection. Should the specimens be as transparent as is desired they may then be transferred from time to time to higher percentages of glycerin, till at last they are permanently stored in pure glycerin. Should they not be clear enough, they are placed in equal parts of a one per cent. potassium-hydroxid solution and fifty per cent. ammonium hydroxid for from five to seventy-two hours. They are then placed in twenty per cent. glycerin for forty-eight hours or more, the glycerin being increased in strength as before. By following this method, the systems of bones, cartilages, arteries, veins, lymphatics, and various ducts can be demonstrated with a transparent embryo or with large sections of adult tissue without any distortion of the structures. Bardeen has devised a method by which specimens may be mounted upon glass slides and placed in any desired position in jars of glycerin. In this method the specimens are removed from pure glycerin, wiped, and quickly washed. They are then placed in a little thick gelatin solution and are laid upon a warm glass slide in the desired position. As soon as the gelatin is hardened, the specimens are returned to the pure glycerin without any danger of their coming off.

CHAPTER XXIII

BACTERIOLOGIC INVESTIGATIONS

ALTHOUGH it is well known that a bacteriologic investigation is often a most important factor in the ultimate value of a post-mortem examination, such an investigation is frequently neglected because of the lack of facilities or of knowledge of the technic.¹ This ought not so to be. In the first place, the cost of equipment, as in post-mortem sets, is very largely determined by the *conveniences*, rather than by the *necessities*. The outfit mentioned on page 41 can be kept always in readiness, while the culture-tubes may be obtained quickly and at reasonable rates from the larger pharmaceutical manufacturing companies and their agencies. In the second place, the technic is not so complicated as to require more skill, except in the finer manipulations and diagnoses, than should be expected from an educated physician. As time goes on, the general practitioner who is not within easy reach of a pathologic laboratory or of a board of health will be more and more expected to be sufficiently equipped with apparatus and adequately trained to make cultures and even inoculations for diagnostic purposes. Of course, it is impossible under such circumstances to do the work of well-endowed laboratories and skilled bacteriologists, but the material may at least be studied until the time arrives for placing it in the hands of those devoting their especial attention to the technic of bacteriologic investigations.

COLLECTION OF MATERIAL FOR MICROSCOPIC OBSERVATIONS AND FOR CULTURE PURPOSES.—The important factor in the technic of a bacteriologic examination is that all instruments shall be scrupulously clean and absolutely sterile, and all sources of contamination carefully guarded against in every possible manner. The fluid contents and accumulations in abscess and serous cavities, especially meningeal, pericardial, peritoneal, and pleural, the blood, endocardial vegetations, ulcerated areas, and the cut surfaces of solid organs may present foci of bacterial invasion which are at once examined by "smear prepara-

¹ SIMMONDS (*Virchow's Arch.*, vol. clxxv, no. 3, p. 418) believes, after making routine bacteriologic examinations in 1200 cases, that this procedure may sometimes give the only definite knowledge concerning the cause of death.

tions," and later on by cultures and by animal inoculations, should such be deemed necessary. It is important to obtain material as fresh as possible and in sufficient amount to permit of a thorough examination. Canon¹ states that there is danger of the migration of organisms within the cadaver during the first thirty-six hours, even if it be properly cared for. Should an early examination be wanted, one of the veins of an arm may be exposed shortly after death and the blood thus obtained. The method so frequently employed of taking up a small quantity of the blood with the platinum loop often gives negative results, especially for culture purposes. Bulbs blown in ordinary glass tubing furnish one of the most satisfactory means for the securing of fluids during an autopsy. They may be purchased in supply houses or prepared as follows: A piece of thick tubing is chosen, measuring about nine inches in length. The lower portion of the tube is drawn to a point and sealed. About three inches from this end, the glass is heated to a white heat, the tube being turned all the time and not allowed to bend. The open end is now blown into until a bulb about one inch in diameter is produced in the heated portion of the glass. The upper part is now closed by heat, or the opening preferably is filled with a small plug of cotton, and then the whole is sterilized by dry heat. When the bulb is wanted for use, the capillary end is broken off, and, after aspiration of the fluid, immediately sealed by drawing it to a point again. The end previously filled with cotton is also melted until it closes. In these hermetically sealed bulbs the material may be kept securely until the autopsy is completed, and then be taken to a suitable place for such further examination as may be necessary. An ordinary 5 to 10 c.c. pipette sterilized and securely wrapped in cotton may also be used for this purpose. The end of the pipette is placed in the fluid and suction is made through a clean piece of rubber tubing, or the pipette is fitted with a suction cap or bulb. Both ends are then sealed with the flame. By either of these methods sufficient material may be obtained for making differential staining tests and also for the inoculation of cultures or of animals. Solid material may be removed from the interior of an organ by means of a small spear made for this purpose, which has an eye in which some tissue is retained as the spear is withdrawn.

SMEAR PREPARATIONS.—Smears which are to be examined during

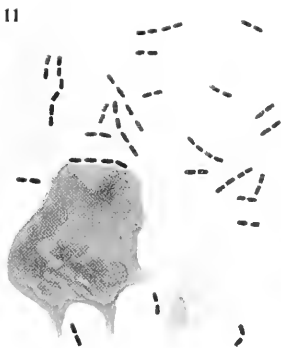
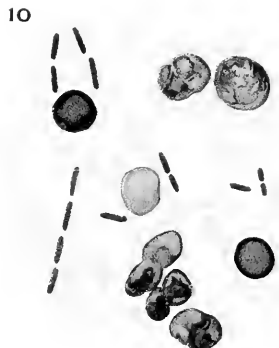
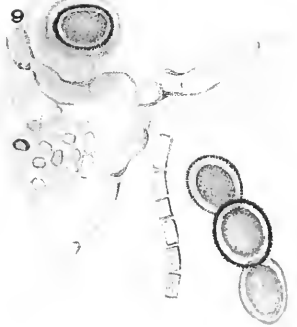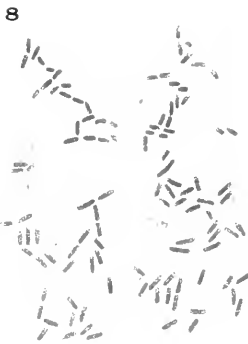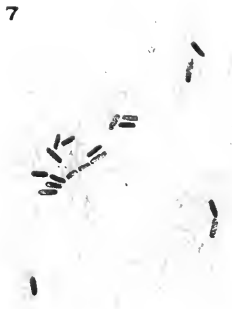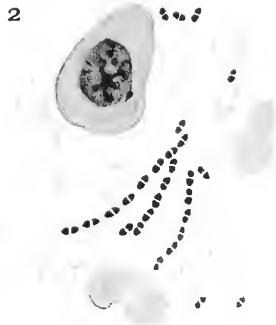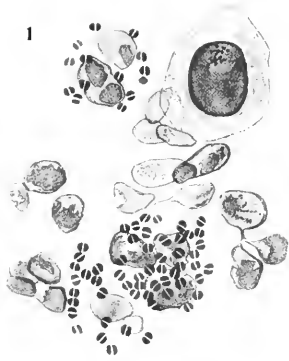¹ *Deutsche Zeitschrift f. Chirurgie*, 1901, vol. lxi, nos. 1 and 2, p. 93.

the autopsy may be easily and quickly made, as there is not the same risk of contamination that there is in obtaining fluids and solids to be used for inoculation. They are prepared in the following manner: A number of carefully cleaned and dried cover-slips and slides are placed in readiness.¹ A platinum loop for fluids, or the spear-headed spatula for solids, is then sterilized by heating to a red glow in an alcohol flame or in the upper (hottest) part of a Bunsen burner. If the liquid to be examined is of considerable consistency, like pus, blood, and exudates, a drop of it is placed by the aid of the sterilized loop upon a clean cover-slip. The cover-slip is then dropped upon a slide one-third of its length from one end, and, after the drop has spread, the cover-slip is drawn gently by means of forceps across the remaining two-thirds of the slide. The slide is much easier to manipulate than two cover-slips prepared by drawing one over the other, is not so easily broken, and gives a larger field for future study. Fluids may also be spread zigzag upon the slide or cover-slip with the platinum loop or with a small pipette, the latter being preferable whenever the fluid is very thin, making large amounts necessary. Should the material not be sufficiently fluid to make a satisfactory smear preparation, a little distilled water or physiologic salt solution may be put on the glass before performing the above manipulations. If preferred, a solid organ may be incised with a scalpel sterilized by heat, and the cover-slip or slide applied directly to the freshly cut surface. The material thus collected may then be smeared over the glass with the platinum loop. The "smear" being dried with *very little* heat,—or, better, with none,—now requires only "fixing" on the glass. This is done by the routine method of passing it three times through a flame, with the smeared surface upward to avoid burning the material. If a cover-glass is used, the passage through the flame is made more quickly than when the thicker glass slide is employed. In "fixing," very great care must be used to avoid the application of too high a temperature,—shown by a brownish coloration,—which would seriously distort the bacteria, especially if the film had not been thoroughly dried previously. By the heat applied in this way, the albuminous organic matter is dried or coagulated, and the bacteria and cellular elements are thus caused to

¹ It is well to use new cover-slips which have been cleansed in strong nitric acid, washed in distilled water, and kept in alcohol to which a few drops of ammonia have been added. When wanted for use, they should be wiped dry between the fingers with Chinese tissue paper or with a clean cloth.

PLATE V.—BACTERIOLOGIC CHART.

No. 1. *Gonococcus*: smear preparation from urethral pus; stain, methylene blue. No. 2. *Pneumococcus*: smear preparation from sputum; Welch's acetic acid stain. No. 3. *Streptococcus pyogenes*: smear preparation from pus; stain, methylene blue. No. 4. *Micobacterium tuberculosis*: smear preparation from sputum; stain, Ziehl's method. No. 5. *Vibrio cholerae*: stain, carbol fuchsin. No. 6. *Corynebacterium diphtheriae*: stain, Löffler's method; lower portion of figure shows the polar staining of Neisser's granules. No. 7. *Bacterium typhosum*, showing flagella; stain, van Ermenghem's method. No. 8. *Bacterium dysenteriae*: stain, methylene blue. No. 9. *Achorion Schönleinii* (favus fungus), with conidia and mycelia: stain, Bismarck brown. No. 10. *Bacillus anthracis*: smear preparation from spleen of a mouse; stain, gentian violet; to bring out the spores stain with Ziehl's solution. No. 11. *Bacillus aërogenes capsulatus*: smear preparation from spleen; stain, gentian violet. No. 12. Yeast cells with buds and ascospores, starch cell in lower right-hand corner; stain, weak Lugol's (Gram's) solution.



adhere so firmly to the glass surface that they will not be washed off by future manipulations. Such preparations may be kept for a considerable length of time before being stained, and can be safely and easily protected by gumming the clean surface of a piece of card-board cut to the size of the ordinary glass slide, on which also may be written all necessary data. The cards may then be packed in a slide-box or in an ordinary pill-box, care being exercised that the films do not come in contact with anything that will be liable to rub or scratch them. Another method of keeping slides apart is to lay short pieces of match-sticks across the ends of one of them placed face up and then to put another slide face down on the match-sticks and bind the slides firmly together with a gum elastic band placed around them lengthwise.

SELECTION OF CULTURE-MEDIA.—A diagnosis made from the study of smear preparations must often be corroborated by cultures, though the previous study of the smear has frequently offered valuable suggestions as to the particular kind of culture-media to employ in the case under observation. For instance, if a *Diplococcus* be found as the prevailing organism, a special medium will be necessary, as the three most common varieties of the *Diplococcus*—viz., the *Pneumococcus*, the *Gonococcus*, and the *Diplococcus intracellularis*—grow poorly and in many cases not at all upon ordinary media. Or the microbe may be one that can be most easily isolated by immediate inoculation into an animal, as in the case of the tubercle bacterium and the *Pneumococcus*. Again, existing conditions of the organs and tissues may point to infection by an anaërobic organism, as the gas bacterium, and in such cases a medium and a method suitable for anaërobic growth—namely, the exclusion of oxygen—must be employed. Wallis¹ drops a little of the melted media upon a cover-glass, places a hair suspected of containing the parasite upon it, puts the cover in a moist chamber, and incubates at the room temperature. The slide is examined in the usual manner.

The following list, prepared chiefly according to the nomenclature adopted in the third German edition of Lehmann and Neumann's *Bakteriologische Diagnostik*, gives the best media for the isolation of the pathogenic micro-organisms most commonly found *post mortem*, those having spores being called bacilli, while those which have none are designated bacteria. (Plate V.)

¹ *Jr. Amer. Med. Assoc.*, August 20, 1904, p. 531.

- Bacillus anthracis*. All ordinary media, especially agar. White or house mouse. The *Bacillus subtilis* is motile, while this organism is not, though very similar morphologically. (Plate V, no. 10.)
- Bacillus œdematis maligni*. Anaërobic culture methods. Ordinary media with the addition of glucose.
- Bacillus tetani*. Anaërobic culture methods. Grows in long threads on ordinary media with the addition of glucose. Spores; motile; flagellated.
- Bacterium œrogenes capsulatum*. Anaërobic culture methods. Ordinary media with addition of glucose. (Plate V, no. 11.)
- Bacterium coli commune*. Glucose agar-agar shows gas formation, thus distinguishing it from the typhoid germ. It also contains fewer flagella than the latter. Agglutinates. Milk is coagulated. Marked indol production in peptone solution.
- Bacterium dysenteriae* (Shiga). Plain agar-agar. A flagellated organism not stained by Gram's method. Agglutinates. Milk not coagulated, nor are sugars fermented. Does not form indol in peptone solution. (Plate V, no. 8.)
- Bacterium enteritidis*. The bacterium of hog cholera may produce gastric disturbances in man after eating contaminated meat. It is probably a modified form of the *Bacterium coli*.
- Bacterium influenzae*. Agar-agar smeared with human blood or glycerin agar.
- Bacterium paratyphosum*. Grows on ordinary media. This organism is classified between the typhoid and the colon bacterium. Agglutinates, but may have to use several cultures before securing the proper one.
- Bacterium pestis*. All ordinary media.
- Bacterium pneumoniae*. A facultative organism growing on all ordinary media.
- Bacterium pyocyaneum*. Plain agar-agar.
- Bacterium rhinoscleromatis*. Probably the same as the *B. pneumoniae*.
- Bacterium septicæmiæ hæmorrhagicum*. The bacillus of chicken cholera. Should be studied with wine, milk, and glucose media.
- Bacterium typhi murium*. The bacillus of mouse septicæmia is similar to the bacterium of hog cholera and the paratyphoid.
- Bacterium typhosum* (Eberth's bacillus). Hiss's gelatin-agar medium. Can grow on all media. Not stained by Gram's method. Flagellated organism. Cultures best obtained from blood, spleen, and urine. Agglutinates. Does not coagulate milk or form indol in peptone solution. In dextrose, lactose, and saccharose bouillon very little acid is produced and no gas. (Plate V, no. 7.)
- Bacterium vulgare* or *proteum*. Non-motile; stains with Gram. It is a facultative, sugar-decomposing, and agglutinative organism.
- Corynebacterium diphtheriae*. Blood-serum bouillon. A guinea-pig may be inoculated to see if the organism is virulent, thus distinguishing it from the so-called pseudodiphtheria bacillus. Non-motile. The *Bacillus xerosis* is, in all probability, this organism. (Plate V, no. 6.)
- Corynebacterium mallei*. Optional anaërobic. Guinea-pig is to be inoculated in the testicle. Not stained by Gram's method.
- Corynebacterium xerosis*. See *Corynebacterium diphtheriae*.
- Diplococcus intracellularis meningitidis*. Careful search will show this organism in the blood in twenty-five per cent. of all cases. Rarely found by culture *post mortem*. Ascitic fluid.
- Gonococcus* or *Micrococcus gonorrhœæ*. Ascites-glycerin agar and hydrocele agar give fairly good results. Gonorrhœal ophthalmia may be produced in rabbits by inoculating the mucosa of the eye. Does not stain by Gram. (Plate V, no. 1.)

- Micrococcus* or *Streptococcus intracellularis*. Glycerin agar or agar smeared with blood gives the best results. Löffler's blood-serum and potato may be used. The coccus is found in the pus of the brain, cord, and ear, the nasal mucus, the sputum, and the urine of those affected with the disease. A large quantity of the exudate should be used, for many of the bacteria present are dead.
- Micrococcus melitensis*. Glycerin agar or potato. Grows as a bacterium. Material to be taken from the cervical or inguinal glands and from the lungs. Agglutinates.
- Micrococcus* or *Staphylococcus pyogenes aureus*. Grows luxuriantly upon all media in general use. The *M. citreus* and the *M. albus* are but varieties of this genus. Suppuration is usually circumscribed.
- Mycobacterium lepræ*. It is innocuous for animals. It is grown upon glycerin agar-agar with great difficulty. Acid resisting.
- Mycobacterium tuberculosis*. Glycerin agar-agar is the best medium. Confirm diagnosis by subcutaneous inoculation of guinea-pig. Probably agglutinates under proper conditions. O. von Schrön¹ has recently announced, through his assistant Galbo (*Riforma medica*, 1904, vol. xx, no. 29, p. 800), the discovery of the phthisiogenic micro-organism in the caseous masses of tuberculous lungs. Von Schrön considers tuberculosis and phthisis as two distinct diseases, the former preceding the latter in the formation of cavities; the walls being formed by three strata, the results of evolution, involution, and degeneration of the parasite, the specific crystals being prisms, and not rhombs, as in the case of the tubercle bacillus. (Plate V, no. 4.)
- Pneumococcus* or *Streptococcus lanceolatus*. Ascites agar and ascites-glycerin agar are the best media. The best method is to inoculate a mouse or rabbit subcutaneously with the rusty sputum or with pus. A mouse dies in from twelve to twenty-four hours, and its blood contains large numbers of the *Diplococcus pneumoniae*, showing the capsule most strikingly; a rabbit dies in from two to five days. The agglutination of *Pneumococci* by a long, complicated procedure may be obtained with the serum of immunized animals and pneumonic patients. (Plate V, no. 2.)
- Sarcina*. Best cultivated in bouillon or hay decoction, displaying fine shades of various colors.
- Spirochata Obermeieri*. No culture method known. Monkeys show disease after inoculation.
- Spirochata pallida*. See *Treponema pallidum*.
- Streptococcus pyogenes*. This organism is most easily recognized by smear preparations and grows well upon all media in common use. It produces erysipelas as well as pus. Suppuration is usually wide-spread; but may be circumscribed in an immune animal. (Plate V, no. 3.)
- Streptothrix actinomyces*. Grows well upon agar-agar and blood serum. Does not stain with Gram's solution.
- Treponema pallidum*.² After the discovery of the *Cytorrhycles luis* by Siegel, Schaudinn and Hoffmann announced the presence in syphilitic lesions of the *Spirochata pallida* and *S. refringens*. The *S. pallida*, or, as better named,

¹ *Medico-legal Jr.*, March-June, 1905.

² The meaning of which is "a pale, turning thread." A recent and easily accessible account (with literature) of this organism is by PFENDER, *Amcr. Med.*, March 10, 1906, p. 350. For an excellent illustration see *Deut. med. Wchnschr.*, 1905, vol. xxxi, no. 42.

the *Treponema pallidum*, is a delicate, actively motile, faintly refractile, long, thread-like, spiral, flagellated protozoön, tapering at both extremities and terminating in pointed ends. The ultraviolet microscope has demonstrated a nucleus in a number of specimens, and specimens presenting six to eight spirals are probably two or more joined individuals. The thickness rarely reaches a quarter of a micron.

Vibrio cholerae. Glycerin agar. All ordinary media, especially gelatin at 22° C. Usually a single flagellum. Agglutinates. (Plate V, no. 5.)

The following diseases are due to specific organisms or protozoa, but the etiologic factor as such, though described, has not yet been definitely accepted as the cause of the affection, symbiosis possibly playing an important part in the etiology of some of them: Acrodynia, or epidemic erythema; poliomyelitis; beriberi (possibly an arsenical neuritis); cancer; chancroid; chicken-pox; chorea; cow-pox; foot-and-mouth disease; measles (bacillus of Canon and of Czajkowski); miliary fever; mumps; pellagra; rabies; rheumatism; rose rash; scarlet fever; smallpox; typhus; whooping-cough (*Bacillus pertussis*, *B. minutissimus sputi*, and *B. tussis convulsiva*); yellow fever (*Bacillus X* and *B. icteroides*).

INOCULATING CULTURE-MEDIA.—Test-tubes containing any of the solid or liquid media may be inoculated at the place where the autopsy is performed when it is not so far from the laboratory as to endanger the growth of the culture by exposure to extremes of temperature. Sufficient heat is secured, however, by placing the tubes after inoculation, *securely wrapped*, in an inside coat-pocket.

The first step in inoculation of the tube containing the medium is to “flame” the cotton plug in its mouth, for the purpose of killing any bacteria that may have fallen upon the cotton-wool. During inoculation the tube is held as nearly in the horizontal position as is consistent with safety to its contents, so as to diminish the risk of contamination of the medium by the falling into the tube of the bacteria from the air. Thus, should the tube contain a solid medium, such as blood-serum, it may even be inverted before inoculation. The platinum wire, held in the right hand, is now sterilized by heat and cooled, while the cotton plug is removed from the test-tube by a corkscrew motion and held, inner part outward, between the middle and index-fingers of the left hand in such a manner that it does not come in contact with any portion of the hand or other extraneous object. With the tip of the platinum wire a small portion of the substance to be inoculated is now placed on the surface of the medium; if this surface

is slanting, the fluid is rubbed gently over it, or drawn in a line across it, thus making a "smear" and "stroke" culture, while the needle is thrust deep down into the medium if a "stab" culture is to be made. The öse is then withdrawn, the cotton plug reinserted, the needle sterilized, and the tube labelled and put in a warm spot until it can be placed in the incubator.

If the culture is to be made from the surface of a solid organ, the method is the same, except that the organ is first seared with a hot knife and next incised with a sharp, sterile knife. Should the same knife be used for both purposes, it is wise, as a precautionary measure, to sterilize the instrument again before plunging it deep into the tissue. In some instances, in which many of the bacteria are dead, much larger amounts of the infectious material must be used for inoculation, and then the entire contents of a bulb or pipette may be introduced into a flask of bouillon or other medium.

CULTIVATION OF THE INOCULATED TUBES.—The pathogenic bacteria grow best at about the body-temperature, and so all cultures, except gelatin plates, are placed in an incubator during growth. If anaërobic methods are indicated, the tubes must be prepared for the exclusion of oxygen. Wright has devised a simple and satisfactory method, which is a modification of Buchner's two-tube method and does not require any special apparatus. Its principle is based upon the absorption of the oxygen in the air by pyrogallic acid and caustic soda, leaving an atmosphere of nitrogen. A single tube is inoculated in the usual way. The cotton plugs are then cut off even with the mouth of the tube and pushed in to the distance of three or four centimetres. One cubic centimetre of a ten per cent. aqueous solution of pyrogallic acid is then dropped upon the cotton plug and followed by the same amount of a decinormal solution of caustic soda. The mouth of the tube is then quickly closed with a close-fitting rubber stopper and the culture-tube is placed in the incubator. Hirshberg¹ has slightly modified this method by mixing the pyrogallic acid and sodium nitrate directly with a second tube of melted agar and then pouring this over a deep stab culture of the inoculated agar tube. Hesse's method of turning sterile oil into a test-tube in which a deep stab culture has been inoculated is often convenient.

PREPARATION OF THE INOCULUM.—The materials used for inoculation are either the pathologic products—namely, the secretions and

¹ *Jr. Amer. Med. Assoc.*, May 21, 1904, p. 1355.

excretions and the solid tissues, which have been collected in sterile bulbs or pipettes from the different cavities of the body and from the organs—or cultures which have been obtained by the inoculation of these products upon culture-media. If the material is in a sterile bulb, break off the end of the tube with sterile forceps and expel the contents, by the application of heat to the bulb,—the warmth of the hand is usually sufficient,—into a sterile capsule (a small Petri dish with a tightly-fitting ground-glass cover). The injecting syringe is then filled from the capsule. If the fluid is too thick, it may be diluted with a sterile salt solution. Cultures of bacteria may be prepared in the same manner, and solid tissues may be emulsified in a salt solution.

INOCULATION OF ANIMALS.—The animal to be used for inoculation should be carefully selected from those commonly employed for experimentation with reference to its own health and to the species required, as indicated by the microscopic examination of the smear preparation. The animals most used for this purpose are the rabbit, guinea-pig, white mouse, rat, pigeon, and domestic fowl. These differ in their susceptibility to the different pathogenic bacteria infesting man, and negative results are sometimes seen because animals are used which are unsuited to the disease under investigation. Thus, in cases of suspected syphilis the baboon, ape, or monkey must be employed, and in typhoid inoculations the animal must be specially medicated so as to render it susceptible to the bacterium causing the disease.

The animal should be weighed and the rectal temperature (Fig. 183) taken before inoculation, and both weight and temperature should be recorded at a certain time each day during the period of observation. The same rules apply as to asepsis in the inoculation and to avoidance of contamination of the inoculum as are required in a surgical operation. The instruments, similar to those used by surgeons, are sterilized by boiling, owing to the difficulty of removing chemic disinfectants which even in traces might inhibit the growth of bacteria and so vitiate the experiment. An ordinary hypodermic syringe may be employed, but one should be selected that can easily be cleansed and disinfected. Koch's inoculation syringe is much used; many, however, prefer Roux's or some modification of it. The glass and metal portions of the syringes may be sterilized by boiling, but the washers are injured by frequent boiling and should be disinfected by a five per cent. solution of carbolic acid, followed by *careful* washing in sterile water.

The site of inoculation varies with the different animals and also



FIG. 183.—Method of determining the rectal temperature of a guinea-pig.




FIG. 184.—Animal-holder employed in securing a mouse in position while being inoculated.

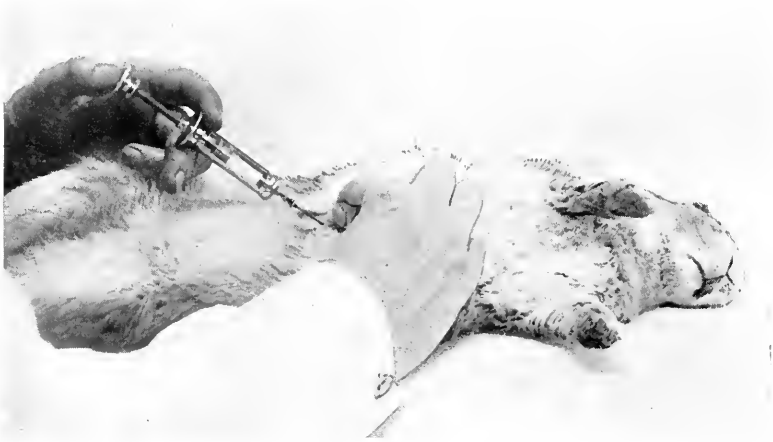

FIG. 185.—Method of performing peritoneal injection in a rabbit.




FIG. 186.—Ear method of inoculating a rabbit.



FIG. 187.—Post-mortem examination of guinea-pig, made in Ravel pan. Near the four corners, but not shown in the illustration, are hooks upon which the chains are fastened in order to hold the animal in position.

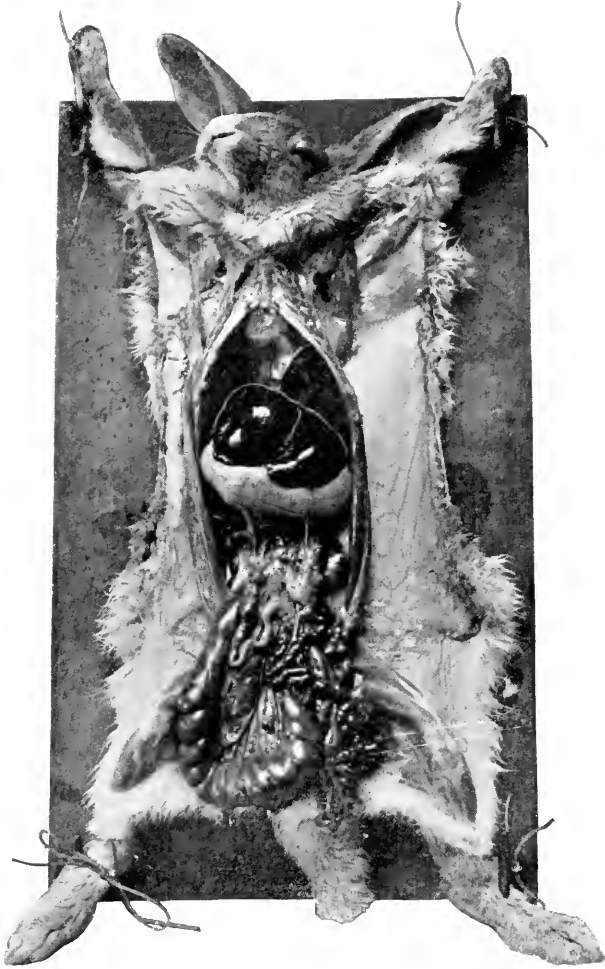

FIG. 188.—Post-mortem examination of a rabbit upon wooden post-mortem board.

with the different varieties of the pathogenic bacteria. The usual methods are the subcutaneous, the intraperitoneal, and the intravenous. In small animals like the mouse the last two methods are rarely used, although a very small dose, one or two minims, of fluid may be injected into the peritoneal cavity. Subcutaneous inoculation is commonly practised in the mouse. A fold of skin is pinched up between the thumb and forefinger of the left hand, the hypodermic needle attached to the barrel of its syringe, filled with the material to be introduced, is thrust into the ridge of skin until it enters the subcutaneous tissue, when the fluid is slowly injected; or a piece of skin is snipped with a pair of sharp-pointed scissors, a probe is pushed into the subcutaneous tissue, making a small pocket, in which a portion of the solid inoculum is deposited. (Fig. 184.) The wound may then be dressed with gauze and sealed with collodion.

The intraperitoneal inoculation is made as follows: The animal is held by an assistant or secured to a table. A broad area over the abdomen is shaved, care being taken not to injure the nipple, and the skin is thoroughly disinfected with a two per cent. lysol solution, which is washed off with alcohol. The entire thickness of the abdominal parietes is then pinched up into a triangular fold, the peritoneal surfaces are slipped one over the other to ascertain that no coil of intestine is included in the fold, and the hypodermic needle is passed through the fold near its base. The fold is then released, but the syringe is held steady. The parietes now flatten out, leaving the needle free in the peritoneal cavity. The fluid is then slowly injected. (Fig. 185.)

Intravenous inoculation is not usually practised in animals smaller than a rabbit. In this animal the posterior auricular vein is the one selected for the operation. (Fig. 186.) If a guinea-pig should be chosen, the jugular vein is selected and an anæsthetic is used, the A. C. E. mixture being preferred for general and cocaine for local anæsthesia. The animal is held by an assistant or securely wrapped in a towel fastened with pins, the selected ear is grasped by the root and stretched forward towards the operator, the dorsum of the ear having been previously shaved and cleansed. The syringe is held as one holds a pen, and the needle is thrust through the skin and into the vein itself, being pointed in the direction of the blood stream. The inoculum is then slowly injected and the needle withdrawn.

In the selection of a site for inoculation the general rule is to inject each variety of micro-organism into the kind of tissue which it most

often infests in man. For instance, if the lymph-glands are the primary seat of invasion, the animal should be inoculated in that portion of its body which will afford the quickest means of carrying the infectious material to the lymphatics; as, in the test for glanders the bacillary matter is introduced into the testicle, which contains an abundance of these vessels and but a scant blood supply. Or, if the brain and spinal cord are most affected by the disease, as in rabies, an intracranial inoculation is preferred. Thus, the lesions found during the autopsy and the bacteria seen in the microscopic specimens will give a clue regarding the most desirable seat for the inoculation.

POST-MORTEM EXAMINATION.¹—The post-mortem examination of animals dying from disease produced by experimental inoculation should always be made as soon as possible after their death, and not later than twelve hours. The animal is fastened on a board, ventral surface upward, by nails driven through the extremities, or by being tied with string to special contrivances placed at the corners. Its fur is then wet with a weak antiseptic liquid, such as a two per cent. lysol or a five per cent. carbolic solution, to avoid contamination, to prevent the flying off of hairs, and to kill the vermin which are so often present.

The tray of the sterilizer containing the necessary instruments, such as scissors, scalpels, forceps, etc., and the slides, cover-slips, and culture-media, are placed where they may be easily reached. Then, with sterile forceps and scalpel, the skin of the animal in the middle line is incised from the top of the sternum to the pubes, or, if scissors be used for this purpose, the reverse order is followed. Two other incisions are made at right angles to this line, through the axillæ and groins. The skin is next reflected in flaps, and may be tacked to the board for the sake of security. The seat of inoculation is then inspected, and, if any lesions are visible, the surface is seared and material removed for cultures and smears. The surface of the thorax is seared and the ribs are divided on each side of the sternum, the chest-plate being removed in the usual way. The pericardial sac is burnt through with the searing iron or incised with a scalpel. The right ventricle of the heart is seared, and into it the pipette is passed and filled with blood for the preparation of smears and inoculation of tubes. Through a

¹ The reader is referred to the chapter on comparative postmortems for a fuller description of the technic, especially in necropsies on the larger animals, as the cat, dog, sheep, cow, and horse. The methods in vogue for performing a bacteriologic postmortem are seen in Fig. 187 (guinea-pig) and Fig. 188 (rabbit).

seared tract in the middle line of the abdominal wall an incision is made and a specimen of the peritoneal fluid collected. A specimen of the urine is now saved in the same manner as described for collecting the blood. The spleen is excised and placed in a sterile capsule, and through its seared surface the spear-headed spatula is plunged and twisted around so that the eye is filled with material for microscopic and cultural purposes. This process may need to be repeated several times. The other organs, as the lungs, liver, kidneys, lymphatic glands, etc., are removed in a like manner, and all the cavities of the body carefully examined. Specimens of the various tissues may be cut into cubes and placed in fixing fluids for future sectioning. Eyre suggests that a different knife or separate sterilization is needed for cutting each organ. After use the instruments are sterilized and disinfected by boiling. The animal is wrapped in a cloth moistened with an antiseptic solution, as pure formalin, and cremated. Every precaution should be taken to prevent dispersion of the pathogenic bacteria,—as, *e.g.*, by the dropping of cover-glasses, which on becoming broken might cause infection later on. Von Székely found some dried-up gelatin cultures of anthrax and of malignant œdema, eighteen and one-half years old, to be still virulent to white mice.

CHAPTER XXIV

WEIGHTS AND MEASUREMENTS

A KNOWLEDGE of the weights and dimensions of the normal and pathologic organs of the body is required of all necroscopists. An organ should be measured before it is weighed, with the exception of the intestine, which is preferably measured after it has been opened in its entirety, cleansed, and weighed. Measurements should be made as nearly as possible under similar conditions. In measuring an organ its length, breadth, and thickness may often be more quickly and accurately ascertained by thrusting the steel rule through it than in any other manner. In the healthy body size is dependent upon sex, age, height, and weight of the subject, while in morbid states it differs according to the above conditions and the disease present. Some parts are preferably weighed before opening, others after opening, and still others both before and after the incisions are completed. Letulle advocates the following plan:

Weigh before opening.	Weigh after opening.	Weigh before and after opening.
Pineal gland. Pituitary body. Spinal cord. Spleen. Suprarenals. Thymus and thyroid.	Alimentary tract. Aorta. Bladder. Glands, including salivary. Heart. Pancreas.	Brain. Liver. Lungs. Kidneys. Uterus.

VARIOUS SYSTEMS OF WEIGHTS AND MEASUREMENTS.—It is customary in this country and in England to give the weights of the organs in avoirdupois ounces,¹ their dimensions in inches, and their capacity in cubic inches, though the metric system has more to commend it and will probably be employed after 1909 in all of the Departments of the United States Government in the transaction of business requiring the use of weights and measures. The grain is the same in both Troy and avoirdupois weights. The ounce avoirdupois contains 437.5 grains, or 28.35 grammes; and the ounce Troy, 480

¹ Troy weight is sometimes used and may give rise to much confusion.

grains, or 31.1 grammes. To convert grammes into avoirdupois ounces divide by 28.35; into Troy ounces, divide by 31.1. To convert grammes into grains divide by 0.065. Conversely, to convert ounces avoirdupois into grammes multiply by 28.35; into Troy ounces, multiply by 31.1. To convert grains into grammes multiply by 0.065. A kilogramme equals 1000 grammes, or 2.2 pounds. A gramme equals 1000 milligrammes, or 15.432 grains. A litre equals 1000 cubic centimetres, or 61.028 cubic inches, and is equivalent to 2.113 American pints or 1.76 English pints. A metre equals 1000 millimetres, or 39.37 inches. A millimetre equals $\frac{1}{25}$ of an inch. A micron equals the thousandth part of a millimetre. The following abbreviations are employed in this chapter: mm., for millimetre; cm., for centimetre; in., for inch; ft., for foot or feet; gm., for gramme; kg., for kilogramme; lb., for pound; cc., for cubic centimetre; cu. in., for cubic inch; gr., for grain; dr., for drachm; oz., for ounce.

HEIGHT AND WEIGHT OF THE BODY.—The American Insurance standard is as follows:¹

A man of 5 ft. and 1 in. should weigh....	54.55 kgs. (120 lbs.)
A man of 5 ft. and 3 in. should weigh....	59 kgs. (130 lbs.)
A man of 5 ft. and 6 in. should weigh....	65 kgs. (143 lbs.)
A man of 5 ft. and 9 in. should weigh....	70.45 kgs. (155 lbs.)
A man of 5 ft. and 11 in. should weigh....	75 kgs. (165 lbs.)

The average weight of a full-term boy at birth is 3600 gms. (7 lbs., 15 ozs.); that of a girl, 3250 gms. (7 lbs., 2 $\frac{2}{3}$ ozs.). A child may be born weighing less than a pound and yet live. The mean length of a full-term, sound child is between 50 and 51 cms. (19 $\frac{1}{2}$ and 20 ins.), the male being slightly longer than the female. Draper considers it important to note if the navel is at the middle of the body, as this is the sign of a full-term child. The rule that a child has usually attained double its birth weight at the fifth month and triple at from the twelfth to the fourteenth month is fairly accurate. When a child is two years old, it is about half as tall as it will be when fully grown. The greatest recorded weight is that of a man born in North Carolina in 1798 who measured 7 ft. 8 ins. (2.338 metres) in height and who weighed over 1000 lbs.²

Jamin and Müller, of Erlangen, find the specific gravity of the

¹ From FINLAYSON'S *Clinical Manual*.

² GOULD and PYLE, *Anomalies and Curiosities of Medical Literature*, quoted from the *Medical Press and Circular*.

living body at eight years of age to be 1.130, and 1.065 after sixty. The average for all ages and both sexes is 1.088 in health and 1.074 in pathologic conditions. In obesity it may be as low as 1.004. Katz¹ has made some interesting chemie analyses of muscle taken from man and from the lower animals. The younger the animal, the more water will it contain, the cardiac muscle containing the least water. Fehling² gives the percentage of water in a very young fœtus as 97.5 per cent.; after birth, 74.7. In the adult it is 58.5 per cent. Horse-flesh can be told by its high iodine index and specific blood-test.

The approximate weights of the organs of the body with their percentage in relation to the body-weight are as follows:

	ADULT			NEW-BORN		
	Grammes	Ounces	Percentage	Grammes	Ounces	Percentage
Brain ³	1400	49.	2.37	385.	13.	14.34
Heart	300	10.	0.46	24.	.846	1.00
Lungs	1175	41.	2.	58.	2.045	2.16
Thymus gland	5	0.13	0.0086	10.	.3	0.54
Spleen	170	6.	0.346	8.5	.3	0.34
Liver	1600	57.	2.75	118.	4.162	4.30
Pancreas	200	7.	0.346	11.1	.391	0.41
Kidneys ⁴	300	10.5	0.48	23.6	.832	0.88
Testicles	48	1.5	0.12	0.8	.0282	0.03
Ovaries	14	0.5	0.04	0.5	.0176	0.18
Adrenals	10	0.35	0.014	8.	.3	0.31
Muscles	30000	1050.	43.09	625.	22.045	23.40
Skeleton	11500	400.	15.35	445.	15.696	16.17

Lambion⁵ gives the following figures, obtained at the Liège Maternity, as to the weight of the placenta in cases of miscarriage: The average weight of the placenta at 6 weeks was 20 gms. (5 drs.); at 90 days, 67 gms. (17¼ drs.); at 120 days, 111 gms. (28¾ drs.); at 165 days, 262 gms. (67¾ drs.); and at 235 days, 330 gms. (84⅞ drs.). The average weight of the placenta at term is a little over a pound (500 gms.). The umbilical cord, at birth, averages 27 gms. (7 drs.) in weight and ½ metre (19 ins.) in length.

¹ *Arch. f. d. ges. Physiol.*, 1896, vol. lxxiii, no. 1, p. 1.

² *Cook, Jr. Amer. Med. Assoc.*, June 6, 1903, p. 1548.

³ According to Marchand, the brain's weight at birth is doubled at eight months and is trebled at three years of age.

⁴ The right being about 5 gms. (77 grs.) heavier.

⁵ *De la détermination de l'âge du fœtus d'après le poids du placenta dans les cas de fausse couche*, Paris, 1898.

Embryos¹ about 1 mm. ($\frac{1}{25}$ in.) long are about 12 days old; 2.5 mms. ($\frac{3}{10}$ in.), 14 days old; 4.5 mms. ($\frac{1}{10}$ in.), 19 days old; 7 mms. ($\frac{3}{10}$ in.), 26 days old; 11.5 mms. ($\frac{23}{20}$ in.), 34 days old; 17 mms. ($\frac{2}{3}$ in.), 41 days old. For all embryos from 1 to 100 mms. long, multiply the length of the embryo from the vertex to the breech in millimetres by 100 and extract the square root; the result will be the age in days. For embryos from 100 to 200 mms. long, measure from vertex to breech; this length in millimetres will equal the age expressed in days. Or, for the last five lunar months of fetal life, if the height expressed in centimetres be divided by 5, the approximate age of the child in lunar months will be obtained. For example, if the child measures 35 cms., we divide this by 5, and we have 7, which is the number of months which the child has passed *in utero*. The fetal age of the child in the first five months about equals the square root of the height expressed in centimetres. For example, if the height is 16 cms., the child is 4 lunar months old. In terms of the English system, if the length of the new-born child expressed in inches be divided by 2, it will give approximately the number of lunar months that the child has passed *in utero*.

THE SKULL AND ITS CONTENTS.

Shape.—The form and size of the skull varies. The characteristic measurements of the cranium are its length, height, and breadth. The cephalic index is the ratio of its length (taken as one hundred units) to its breadth. The altitudinal index is the ratio of its length to its height. The accepted horizontal plane is that passing through the upper edges of the external auditory meatus and the lower orbital margin.

According to the variations of the cephalic index, we distinguish the *dolichocephalic* (index less than 75) and the *brachycephalic* (index more than 80) types. Intermediate forms are called *mesocephalic*. If the ratio of the breadth to the height is less than 70, the skull is *platycephalic*; if between 70 and 75, *orthocephalic*; if above 75, *hypsi-cephalic*. The character of the facial profile is indicated by the *facial angle* of Camper,—namely, the angle between a line on the level of the external auditory meatus and the floor of the nasal cavity and a

¹ MALL, *Bull. Johns Hopkins Hosp.*, vol. xiv, no. 143, February, 1903, p. 29: abstracted in *Medicine*, vol. ix, no. 3, 1903, p. 240.

line touching the middle of the forehead and the anterior portion of the alveolar process of the superior maxilla. If this angle be 80 degrees or more, the skull is called *orthognathous*; if it is between 80 degrees and 65 degrees, *prognathous* (Gegenbaur).

Pathologic types of skull are due in part to premature synostosis. Among them we distinguish the *hydrocephalic* type (from dropsy of the ventricles), the *cephalonic* (or big head), the *microcephalic* (or small head), the *dolichocephalic* (or long head), the *sphenocephalic* (or wedge-shaped head, due to compensatory development of the anterior fontanel), the *leptocephalic* (or narrow head), the *clinocephalic* (or saddle-shaped head), the *trigonocephalic* (or triangular head, due to narrowing of the frontal bone from fetal synostosis of the frontal suture), the *brachycephalic* (or short head), the *pachycephalic* (in which the bones of the cranium are thickened), the *oxycephalic* (or pointed head), the *platycephalic* (or flat head), the *trochocephalic* (or round head), and the *plagioccephalic* (or asymmetric oblique head).¹

In the new-born child the anterior fontanel measures from 2 to 2½ cms. (¾ to 1 in.); the occipitofrontal circumference, 34½ cms. (13⅔ ins.); the occipitofrontal diameter, 11¾ cms. (4⅔ ins.); its occipitomenal diameter, 13½ cms. (5⅓ ins.); bisacromial diameter, 12 cms. (4¾ ins.); intertrochanteric diameter, 9 or 10 cms. (3½ or 4 ins.). The width of the large fontanel may be stated to be from 2 to 2½ cms. (¾ to 1 in.).

THE BRAIN.

MALE			FEMALE		
Normal	Maximum	Minimum	Normal	Maximum	Minimum
1400 (49½ oz.)	2222 (78½ oz.)	960 (34 oz.)	1245 (44 oz.)	1585 (55 oz.)	880 (31 oz.)

The average male brain is about 9 per cent. heavier than that of the female. The maximum weight is attained at about 35 years of age in man, possibly somewhat later in the female. The average weight of the cerebrum is about 1000 grammes; of the brain-stem and cerebellum, each 135 grammes. The weight of the pia and arachnoid is 25 to 40 grammes. The brain of the recently deceased Japanese

¹ ZIEGLER'S *Text-Book of Special Pathological Anatomy*, English Translation by MACALISTER and CATTELL, vol. i, pp. 206, 207.

anatomist, Taguchi, weighed 1920 grammes (67¾ ozs.), the body-weight being 49 kgs. Tourgenieff's brain weighed 2120 grammes (74¾ ozs.), while that of Rustan reached 2222 grammes (78⅓ ozs.).

The weight of the encephalon relative to that of the body is subject to great variation, but may approximately be put down as 1 to 36.5 in the adult male and 1 to 35.2 or 1 to 36.46 in the female. These figures are based on observations upon persons dying from more or less prolonged disease, but in the cases of a few individuals who died suddenly from disease or accident the average ratio was found to be 1 to 41. The proportion to body-weight is much greater at birth than at any other period of extra-uterine life, being about 1 to 5.85 in the male and 1 to 6.5 in the female.

The weight of the human cerebrum also bears a somewhat definite relation to the stature of the individual. The weight in ounces may be obtained for a male by dividing the height in inches by 1.6, and for a female by multiplying the quotient thus obtained by $\frac{30}{31}$. The weight in grammes may be obtained by multiplying the height in centimetres by 7 for a male, and the product again by $\frac{30}{31}$ for a female. Thus,

$$\begin{aligned} \text{Weight in ounces of the mean cerebrum} & \dots\dots\dots = \frac{\text{height in inches}}{1.6} \\ \text{Weight in ounces of the mean female cerebrum} & \dots\dots = \frac{\text{height in inches}}{1.6} \times \frac{30}{31} \\ \text{Weight in grammes of the mean male cerebrum} & \dots = \text{height in centimetres} \times 7 \\ \text{Weight in grammes of the mean female cerebrum} & = \text{height in centimetres} \times 7 \times \frac{30}{31} \end{aligned}$$

These proportions are slightly deficient for the higher and excessive for the lower statures.

Dimensions.—The mean cubic capacity of the male cranium is 1450 ccs. (88½ cu. ins.); that of the female is 1300 ccs. (79⅓ cu. ins.). (Welcker.) The length of the male brain is from 160 to 170 mms. (6⅔ to 6⅘ ins.); that of the female brain is from 150 to 160 mms. (6 to 6⅔ ins.). The greatest transverse diameter is 140 mms. (5⅓ ins.); the greatest vertical diameter is 125 mms. (5 ins.). The volume is about 1330 ccs. (81 cu. ins.). The specific gravity of the brain is from 1.035 to 1.040.

PITUITARY GLAND: Length, 0.008 metre ($\frac{1}{3}$ in.); breadth, 0.012 metre ($\frac{1}{2}$ in.); thickness, 0.065 metre (2⅓ in.); weight, 5 gms. (77 grs.). (Zander.)

PINEAL GLAND measures 0.01 metre ($\frac{2}{5}$ in.) by 0.005 metre ($\frac{1}{5}$ in.) by 0.005 metre ($\frac{1}{5}$ in.) (Charpy), and weighs 0.20 gm. (3 grs.). (Engel.)

SPINAL CORD measures in the adult 0.448 metre ($17\frac{1}{3}$ ins.), and its weight, deprived of its nerves, is 27 to 30 gms. (415 to 463 grs.). The transverse diameter of the cervical enlargement, 0.013 metre ($\frac{1}{2}$ in.); of the dorsal, 0.01 metre ($\frac{2}{5}$ in.); of the lumbar, 0.012 metre ($\frac{1}{2}$ in.). The anteroposterior diameter of the cervical enlargement, 0.009 metre ($\frac{9}{25}$ in.); of the dorsal, 0.008 metre ($\frac{8}{25}$ in.); of the lumbar, 0.009 metre ($\frac{9}{25}$ in.).

THE HEART.

Weight.—The mean weight of the heart in the adult male is about 310 gms. (11 ozs.); its proportion to the body-weight is 1 to 169. That of the adult female is about 255 gms. (9 ozs.); proportion to body-weight, 1 to 149. The specific gravity of the heart is 1.055, or about that of the blood (1.058). The amount of blood in the entire body is ordinarily estimated at $\frac{1}{13}$ of the body-weight, but the later investigations of Haldane and Smith place it at 1 to 20.5.

Dimensions.—The determination of the exact measurements of the heart is most difficult, as the muscular fibres contract and expand under such diverse circumstances and the positions of the parts are so different. Constantin Paul has called attention to the fixed manner in which the inferior vena cava enters into the heart on a line with the tip of the right auricular appendix. The heart is generally of about the same size as the right fist of the cadaver. Its extreme length is about 125 mms. (5 ins.); width, 87 mms. ($3\frac{1}{2}$ ins.); thickness, 62 mms. ($2\frac{1}{2}$ ins.), slightly less in the female than in the male. The thickness of the wall of the right ventricle is from 2 to 5 mms. ($\frac{1}{8}$ to $\frac{1}{2}$ in.); of the left ventricle, from 7 to 12 mms. ($\frac{1}{4}$ to $\frac{2}{5}$ in.); ventricular septum, 15 mms. ($\frac{3}{5}$ in.). Pathologically, these measurements may be increased threefold or more.

The dimensions of the orifices of the heart are shown in the following tabular statement:

Orifices.	Diameter.	Circumference.		Area.	
		Male.	Female.	Male.	Female.
Aortic.....	24 to 25 mms., or 0.9 to 1 in.	81 mms.	76 mms.	530 sq. mms.	452 sq. mms.
Mitral	30 to 35 mms., or 1.2 to 1.4 ins.	103 mms.	101 mms.	855 sq. mms.	804 sq. mms.
Pulmonary	27 to 30 mms., or 1.1 to 1.2 ins.	91 mms.	89 mms.	660 sq. mms.	615 sq. mms.
Tricuspid.....	37 to 45 mms., or 1.5 to 1.8 ins.	122 mms.	115 mms.	1194 sq. mms.	1017 sq. mms.

In childhood the pulmonary orifice is wider than the aorta; at puberty, of equal width; in the adult the converse holds good.

Volume.—In the new-born the volume is about 20 to 25 ccs. ($\frac{2}{3}$ to $\frac{5}{6}$ fl. oz.), which is increased to 250–310 ccs. ($8\frac{5}{8}$ to $10\frac{1}{2}$ fl. oz.) in the adult. Up to the age of puberty it is about the same in both sexes, but after that it is from 25 to 30 ccs. ($\frac{5}{6}$ to 1 fl. oz.) larger in the male. Because of obvious difficulties, these figures can only be regarded as approximate.

Thickness of the aorta, $1\frac{1}{2}$ to 2 mms. ($\frac{1}{8}$ to $\frac{2}{5}$ in.). (Orth.) Circumference of the thoracic aorta, 4 to 6 cms. ($1\frac{1}{2}$ to 2 ins.); of the abdominal aorta, 35 to 45 cms. ($13\frac{3}{4}$ to $17\frac{3}{4}$ ins.); weight, 35 to 45 gms. ($1\frac{1}{4}$ to $1\frac{5}{8}$ ozs.). The transverse sections of the aorta will about admit the thumb. The length of the inferior vena cava is 0.22 to 0.25 metre ($8\frac{2}{3}$ to $9\frac{7}{8}$ ins.); of the superior, 0.06 to 0.08 metre ($2\frac{3}{8}$ to $3\frac{1}{6}$ ins.); of the great azygos, 0.20 to 0.25 metre ($7\frac{7}{8}$ to $9\frac{7}{8}$ ins.); and of the portal veins, 0.05 to 0.12 metre (2 to $4\frac{3}{4}$ ins.).

THE THORACIC DUCT.

The length of the thoracic duct is 0.30 to 0.34 metre ($11\frac{3}{4}$ to $13\frac{3}{8}$ ins.).

THE LUNGS.

Weight.—Obviously the lungs are subject to great variation in weight, depending upon the amount of blood or other liquid in their cavities. Their combined weight ranges from 850 to 1370 gms. (30 to 48 ozs.), the average being from 1020 to 1190 gms. (36 to 42 ozs.). (1300 gms. in the male and 1023 gms. in the female.—Krause.) The right is generally 59 gms. (2 ozs.) heavier than the left. The weight of the right lung is from 360 to 570 gms. ($12\frac{2}{3}$ to $20\frac{1}{3}$ ozs.); that of the left lung, from 325 to 480 gms. ($11\frac{1}{2}$ to 17 ozs.). The lungs are heavier in the male than in the female, and also appear to be heavier in proportion to the body-weight.

Dimensions.—The extreme length of the right lung in the male is 271 mms. ($10\frac{4}{5}$ ins.), and that of the left is 298 mms. (12 ins.); in the female, 216 mms. ($8\frac{3}{5}$ ins.), and 230 mms. ($9\frac{1}{5}$ ins.), respectively. The extreme outer and posterior diameters in the male are, of the right, 203 mms. ($8\frac{1}{8}$ ins.), and of the left, 176 mms. (7 ins.); and in the female, 176 mms. (7 ins.), and 162 mms. ($6\frac{1}{2}$ ins.), respectively. The transverse diameter at the base is, in the male, 135 mms. ($5\frac{2}{5}$ ins.) for the right, and 129 mms. ($5\frac{1}{6}$ ins.) for the

left. In the female the measurements are 122 mms. ($4\frac{7}{8}$ ins.), and 108 mms. ($4\frac{1}{3}$ ins.), respectively. (Krause, quoted by Vierordt.)

The specific gravity of a healthy adult lung varies from 0.345 to 0.746. When fully distended with air it is about 0.126, while that of the lung tissue itself, entirely deprived of air, is about 1.056, which is again about the specific gravity of the blood.

THE SALIVARY GLANDS.

Parotid (weight), 25 to 30 gms. (386 to 463 grs.); submaxillary, 8 gms. (124 grs.); sublingual, 2 to 3 gms. (31 to 47 grs.).

THE ALIMENTARY TRACT.

ESOPHAGUS, length, 0.26 metre ($10\frac{1}{4}$ ins.); breadth, 0.045 metre ($1\frac{4}{5}$ ins.); thickness, 0.009 metre ($\frac{1}{3}$ in.); weight, 40 gms. ($617\frac{1}{4}$ grs.).

STOMACH (empty), length, superior border, 0.09 metre ($3\frac{3}{8}$ ins.); thickness, 0.007 metre ($\frac{7}{5}$ in.); weight, 145 gms. ($5\frac{1}{5}$ ozs.).

SMALL INTESTINE, length, 6 to 8 metres ($19\frac{2}{3}$ to $26\frac{1}{4}$ ft.); weight, 640 to 730 gms. ($22\frac{4}{7}$ to $25\frac{3}{4}$ ozs.); duodenum, length, 0.26 metre ($10\frac{1}{4}$ ins.). Large intestine, length, 1.40 to 1.70 metres (45 to 67 ins.); cæcum, 0.08 to 0.1 metre ($3\frac{1}{8}$ to 4 ins.); weight, 460 gms.

VERMIFORM APPENDIX, length, 0.04 to 0.08 metre ($1\frac{1}{2}$ to 3 ins.); weight, 7 to 20 gms. (100 to 300 grs.). The longest appendix of which we have found a record is 33 cms. ($12\frac{1}{4}$ ins.).

THE LIVER.

Weight.—The liver weighs from 1400 to 1700 gms. (50 to 60 ozs.) in males, and a little less in females. The weight varies, whether before or after letting out the blood, especially in certain cardiac cases and in the enlargement from malaria. In a four-months' fœtus it is about one-tenth of the body-weight; at birth it is one-twentieth; in the adult male it is one-fortieth; in the adult female it is one thirty-sixth. Supernumerary livers may weigh 28.35 gms. (1 oz.) or more.

Dimensions.—The transverse diameter is from 150 to 300 millimetres, or 6 to 12 inches; vertical diameter, from 75 to 175 millimetres, or 3 to 7 inches; and anteroposterior, from 75 to 175 millimetres, or 3 to 7 inches. According to Orth, the transverse diameter of the liver varies from 25 to 30 centimetres, that of the right lobe being from 18 to 20 centimetres and that of the left from 8 to 10 centimetres. The anteroposterior diameter averages from 19 to 21 centimetres,—

from 20 to 22 centimetres for the right lobe and 15 or 16 centimetres for the left. The greatest vertical diameter is from 6 to 9 centimetres. The hepatic lobules vary in size from 1 to 3 millimetres.

Volume and Specific Gravity.—This varies from 1475 to 1638 ccs. (90 to 100 cu. ins.). The mean volume is 1574 ccs. (96 cu. ins.). The specific gravity is between 1.050 and 1.060, which in fatty degeneration may be reduced to such an extent that small portions of the liver will float upon the water.

Gall-bladder: length, 0.08 to 0.17 metre ($3\frac{1}{6}$ to $6\frac{2}{3}$ ins.); diameter at base, 0.03 metre ($1\frac{1}{5}$ ins.); thickness of wall, 1 to 2 mms. ($\frac{1}{25}$ to $\frac{1}{13}$ in.).

THE KIDNEYS.

Weight.—Each kidney weighs from about 127.5 to 170 gms. ($4\frac{1}{2}$ to 6 ozs.) in the male, and from 113 to 156 gms. (4 to $5\frac{1}{2}$ ozs.) in the female. The left kidney is usually a little heavier than the right,—from 5 to 7 gms. (77 to 108 grs.) heavier. At the end of the first year the kidneys together weigh 62 gms. (2 ozs.). The ratio of the weight of the kidneys to the body is as 1 to 200. The mean proportion of the weight of the heart to the weight of the kidneys between the ages of twenty and thirty-five years is as 1 to 1.1 (Thoma).

Dimensions.—Length, about 10 cms. (4 ins.); breadth, 5 to 6 cms. (2 to $2\frac{1}{3}$ ins.); and thickness, from 3 to 3.5 cms. ($1\frac{1}{4}$ to $1\frac{1}{2}$ ins.); or in the proportion of about 1 to $\frac{1}{2}$ to $\frac{1}{3}$. The left kidney is usually a little longer and narrower than the right.

Specific Gravity.—About 1.050.

The following points serve to distinguish between the right and left kidneys:

RIGHT KIDNEY.

Impression from liver.
Shorter and broader than its fellow.
From 5 to 7 grammes lighter than its fellow.
The spermatic or ovarian vein empties into the inferior vena cava.

LEFT KIDNEY.

No impression from spleen.
Longer and narrower than its fellow.
About 5 to 7 grammes heavier than its fellow.
The spermatic or ovarian vein empties into the renal vein.

The right kidney is usually situated a little lower down in the body than its fellow, owing to the liver being larger than the spleen.

In both kidneys the posterior surface is the flatter, the external border is convex, the internal border concave, and the upper portion is more expanded than the lower. At the hilum the attachment of ves-

sels and ureter is, from above downward, the body being in the erect posture, artery, vein, ureter (AVU); and from before backward, vein, artery, ureter (VAU). Place the organ on the table, with its posterior surface down, the lower extremity (the ureter pointing downward) being towards the observer. The ureter is then behind and below the other vessels, and the hilum will be directed towards the side of the operator to which the kidney belongs,—*i.e.*, towards the left hand if it is the left kidney, and towards the right hand if it is the right kidney.

The ureters are from 27 to 30 cms. ($10\frac{5}{8}$ to $11\frac{7}{8}$ ins.) long, with a circumference of 1 cm. ($\frac{2}{5}$ in.). Bladder: height, when empty, 4 cms. ($1\frac{1}{2}$ ins.); transverse diameter, 6 to 7 cms. ($2\frac{1}{3}$ to $2\frac{3}{4}$ ins.); weight, 30 to 60 gms. (1 to 2 ozs.). Urethra: male, 15 to 17 cms. ($5\frac{3}{4}$ to $6\frac{3}{4}$ ins.); female, 3.5 cms. ($1\frac{3}{8}$ ins.), with a diameter of 7 to 10 mms. ($\frac{1}{4}$ to $\frac{3}{5}$ in.).

THE ADRENALS (SUPRARENAL BODIES).

Weight.—Each suprarenal weighs about 5 gms. (75 grs.), the left being slightly the heavier. They are nearly as large at birth as in adult life.

Dimensions.—Vertical length is from 30 to 50 mms. ($1\frac{1}{4}$ to 2 ins.); breadth, from side to side, about 30 mms. ($1\frac{1}{4}$ ins.); thickness, from 5 to 6 mms. ($\frac{1}{5}$ to $\frac{1}{4}$ in.).

THE SPLEEN.

Weight.—This organ varies in health within wide limits in both size and weight. Ordinarily its weight is between 100 and 300 gms. ($3\frac{1}{2}$ and 10 ozs.), with the average at about 170 gms. (6 ozs.). In intermittent and sometimes other fevers it may weigh 18 to 20 lbs. Its weight in proportion to the body-weight is at birth about 1 to 350; in the adult, 1 to from 320 to 400; and in old age, 1 to 700.

Dimensions.—Generally the spleen is from 125 to 150 mms. (5 to 6 ins.) in length; from 75 to 90 mms. (3 to $3\frac{1}{2}$ ins.) in breadth; and from 25 to 40 mms. (1 to $1\frac{1}{2}$ ins.) in thickness.

Volume.—This does not usually exceed from 200 to 300 ccs. (12 to 18 cu. ins.).

THE PANCREAS.

Weight.—The weight is variable,—from 30 to 100 gms. (1 oz. to $3\frac{1}{2}$ ozs.); it may even be 170 gms. (6 ozs.) in adults.

Dimensions.—Length, 23 cms. (9 ins.); breadth, 4.5 cms. ($1\frac{1}{2}$ ins.); thickness, 3.8 cms. ($1\frac{1}{2}$ ins.). (Orth.)

Specific Gravity.—1.046.

THE THYMUS GLAND.

Weight.—See p. 107.

Dimensions.—At birth the length is about 60 mms. ($2\frac{3}{5}$ ins.); width, 37 mms. ($1\frac{1}{2}$ ins.); and thickness, from 6 to 8 mms. ($\frac{1}{4}$ to $\frac{1}{3}$ in.). From birth to the second month the length is 5.2 cms. (2 ins.); from the ninth month to the second year, 6.96 cms. ($2\frac{3}{4}$ ins.); and from the third to the fourteenth year, 8.44 cms. ($3\frac{1}{3}$ ins.). The breadth across the middle is from 2.7 to 4.1 cms. (1 to $1\frac{3}{5}$ ins.); above and below, from 0.7 to 0.9 cm. ($\frac{7}{25}$ to $\frac{9}{25}$ in.). (Friedleben.)

THE THYROID GLAND.

Weight.—From 28 to 56 gms. (1 to 2 ozs.), being larger in the female.

Dimensions.—Each lateral lobe is about 50 mms. (2 ins.) in length, from 18 to 30 mms. ($\frac{3}{4}$ to $1\frac{1}{4}$ ins.) in breadth, and from 18 to 25 mms. ($\frac{3}{4}$ to 1 in.) in thickness. The right lobe is usually the larger. The isthmus is nearly 12 mms. ($\frac{1}{2}$ in.) in breadth, and from 6 to 18 mms. ($\frac{1}{4}$ to $\frac{3}{4}$ in.) in depth.

THE TESTES.

Weight.—Each testicle with its epididymis weighs from 18 to 25 gms. ($4\frac{1}{2}$ to 6 drs.), the left being slightly the heavier.

Dimensions.—Length, about 37 mms. ($1\frac{1}{2}$ ins.); breadth, antero-posterior, 30 mms. ($1\frac{1}{4}$ ins.); thickness, from side to side, 24 mms. (1 in.).

THE OVARIES.

Weight.—From 4 to 8 gms. (1 to 2 drs.).

Dimensions.—Length, usually about 37 mms. ($1\frac{1}{2}$ ins.); breadth, 18 mms. ($\frac{3}{4}$ in.); thickness, 12 mms. ($\frac{1}{2}$ in.). The right is usually a little larger than the left.

Nauwerck, quoting from Puech, gives the following dimensions:

Length, maidens	from 4.1 to 5.2 cms. ($1\frac{3}{5}$ to 2 ins.).
Length, women	from 2.7 to 4.1 cms. (1 to $1\frac{3}{5}$ ins.).
Breadth, maidens	from 2.0 to 2.7 cms. ($\frac{3}{4}$ to 1 in.).
Breadth, women	from 1.4 to 1.6 cms. ($\frac{1}{2}$ to $\frac{5}{8}$ in.).
Thickness, maidens	from 1.0 to 1.1 cms. ($\frac{2}{5}$ to $1\frac{1}{5}$ in.).
Thickness, women	from 0.7 to 0.9 cms. ($\frac{1}{4}$ to $\frac{9}{10}$ in.).

THE UTERUS.

Weight.—Generally from 28 to 42 gms. (1 to 1½ ozs.) in virgins and 105 to 120 gms. in multiparæ.

Dimensions.—The virgin uterus is from 5.5 to 8 cms. long, from 3.5 to 4 cms. broad, and from 2 to 2.5 cms. thick; in multiparæ the womb is from 9 to 9.5 cms. long, from 5.5 to 6 cms. broad, and from 3 to 3.5 cms. thick. The walls of the virgin uterus are from 1 to 1.5 cms. thick; of the cervix, from 0.7 to 0.8 cms. thick. In multiparæ the uterine walls may be as thick as 2 cms. and the cervix is from 0.8 to 0.9 cm. thick. (Orth.)

The length of the uterine cavity in virgins is 5.2 cms., after the menopause 5.6 cms.; in multiparæ 5.7 cms., after the menopause 6.2 cms. (Nauwerck.)

THE BREASTS.

Weight.—Breasts at birth, 0.30 to 0.60 gm. (4⅝ to 9¼ grs.); of adult, 150 to 200 gms. (5¼ to 7 ozs.); during lactation, 400 to 900 gms. (14 to 31¾ ozs.).

THE PROSTATE AND SEMINAL VESICLES.

Weight.—Average, from 18 to 20 gms. (4½ to 4¾ drs.).

Dimensions.—Transverse diameter, about 37 mms. (1½ ins.); vertical, 30 mms. (1¼ ins.); anteroposterior, 18 mms. (¾ in.). These measurements are subject to great variation, according to the fulness of the rectum and bladder.

The seminal vesicles measure 4.2 by 17 by 0.9 cm. (1⅓ by 6⅓ by ⅓ in.).

(For elaborate tables showing the average dimensions and weights of the various parts and organs of the human body, the reader is referred to volume one of the *National Medical Dictionary*, by Billings. The regulations for making medicolegal autopsies in Bavaria, as amended in 1897, also give some weights and measurements of value.)

CHAPTER XXV

POST-MORTEM EXAMINATIONS OF THE LOWER ANIMALS ¹

THE great number, importance, and variety of diseases which human beings may contract from the lower animals are increasingly obtaining recognition. Our domestic animals suffer from nearly all the contagious maladies found in man, and impart to him various disorders from which he would otherwise be exempt, such as glanders, actinomycosis, anthrax, hydrophobia, foot-and-mouth disease, echinococcus cysts, trypanosomiasis, etc. The rat disseminates bubonic plague, the mosquito malaria, yellow fever, and dengue, and the pig trichinosis, and were it not for the rat, the mosquito, and the pig these diseases would probably cease to exist. The lower animals are especially rich in parasitic diseases and in malformations. As stated by Orth, the advantages of a study of animal pathology is that the necessary material is easy to obtain, and by voluntary killing accurate morphologic investigations may be made in a perfectly fresh condition at any desired stage of the disease.

Many of the suggestions made in the previous chapters apply with equal force to the performance of necropsies upon the lower animals. Such examinations are of two distinct classes,—veterinary postmortems and laboratory postmortems. For laboratory study small animals, such as the guinea-pig (Fig. 187), rabbit (Fig. 188), mouse, and rat, are generally chosen, while in veterinary investigation the subject is usually a dog, a horse, a cow, sheep, goat, or cat. So intense is the interest now taken in comparative pathology that all classes of animals come to section, even reptiles (especially snakes) receiving no small amount of attention.

INSTRUMENTS.—In post-mortem examinations of the large domestic animals (cow, horse, mule, etc.) the instruments used must necessarily be larger than those employed in human autopsies. The following is a partial list: (1) Large butcher's knife, to remove the skin, expose the thorax and abdomen, and incise the organs; (2) large

¹ Much of the material and all the illustrations in this chapter are taken from KIRK's excellent work entitled *Lehrbuch der pathologischen Anatomie der Haustiere*, 1905, vol. i, pp. 1-56, and 1900, vol. ii, pp. 1-54.

cleaver; (3) large butcher's saw, to open the thoracic and cranial cavities, expose the nasal septum, etc.; (4) large chisel, to remove the cord; (5) hammer, for the same purpose; (6) bone-forceps (costotome); (7) enterotome; (8) scissors; (9) brain-knife; (10) dissecting forceps; (11) large needle; (12) a meat-axe, watering can, strong twine, etc. Kitt cautions the veterinarian against using the same knife for a pathologic postmortem that is subsequently to be used upon an animal whose flesh is to be eaten.

UTENSILS.—Buckets, pitchers, large and small enamelled plates, sponges, soap, towels, and disinfectants, and green soap or lysol are especially useful.

CLOTHING.—An operator's apron may be drawn over the clothes or an ordinary rain-coat worn, but a special suit for operating is better.

GENERAL SUGGESTIONS.—In many cases the necropsy must be made at the place where death occurred, be this in the fields, stable, slaughter-house, or veterinary morgue. The procedure will vary with the conditions and conveniences, but the end in view should be carefully considered and certain general rules observed. If the animal is alive, the method of killing to prepare for the desired investigation should be one that will not injure the organs involved. In cerebral trouble the animal should not be killed by a blow upon the head, but by poison or chloroform; in inflammatory conditions all loss of blood should be avoided; if the trouble is in the digestive system, no poison should be used; and in pulmonary affections the animal must not be shot through the heart (Csokor).

OPERATIVE TECHNIC.—In opening the cadaver the normal position of the intestines should be retained as far as possible, and they should be carefully examined to see that they are uninjured and are sufficiently exposed. Horses, large and small ruminants, and the larger swine are usually placed upon the left side of the body so that the right side may be opened. A dorsal position may be chosen for dogs and cats, and even for swine or larger animals if sufficient assistance be present, as it gives a better view of the abdominal cavity.

The postmortem is begun by removing the hide, which has a market value and must not be injured. As scalpels and straight-edged knives are apt to button-hole the skin, a butcher-knife with rough cutting edge is to be preferred. Beginning at the angle of the chin a longitudinal incision is made down the median line the whole length of the body, avoiding the udder, prepuce, and scrotum, and the navel in the case

of young animals. A transverse incision is made perpendicular to the first along the median surface of the foreleg and the skin is drawn back from the edges up over the dorsal surface. A similar cut is made upon the median surface of the thigh and leg down to the tuberosity of the os calcis. On both the limbs and the body the hair-seams will serve as a useful guide for the knife. A circular incision is made around the head from angle to angle at the lips, thus permitting the removal of the eyelids, ears, etc. If the head is to be preserved, as in the case of a deer, the circular incision is made at the manubrium. The skin may be detached either with the hands or with the handle of a chisel, and is more easily removed when the animal is warm than after rigidity has set in.

REMOVAL OF THE EXTREMITIES.—After the animal has been skinned, it is placed on its side, and the uppermost limbs are removed in order to secure more room for subsequent manipulation. First the foreleg is held up by an assistant and the shoulder-joint disarticulated. The musculature of the part is cut through in the median portion by a butcher-knife grasped firmly by the whole hand. During the execution the extremity should be constantly raised by an assistant and the blade of the knife should be held somewhat towards the thorax so as to cut obliquely to the ribs.

To remove the posterior extremity make a deep circular incision through the hip muscles, beginning with the broad crural fascia and above the large trochanter, passing up over and through the musculature of the croup and downward and outward into the ischiatic fossa, but not behind the tuberosity of the ischium; raise the foot; cut through the adductors in a line with the acetabulum, open its capsular ligament, and section the round ligament. The incision of the capsular ligament is accompanied by a snapping sound, due to the entrance of air into the joint. The limb can now be drawn backward, the remaining fascia and muscles sectioned, and the whole removed.

EXPOSURE OF THE ABDOMINAL CAVITY.—Before opening the abdominal cavity of a filly the udder should be entirely removed from the abdominal wall, and in geldings and stallions the scrotum and the penis should be isolated and thrown back, and in newly born animals the umbilicus and adjacent parts are not to be injured. It should be remembered that in herbivora meteorism occurs soon after death, so that the intestines are pressed up closely against the abdominal wall and may easily be injured.

The operator should stand in the space between the remaining extremities with his face towards the breast of the animal. An incision is made through the median line of the body, beginning with the ensiform cartilage of the sternum, extending as far as the pubic region, cutting through the muscles and fascia only and not injuring the peritoneum. This will not be difficult if the blade of the knife be held flat and the ball of the thumb placed near the edge and close to the point. As the peritoneum is carefully torn through with the fingers, the exit of gases, liquids, or abnormal contents of the abdominal cavity should be noted, as well as the position of the intestines. The index and middle fingers are then separated so as to form a V-shaped space, in which the knife is placed and its point thrust through the abdominal wall along the line of the *linea alba*, the fingers following. At the posterior end of the longitudinal incision a second incision is made, perpendicular to the first, extending from the pubic region to the lumbar. The right upper half of the abdominal wall is held up by its edges with the left hand. The assistant pulls on the lower ribs in order to make the abdomen tense, and its covering is cut through with sawing strokes of the knife as far as the costal processes. The knife is so held by the whole hand that the point is shoved away from the operator towards the lumbar region and the lower part of the blade is used instead of the point.

We have now a large anterior and a small posterior segment of the abdominal wall. They may easily be drawn back and a view of the abdominal organs obtained. The ribs of the horse extend so low down that a sufficiently extensive view for pathologic purposes cannot be obtained; therefore, before removing the abdominal contents the thoracic cavity is exposed. Then, by thrusting the hand well up under the lower ribs, we notice whether the diaphragm is tightly vaulted forward or is more or less relaxed.

EXPOSURE OF THE THORACIC CAVITY.—A small incision is made between two of the true ribs and note is taken whether or not air enters the thoracic cavity and the diaphragm becomes relaxed. If the abdominal examination showed the diaphragm drawn down posteriorly, the incision should receive special attention; instead of air entering, there may be an exit of gas from the pleural cavity, indicating some essentially pathologic condition. Whether there be a positive or negative pressure may readily be determined by a trocar connected by a rubber tube with a V-shaped tube filled with mercury.

The direction for cutting the ribs is through the costal angles following the course of the iliocostal muscle. An incision is made between the true ribs and the blade of the saw introduced, an assistant making the breast tense while the sawing is done; very little pressure

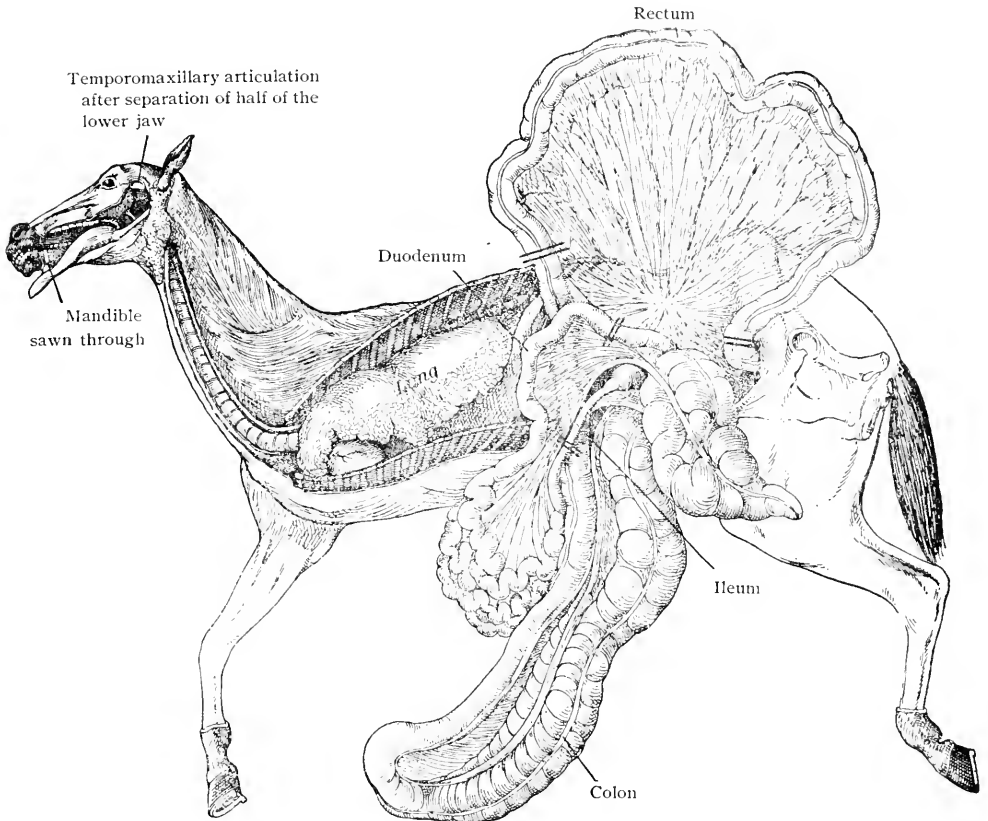


FIG. 189.—Equine viscera, the animal resting on its right side, the anterior and posterior left limbs having been removed, and the abdominal, thoracic, oral, and pharyngeal cavities opened. The double lines show the places in the intestines which are to be tied previous to being cut.

should be used or the bone will splinter. When the ribs have been sawed through, they are turned over towards the median line and removed by severing the costal cartilages. The situation of the organs and the pathologic contents should be carefully noted. (Fig. 189.)

REMOVAL OF THE ABDOMINAL CONTENTS IN THE RIGHT LATERAL POSITION.—After exposing the abdominal cavity by the longitudinal and transverse incisions, pull the two left coils of the colon either up

over the thorax or out across the body on the right side, so that the sigmoid flexure looks towards the head or lies on the ground and the body and tip of the cæcum come into view. Spread the mesorectum out over the left flank and pelvic region. Stroke back the fæces, doubly

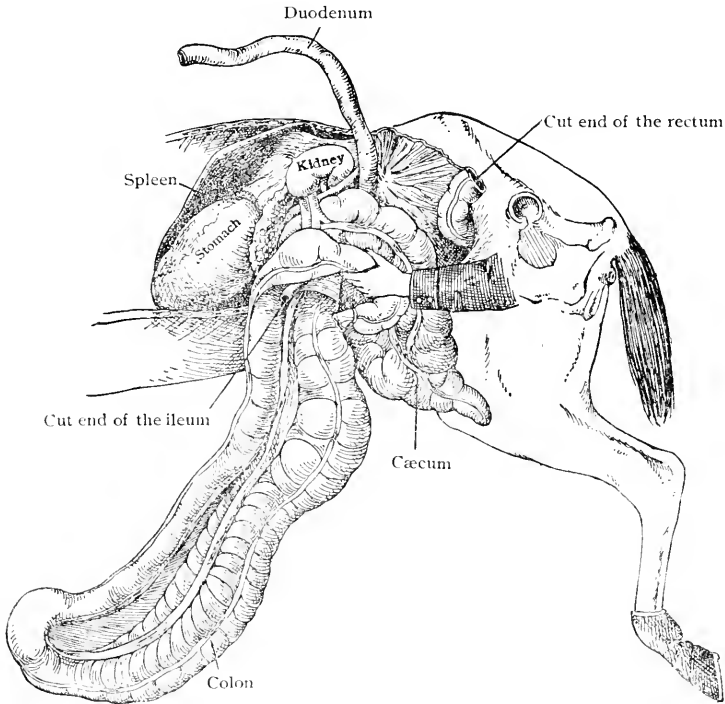


FIG. 190.—Further dissection of animal seen in Fig. 189. Appearance of the parts after removal of the rectum, ileum, and jejunum.

ligate the rectum at its entrance into the pelvis, and section. Cut away the mesorectum up to its origin at the rectoduodenal ligament, doubly ligate the rectum, section, and remove.

The ileum is easily recognized by its thicker walls and its entrance into the cæcum. Apply a double ligature, section, and, holding the intestine in the hand, cut away all the mesentery from the whole of the small intestine as far as the rectoduodenal ligament, divide this, doubly ligate the duodenum, and section. The junction of the colon with the rectum is now exposed,—the so-called stomach-like or gastroid dilatation,—under which lies the anterior root of the mesentery. Grasping the dilatation with the left hand (Fig. 190), pull it towards

the cæcum, and with the right hand work loose or cut partly away the connections between the gastroid dilatation and cæcum and the omental sac, kidney, and pancreas. In this way better access to the portal vein and anterior root of the mesentery is obtained. With the fingers work through the cellular tissue surrounding the root of the mesentery, grasp it with the hand, and together with the portal vein cut it away close to the intestine, leaving as much of it as possible with the aorta. The colon and cæcum are now drawn out of the cavity, all the remaining sections being easily torn or cut away, while the right branch of the pancreas which lies upon the cæcum and the root of the mesentery must be carefully dissected away. Grasp the spleen, section the suspensory (gastrosplenic) ligament and the gastrosplenic omentum, and free the spleen from the stomach. Separate the branches of the pancreas from the larger blood-vessels and the kidneys, so that it hangs only by its body from the liver, and leave it in this position or, after examining its excretory duct, cut it away. Next remove the stomach and duodenum by cutting along the sigmoid curvature and the smaller curvature of the stomach and by sectioning the duodenorenal ligament, the hepatic and pancreatic ducts, the diaphragmatic and gastrohepatic ligaments, and the œsophagus, after pulling the latter down as far as possible from the diaphragm. Excision of the liver is an easy matter: section first the left lateral ligament, then the coronary and suspensory ligaments, the vena cava on the anterior surface of the liver, the right lateral portion of the coronary ligament, and the right hepatic and renal hepatic ligaments.

REMOVAL OF THE ABDOMINAL CONTENTS IN THE LEFT LATERAL POSITION.—The rectum is sectioned at its entrance into the pelvis after pressing back the fæces with the fingers, applying a double ligature, and cutting between them. Seize the colon at its anterior curvature and pull it carefully out of the abdominal cavity as far as possible. The left folds of the colon will fall out with very little assistance. (Fig. 191.)

In the region of the kidney will be seen the arch of the duodenum lying between the anterior and posterior roots of the mesentery and covered by the ribs. Cut through this arch and its mesentery, after applying a double ligature, and remove. The cellular tissue lying between the cæcum and psoas muscle and the right kidney should be carefully worked loose and the pancreas separated from the cæcum and the colon; this is done by tearing or cutting through the peritoneum

covering the intestine and pancreas, getting the hand in under the pancreas, and working it loose. Beginning posteriorly, cut away the mesorectum from behind forward and any connections that may remain between the cæcum and colon and the region of the kidney, grasp as much as possible of the attachment of the mesentery, pull the intestine back away from the kidney, and section the root of the mesentery in front of the left hand, as far from the aorta as possible. With

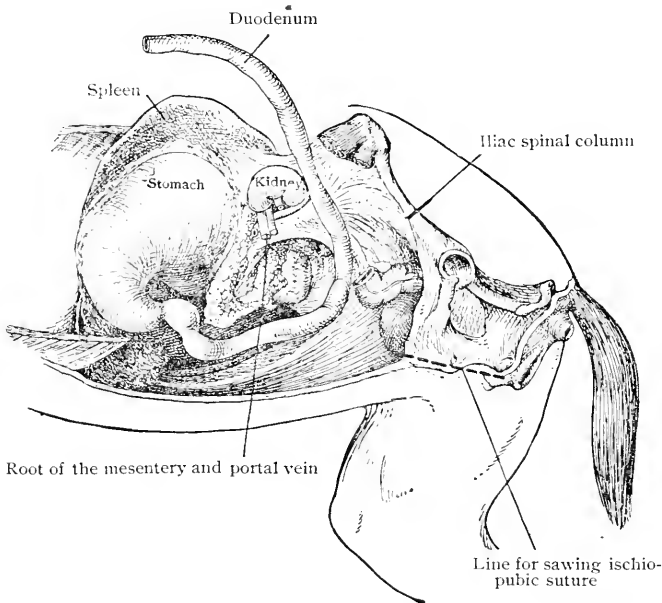


FIG. 191.—Further dissection of animal seen in Figs. 189 and 190. Appearance of the parts after removal of the large intestine.

the exception of a small portion of the duodenum and the pelvic portion of the rectum the large and small intestines can be drawn out from the abdominal cavity by cutting or tearing away any attachments which may remain; the operator stands alternately at the back and in front of the cadaver while removing these portions.

REMOVAL OF THE KIDNEYS, STOMACH, LIVER, AND SPLEEN.—The removal of the kidneys leaves a freer field for the stomach, spleen, and liver. With the hand and fingers separate first the right and then the left kidney and the suprarenal capsules from the surrounding cellular tissue. If the ureters and kidneys are intact the kidneys may at once be cut away together with their vessels. In case of any abnormalities they should be left hanging or a sufficient length of the ureters removed

with them, together with the surrounding tissues, or they may remain attached to their ureters and be placed in the pelvic region.

The pancreas, spleen, and stomach are freed from the mesentery and sectioned. The assistant pulls on the right side of the diaphragm, and the inferior vena cava between it and the liver is cut through, together with the œsophagus and the right hepatic ligament. The stomach is turned backward. The left hepatic ligament is sectioned and all the three organs removed together in a mass.

If the kidneys are left in place, the exenteration of the stomach, pancreas, and liver is more difficult and demands more caution, especially if the animal has not been bled, because the field is obscured by blood and other impurities. Dissect away carefully the attachments of the right kidney to the suprarenal capsule and left branch of the pancreas, which lies deep down, covered by the branches of the mesenteric arteries; next the adrenals, then the fundus of the stomach from the crura of the diaphragm, the suspensory ligament of the spleen, the splenorenal ligament, the right coronary and lateral ligaments of the liver, the hepatic renal ligament, the vena cava, with the falciform ligament, the œsophagus, and the left lateral and coronary ligaments of the liver.

All these organs may be removed with the diaphragm, and, when there are adhesions to its posterior surface, this is the preferable method. The right lobe of the liver is first separated from the kidney; the pancreas, spleen, and stomach are worked loose from the spinal column; the posterior vena cava, the œsophagus, and the pulmonary attachments to the diaphragm are sectioned; the diaphragm is freed from the thoracic wall by a circular excision, and the whole mass removed together. Finally, the aorta and the venæ cavæ with their branches are dissected off the spinal column from the diaphragm to the pelvis.

EXENTERATION IN THE DORSAL POSITION.—The body may be kept on its back by tying the feet to rings in the wall or to posts or poles. The extremities remain attached to the body, of course, and the broad muscles of the chest are only to be sufficiently incised to permit the anterior extremities to spring out a little and give access to the chest. If during the postmortem the extremities are released too much, the body will fall to one side and make the exenteration more difficult.

A longitudinal median incision is first made, then a bilateral trans-

verse incision just posterior to the last ribs. The two left folds of the colon are drawn up over the right side of the body. The rectum is pulled out and spread over the left thigh and left ventral wall and the small intestine spread out over the region of the lower ribs. The ileum is found at its insertion into the cæcum; it is thicker than the rest of the small intestine. It is tied off and sectioned, remaining in the hand after its mesentery is severed close up to the intestine. In this way the whole of the right lateral small intestine is removed from the abdominal cavity and its mesentery left hanging by its root. When it passes into the duodenum between the two roots of the mesentery, doubly ligate and section. Doubly ligate and section the rectum at its entrance into the pelvis and again at its junction with the colon.

The pancreas and first part of the duodenum are dissected away from the colon as in the first method. The roots of the mesentery and both the branches going to the large intestine are sectioned close up and the large intestine is removed.

The stomach, spleen, etc., are removed as in the first method. Many operators prefer to excise the spleen and open the stomach along its greater curvature and the duodenum on its inferior surface, whereupon the pathway of the bile ducts may be determined and then the empty organs cut away.

In the dorsal position the thoracic organs may be ablated by drawing them down towards the abdominal cavity. An incision is made between the rings of the trachea, two fingers are inserted, the trachea is grasped firmly, and the larger vessels are sectioned at the thoracic inlet; the aorta is dissected away from the vertebræ and the posterior vena cava and œsophagus are sectioned. If it be desired to remove the thoracic viscera together with the trachea and cervical organs, the first rib is sawed through and excised; the cervical organs are then ablated according to the method to be described later.

VIENNA METHOD OF EXENTERATION IN THE LEFT LATERAL POSITION.—Csokor's quick method for removing the thoracic and abdominal contents is as follows: The extremities are removed and the abdominal cavity is exposed by a longitudinal and a transverse incision as in the first method; then the muscles of the back are cleared away and the sectioned abdominal wall is drawn up by a hook. With a hatchet each rib is cut away from the spinal column and then from the breast-bone. The whole right wall of the thorax and abdomen is now drawn up over the head of the animal and the contents of both cavities

are exposed. The right kidney is next removed and then the thoracic contents. After their ablation the cardiac end of the stomach is freed from the diaphragm and the duodenum is detached from the liver and its surroundings and excised together with the stomach and spleen. The abdominal aorta is separated from the spinal column, the rectum sectioned, and all the intestines removed. The remaining organs are extirpated as in the other methods. This modification permits a very rapid necropsy, but the removal of the stomach and spleen is somewhat difficult.

DISCUSSION OF THE ABDOMINAL CONTENTS.—To ascertain the macroscopic conditions of the abdominal contents it is necessary to make a few special incisions. The aorta is first examined and its dorsal wall slit up with the shears to expose the entrances into its branches, which are then cut open. On account of its great frequency, close search is to be made for an aneurism in the root of the mesentery. It is usually felt externally as a thick, cystic expansion. The branches to the small intestine—the duodenal, jejunal, and iliac arteries—are first given off from the short trunk of the artery lying in the root of the mesentery (the anterior mesenteric artery); next a large vessel, the ileocolic artery, which gives off a large branch, the inferior colic, and the ileocaecal artery with its three branches. The superior colic comes off above the root of the mesentery on a level with the anterior rectal artery. After examining these branches slit the inferior and superior colic arteries in the mesocolon from their origin to the sigmoid flexure. If it seems necessary, examine the arteries of the small intestine in the same way and observe the mesenteric lymph-nodes. The bowel is opened with the shears along the line of the attachment of the mesentery so as to get a good view of Peyer's patches; keep the intestine lying flat, for if held up the contents run down into the lower portions, and are then troublesome.

If the stomach is sufficiently full, cut it open with a knife along its greater curvature. If the duodenal portion remains with the stomach and liver, open it with the shears on its inferior surface in such a way that the termini of the hepatic and pancreatic ducts will not be injured and their patency may be demonstrated. Press and push along the course of the ducts so as to force out their contents. If there is any suspicion of abnormalities in these ducts, it is better to leave the stomach and duodenum in place and to open them before removal.

REMOVAL OF THE THORACIC CONTENTS.—First carefully examine

for sharp points of bone and excise them with cutting forceps. The pericardium should then be examined and worked free with the hands. The posterior vena cava is tied off and divided between the ligature and the diaphragm; the attachments of the liver and heart to the diaphragm are sectioned and an incision is made obliquely through the aorta down to the vertebral column. Thrust the finger into the posterior aorta, pull it up, and cut along the spinal column in the line of the vena azygos and the attachment of the longus colli. Now make an oblique section through the œsophagus, trachea, anterior aorta, and anterior vena cava along the line of the first rib, so that the thoracic organs may be removed. This avoids cutting the large veins, which bleed so freely as greatly to obstruct the view of the parts under observation.

SECTION OF THE ORAL CAVITY AND CERVICAL ORGANS.—This is begun by removing the ramus of the lower jaw on one side. Cut the buccal parietes and the cheek at the angle of the lips up to the zygomatic arch, between the molar teeth and the space between the lower jaw and the large maxillary swelling, dividing the masseter and sawing through the bones. The ramus of the jaw may now be worked up and down, its muscular connections severed by a knife introduced along its median surface, and an incision made between the parotid gland and the posterior border of the bone. The temporal muscle is cut through above the coronoid process and the ligaments and capsule of the joint are sectioned, the jaw being moved up and down to find the joint. After examining the local conditions, sever the left connections of the tongue with the jaw and the soft palate; saw through both to the large branches of the hyoid bone. The larynx, trachea, and œsophagus are easily freed from their loose cellular tissue by cutting into the channel of the external jugular vein, between the longus colli muscle and the œsophagus, so that the thyroid gland is not injured.

DISSECTION OF THE THORACIC AND CERVICAL ORGANS.—In order more closely to inspect these organs, cut through the vault of the velum palati with the shears and continue down into the œsophagus, sectioning it dorsally. With the knife grasped firmly incise the larynx in the median dorsal line between the arytenoids. Pushing the œsophagus aside, cut the posterior muscular ligament of the trachea with shears throughout its whole length and thrust the cartilages apart to get a good view of the interior. The lobes of the lungs are laid open with

long, deep, bisecting strokes, and portions of each lobe are tested by throwing them into water to see whether they contain air and will float or will sink because of collapse or the presence of an exudate. The lymph-nodules around the roots of the bronchi should always be examined and sectioned.

If the heart is hacked into or improperly opened, the distinctive appearance of any abnormality that may be present is destroyed, and these anomalies are of great importance to the whole organism. First make an incision into the right ventricle along the septum, insert the shears, and cut up into the pulmonalis. Holding the heart by this flap, lengthen the incisions towards the apex and the flap so as to get a better view of the ventricle. In the same way incise the left ventricle close to the septum and on the anterior surface; insert a finger through the opening, find the entrance into the aorta, and with the shears cut down between the pulmonalis and the left auricle. It is true that in this way both semilunar valves are sectioned, but the auriculoventricular valves are spared and they are much more likely to present abnormalities than the semilunar. The size of the openings can be tested by inserting a finger, and the thickness of the walls measured, after which each auricle is cut through up into its vessels and a good view of their openings obtained.

EXENTERATION OF THE PELVIS.—The removal of the pelvic organs is preceded by the previously described excision of the kidneys and ureters and in males by the exposure of the testicles and the external genitalia. The scrotum and penis were then turned back, and now their dorsal suspensory ligament and surroundings are divided as far as the ischiatic notch and all the flesh lying ventrad to the ischiatic suture is carefully cleaned away. The scrotum and the right and left inguinal canals are split open and the testicles together with the spermatic vessels pulled up into the abdomen. It is especially necessary to cut the tendinous ligament which binds the corpora cavernosa to the ischium close to the bone, as well as the strong ischiopenile muscle. Two sections made by sawing will remove the right wall of the pelvis. The first one is made through the ischiopubic suture over the acetabulum to the iliac spinal column; the second, through the thin part of the iliac bone, after cutting away the flesh that lies over the acetabulum on the iliac column. By cutting the bone loose from the pelvic cellular tissue, it is easily pulled away.

The lateral wall of the pelvis being removed and a good view of

the organs obtained, divide the connective tissue between the rectum and the superior pelvic wall; free the uterus and ovaries, the neck of the bladder, the vagina, and the accessory sexual glands; cut through the strong rectococcygei and the skin between the tail and the anus; and make a circular incision around the anus and the vulva (or the region of the penis). Remove the whole mass and section the organs dorsally.

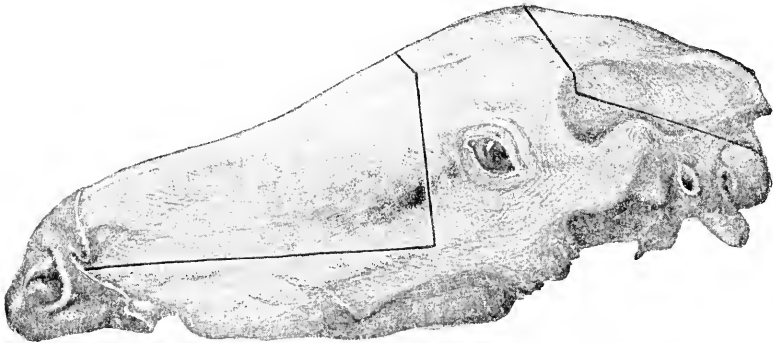


FIG. 192.—Lines to guide the saw in opening the cephalic cavities of a horse.

EXENTERATION OF THE CRANIAL CAVITY.—To remove the head from the trunk we may either cut around the joint as if the throat were being cut or puncture the capsule ventrally and amputate between the condyles and the atlas. It is best to remove the whole of the lower jaw and let the skull, wrapped in a cloth, rest on its base and the molar teeth; it may then be held much more steadily than if the inferior maxilla had been left in place. The cranial attachments of the cervical and temporal muscles are next cut away and the soft parts removed from the roof of the skull.

There are three lines for sectioning the cranium. The first lies transversely across the forehead about a thumb's breadth above the upper border of both superciliary ridges. The two other lines begin at the ends of the frontal incision, pass backward across the temples and petrous bones, and converge to the condyloid apophyses (Figs. 192 and 193). The first section can be made continuously, but the second and third will have to be done in several portions on account of the convexity of the cranium.

The walls of the cranial vault are not equally thick, and care must be taken not to penetrate too deeply into the middle of the parietal bones and the squamous portion of the temporal bones. The frontal

section passes through the frontal sinuses, so that there is very little danger here; and the same is true of the vertex and the pyramidal region above the condyles. The plates are not usually sawed clear through along the whole line, but the connections are broken with a chisel. Rest the palm of the hand upon the skull, grasp the chisel firmly near its edge so that it cannot enter too deeply, and tap gently with the hammer. When the bones are completely severed, pry the piece off by rocking the chisel backward and forward, first in the frontal and then in the condylar region. A sudden strong pull on the pericranium, grasping it at the edge of the frontal section, will generally separate it from the other parts of the head; sometimes the whole brain will come away at one jerk, together with the root of the skull.

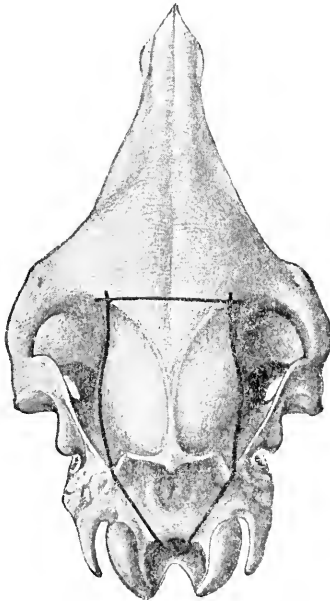


FIG. 193.—Lines of sawing for opening the cranial cavity of a horse.

If the dura is too closely held or is adherent to the inner table of the skull, with the shears incise it in the line of the section in such a manner that the dorsal portion will come away with the calvarium. Next excise the longitudinal and transverse blood-vessels in the duras. That part of the dura lying over the hemispheres is held up with forceps and cut with scissors so that it may be thrown back on both

sides. The tentorium is sectioned anteriorly and posteriorly and removed. The membranous transverse septum which is torn away from the falx is incised laterally and pulled out from the transverse fissure, due attention being paid to its vascularity.

DISSECTION OF THE BRAIN.—After examining the pia mater and the superficial surface of the brain, the hemispheres should be separated so as to expose the corpus callosum. The interior of the brain may either be examined now or after its removal. A horizontal incision is made immediately over the corpus callosum, starting at the median surface, and using preferably the so-called “brain-knife” or a long, flat scalpel. If the incision is not quite deep enough to enter the lateral ventricle, you will come first to the so-called “egg-shaped middle point” (*centrum semiovale Vieussenii*); press this gently with the finger and you will find a yielding point which, when incised, opens into the lateral ventricle. Follow the finger with the knife and slit open the roof anteriorly and posteriorly. Look for a collection of fluid, and examine the choroid plexus, corpora striata, horns of the ventricle, and median septum. This is seized in the middle, raised a little, sectioned transversely, and thrown back, the connections holding it to the peduncles being severed. Now carefully insert four fingers into the transverse fissure and raise the posterior lobes in order to expose the corpora quadrigemina, optic thalami, pineal gland, and middle choroid plexus. By separating the two thalami a little, you can divide the *commissura mollis* and see into the third ventricle.

To remove the brain, support the skull upon the incisors in such a position that the condyles look upward and the brain would fall out if it were free. Into the space thus obtained between the medulla and the base of the skull, insert a finger, the closed scissors, or the handle of a scalpel, and sever the nerves one by one as they appear. The olfactory bulbs, which are unusually large in comparison with those of man, are worked out from the ethmoidal depressions by a circular thrusting motion of the handle of the scalpel. When they are all separated, the brain will fall into the waiting hand, which must steady it constantly or the olfactory bulbs would be torn away by its falling out too soon.

After the brain is removed, the inferior surface is first examined; then, turning the brain over, the cerebellum is cut into halves. Expose the fourth ventricle and incise the floor longitudinally. With a thin-bladed knife cut radially to the cortex and transversely to the crura,

making numerous narrow incisions to detect the presence of any small hemorrhage or other lesion.

REMOVAL OF THE SPINAL CORD.—This requires much time and labor when properly done, but is managed in various ways. But little time is spent in routine work when you have a butcher to assist you. The animal is suspended and the vertebræ are split off from their bodies by a hatchet; when this is cleverly done, the line of cleavage being kept a little to one side, the cord is but slightly injured. It is better, however, to proceed as follows: Saw off the ribs at their angles, separate the ilium from the sacrum, and clean off all the flesh. Laying the spine upon the table, begin at the pelvis and chisel off the vertebral arches, remembering that two chisels are necessary, one for each side, as the two instruments have different curves (Fig. 38). If an ordinary chisel is used, the arches should be partially sawed through to make their division easier. The hand holding the chisel supports itself on the spine, and the chisel is held as flat as possible while an assistant grasps the spinous processes and springs the arch apart. You may also expose the spinal canal ventrally by sawing through the vertebral bodies and arches on one side only. Section the nerves at their points of exit laterally to the intervertebral ganglia and lift out the cord enclosed in its membranes. Cut open the dura with the scissors and section the cord transversely with a sharp, thin knife.

EXPOSURE OF THE ACCESSORY SINUSES.—To expose the nasal fossæ saw the head in two, after removing the brain, a little to one side of the median line so as not to injure the septum on either side. These fossæ may be sectioned transversely or their walls chiselled away to show the accessory sinuses. Csokor saws through the osseous structure of the nose transversely from the level of the malar or lachrymal bone to the roots of the molars; a section is then made horizontally beginning at the anterior nares and joining at the first section (Fig. 192). On raising this cap you have the maxillary, nasal, and frontal fossæ well exposed.

One or two long bones should be sawed through to judge of the condition of the bone marrow.

POSTMORTEMS ON RUMINANTS.—There are certain peculiarities in the skulls of ruminants which must be remembered when exposing the cranial cavity. It is only in very young animals that the cranial bones possess diploë, and in necropsies on hornless cattle the incisions are the same as for horses. On account of the prominent crests, which fall away very abruptly, and because a calf's head is somewhat rounder,

the sawing will have to be done in more numerous segments, and great pains must be taken on account of the thinness of the bones. The older the animal, the larger are the hollow places between the internal and external plates; the diploë disappears and only a few crusts and plates

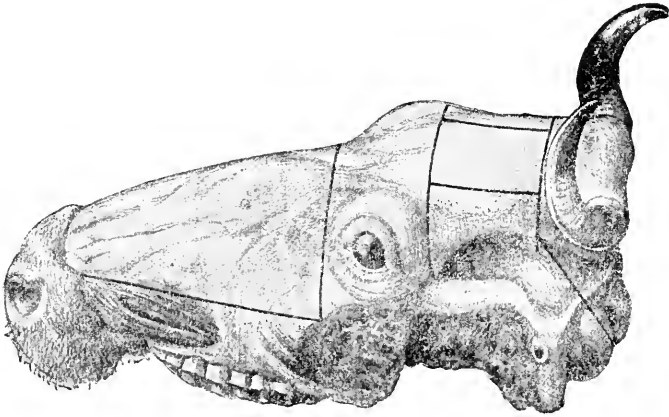


FIG. 194.—Lines used in sawing in order to expose the cranial and nasal cavities in a ruminant.

of bone interrupt the hollow spaces. The lateral and posterior portions of the skull are very prominent because of two large crests. The transverse section is nearly coincident with the posterior border of the

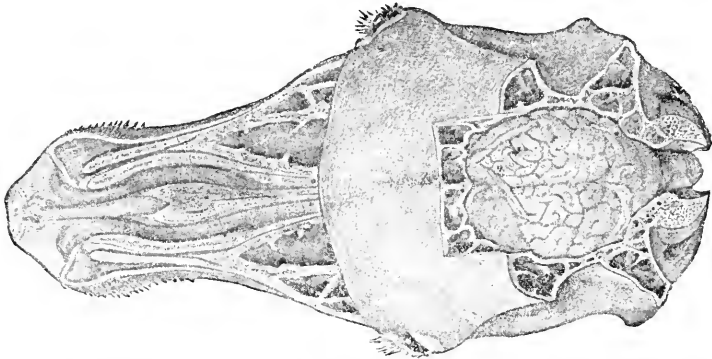


FIG. 195.—Appearance of cranial cavity of a cow after removal of the bony vault.

superciliary ridges. The lateral sections are made in two segments, beginning at the ends of the transverse frontal incision and passing back over the temples to the foramen magnum. Clement has devised a better method (Figs. 194 and 195). First clear away all that part of the calvarium formed by the frontal eminence and the lateral depressions by sawing through the skull in a line passing from just in

front of the horns obliquely backward and downward to the condyles or foramen magnum. After removing this plate of bone the whole of the posterior portion of the brain is exposed. Next make a transverse

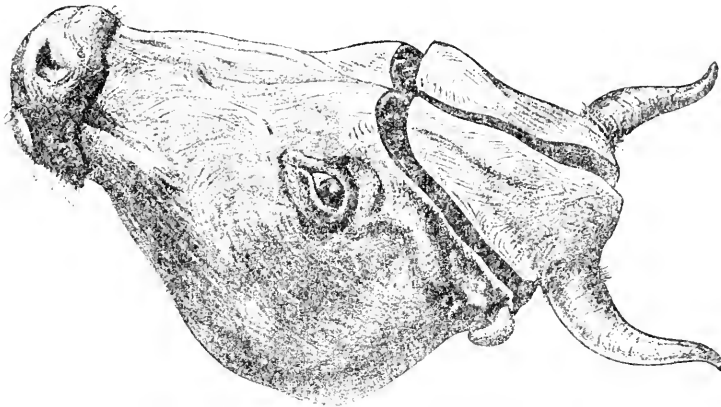


FIG. 196.—Second method, showing the lines of sawing in the removal of the brain of cattle.

incision on a level with the superciliary ridges across the anterior end of the cranial cavity. Finally make two short longitudinal incisions, one on each side, about three centimetres from the median line; with

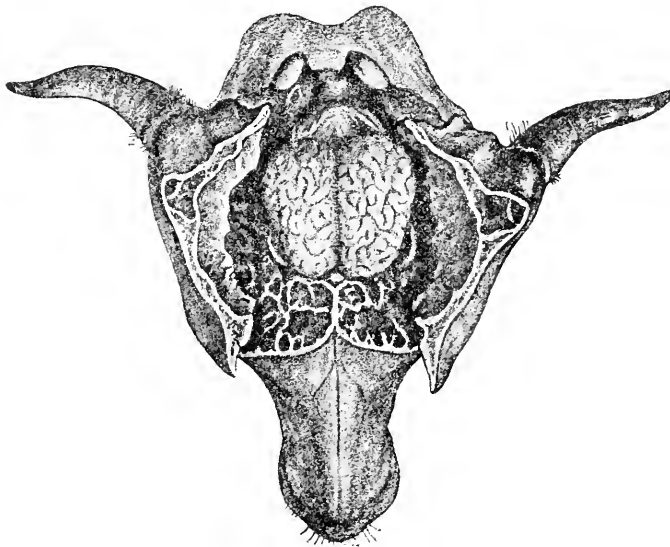


FIG. 197.—Second method of opening the cranial cavity in cattle.

mallet and chisel remove the oblong piece enclosed, and the whole brain is exposed. The curved horns of a sheep or a goat serve as

convenient handles for removing the calvarium and may very well be left on, while the horns of neat cattle should be knocked off.

Another method for the removal of the brain in ruminants is that of Martin. The lines for sawing are well seen in Fig. 196. Care must be taken in the sawing that the brain is not injured. After the sawing is completed, the horns are hit apart with an axe, and the brain is exposed as in Fig. 197.

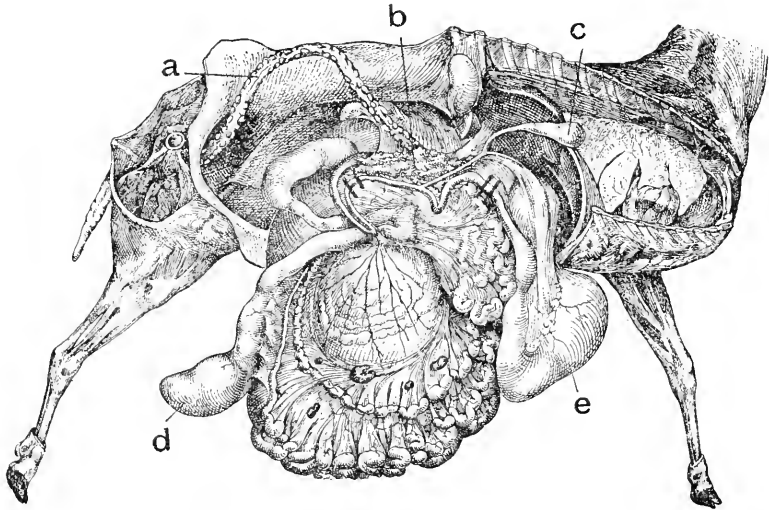


FIG. 198.—Post-mortem examination of a sheep. *a*, rectum; *b*, pancreas; *c*, gall-bladder; *d*, cæcum; *e*, abomasum (fourth or principal ruminant stomach).

POSTMORTEMS ON SWINE.—With the body lying on its left side, the right extremities are removed, the abdomen is exposed by longitudinal and transverse incisions, the diaphragm observed, and the lateral thoracic wall divided by cutting with the bone-shears or sawing through the angles of the ribs and severing the cartilages close to the sternum. To remove the abdominal contents, first find where the duodenum is attached to the rectum; sever the duodenorectal ligament, separate the pancreas from the mesentery, and section the duodenum. The anterior root of the mesentery is loosened by working it free with the hand and pulling on it, then sectioned, the whole of the mesentery excised from before backward, and the rectum divided. Now cut away the spleen from the stomach, examine the opening of the bile duct, section it and the œsophagus, and separate the stomach from the diaphragm, leaving the liver freed from its suspensory ligament. The thoracic and cervical organs are removed as with other animals.

In old quadrupeds the brain lies very deep, because of the immense air-spaces in the cranial bones which surround the brain on all sides except the temporal region. The transverse section is made a full thumb's breadth above the superciliary ridges (the eyes being first removed) and the lateral sections run back to the occipital foramen.

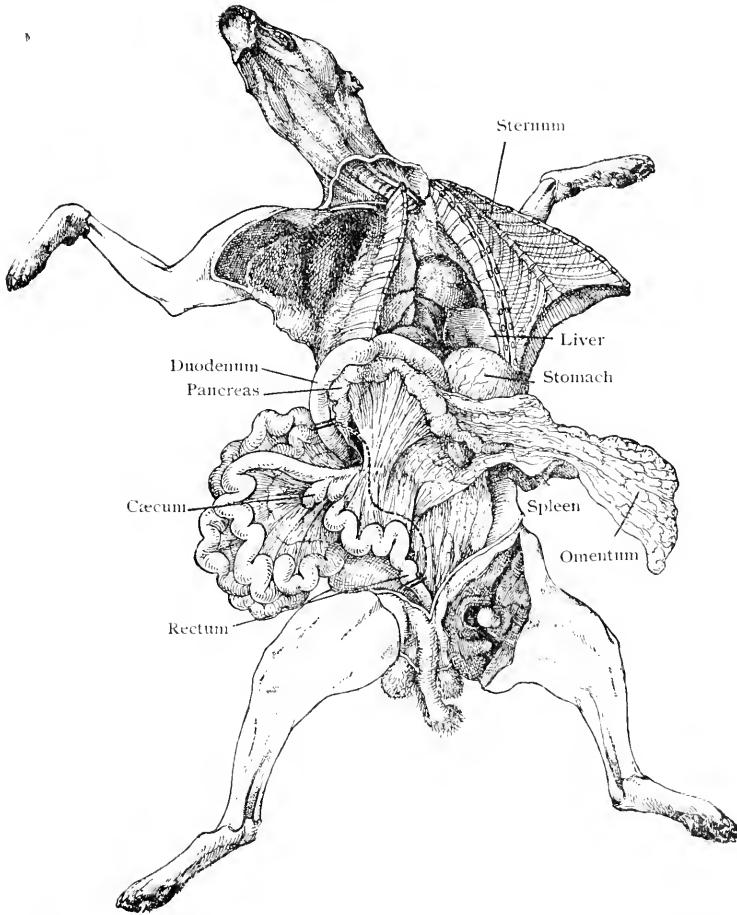


FIG. 199.—Postmortem of the dog. Double lines show places at which the intestines are to be tied; the dotted line indicates the direction for incising the mesentery.

Instead of a transverse section we may make two oblique ones, beginning at the posterior border of the frontal process and joining each other and the lateral incisions in the anterior frontal region.

POSTMORTEMS ON DOGS, CATS, AND SHEEP.—The necropsy of a dog is easily made in either the dorsal or the left lateral position.

The procedure is the same as for the horse, but it is not necessary to remove the extremities entirely or to take off the hide; simply cut through the muscles enough to allow the limbs to fall away a little and the body will be sufficiently steady. (Figs. 199 and 200.) The thickening at the junction of the cartilages with the ribs is easily felt, the articulations are cut, and the sternum is pushed upward and for-

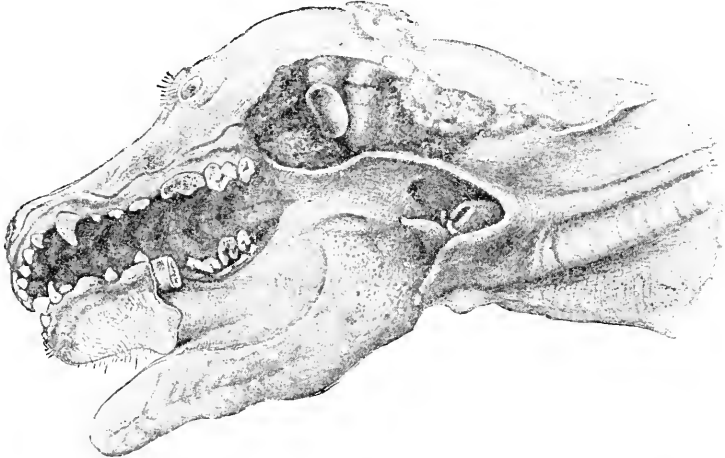


FIG. 200.—The left ramus of the mandible has been removed and the tongue pulled outward and downward, thus exposing the oral and pharyngeal cavities in a dog.

ward after freeing the pericardium and the pleura. Section the tracheal vessels and œsophagus at their entrance into the thorax and remove the thoracic organs.

The removal of the abdominal contents of a dog is easy. Divide the rectum at the pelvis and the two mesenteric roots, and the abdominal aorta and inferior vena cava behind the liver; thrust the hand in between the liver and the diaphragm, and with scissors section the suspensory ligament of the liver, the vena cava, and the œsophagus after it is pulled down from the diaphragm and tied off or compressed with the fingers. All the abdominal contents may now be removed together. Spread them out, examine each again, test the patency of the bile ducts, and straighten out the bowels. It is, however, better first to remove the intestine, which is sectioned through the duodenum at the pancreas and through the rectum at the pelvis. Next either remove the liver with the stomach or after inspecting the bile ducts cut away the stomach from the œsophagus and duodenum and then remove the liver.

To expose the cranial cavity we have the same three lines as usual, the transverse section lying directly posterior to the rudimentary superciliary ridge, crossing the frontal sinuses and the anterior lobes of the brain. The anterior temporal and the parietal bones are not thick and contain diploë, so that the sawing must be carefully done. Since the petrous portion of the temporal bone has deep impressions upon its internal surface, in which convolutions of the cerebellum lie, and since the bony processes project from the adjacent bones, great care must be taken not to tear the cerebellum. In small dogs with round heads the line for sectioning is more nearly a circular one.

The postmortem of a cat is made in the same way. I have seen diphtheria, tuberculosis, *Trichina spiralis*, and possibly scarlatina in the cat.

The postmortem in the case of sheep is seen pictured in Fig. 198.

POST-MORTEM EXAMINATION OF BIRDS.—Plug up the nostrils, mouth, and vent with cotton; make an incision from the point of the breast-bone, or a little above, backward to and through the anterior portion of the anus, leaving the uropygium (pope's nose). Loosen each leg to the knee (above the femur) by tearing the soft parts with your thumb and fingers, then cut with a knife until they meet around the pelvis at the rump. With your thumb-nail work the wings loose, hold the skin firmly, and, pressing your nail towards the body, cut off the wings at the elbow. To get at the brain make a V-shaped slit with its apex towards the median line at the foramen magnum, running up towards the centre of the skull; the brain is then removed attached to the cord, and the skin is kept whole for taxidermic preservation. The "wish-bone" of birds is the joined clavicles.

POST-MORTEM RECORDS.—Kitt suggests the following scheme for the more intelligible recording of the findings in postmortems on the lower animals.

RECORD OF NECROPSY.

Species	Sex	Age	Color of hair	Owner
Clinical history		Treatment	Mode of death	Date of death
Necropsy performed by			Where performed	Date
Order of			Persons present	

A.—EXTERNAL EXAMINATION.

- Position of the cadaver (on back, right or left side, hanging)
- Nutritional condition (weight)
- Removal or absence of parts
- Rigor mortis

Condition of the skin and its appendages (the skin around the head, trunk, and extremities; the horns, claws, hoofs, ears, scrotum, prepuce, udder)

The natural body openings and visible mucous membranes (the discharge of foam, fluids, and excrements; the color of the lips, nasal mucous membranes, conjunctivæ, anal and vaginal mucosæ)

B.—INTERNAL EXAMINATION.

Facts obtained in removing the hide

Condition of subcutaneous tissues, fat, lymph-nodules, vessels, extravasated blood, muscles, ligaments, tendons, fascia, joints, and bones

Abdominal and thoracic data

Condition of diaphragm, position of organs, appearance of peritoneum, mediastinal and costal pleuræ, and pericardium

The oral cavity, tongue, teeth, soft and hard palate, salivary glands, pharynx, Eustachian tubes, œsophagus, retropharyngeal and laryngeal lymph-nodules

The larynx, trachea, thyroid, and surroundings

The lungs, bronchi, bronchial lymph-nodes

The pericardial sac, heart, and thoracic vessels

The liver and bile ducts, portal vein, and periportal lymph-nodules

The spleen (capsule, pulp, trabeculæ, Malpighian bodies, and vessels)

The stomach and crop

The pancreas; the large and small intestines

The mesentery, omentum, posterior aorta and its branches, and vena cava

The kidneys, adrenals, ureters, capsule and pelvis of the kidney, and its half section

The urinary bladder, urethra, and accessory sexual glands

The pelvic portion of the rectum

The genitalia: uterus, vagina (pregnancy, fetal membranes, embryo); or the male genitals

The cranial cavity and the brain: calvarium, sinuses, cavities at the base of the skull, dura, cerebral superficies, ventricles, gray and white matter

The eyes; the middle and internal ears

The fourth ventricle and the spinal cord with its membranes

The nasal fossæ and accessory sinuses

The udder and supramammary lymphatic nodules

The bone marrow

Microscopic and chemic report

INSPECTION OF SPECIAL ORGANS.—The essentials for diagnosis which are to be looked for and recorded are about as follows: 1. Name of the organ; from what animal; whether it died or was killed; whether the organ was entire or fragmented; whether parts, lobes, etc., have been amputated; and if there are any adhesions to adjacent parts. 2. Weight. 3. Length and breadth of the part. In the absence of a tape measure we may ascertain these dimensions approximately by comparison with the breadth of the hand and the length of the finger. Every person should know the length of his index-finger, which is usually about ten centimetres and may be used to measure

organs, pathologic spots, streaks, canals, etc. 4. Surfaces: whether smooth, even, wavy, granular, corrugated, rough, transparent, or cloudy. Color of the surface: general and primary color, special deviations and shades. The external contour of the organ and any prominences, with especial reference to their size as compared with grains of sand, millet-seeds, lentils, peas, beans, hazel-nuts (or filberts), a pigeon's, a hen's, or a goose's egg, the fist, the thickness of a child's arm, a child's head, etc. (Plate II.) 5. The consistence as determined by palpation: soft, elastic (like the lungs), doughy, splenified, hepatized, tough, inelastic, carnified, indurated, leathery, like the kidneys and skin, as hard as wood, cartilage, bone, or stone. 6. Sectioning of special parts: through the compact, so-called parenchymatous organs (muscles, liver, kidneys, lungs) large dissecting incisions are made. Through the brain and heart sections must be made in a certain way in order properly to expose certain cavities. On sectioning notice the resistance of the tissue, whether it cuts easily or is tough and pulls, whether the knife creaks as it goes through, whether the tissue is so hard that a saw is necessary, and observe if any fluid follows the section or if there are any abnormal contents. The surfaces of the section must be noted, their color, thickness, consistence, fluidity, and vascularity, as well as any other peculiarities which may be present. The pathologic diagnosis is made by considering the details gained in this way, which lead to one conclusion and exclude another. A gross anatomic diagnosis is often only provisional and dependent upon microscopic and chemic confirmation.

CHAPTER XXVI

PLANT PATHOLOGY ¹

WHILE the Bible and earlier writers describe many diseases of plants, such as wheat rust, fig blight, and insect galls, plant pathology and the scientific treatment of parasitic diseases may be said to date from the beginning of the nineteenth century. The rapid spread of the potato bug (1859) in this country and the downy grape mildew in Europe (1878), directed attention anew to this subject. Millardet's Bordeaux mixture of copper was the cure found for the rust and Paris green for the potato bug. The San José scale imported from China, where it is said to have a natural enemy, has spread from the Pacific to the Atlantic, while the asparagus rust has extended in the opposite direction.

The life history of plants is identical in many of its phases with that of animals, but vegetable morphology is easier of interpretation than that of animal structures. As bacteria are regarded as vegetable organisms, bacteriology is properly a branch of plant pathology. Plants are subject to some diseases that closely resemble maladies occurring in man, some of which appear to yield to similar treatment; thus, chlorosis of plants, like certain microscopic diseases of apples and pears, is best treated by burying scraps of iron near the parent root. The influence of heredity and natural selection is well marked in plants. The younger Darwin has recently endeavored to demonstrate natural selection in inanimate matter (rocks), and the ultimate result of these studies will doubtless add much to our knowledge of pathology.

The growth and evolution of plants are modified by climatic conditions, temperature, humidity, and diathermancy of the air. Sudden changes of temperature, protracted heat or wet, and excessive or deficient precipitation not only affect the normal growth of plants, but may cause disease either directly by action on the plant itself or indi-

¹ For literature, see section of "Vegetable Pathology" in the current numbers of the *Index Medicus* and in the forth-coming volume of the second series of the *Index Catalogue*; SMITH'S *Bacteria in Relation to Plant Disease*, no. 27 of the Carnegie Ins. Wash. Publ., 1905; and STEVENS, *Science of Plant Pathology*, *Pop. Sci. Monthly*, 1905, vol. lxxvii, p. 399.

rectly on the soil. Judicious transplantation may save an ailing plant, or ill-advised change of soil or climate may cause a hearty one to perish. Transplantation also favors the extension of diseases. Unhealthy soil is also a fruitful source of disease. In the presence of bacteria *Leguminosæ* are capable of utilizing the free nitrogen of the air by building it up into organic compounds.¹ It would seem that possibly some of the newer elements of the air, which are present in small quantities, may be needed for this reaction, and that the gas itself is not used up, acting as a catalyte; just as, theoretically, a small amount of sulphuric acid can convert a large quantity of starch into glucose.

The analogies presented both in health and disease between plants and animals—the borderland between which is growing each year more and more difficult to define—offer a most promising field for scientific investigation. Among the many interesting subjects for study in the field of plant pathology may be mentioned trauma, mechanical and produced through the agency of insects, etc.; the effect of anæsthetics upon plants; the influence of colored light upon the growth and development; heredity, as shown by the experiments of Mendel and Burbank; the dissemination of diseases by insects and parasites; the study of plant diseases, as ergot and galls, for discovering remedial agents; the killing of adherent spores of disease by formaldehyd gas and other disinfectants without preventing subsequent germination; the analogy of plants affected by bacteria with animals affected by animal parasites; the comparative action of bacteria upon wild and cultivated plants, as in the case of ginseng; the mutation of species as studied by de Vries; an investigation of cabbage club-foot, an infection analogous in so many ways to cancer that it is supposed by some to be identical; and the study of organisms similar to the *Corynebacterium tuberculosis* and the colon bacillus, found upon grass.

¹ *Science*, October 27, 1905, p. 527.

CHAPTER XXVII

THE TEACHING OF POST-MORTEM TECHNIC AND THE INTERPRETATIONS TO BE DRAWN FROM THE MATERIAL SO OBTAINED

IN the ideal teaching of post-mortem technic there should be a well-equipped autopsy room, an abundance of material,¹ and a small class (not more than fifteen) of students well trained in anatomy, including histology and embryology, physiology, and physical diagnosis. The teacher should be one who is experienced in the practice of medicine, and in gross pathology, so that he is capable of drawing correct interpretations from the parts under consideration. The physical signs elicited during life should be explained by the pathologic lesions found,—*e.g.*, cavities present in the lung, lobar pneumonia, pleurisy, carcinoma of the stomach, typhoid ulcers, cirrhosis of the liver, gastroptosis, etc., may well be used to impress on the mind of the student not only their morbid appearances, but also lessons in diagnosis, symptomatology, and treatment. The student would thus gain more and would certainly be more interested in autopsies than in any other way by easily associating in his mind pathologic conditions with the physical signs and symptoms to which they ordinarily give rise. When practicable, the disease should have been studied during life by the student under the guidance of a competent physician or surgeon. The teacher should never forget to contrast the normal tissues with the abnormal. The material for postmortems should not be drawn from one source, but from many. In my experience I have found an entirely different set of pathologic pictures in the different hospitals of Philadelphia; for example, in the Presbyterian or University Hospitals, where a large number of pay patients are treated, the frequency and the character of certain pathologic lesions are not the same as those seen in the Municipal Hospital, where contagious diseases are treated, and Blockley, where the scum of the earth die. In the Coroner's work the material is markedly different from that found, for example, in an insane asylum or the Institution for Feeble-Minded Children at Elwyn. Again, the

¹In case bodies are not to be had, animals can always be secured. Indeed, there is a wider field for investigation in animals to-day than in the human body.

Pennsylvania Hospital, with its large number of foreign-born patients, will show marked differences in the character of its autopsies to those made at the Woman's Hospital, the West Philadelphia Hospital for Women, or the Children's Hospital.

To cover the ground of post-mortem technic in our medical colleges no less than ten hours of demonstration are needed by the one in charge and no less than six complete postmortems should be made by the student, and there is no end to the number of postmortems that can be seen with benefit by the student, especially if he has had an opportunity of following the fatal illness or of having seen the patient some time previously during life. In the teaching of autopsies to me the most striking feature is the lack of anatomic knowledge of a practical nature. Thus, many students after passing their examination in anatomy are unable to tell the difference between a kidney and a spleen, though they will talk most learnedly about the Malpighian bodies and the loops of Henle.¹ The greatest place in the world for following the patient throughout the entire course of the disease is in Vienna, and it is for this reason that each year so many Americans go abroad. There, for example, Gohn will, with his assistants, in the morning make the autopsies, which are free to all, and in the afternoon demonstrate the specimens to a private class of twenty at a gulden apiece. The interval has afforded him sufficient time to prepare frozen sections and also gives him an opportunity of regulating his course so that the entire subject of gross morbid anatomy will be fairly well covered in the course of fifteen or twenty demonstrations; and it is surprising how frequently the autopsies run in certain directions; thus, one day the autopsies may reveal various examples of liver disease, while at another time, there may be a predominance of gastric lesions. In a separate but adjoining room Kolisko will be found to be investigating the cause of death in medicolegal cases, one of the most important and exacting departments of post-mortem examinations and one too frequently not touched upon by the autopsist owing to lack of familiarity with this subject.

¹ See article by the writer in *Medical News*, 1898, vol. lxiii, p. 262.

CHAPTER XXVIII

MEDICOLEGAL SUGGESTIONS

ALTHOUGH a physician is not expected to have a profound knowledge of legal matters pertaining to his profession, yet every doctor should be more or less familiar with the medical laws of the State or country in which he is practising. He should be well acquainted with the regulations of the Board of Health, of the Coroner's office, and of the criminal courts, and do all in his power to aid in their rigid enforcement. A synopsis of such laws and regulations is usually readily obtainable in book form, and nearly every physician has among his patients or friends a lawyer who is glad to discuss legal questions in return for medical information. Some of the salient points relating to medicolegal investigations and autopsies will here be briefly considered, though many references to these matters will be found elsewhere throughout this work, especially in Chapter XXIX.

OBLIGATIONS OF PHYSICIANS TO THEIR PATIENTS.—The obligation of a physician to society in the practice of medicine is in a certain sense voluntary. His is the right to refuse any and all cases that may apply to him for treatment or advice. Services once begun, however, he must, after giving notice of his intention to discontinue them, allow his patient reasonable time to fill his place, as otherwise he renders himself liable for damages. This obligation is equally binding in the case of charity patients. Contracts between a physician and a patient may be either express or implied. An express contract is where services are rendered in accordance with a definite agreement previously entered into between the parties. There is the promise of proper treatment in an implied contract just as there is the promise of payment. Generally, however, the contract is implied by the law from the fact of employment and consequent attendance. Both forms of contract are equally binding, and both are subject to public policy. Contracts making the payment contingent upon successful treatment are valid, but, should the patient fail to follow the doctor's directions or to give him sufficient opportunity for treatment, the Court would probably allow the latter reasonable compensation. If the physician fail to exercise ordinary skill, he renders himself liable for malpractice.

In law malpractice consists in the failure to possess or use such ordinary knowledge or skill as is generally possessed and used by physicians and surgeons in similar localities, whereby injury accrues to the patient. The term is also applied to acts which are expressly forbidden by statute. The average physician is not obligated to exercise the highest expert skill nor is his implied contract one binding him to effect a cure; he must simply treat the case with reasonable skill, diligence, and faithfulness. That done, he cannot be held accountable for results. Births, deaths (with their probable cause), and infectious diseases are to be reported to the proper authorities for registration. In hiring a wet-nurse for a syphilitic child the woman must be informed of the fact that the infant is specifically infected and of the risk that she runs in taking it to nurse. It is a criminal offence to practise medicine or surgery while intoxicated.

The obligations of a patient to his physician, in so far as they relate to the treatment given, are more or less vague. They cannot be exactly defined. The patient should conform to the directions given him, but no legal liability arises if he does not: the risk is his. If in such circumstances the attending physician is of the opinion that his advice is being disregarded, to the detriment of his patient and perhaps of his own reputation, he is always at liberty to withdraw from the case and to request that another physician be called in.

As to the physician's compensation, it may be stated that in the absence of a special contract the measure of the liability of the patient to his physician is the customary charge made by others of equal standing for similar services. The question of compensation is a broad one and its full treatment is beyond the scope of this work. It may be remarked, however, that the specialist should protect himself by an express contract. Physicians should also be careful to have their accounts so kept as to be able to use them as evidence if dispute should arise. Much trouble and loss are frequently caused by neglect in the entries made by physicians in their books. In the case of *Laffin vs. Billington*, the Appellate Term of the Supreme Court of New York held that a contract by a physician to give expert testimony for the plaintiff in a personal-injury case and to receive as his pay therefor a percentage of any amount realized is invalid.

EXPERT TESTIMONY.—No Court can compel a physician to give expert testimony, to make autopsies, or to conduct laboratory investigations without his consent, but any knowledge which the doctor may

possess pertaining to an individual criminal case must be given to the Court in the same manner as if he were a lay witness. His scientific training is, however, his own personal property, the result of many years' study, careful research, and expenditure of money, and he is entitled to commensurate remuneration for the use of his knowledge as an expert. For the good of society, any facts pertaining to a given criminal case which are known to him should be freely and willingly given to the Court, though he thereby may be put to considerable loss of time and money. The expert should be cautious in expressing opinions before the case is called for trial. (Wormley.) Thus, in the Williams case, tried in Philadelphia in 1903, I was asked by the District Attorney while on the witness stand if I had ever expressed to the attorney for the defence an opinion as to the cause of death, and, if so, what that opinion was. The recent (1905) health census of New York City raises some interesting questions as to the power of compelling persons to answer certain questions for mere statistic purposes.

That the Court can compel a physician to divulge professional secrets is an undecided point. In some States and countries such confidences of the patient are held sacred, as are the relations between legal counsel and client; while in other places (wrongly, we believe, in civil cases, but rightly in first-degree criminal cases) they must be divulged to the Court should questions pertaining to the same be asked the physician while on the witness stand. The matter is one for the Court to decide, and such decision, being given, absolves the witness. Whether the prescription of a physician is a privileged communication or not is a matter of much debate, the weight of opinion, probably, being that it is not.

An expert is one who by reason of his peculiar experience, special study and training, or the performance of certain duties, is competent to ascertain particular facts of a technical nature or to form an opinion or judgment upon them, such as could not be expected from the judge or jury. No ordinary witness is permitted to express an opinion upon the facts as presented to him, as this is supposed to be the province of the members of the jury. Thus, in one of my cases, where infanticide was suspected, an iceman had found the dead body of a baby in an ash-barrel, and the Judge would not permit the finder to act as an expert in giving the approximate weight of the child, though it would seem that, on account of his frequent weighing of ice, he would be more fitted to give a correct estimate of the weight than many other

persons. The weight of the child (nine pounds) was desired as evidence that it was born at or near full term.

The jury is required to arrive at a decision upon the points at issue from the facts proved before it, and hence must necessarily base its verdict thereon. Where, however, there arise in the case technical issues, matters involving special knowledge, regarding which persons in general are not qualified to reach a correct judgment, and where, therefore, the opinion of those versed in such knowledge is necessary to the formation of a proper verdict, experts are called to testify. In so doing they must frequently give their judgment upon matters often presented to them in the form of hypothetical questions. Such questions are presumed to be framed from the testimony already accepted in the case. Great care should then be exercised in testifying, especially as sometimes the ingenuity of counsel is used so to formulate the hypothetical question as to confuse the issues in the mind of the jury or to elicit from the witness an opinion contrary to his true interpretation of the statements.

A medical man should refuse to testify as an expert unless he is thoroughly qualified for that duty. In no case should he go on the witness stand without being as fully informed as is possible on the subjects on which he is to be examined, nor should he allow himself to be questioned on subjects on which he is not prepared. He should be honest and candid with those securing his services before the trial, and, no matter what may be the consequences, his answers while on the witness stand must be made with absolute impartiality. Upon a suit for damages an expert may be held responsible for errors which he may have committed in the performance of his work. Thus, a chemist passing glucose as free from arsenic might have to pay damages should beer be made out of the glucose and arsenical poisoning result therefrom.

The medical expert should at all times confine himself to purely medical topics and never become involved with matters that will place him in the light of a lay witness, of a detective, or of an attorney, and he should carefully avoid acting as a champion of the parties who are paying for his services and of attempting to plead one side of the case. His language should be as free as possible from technicalities and be such as can readily be followed by the least educated of the twelve jurymen, many of whom are only too often, unfortunately, unfit for the performance of their duties. Some judges carry this plainness

of language to an extreme. Thus, while acting as an expert in a murder trial, the writer was once requested by the Judge not to use the word "hemorrhage" in testifying, as this term was too technical for the jury to understand. I at once substituted "bleeding" for the objectionable word and proceeded with my testimony. A well-known medical expert on being once criticised by the Judge for being too technical in his statement of, "I incised the abdomen and the intestines protruded," immediately changed it to, "I ripped open the belly and the guts fell out." When not absolutely certain of a point unhesitatingly acknowledge the fact; thereby harm and the possible jeopardizing of a human life may be avoided. But when sure of your ground undeviatingly adhere to it. At the close of testimony, especially if long and exacting, an opportunity is almost always given to correct any misstatements which may have been inadvertently made, and to make clear the meaning of any dubious points of the original testimony which may have been clouded by the cross-examination conducted by the opposing counsel.

Often too much is expected from the expert, as the following instance shows: While testifying as an expert in a country town on a case where the postmortem revealed beneath the left eye a small incision closed with two stitches, ecchymoses about the eyeball, and a fracture of the skull, the District Attorney and the Judge criticised me severely because I would only state that the man had died from hemorrhage of the brain due to fracture of the skull. They desired me to say that the man had been knocked down with the fist of a person who had a ring upon his ring-finger, and that in this manner the cut and the fracture had been produced. I admitted that they could have been made in that way, but would not declare, apparently much to their disappointment, that they were so caused.

MEDICOLEGAL POSTMORTEMS.—The objects of a medicolegal post-mortem include the finding out of the cause and mode of death, the establishment of a *corpus delicti*, the determination as to whether a crime has been committed, and if so the discovery of a motive therefor and the exact nature of the process employed therein. In such legal investigations the pathologist should protect his reputation in every possible manner, and he ought to hesitate to make a postmortem without the presence of a witness, who should, if practicable, be a professional brother. For ascertaining the cause of death a line of inquiry should be mapped out based upon a hypothetical or tentative diagnosis

suggested by the clinical history or special circumstances of the case. This may subsequently be corrected, modified, or abandoned as the autopsy proceeds, but the final diagnosis should, of course, not be made until the autopsy has been completed and any material requiring subsequent investigation reported upon by those undertaking this part of the work. The autopsic findings should be dictated at once to an amanuensis, and the record verified and signed upon its completion.

The obducent should have an opportunity to view and examine the body before it is taken away from the place or position in which it is found, and especially before the clothes are removed. He should prior to the autopsy be put in possession of information as to the general, and also any special, circumstances of the case, and more particularly in regard to any injury or violence which the deceased may have received. He should also be advised as to any known disease or other condition which may have contributed to the death. No one ought to be allowed to witness the examination out of mere curiosity or unless specially authorized. The examination should not be commenced unless there is sufficient daylight in prospect to allow of the whole inspection being made without artificial light. All measurements should be accurately determined. Examine carefully the contents of the stomach to ascertain the length of time which has elapsed since the death occurred. Where the services of the obducent are called in by the law, he is freed from the necessity which exists in ordinary cases of obtaining the consent of the relatives of the decedent. One making a medicolegal autopsy is like a scout in the enemy's country: he never knows how and when he is going to get caught.

In general the medicolegal post-mortem examination does not differ materially from the pathologic, except that in the former greater precautions are necessary in order to avoid sources of error or confusion, and that the cranial contents are examined before opening the large blood-vessels, as signs of congestion disappear after the severance of the aorta and *venæ cavæ*. Doubly ligaturing the *œsophagus* at the left of the trachea is a good routine practice, and it should always be done in cases of suspected poisoning. The urine collected from a cadaver is practically always albuminous. The importance of always examining the *vertebræ* cannot be too strongly insisted upon, as severe injuries thereof may exhibit no external signs of violence, while there may be other lesions found on the body which might otherwise be erroneously assigned as the cause of death. In some

cases after a most rigid and painstaking inspection no cause of death can be ascertained, but with care and systematic examination oversights, inaccuracies, and mistakes will be reduced to a minimum.

In case of suspected poisoning the primæ viæ should be tied at each end and removed. Double ligatures should then be applied at the junction of the duodenum and the ileum and at the end of the small intestine, dividing the viscera into three portions. The contents of the stomach and those of the intestines should be emptied into separate jars. Many poisons are extremely volatile and unless great care is exercised traces of them may be lost and justice defeated.

Each organ should be received in a separate receptacle, and each receptacle should be marked, sealed, dated, and deposited where tampering with it would be impossible. The mouth of the receptacle should be so large that no injury will be done to the organ during its introduction. It is also well to remember that a tissue, owing to its fresh state, goes into a bottle more readily than it comes out, because of its being hardened by the preservative fluid.

The form of report used by the writer in medicolegal cases is as follows: "I made a post-mortem examination of the body of Walter Foster on April 10, 1898, at St. Agnes Hospital, Philadelphia. The body was identified by George Bell, 636 Siegel Street, and Michael A. Bruder, 1847 Sartain Street, both of Philadelphia. I find that death was caused by shock and hemorrhage from stab-wound of the heart."

While acting as Coroner's physician I rarely volunteered more than this information, but waited for the District Attorney to ask questions in regard to the nature of the wound and as to other facts of interest. By this method the jury is not confused by an enormous amount of irrelevant testimony, though the expert must be prepared to give, under cross-examination by counsel for the defence, the minutest details as to how the postmortem was performed.

It may be remarked that there is a growing tendency to perfect and render more scientific the proceedings incident to and growing out of violent deaths. Courts have at times appointed a commission of physicians to examine into the physical condition of the plaintiff in personal injury cases. It has been suggested that in postmortems involving the question of crime the investigation should be carried on jointly by experts representing the State and the defendant; also that the question as to the cause of death shall be dissociated from that of the guilt or innocence of any particular individual and determined

by a jury or commission of experts: but this brings us into the realm of speculation. We do not now confront such conditions.

AUTOPSIES ON INFANTS.—The first question to determine in the examination of a babe is: was it born alive? If so, was it a full-term or a premature birth? If born dead, how many months of uterine gestation caused it to reach its present development, and after attaining its maximum growth was it carried as a foreign body in the uterus?

DETERMINATION OF THE VIABILITY OF A CHILD FROM THE POST-MORTEM APPEARANCES.—The reader is advised carefully to read Paragraphs 23 and 24 of Virchow's regulations for the performance of medicolegal postmortems. (See Chapter XXIX.) To discover the ductus arteriosus remove the thymus gland, incise the right ventricle along its septum, and extend the incision into the pulmonary artery along the middle portion of its anterior wall. The orifice is situated between and beyond the two openings of the right and left pulmonary branches. If the duct is open, a sound will readily pass into the aorta. It should be remembered that decomposition may produce bullæ in the lungs, that the lungs may be distended by the forcible introduction of air in the methods used for artificial resuscitation, and that air may get into the lungs of the child from emphysematous conditions affecting the uterus of the mother.

If in the hydrostatic test the lungs float on top of the water, aëration is complete,—a strong proof of breathing at or after birth; if they float beneath the surface, aëration is incomplete; and if they sink, respiration is considered not to have occurred. Decomposition of the lung tissue may cause it to float. A very valuable sign of the viability of the child is the presence of uric acid crystals in the kidneys.

Rigor mortis does not prove, as has sometimes been asserted, that the infant was born alive in the legal acceptance of this phrase. The rigidity may be of the so-called antenatal variety; it may even unduly prolong labor by interfering with delivery.¹

The *Lancet* of April 26, 1902, raises the query whether the dead body does not possess properties akin to radio-activity, and alludes to the photographs taken by Vignon and exhibited by him, with the winding sheet preserved at Turin and traditionally said to be that of Christ, which seem to justify the belief that the human body is either radioactive or that it gives off vapors which exhibit a similar action to light

¹ *Lancet*, February 14, 1903, p. 460.

upon sensitive surfaces. Peroxid of hydrogen may be the main factor concerned. *N*-rays of short wave length can be reflected, polarized, and refracted, and are transmissible by a metal wire. Ballet has found the emission of these rays to be decreased in diseases of the cord, as myopathies and neuritis, and increased in diseases of the brain, as hemiplegias and spastic paraplegias. Certain substances seem to store up these rays and emit them later. The question is whether there are not various rays of a similar nature. The conversion of radium into helium may also be of importance in this connection. Fluorescence and phosphorescence have also been much studied of late, and all these phenomena may have an important bearing on the future of pathology. An ion contains electrons. The *N*-rays increase the brightness of a spark, and phosphorescent bacteria may be used for detecting them. Sight, taste, smell, and hearing become more acute under their influence. Chloroform applied to plants seems to hinder their production. The *Comptes-rendus hebdomadaires des séances de l'Académie des sciences*, 1903-4, contains most of the best literature on the *N*-rays.

POST-MORTEM EXCITABILITY OF THE INHIBITORY NERVE APPARATUS IN THE MAMMALIAN HEART.—Locke¹ and Danilewsky² have recently made some interesting experiments with an aqueous solution of: Sodium chlorid, 0.9 per cent.; calcium chlorid, 0.024 per cent.; potassium chlorid, 0.042 per cent.; acid sodium carbonate, 0.01-0.03 per cent.; and glucose, 0.1 per cent. When passed through the coronary circulation under the pressure of an atmosphere of oxygen, perfusion of a rabbit's heart twenty-four hours after death with this solution not only starts beats but also so revives the nervous structures that stimulation of the vagus causes inhibition. Three days after death the auricles may be made to beat. The most astounding experiment of all was that by Locke, who took an adult rabbit's heart which had been hanging in the laboratory for five days, and which when perfused with the above solution of 35° C. gave beats of sufficient strength to give a tracing 2.5 mm. high.

PERIOD OF INTRA-UTERINE GESTATION.—In deciding the period of intra-uterine life of the infant the external evidences of value are: (1) Length and weight of the child (for the dimensions and weights of the new-born see page 395 and 396). (2) Conditions of the

¹ *Zentralbl. f. Physiol.*, December 30, 1905.

² *Archiv f. Physiol.*, 1905, *Sup'l Band*, p. 190.

skin and its appendages. In the healthy babe at full term the skin is white and covers the body smoothly; woolly hairs are present in perceptible numbers only on the shoulders; the hair of the head is from two to three centimetres long; the nails are hard and horny, extending beyond the ends of the fingers, but not of the toes. (3) Condition of the umbilical cord, which at term is fifty centimetres in length and is inserted somewhat below the middle of the abdomen, falling off by inflammatory demarcation on the fifth or sixth day. (4) State of the cartilages of the nose and ear, being hard in the mature infant. (5) Presence or absence of the *membrana pupillaris*, which disappears after the eighth month. (6) Condition of the genitals in both sexes; as descent of the testes begins at the seventh month, those of the full-term male should be in the scrotum. The female labia are generally found closed. (7) The measurement of the fontanelles, of the cranium, and of the transverse diameter of the body at the shoulders and hips. (8) The size of the centre of ossification (Béclard's) in the lower epiphysis of the femur. To view this the leg is flexed on the thigh, a transverse incision is made below the patella, which is removed, and the femur is then exposed. Thin transverse sections of the cartilage are made until the greatest diameter of the centre of ossification, if present, is reached. The centre is absent before the thirty-seventh week, and in the child at full term has a diameter of from two to three lines, though it may even then be absent. If the diameter is more than three lines, the child has very likely lived for a time since its birth. (Reese.) The osteochondral line is also to be examined for syphilitic changes. (9) With but very rare exceptions, a full-term child presents in the inferior maxilla eight alveolar compartments completely separated the one from the others. (Vibert.)

From the internal examination important evidence as to the age of the child, and especially as to respiration, is secured. Upon exposing the abdominal cavity, which is to be done before opening the thorax or cranium, the position of the diaphragm in its relation to the ribs is immediately noted, as especially urged by Virchow. If the lungs do not contain air or are but partially distended, the diaphragm reaches to the fourth rib; when the lungs are fully distended, the diaphragm is at the fifth or sixth rib on the right and at the sixth rib or intercostal space on the left.

To facilitate the examination of the umbilical vessels, Nauwerck

recommends a division of the usual abdominal incision, shortly before reaching the navel, into two diverging incisions extending to the pubes. The abdomen is opened, and the umbilical vein, made prominent by traction on the triangular flap, is traced along its course, ligated, opened with small scissors, and divided. Turning down the flap over the pubes exposes for examination the umbilical arteries to either side of the remains of the urachus. (Figs. 164 and 168.)

CRIMINAL ABORTION.—Formerly abortion was not legally a crime if performed with the consent of the mother prior to the viability of the foetus. It was at one time not regarded as murder even to take the life of a child at any period of uterine gestation. The barbarousness and danger to society of this view were later recognized, both abroad and in this country, and various laws with different penalties attached thereto were enacted making it a criminal offence to practise abortion at any period of gestation, unless for the express purpose of saving life. (Witthaus and Becker.)

There is no other class of cases so trying to the patience, ingenuity, and skill of the pathologist as those of abortion, which is accomplished by numerous methods. Many respectable women expose themselves to cold, falls, and douches with the hope of relieving themselves of their offspring apparently by accident. Many pills and potions are sold to induce a resumption of the menstrual discharge, and one often finds them on sale in drug-stores of the first rank and openly advertised even in the religious press. These nostrums are sometimes composed of poisons that may cause the death of a pregnant woman. Lead has recently been used extensively in England in order to produce abortion, and this toxic agent has been found in the organs of a child carried to term in a case where the abortion did not occur after the use of this substance. The use of instruments, especially the spiral douche advertised in so many papers, is a very common method of procedure. Indeed, the most successful criminal abortionists operate so that, unless through accident, no evidence of the operation is left. Usually all that can be found is evidence of a recent pregnancy. When infection occurs it usually travels by means of the ovarian veins. Septic abscesses in the lungs are common and ulcerative endocarditis may occur. The five most frequent causes of spontaneous abortion are syphilis, alcoholism, the infectious fevers, endometritis, and diseases of the placenta, as apoplexy. It must be remembered that, while there are generally accom-

plices in abortion, yet in many cases it is self-inflicted. The difficulty of distinguishing between the two is almost insuperable. All that the obducent can do is to use the utmost care in his examination and to note all the circumstances, with a view not only to the conviction of the guilty abettors, but also to clear, if possible, those unjustly accused.

When violence is done to the child, the nature of the injuries must be carefully noted. When violence is done to the uterus, some form of infection usually follows. In examination care must be taken to exclude the possibility of previous disease of the uterus or adnexa as a cause of the infection or possibly as a cause of abortion. In former days, when curettage was more used than it is now in the treatment of abortion, an additional factor was added, making it difficult and often impossible to distinguish dilatations of the os due to the instrument producing the abortion and to the passage of the foetus from those induced by the introduction of the curette and the subsequent packing with iodoform gauze. The vital history of the foetus should be compared with the physical condition of the mother, the history of the sexual life of the parents, specific disease, etc.

USUAL CAUSES OF DEATH.—In Chapter XXX will be found a list of all the recognized causes of death, and it is recommended that this International System of Classification be used by every one in order that uniformity of nomenclature may be secured throughout the world. Sudden death is usually due to failure of the circulatory apparatus, to cessation of respiration, to disturbance of the nervous system, to deficient nutrition, to poisons either produced within the body or introduced from without, or to violence by physical or chemic forces, heat or cold, electricity, wounds, missiles, etc.

Many conditions that have existed a long time may cause sudden death by overcoming the balance of life. Thus, in chronic nephritis uræmia may develop suddenly and cause death after only a very slight acute illness. Again, an aneurism may rupture without sudden increase in the symptoms or any violence, simply by a natural, slow progress of the lesion. All mortal diseases and many that by themselves do not end fatally may contribute to the production of sudden death as well as to slower dissolution.

No disease causing severe disturbance of heart, kidney, lung, nerves, or digestion can be ignored in estimating the factors that brought about the death of the patient. Certain maladies of common occurrence should be in our minds in making examinations, though

never so prominently as to prevent a proper search for other conditions. Thus, in children consider diseases acquired in intra-uterine life, malnutrition, accidents at birth, infection by the umbilicus, hemorrhages, infectious diseases, pneumonia, enteritis, bronchitis, meningitis, congenital syphilis and other hereditary diseases, infectious fevers, malformations, etc.; in young adults, infections (local and general), violence, typhoid fever, and tuberculosis; in middle life, diseases of the lungs, kidneys, heart, and blood-vessels, hepatic and gastro-intestinal conditions, infections, violence, occupation neuroses, pneumonia, tuberculosis, cancer, etc.; in old age, nephritis, carcinoma, softening of the brain and heart, gall-stone formation, sarcoma, aneurism, cerebral hemorrhage, embolus, thrombosis, tumor or abscess, arteriosclerosis in its most varied forms, obstruction of the coronary arteries, heart lesions, etc.

In Coroner's cases death very commonly results from heart exhaustion, due, as the case may be, to intrinsic disease, to excitement, or to poisons. Care should be taken to determine the cause of this exhaustion, whether it was due wholly to heart disease, such as a valvular lesion, or to one of the exciting causes. In kidney congestions consider whether death was due to failing heart causing passive congestion, to poisons, or to inflammatory congestion, such as would be part of an acute nephritis. Ascertain if the œdema of the lungs is dependent upon cardiac, renal, or cephalic lesions or primarily upon a lung condition principally.

VIOLENT DEATH.—When there is doubt as to homicide, all the precautions necessary for such cases must be strictly observed. The sort of violence, its mode of application, and something of an estimate as to the amount, direction, and conditions of application of force can usually be made from post-mortem examination. In the inspection of wounds the condition of the tissues and the position and direction of all lesions discovered are to be very carefully noted, as sometimes the instrument with which they were inflicted may safely be inferred therefrom, and at times the findings will point to the circumstances under which the injuries were received. A minute description of the injuries is absolutely necessary, so that if called upon in court an exact account of them can be given. The amount of contusion, laceration, extravasation of fluids, and damage to any vessels must be carefully noted. It is important in gunshot wounds that the projectile should be found. About the wound of entrance look for

PLATE VI

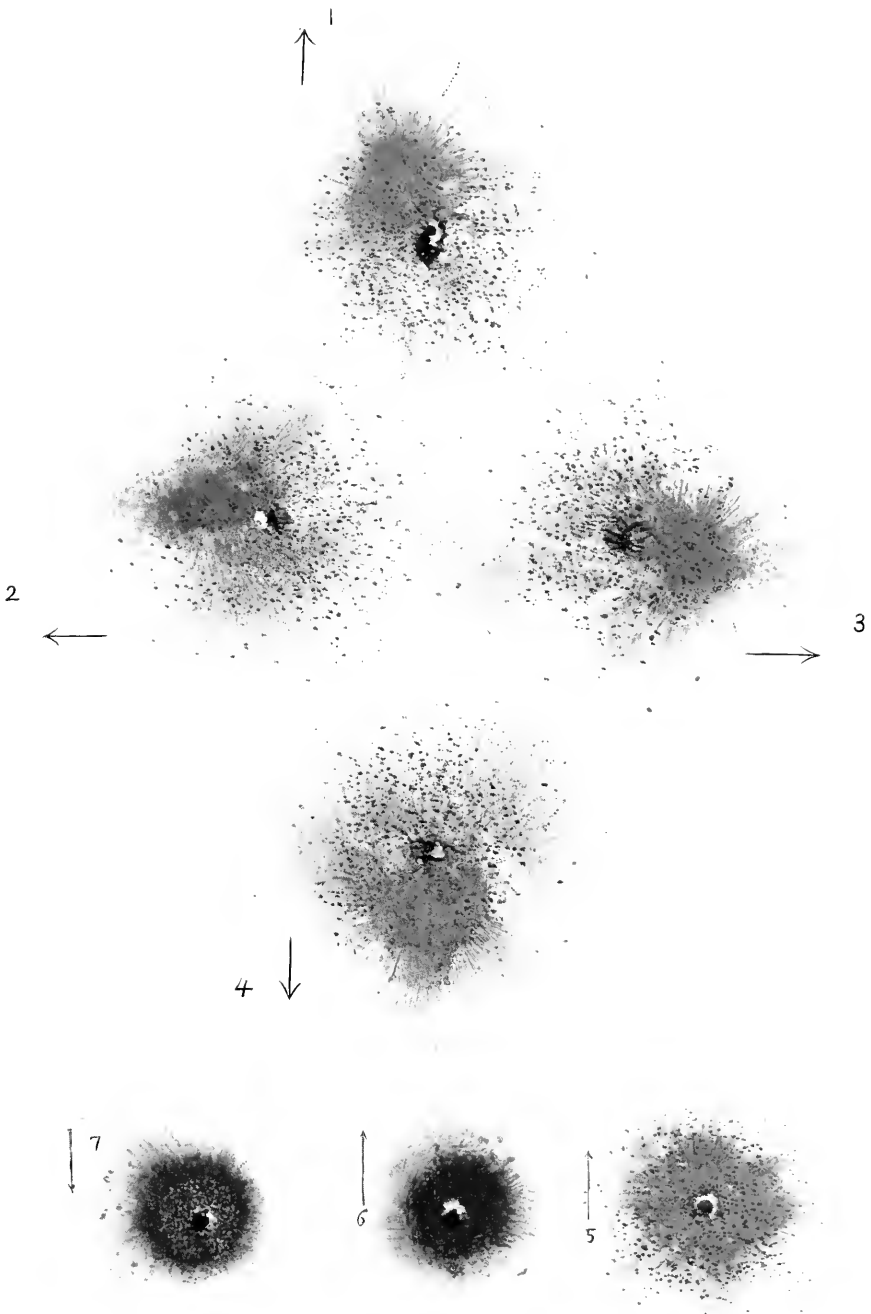


PLATE SHOWING COMPARATIVE EFFECTS OF "BLACK" AND "SMOKELESS" POWDER CARTRIDGES AT SHORT RANGE.

Figs. 1, 2, 3, and 4 are produced by a revolver (.38 inch) charged with ordinary black powder and held in hand. The firing distance is eight inches. The markings were made before the members of the Academy of Surgery of Philadelphia on the evening of May 5, 1902. In Fig. 1 the hammer is up; Fig. 2, to the left; Fig. 3, to the right; Fig. 4, down. Fig. 5, revolver immovably held by fixing in a vice; bullet-hole in centre of brand; black-powder cartridge. Fig. 6, revolver cartridge of "smokeless" powder, fired from hand; hammer up; showing circular powder mark, with little or no "brand"; Fig. 7, same, hammer down. (The illustrations are about one-half natural size.)



powder marks, singeing, and smudge. If the projectile struck a bone, a splinter may have been detached and caused injuries not along the line of the main wound. The effect of small arms loaded with smokeless powder has recently been studied by Johnson.¹ Such markings are less distinct and more indefinite than in the case of black powder. Even at a distance of three inches or less the markings may be so indistinct as to be capable of being wiped away from the skin with ease, and when the part is covered with clothing no powder marks are found nor is the clothing scorched. Herold² reports a fatal case where a pistol fired at short range left no powder markings of any description. Plate VI shows the effects of black and smokeless powder at short range. (Brinton.³) Death is frequently due to shock, which may result from a blow that leaves no mark visible at the post-mortem. This is quite uncommon. Injuries to the head make it necessary to estimate the structural and tensile strength of the skull in each case. When a fracture of the skull is found or suspected, the skullcap must be cut away with the saw only, not using the chisel. *Contrecoup* must always be considered in hunting for fractures and lacerations of blood-vessels. Rawling⁴ has recently published an interesting article on the mechanism of skull fractures, and Wadsworth⁵ has discussed the question of injuries to the brain. Accidents of various sorts may produce most marked and varied deformities, and give rise to such interesting medicolegal questions as the following: What was the duration of life after the reception of the fatal injuries? Did an electric shock immediately kill the person, or, being only stunned, did he die from the effects of the fall? Did a woman whose decomposed body was found in water, with enough arsenic in her system to kill, die from the effects of the poison or from drowning? In a case where a man shot his wife and then committed suicide, which one died first? A most inviting field of research and of medicolegal dispute are cases of malignant tumors and of infection arising within the body from traumatic injury received externally.

SUICIDE.—Upton, formerly of the *Chicago Tribune* and an authority upon suicide in America, says that during the last thirteen years,

¹ *Annals of Surgery*, 1904, May, p. 798, and June, p. 1006.

² *Legal Medicine*, 1902.

³ *Int. Clinics*, Twelfth Series, vol. iii, p. 148.

⁴ *Lancet*, 1904, April 9, p. 973, and April 16, p. 1034.

⁵ *Proceedings Phila. Path. Soc.*, February 28, 1901.

1891 to 1903 inclusive, 77,617 suicides (57,317 men; 535 physicians) were reported as suicides in the newspapers of this country.¹ That the number of suicides, especially among children, is increasing throughout the world is undoubted, this being more notable in times of financial trouble. Up to the time of the Japanese war, suicide had not increased in Russia. Prior to 1894 the larger number of suicides shot themselves; now such poisons as gas and carbolic acid are most frequently employed, arsenic not being used so often as formerly. In Chicago in 1902 there were 147 cases of self-destruction, 127 of which were by carbolic acid. In Philadelphia during the same year there were 196 cases, of which 42 were from gunshot wound, 33 from gas asphyxiation, 32 from strangulation, and 31 from carbolic acid. According to Vibert, the order of frequency of suicides in France is by hanging, drowning, shooting, illuminating gas, and poison. In Germany a favorite method of committing self-murder in the army is to explode a blank cartridge in a rifle, the barrel being previously filled with water.² In a recent suicide in Philadelphia an insane patient at Blockley held a razor in each hand and gashed his throat in both directions. I have seen cases where a man cut his wife's throat and then his own, thus affording a favorable opportunity of comparing the wounds inflicted. Great care must be used in making deductions from such examinations, as well as in saying from the inspection of an incision whether it was made by a right-handed or a left-handed person. To prevent detection ingenious ways of hiding the effects of poisons upon certain parts are often tried. Thus, potassium bichromate may be introduced into the stomach inside of figs, a device which will prevent injury to the upper intestinal tract.

During my term of service of nearly three years as Senior Coroner's Physician of the City of Philadelphia, I performed, according to the official records, 799 postmortems, of which 59 were homicidal. It should be remembered that there were two physicians for Philadelphia, and that the Coroner's jury were able in many cases to render a verdict without a necropsy being made, practically no accident cases, no suicides from known causes, and no subjects accompanied by letters from a physician stating the probable cause of death undergoing such examination. Of persons "found dead" the bodies were too much

¹ In 1905 the number of deaths by violence reported was 9212, the homicides exceeding those of 1904 by 730. There were 133 executions in 1905 and 66 lynchings.

² *London Times*, July 30, 1903.

decomposed to permit of a proper diagnosis, some of them having been in the water for months or showing skeletal parts alone. Under the head of Bright's disease and uræmia are included some cases of alcoholism or of deaths incapable of diagnosis *post mortem* without extended chemic or microscopic study, etc. All the victims of heat-stroke, with one exception, appeared to be alcoholics.

The chief causes of death, arranged alphabetically, were:

Abortion	33	Heat	9
Abscess of various parts of the body	5	Hemorrhage from various causes other than extra-uterine, injuries, etc.	16
Alcoholism	45	Inanition	14
Aneurism	24	Injuries, as kick of horse, blows, run over by wagon, etc.	16
Apoplexy	28	Meningitis, tuberculous, and spotted fever	6
Appendicitis	7	Peritonitis from other causes than abortion and appendicitis	9
Bright's disease and uræmia	84	Poisoning	56
Burns and scalds	5	Scarlet fever	4
Cancer	12	Stab wound	8
Childbirth	3	Strangulated hernia	4
Cholera infantum	9	Strangulation	7
Cholera morbus	5	Stillborn	15
Concussion of brain	3	Suffocation	9
Convulsions	7	Syphilis	3
Croupous pneumonia	19	Tetanus	2
Cyanosis	8	Traumatic hemorrhage of the brain.	9
Diphtheria, including croup	11	Tuberculosis of the lungs	16
Drowning	50	Typhoid fever	6
Electric shock	8	Miscellaneous	68
Erysipelas	2	Total	799
Extra-uterine hemorrhage	4		
Found dead	9		
Fracture of skull	27		
Fractures, other parts	3		
Gunshot wounds	25		
Heart disease	76		

The fifty-nine cases of homicide were made up as follows:

Burns	1	Gunshot	18
Drowning	2	Knife wound	10
Injuries, as hemorrhage from fracture of the skull from a fall following a blow, etc.	24	Poisoning (illuminating gas 2 and strychnine 1)	3
		Strangulation	1

The kind of poison used in the fifty-six cases was:

Aconite	1	Chloroform	1
Ammonia	1	Creosote	1
Arsenic	5	Cyanid of potassium	1
Carbolic acid	10	Ether narcosis	2

Hydrocyanic acid	2	Oxalic acid	1
Illuminating gas	12	Phosphorus	1
Lead	1	Silver nitrate	1
Oil of mirbane.....	1	Stramonium	1
Opium (acute)	10	Strychnine	2
Opium (chronic)	1	Sulphuric acid	1

Cases of poisoning are almost daily being reported from new sources, by novel methods of procedure, and from a constantly increasing number of unexpected causes. Thus, in flash-light photography the magnesium oxid and the chlorate of potassium may produce on ignition chlorin gas sufficient to inflict bodily harm.¹ A dye, parphenylendiamin, used in the preparation of certain furs, may give rise to bronchial asthma and skin eruption. The use of thread to remove particles of food from the teeth may cause arsenical poisoning and the picking of the teeth with splinters of matches may give rise to phosphorus necrosis. Children playing with "tin" toys, and soldiers in whose flesh are embedded bullets may suffer from lead poisoning. Poisonous toxins are often produced in imperfectly cured fish. The spraying of fruit trees may occasion fatal poisoning by the material falling on vegetables below, such as salads and beet greens. Löffler calls attention to poisoning by milk from cows that have eaten poisonous plants. Petroleum speers, resembling old-time chloroform parties, are increasing, boys even stealing kerosene from the public streets for the purpose. Women smoke "tea" cigarettes and boys suck the cologne from automatic machines. The effects of poisons may be modified in many ways; thus, the presence of insoluble substances may inhibit to a certain extent their toxic action.

IS AN INTERCRANIAL HEMORRHAGE DUE TO VIOLENCE OR DISEASE; OR IS IT A COMBINATION OF BOTH FACTORS? ²—The usual situations of a cerebral hemorrhage are: (1) Between the bone and dura mater; (2) Subdural of the arachnoid space; (3) Between the pia mater and the brain substance; and (4) In the substance of the cerebral matter itself. The situation of a cranial hemorrhage may be most varied, and it may be associated with capillary hemorrhages situated at a distance from the effused blood. The first point to determine is the condition of the arteries of the circle of Willis, following out with great care the middle cerebral artery. The signs of violence are of the greatest

¹ GRAEFE, *Deut. med. Wchnschr.*, March 13, 1902, p. 191.

² TAYLOR'S *Principles and Practice of Medical Jurisprudence*, 1905, vol. i, p. 500.

importance, and yet it is sometimes difficult to determine whether the violence has been produced first and the hemorrhage afterwards or the person has suffered from an apoplectic stroke and in falling has sustained the injury. Scurvy, purpura, sclerotic kidney, hæmophilia, and arterial atheroma are the most common causes of capillary oozings without a very definite easily observable blood clot. An evident clot in the substance of the brain or in the ventricles is never the result of violence *alone* unless the violence has been sufficiently severe to leave manifest evidence of its infliction, but it is a very frequent result of disease alone or disease plus excitement. The younger the patient and the less inclined to intemperance, the rarer it is to find definite hemorrhage or capillary oozing in the substance of the brain without evident violence. But this may occur from no special cause or from a violent fit of coughing, as in whooping-cough. In difficult labor it is by no means uncommon. Meningeal hemorrhages are much more likely to be the result of injury than of disease. A meningeal hemorrhage is found immediately under the spot struck or by *contrecoup* on the opposite side of the skull. In case of fracture the hemorrhage may occur anywhere in its neighborhood. When a cerebral hemorrhage, no matter what its extent or seat, is associated with a fractured skull the presumption that it was due to violence is practically overwhelming. The age of the clot may throw light upon a difficult problem. Excitement must be allowed to have its influence in giving an increased tendency to cerebral hemorrhage and in aggravating the quantity of effused blood, but no further. Recent effusions of blood are recognized by their red color and the consistency and appearance of the clot. After some days the clot acquires a chocolate or brown color and this passes gradually into an ochre tint from twelve to twenty-five days after the violence. Old clots are firmer and there is much lymph which is sometimes disposed in membranous layers of a fibrous structure. The surface of the brain sometimes presents a mark indicative of pressure.

One of the most common homicidal ways for the production of a fatal hemorrhage is for a man to be knocked down by another and in falling to strike his head with sufficient force to cause a fatal hemorrhage of the brain, with or without a fracture of the skull. An extradural hemorrhage is most apt to be associated with fracture. Children dying from toxic doses of alcohol frequently show internal hemorrhages of the brain.

BURNS AND SCALDS.—Burns are produced by dry heat and show when fresh no maceration of the tissues. When inflicted by intense heat or by flame, there will be found scorching or singeing of clothing and hair, and possibly of flesh. When resulting from contact with a hot surface, note especially the shape of the burn, and, if the alleged hot object can be obtained, a corresponding mark may be found upon it. In burning the hair often reddens. In burns from electricity the markings are apt to be branched. It must not be forgotten that burns and scalds, especially when preceded by an explosion, may cause considerable injury or even destruction of the parts. Scalds are produced by vapor, steam, or a liquid, and usually show some trace of the action of the fluid on the mucous membrane or skin. In plain scalds singeing is absent, but where fire has followed an explosion both scalds and burns may be found. In such cases the mucous membrane of the air-passages should always be examined. In cases of scalds and burns the extent of the injuries must be determined both in breadth and in depth, with a careful observation of secondary changes, such as sepsis, internal congestions, and inflammations. There are probably produced by these means hæmolysins and hæmo-agglutinins,¹ which products are poisonous to the organism, and act as in other forms of auto-intoxication. Death ensues when one-third of the body is burnt, even though but slightly, from shock to the nervous system, hyperpyrexia, and various circulatory disturbances.

DEATH BY ELECTRICITY.—In death by lightning the clothes are sometimes torn off the body and there sometimes occurs a peculiar form of burn, the so-called lightning figures, and a rupture of internal organs, as the liver or heart. In some cases the point of entrance or exit can easily be made out by marks upon the skin or burns in the clothes. The exit of the current is especially to be looked for in the heel owing to the presence of nails in the shoe. It is sometimes most difficult to tell, in those cases where an electric shock has been received and the person falls thereafter, whether such a person died from the effects of the fall or from the electricity. There are no absolutely constant findings at the autopsies. There is often unnatural rigidity of the muscles, sometimes with distortion. There may be evidence of electrolytic action of the blood and organs, as in the brain and cord; there, signs of suffocation and hypervænicity of the blood

¹ EDITORIAL, *Jr. Amer. Med. Assoc.*, January 9, 1904, p. 103.

are found. Microscopically, degenerations are found in the gray matter of the spinal cord along with dilation of the central canal and hemorrhages. It would seem that death is most frequently due to paralysis of the heart or of the central pulmonary system.

Jellinek¹ finds that the anatomic changes in the tissues resulting from the passage of a powerful electric current diminish the resistance of future currents. Mice are killed with a weak current, but pigs show the greatest resistance. Death by electricity occurs more quickly after administration of morphine or cocaine, but is retarded by chloroform anaesthesia. A dose of morphine might therefore be administered with benefit before an electrocution. A horse is more easily killed by electricity than a man, and the alternating current is more deadly than the continuous current.

Cases of death have been alleged to occur from cancer due to the X-rays. The Galway case, tried in the Dublin courts in March, 1904, contains the best account on record of the legal liabilities, the case being decided for the defendants that the burn was not caused by negligence. As already seen Schönberg has shown that all the male rabbits and guinea-pigs exposed to the Röntgen rays proved sterile afterwards. Brown and Osgood have collected the records of eighteen cases of total azoöspemia or oligonecrospermia in X-ray workers.

DEATH FROM HEAT OR COLD.—After fatal heat-stroke the body is often very hot for hours and decomposition may be uncommonly rapid. There may be general internal congestion. It is usually necessary to know somewhat of the history of the case before a verdict can be rendered of heat-exhaustion, sunstroke, or thermic fever. In cases of death from cold we often find pallor or discoloration of the skin and congestion of the viscera with blood of rather bright color. No single characteristic lesion results from exposure to moderate excess of either heat or cold. When no pathologic lesions can be found, death is probably due to shock. Any chronic disease of the viscera tends to reduce the power to resist severe temperature changes. There is no significance in the freezing of the body beyond showing that considerable time may have elapsed since death. The frozen flesh of the mastodon sometimes found in the Siberian plains may be used as food, though it must be thousands of years old.

¹*Elktropathologie*, Stuttgart, 1904. See also BOIS, *Arch. d'électric. méd.*, Bordeaux, 1903, xi, p. 608, and KRATTER, *Eulenb. Jahrb.*, ii, 1904 (lit.).

There are no characteristic changes in sunstroke. Rigor mortis comes on early. Lividity and putrefactive changes develop rapidly after and even before death. Venous engorgement is extreme, particularly in the cerebrum. The left ventricle of the heart is contracted; the right is dilated and may be full of blood imperfectly coagulated and deficient in oxygen. The blood is fluid, dark in color, acid in reaction, and probably contains, as in burns, a poisonous substance which acts on the more highly specialized cells of the body. Petechial patches may appear in the subcutaneous and subserous tissues. The elevation of temperature is often remarkable, and it is extremely disagreeable to make an autopsy in these cases, as I have done, soon after death, with a temperature of 106° F. In a case of mine of stramonium poisoning, with a temperature of nearly 110° F., the clinician had diagnosed sunstroke, because of the high temperature and lack of history afforded by the patient.

INFANTICIDE.—Many methods have been resorted to, as exposure to cold, smothering in various ways, strangulation either by the hands or by a ligature around the neck, and wounding with various instruments, sometimes accompanied by efforts to conceal the act. The child may be intentionally drowned in a vessel containing fluids discharged from the vagina at the time of birth. Gross violence or poisons may be employed.

DEATH BY STARVATION.—There is usually extreme emaciation, which is shown especially by a sinking of the eyes and an unfilled condition of the skin. It is sometimes necessary to determine whether starvation resulted from disease or neglect, especially in cases of those children which have been reared in foundling homes and hospitals. If all food and water be withheld death occurs after forty per cent. of the body-weight has disappeared, of which approximately one-half is due to disappearance of muscular tissue. Ninety-three per cent. of the fat is lost, while the heart and nervous system show the least loss. In man death takes place in from seven to twelve days, bodily exercise diminishing the length of time. When water is used a person may live over forty days. The introduction of many substances, such as iron, is necessary for the perfect body.

SUFFOCATION; STRANGULATION; HANGING; DROWNING.—All these produce death by asphyxia, or carbon dioxid poisoning, combined with oxygen starvation, the signs of which are more or less marked. In death from asphyxia there are usually hemorrhages into the thymus gland, as well as Tardieu ecchymoses in the pleura

and pericardium. In suffocation there is but little tendency for the blood to coagulate, and no marks of violence may be present. The dark, fluid blood, possibly hemorrhages from increased blood-pressure, general congestion of the lungs, frequently congestion of viscera, often blue nails and lips, occasionally suffusion of the face with dark, venous blood, and an absence of other pathologic conditions, present a general type of morbidity that is not easily mistaken when clearly marked, but is difficult to recognize when not conspicuous.

Strangulation adds the factor of mechanical arrest of respiration, and may result from the presence of food, some foreign substance, or a growth or swelling in the throat. When due to throttling the marks about the neck are of great importance. There may be compression of veins.

Hanging may cause death by injury to the spinal cord as well as by compression of the blood-vessels and air-passages. The parchment-like appearance of the skin on the sides of the neck and the rupture of the intima of the carotids afford valuable evidence. In drowning see if the tongue is protruded between the teeth and whether or not punctate hemorrhages are found beneath the pleura. In hanging, lividity of the face and hyperæmia of the conjunctiva occur.

Wachholz¹ has shown experimentally that in acute suffocation there may be found, along with the soft currant-jelly clots in the heart, solid white clots embedded in the meshes of the cardiac muscle. La Casagne and Martin have described a method, called *docimasia hépatique*, of diagnosing sudden death by a marked increase in the sugar contents of the liver of persons who have died suddenly. Wachholz finds from his experiments that no such relation exists.

Reuter, working with Kolisko,² from a study of twenty-two cases of throttling and two hundred cases of hanging, thinks that these two very similar modes of death may be differentiated from each other. In throttling there is (1) cyanosis of the face, with ecchymoses of the eyelids and conjunctiva. (2) The scalp, the coverings of the brain, and its membranes are always rich in blood. (3) As a rule, hemorrhages in the soft tissues of the neck, especially in the muscles, occur. (4) There is marked injection of the upper air-passages, combined with numerous small hemorrhages. (5) Injuries to the larynx and hyoid are

¹ *Vrtiljschr. f. gerichtl. Med.*, 1902, p. 34.

² *Zeitschr. f. Heilk.*, 1901, vol. xxii, p. 145.

rare. (6) Rupture of the intima of the carotid is never noted; in only three cases were there suffusions into the adventitia. In hanging (1) cyanosis of the face is usually not noted; ecchymoses are seen in twenty per cent. of typical and in thirty per cent. of atypical strangulations. (2) The amount of blood contained in the organs in the skull varies, but usually consists only of that which was present in these parts at the time the circulation was interrupted. (3) Hemorrhages in the muscles are rare,—two per cent. in typical and fourteen per cent. in atypical cases. (4) Injuries to the laryngeal and hyoid structures are common,—sixty per cent. in typical and thirty per cent. in atypical cases. (5) Rupture of the intima of the carotids occurs in five per cent. of typical and four per cent. of atypical hangings. The external markings on the neck are also often different.

In a case of drowning water or foreign substances may be found in the openings of the body, in the respiratory organs, or in the stomach, or death may be due to spasmodic arrest of respiration. The froth from the air-passages is coarser than that seen in cases of œdema. Very soon after death we often find watery fluid in the pleura. The spongy condition of the lungs is found only where there has been inhalation of water, which does not always happen. After decomposition has set in, the evidence of drowning gradually disappears until it is impossible to make the diagnosis. In drowning the bleaching of the palmar and plantar skin surfaces occurs very early. Littlejohn¹ discusses the differences in appearance after drowning in salt and in fresh water. Of those drowned in sea water the soft parts are rapidly destroyed by crabs and fishes, in some cases the bones alone remaining after ten days, while the body undergoes putrefactive changes more slowly. He reports a case where calcium phosphate crystals studded the pleura. The place in which a person is drowned may sometimes be told by the character of the material found in the smaller bronchi. Revenstorff² determines the freezing-point of the blood from both sides of the heart, as more or less of the fluid in which an animal is drowned usually passes through the capillaries of the lungs and dilutes the venous blood. He concludes that the method, when positive,—*i.e.*, when it can be shown that the freezing-point of the blood from the right side of the heart is higher than that of the blood from the left side,—is valuable as additional evidence of drowning,

¹ *Edinburgh Med. Jr.*, February, 1903, p. 123.

² *Münch. med. Wchnschr.*, 1902, no. 45, p. 1880.

and is very easily carried out; but decomposition rapidly removes any difference which may have existed, and the blood is not necessarily diluted during death by drowning.

CYTOLOGY.—The different kinds of cells found under various conditions in the serous cavities form a most inviting field of study. Thus, in syphilitic hydrocele we have endothelium; in gonorrhœal hydrocele, marked polymorphonuclear leucocytosis; in tuberculous hydrocele, lymphocytosis; in mechanical hydrocele, few or no leucocytes. Naturally, the age of the process has much to do with the number and variety of the cells.

SEMEN.¹—The Florence test should be first applied, a reaction common to all semen, and then the material studied microscopically. Seminal stains remain intact for years under favorable circumstances and give the biologic blood test.

Schütze² finds in the use of the precipitin method of discovering spermatozoa that the animal need not be inoculated with semen or testicular cells, but that any albuminous fluid of the animal's semen to be proved will produce a serum capable of giving rise to the reaction.

TOXICOLOGY.³—The presence of poisons in the animal economy may be recognized clinically, chemically, pharmacologically, and pathologically. While we have chiefly to do with the latter method, the success of the chemist and the pharmacologist depends largely upon the procedures adopted for the preservation of material by the pathologist at the time of the performance of the autopsy. There are certain poisons which may kill without leaving in the tissues any specific alterations to be found *post mortem*, especially when the examination is postponed for several days.

A poison is any substance which, when taken into the system and either being absorbed or by its direct chemic action upon the parts with which it is in contact, or when applied externally and entering the circulation, is capable of producing deleterious results. (Wormley.)⁴ Poisoning commonly results from alcohol, morphine, lead, arsenic, phosphorus, oxalic acid, carbolic acid, etc.; from food (bromatotoxicis-

¹ See SIMON'S *Clinical Diagnosis*, 1904, p. 664, or any other recent work for the method of applying this test; *Arch. d'anthrop. crimin.*, vols. x and xi.

² *Zeitsch. f. Hyg. u. Infectiouskrank.*, 1901, vol. xxxvi, p. 5.

³ Much of the material in this section is taken from KOBERT'S *Lehrbuch der Intoxikationen*, Stuttgart, 1902, and GLAISTER'S *Medical Jurisprudence*, 1903.

⁴ To show the difficulty of any definition, carbolic acid when sufficiently diluted may serve as a *food*. ZIEGLER, *Gen. Path.*, xi, p. 23.

mus); from meat (kreatoxismus); from milk products (galactotoxismus); from fish and shell-fish (ichthyotoxismus, mytilotoxismus); and from grain ¹ (sitotoxismus); of the latter poisoning there are three kinds,—ergotism, lathyrism, and pellagra.

It should always be remembered that conditions which we are apt to regard as being alone produced by strictly pathologic processes are often due to poisons. Thus, toxic inanition may be produced by chronic poisoning with mercury, lead, arsenic, etc.; fatty degeneration, by phosphorus, alcohol, *Amanita phalloides*,² etc.; calcification of the renal epithelium, by corrosive sublimate; and amyloid degeneration, by repeated injections of turpentine.

Suspicious undissolved foreign bodies may be found in the vomit and in the contents of the alimentary tract, as arsenic (white, metallic, and various salts), antimony, sulphid of antimony, mercury and its preparations, as calomel, oxid, and bichlorid, chrome salts, oxalates, cantharides, nux vomica beans, heads of matches, and parts of poisonous plants. In one of my cases diagnosed as a heat-stroke, with a temperature of over 110° F., the finding of leaves of *Datura stramonium* in the stomach led to the correct diagnosis. Morphine even when given hypodermically may be found in the stomach contents. Certain diseases and chemicals, mentioned on pages 31 and 32, may be detected by odors coming from the body or from the various cavities when opened.

When the acidity or alkalinity of the gastric contents is abnormally increased, certain reagents are to be suspected, such as acids, alkalis, and potassium cyanid. The liver especially shows poisoning by phosphorus, antimony, arsenic, and toxins, while the kidney is affected by hæmolytic and methæmoglobinic poisons, by oxalic acid, oxamid, mercury, silver salts, preparations of cantharides, etc. The spectroscopic picture of the blood should always be obtained as soon after death or removal from the body as possible. The addition of a little distilled water is admissible in methæmoglobinæmia, but even here it is better at once to seal hermetically in glass tubes with exclusion of air as far as practicable. If the blood coming from veins is fluid and scarlet, suspect carbon monoxid poisoning; if a laky purple

¹Recent Japanese writers consider that kakké (beriberi) is due to the continued use of spoiled dry rice.

²W. W. Ford, of Baltimore, thinks that he is able to produce an antitoxin for poisonous mushroom intoxication. *Med. News*, October 21, 1903.

fluid, not changing on the exposure to oxygen, suspect cyanid. If the muscles of the abdominal walls are drawn and contracted spirally, we may suspect any of the instant poisons, as strychnine or potassium cyanid. I have for a long time had a bottle of blood from a case of cyanid poisoning, and have many times exposed it to the air by removing the cork, yet it is apparently still in a good state of preservation and smells of hydrocyanic acid.

The left heart is found markedly contracted in death from overdoses of members of the digitalis group, veratrine, and barium salts. As already stated, the odor of the poison may sometimes be detected on exposing the brain. Much attention has been paid to the actions of poisons on the central nervous system, and the rapid diagnosis of hydrophobia by this method should not be forgotten. For a description of the Negri bodies in hydrophobia, see the *Zeitschrift f. Hyg. u. Infectiouskrank.*, 1903, vol. xlv, p. 519. The joints are alleged to be inflamed after poisoning by colchicum. Testicular atrophy is said to be induced by the long-continued use of capsicum, solanus pseudocapsicum, and conium maculatum.

The mucous membrane of the stomach is irritated and stained by many poisons, as sulphuric acid (black), nitric acid (yellow), oxalic acid (white), bromin (red), iodin (purple), and by a large number of metallic salts, as sulphid of arsenic (yellow), chromate of potassium (red), etc. I have, however, seen several cases of arsenical poisoning with but little inflammation of the gastric mucosa.

Among the questions to be answered in every case of suspected poisoning are: Was death caused by a poison originating within or without the body? What poison caused death? Is the substance found by the chemist the poison which killed the person in whose body it was found? Might not the poison have been administered as a medicine? Is the poison present in such quantity as always causes death? Were there attendant circumstances which conduced to the fatal result? Was more than one poison given? How and when was the toxic substance administered? Could poison have been given and yet not be discovered? Was the fatal dose taken for purposes of suicide? Was it administered with the object of killing? Was it administered accidentally? Did the person for whom it was intended receive the poison? Could the toxic symptoms be simulated? Was cremation practised in order to destroy evidences of poisoning? Was there any motive for homicide? Are there any accomplices? What

became of the vehicle in which the poison was administered? Was there any poison found? Was any poison destroyed?

In order to convict of murder in the first degree in case of poisoning, it is the manifest duty of the District Attorney to prove three things to the Court and Jury beyond any reasonable doubt: first, that the person alleged to be murdered is dead, a fact proved by the identification of the cadaver; second, that death was caused by the poison under consideration and did not take place by natural causes; and third, that the party or parties on trial administered the drug with felonious intent, and that it was not taken accidentally or with suicidal purpose. Naturally, the province of the medical expert will deal largely with the second condition.

On request of ex-Judge Stevenson, the counsel for the defence, in the case of the Commonwealth of Pennsylvania *vs.* John and Emma Williams, Judge McMichael issued the following order, under which I made a post-mortem examination of the bodies of the three children, after the experts for the Commonwealth had already made an original examination and two disinterments.

“ And now, to wit, this sixteenth day of February, A. D. 1903, it is ordered and directed that the defendants through their experts shall have access to the bottles and prescriptions taken from 1135 Vienna Street, and also that they shall be permitted to exhume the bodies of Anna, Josephine, and Laura Williams, and to make such examination as they shall deem necessary and proper, and to remove such portions of said bodies as may be necessary to a proper and adequate chemical examination and analysis to determine the causes of death. It being understood, however, that the Commonwealth shall during these investigations be represented by an expert that they may select.”

Nearly every toxicologist has his own classification of poisons. Thus, one divides them into mineral, vegetable, animal, and mechanical groups; another into irritants, narcotics, and narcotic irritants; a third into chemic and vital poisons; a fourth into those which produce local irritations, act upon the blood, and upon the nervous system and heart, etc. All such divisions are arbitrary, as quickly becomes evident on attempting to place the various poisons in their proper subclasses.

SCHEME FOR THE DIVISION OF POISONS.

INORGANIC	{	Irrespirable gases : carbon monoxid, coal gas, chlorin, bromin,
		hydrofluoric acid, sulphur dioxid, etc.
		Chemic : sodium hydrate, sulphuric acid, etc.
		Irritant : arsenic, antimony, mercury, phosphorus, etc.

SCHEME FOR THE DIVISION OF POISONS.—(Continued.)

ORGANIC	Irritant	{	Irrespirable gases : chloroform, ether, formalin, etc.
			Chemic : carbolic acid, acetic acid, pyrogallic acid, etc.
	Alkaloidal	{	Vegetable : gamboge, colchicum, squill, etc.
			Animal : cantharides, etc.
			Narcotic : opium, hyoseyamus, belladonna, cannabis indica, etc.
Synthetical	{	Sedative : digitalis, hydrocyanic acid, aconite, conium, etc.	
		Excitomotor : strychnine, ergot, etc.	
		Antiseptics : creolin, lysol, etc.	
Toxicin	{	Antipyretics : antipyrin, acetanilid, etc.	
		Hypnotics : sulphonal, trional.	
		Bacterial : toxins, hæmolysins, cytolysins.	
			Animal : snakes, scorpions, ptomaines, etc.
			Vegetable : ricine, abrine, etc.

SYMPTOMS OBSERVED AFTER THE ADMINISTRATION OF THE MORE COMMON POISONS.¹

ACUTE SYMPTOMS:	THINK OF:
1. Death within a few seconds or minutes.	Hydrocyanic acid; potassium cyanid; carbonic acid; carbolic acid.
2. Deep coma.	Alcohol; morphine; opium; chloral hydrate and its derivatives; sulphonal; chloroform and its derivatives; carbon monoxid; anilin oil; oxybutyric acid.
3. Collapse.	Corrosive acids; corrosive alkalies; nicotine; arsenic; antimony; colchicine.
4. Feverish rise of temperature.	Phosphorus; cocaine; under certain circumstances any of the powerful convulsive remedies; enzymes.
5. Mania; furious delirium; psychic excitement.	Chronic alcoholism; atropine; cannabinone; camphor; physostigmine; veratrine; lead (in animals).
6. Mental disturbances of the most diverse kind.	Alcoholism; morphinism; cocainism; pellagra; ergotism; inhalation of ether; saturnism; mercurialism; poisoning by bromid; iodoform; carbon bisulphid.
7. Violent; at times, tetanic convulsions.	Strychnine; toxin of tetanus; salts of ammonia; cytisine; cornutine; picrotoxin; cicutoxin; active principles of digitalis; cocaine; santonin; aconitine; gelsemine; flicic acid.

¹This table and the following one are from ROBERT'S *Compendium der Toxicologie*, 1903.

SYMPTOMS OBSERVED IN CASES OF POISONING.

ACUTE SYMPTOMS:	THINK OF:
8. General paralysis, for the most part ascending.	Coniine; curarine; colchicine.
9. Paralysis of individual groups of muscles.	Lead; arsenic; carbon bisulphid.
10. Dilatation of the pupil.	Atropine; hyoscyamine; scopolamine; cocaine; ephedrine; aconitine; coniine; gelsemine; sausage poisoning.
11. Contraction of the pupil.	Muscarine; pilocarpine; nicotine; arecaline; morphine; codeine; opium; physostigmine.
12. Amaurosis.	Quinine; salicylic preparations; extract of male fern; belladonna; uræmic poisoning.
13. Diplopia and ptosis.	Sausage and fish poisoning.
14. Conjunctivitis.	Irritating vapors (sulphurous, hydrochloric, nitric, and osmic acid; nitrogen dioxid; hydrofluoric acid; chlorin; bromin; carbonyl chlorid; ammonia; ethereal oil of mustard; croton oil vapor); irritating kinds of dusts, as root of ipecacuanha, quillaja bark, pepper, chromate, picrate; arsenism; phenylendiamin, chrysarobin, [formalin].
15. Moist skin.	Opium; morphine; aconitine; muscarine; pilocarpine; nicotine; physostigmine; lobeline; antimony.
16. Skin conspicuously dry, even in a warmed bed. Mouth and throat parched.	Atropine, as well as belladonna, stramonium, and hyoscyamus; hyoscyamine; scopolamine; sausage and fish poisoning.
17. Urticaria or scarlatiniform erythema.	Atropine; hyoscyamine; antipyrin; quinine; balsam of copaiba; cubebene; chloral hydrate; iodin; morphine; and many internal remedies; handling of nettles (urtica).
18. Eczematous eruptions of the skin.	Croton oil; curcas oil; cardol; rhus toxicodendron; powdered cinchona bark; carbolic acid; tar.
19. Diffuse dermatitis, with perspiration of the hands.	Anilin colors; aurantia; chrysoidin; malachite green; Bismarck brown; annotto; anilin yellow.
20. Acne pustules.	Bromid; arsenical and antimonial preparations; powdered ipecacuanha.
21. Blisters containing clear serum on the skin, or even in the mouth.	Spanish fly; ranunculus acris; ranunculus sceleratus, etc.
22. Dark, dirty discoloration of the skin, which is not, however, cyanotic.	Argyria; mercurialism; saturnism; arsenical melanosis; bronzed diabetes.

SYMPTOMS OBSERVED IN CASES OF POISONING.

ACUTE SYMPTOMS :	THINK OF :
23. Bluish discoloration of the peripheral portions of the body [like those seen in Raynaud's disease].	Gangrenous ergotism; carbolism; phosphorism.
24. Cyanosis.	Nitrobenzol; benzokoll; anilin; toluidin; acetanilid; exalgin.
25. Yellowish-brown discoloration of the conjunctiva, alone or in combination with that of the skin.	Phosphorus; helvellic acid; potassium chlorate; nitroglycerin; sodium nitrite; amyl nitrite; pyrogallol; arseniuretted hydrogen; ictrogen [lupinotoxin], in animals. (In picric acid and picrates the discoloration is a pure yellow.)
26. Discoloration primarily of the tongue and the mucous membrane of the mouth.	Reddish yellow—chromic acid and the bichromates. Yellow—nitric and picric acid. Brown — iodine; bromine. Greenish-blue — salts of copper; Schweinfurth green. Whitish — corrosive alkalies; corrosive acids; corrosive metallic salts; carbolic acid.
27. Secondary discoloration of the gums.	Lead; silver; mercury; bismuth. [Augment, for diagnostic purposes, by the direct application of sulphuretted hydrogen gas to the gums.]
28. Specific odor to the breath.	(See pages 31 and 32.)
29. Coryza.	Iodine; bromine.
30. Salivation.	Pilocarpine; muscarine; arecaline; nicotine; cornutine; physostigmine; cytisine; mercury; ammonia; saponine [a glucoside contained in <i>Saponaia officinalis</i>]; cantharidin; caustics.
31. Metallic cough and aphonia.	Atropine; hyoscyamine; scopolamine; sausage poisoning.
32. Oedema of the glottis.	All caustic poisons.
33. Oedema of the lungs.	Morphine; muscarine; pilocarpine; ammonia; nitric acid vapors, etc.; inhalation during the swallowing of sublimate and other corrosive poisons.
34. Luminosity of the breath and vomitus.	Phosphorus.
35. Increased liver dulness.	Phosphorus; agaricus bulbosus; poley oil; alcohol.
36. Diarrhœa with vomiting.	Salts of antimony; arsenic; digitalin; pilocarpine; nicotine; muscarine; colchicine; corrosive poisons; salts of copper; zinc salts; colocynthis; emetine; cephaeline; croton oil, etc.

POST-MORTEM EXAMINATIONS

SYMPTOMS OBSERVED IN CASES OF POISONING

ACUTE SYMPTOMS	TRINK OF:
37 Vomiting without diarrhoea	Apomorphine, Tobelline, strychnine.
38 Colic with constipation	Lead salts.
39 Colic with diarrhoea	Barium salts.
40 Diarrhoea without vomiting	[2,4,7] podophylotoxin, croton oil, salomel, etc.
41 Pulse temporarily and markedly slowed	Opium, morphine, muscarine, arecoline, physostigmine, barbit. alkaloids.
42 Pulse paroxysmally and markedly slowed and thread-like	Lead salts but only during an attack of lead colic.
43 Pulse first slowed then irregularly accelerated	Digitalis, belladonna, atropine, scopolamine, cyanuric acid, strychnine, strychnine, pilocarpine, nicotine, scopalamine.
44 Pulse greatly accelerated	Belladonna, hyoscyamus, atropine.
45 Anorexia	Sarsaparilla, rue, mentha pulegium, phosphorus, ergot, lead.
46 1-24-hour period of good health between the poisoning and the appearance of the symptoms	Toxic of the poisonous fungi but especially <i>Amanita phalloides</i> ; also sometimes arsenic.

TABLE OF THE MOST STRIKING CHANGES WHICH TAKE PLACE IN THE URINE AFTER THE ADMINISTRATION OF THE MORE COMMON POISONS AND MEDICINES

URINARY CHANGES	TRINK OF:
1 Heavy and turbid	Mineral acids, acid salts of the metals.
2 Resinous strychnine alkaline	Toxic alkalies, alkaline carbonates, salts of organic acids with the exception of uric acid.
3 Odor like violets	Oil of turpentine and related etheral oils when employed medicinally.
4 Odor like garlic	Preparations of tellurium when employed medicinally.
5 Odor of methylmercaptan	Asparagus, sometimes used medicinally in the form of a syrup.
6 Odor of rotten eggs	Cystinuria, azoturia, or the disulphate of sodium has been taken medicinally in large doses.
7 Odor of ammonia	Ammoniaemia; cystitis caused by strong bases (and certain bacteria).
8 Chromatic crystals with acid urine	Uric acid, bismutate of potassium, oxalic, parabenic acid.
9 Leucocytes and epithelial casts	Damocyanin; potassium cyanuridate; virus of scarlet fever.
10 Yellow to yellowish-red color	Bilirubin and urobilin.

EFFECT OF POISONS UPON THE URINE.

URINARY CONDITION :	THINK OF :
11. Urine icteric brown.	Phosphorus, toluylendiamin; cephalanthine; icterogen.
12. Urine, reddish.	Senna leaves; rhubarb root; campecia wood (logwood); hæmatoxylin; fuchsin; pyramidon, ¹ antipyrin.
13. Urine colored wine-red by hæmatoporphyrin.	Sulphonal; trional; tetronal; lead (rarely).
14. Urine becomes scarlet upon putrefaction.	Santonin; santonica seeds; chenopodium.
15. Urine contains albumin and red blood-corpuscles.	All corrosive poisons.
16. Urine contains blood pigment in solution.	Arseniuretted hydrogen; helvella esculenta (helvellac acid); cyclamin; solanine; and other saponiferous substances.
17. Urine contains methæmoglobin.	Potassium chlorate; sodium nitrite; amyl nitrite; pyrogallol; chry-arobin; kairin; quinine.
18. Urine contains urobilin.	Lead.
19. Urine becomes black-green on exposure to the air.	Carbolic acid; cresol; lysol; creosote; guaiacol.
20. Urine is green when voided.	Methylen blue.
21. Urine on exposure to the air becomes blackish brown or even pure black.	Melanuria, associated with melanotic tumors and with hæmochromatosis. It may be produced artificially by injections of melanin.
22. Urine reduces Fehling's solution and gives off carbon dioxid with yeast.	Phloridzin; salts of uranium; curarine; hydrocyanic acid; atropine; amyl nitrite; chromates and bichromates; bichlorid of mercury; cantharidin.
23. Urine reduces Fehling's solution, but yields with yeast little or no carbon dioxid.	Chloral hydrate; menthol; thymol; many of the ethereal oils; carbon monoxid; chloroform; formic acid and formates; free oxalic acid; benzaldehyd; morphine.
24. Urine polarizes light to the <i>right</i> .	Phloridzin; salts of uranium; curarine; hydrocyanic acid; atropine; amyl nitrite; chromates and bichromates; bichlorid of mercury; cantharidin.
25. Urine polarizes light to the <i>left</i> .	Chloral hydrate; menthol; thymol; many of the ethereal oils.
26. Urine contains increased number of paired sulphuric acids and diminished number of sulphates.	Carbolic acid; cresol; lysol; creosote; guaiacol; kairin; antifebrin; anilin; paramidophenol.

¹ The red color of urine from pyramidon is due to rubazonic acid, which is soluble in chloroform.

EFFECT OF POISONS UPON THE URINE.

URINARY CONDITION :	THINK OF :
27. Urine contains leucin and tyrosin.	Phosphorus; acute yellow atrophy of liver; pellagra.
28. Few drops of the urine will dilate pupils of a cat's eye.	Atropine; hyoscyamine; scopolamine; cocaine; tropacocaine.
29. Few drops of the urine given to a frog cause tetanic convulsions.	Strychnine; nux vomica.
30. Few drops of the urine upon a culture of <i>Penicillium brevicaulis</i> give off an odor of garlic.	All combinations of arsenic, with the single exception of triphenylarsin. Selenium and tellurium compounds give a similar reaction, but different odors.
31. There is sometimes anuria present.	Oxalic acid; binoxalate of potassium; oxamid; cantharidin; bichlorid of mercury.
32. The urine is voided with strangury.	Pilocarpine; anilin dyes; cantharidin.
33. The urine is voided with difficulty on account of priapism.	Cantharidin; potassium cantharidate; <i>Gyrinus natator</i> .

ACIDS. — Poisoning may be produced by mineral and vegetable acids, the corrosive action depending largely upon the strength and properties of the acid at the time of its introduction into the body. Naturally those parts are most affected which remain longest in contact with the acid. The mucous membrane of the lips rarely escapes, and often the skin of the lower lip is discolored. The mucous membranes of the mouth, œsophagus, and stomach are acted upon, and œdema of the glottis is common. The tissues are softened; sometimes there is actual destruction followed by necrosis, which may lead to perforation. Around these areas of corrosion is a more or less marked hemorrhagic inflammation. If the acid was diluted, this inflammation is more marked and the corrosion less so. The blood in the external veins of the stomach is usually black. Acids neutralize to a large extent the alkalinity of the blood and thus produce disturbance in breathing and in the circulation. In all cases where death does not occur quickly, changes are seen in the parenchymatous organs, especially the kidneys. The color produced by different acids is somewhat characteristic. In carbolic acid poisoning the œsophagus is of a silver-gray color, the stomach is thrown into rugæ, and the mucosa is of a rough, brownish, cracked appearance. The urine may be dark in color and smell strongly of phenol. Gangrene of fingers may occur from the use of carbolic acid. In poisoning by sulphuric acid the mucous

membrane of the upper intestinal tract is brownish or even black, due to the extraction of water from the tissues and the action of this acid on the coloring matter of the blood. It is often difficult or impossible to say whether perforation occurred during life or after death. While putrefaction may occur in the stomach, other parts of the body may be preserved. The effects of hydrochloric acid are similar to those of sulphuric acid, but less marked, corrosive action on the skin being almost absent. The eschars are white, and the false membrane sloughs off, if life persists for some time. If death is delayed for twenty-four hours, there is fatty degeneration of the kidneys. The blood may be fluid or thickened. Nitric acid imparts to the skin and mucosa a yellowish tinge, owing to the formation of a xanthoprotein of picric acid. The stomach may be perforated. In oxalic acid and oxalate of potassium poisoning white to grayish corrosion of the upper intestinal tract occurs, crystals of oxalates of lime being found in the blood and kidneys. Concentrated acetic acid may also cause death.

ACONITE.—In aconite poisoning the physiologic test should always be applied. No characteristic lesions are found *post mortem*.

ALCOHOLISM.—There are no really characteristic lesions. I. *Gastro-intestinal Tract.*—(1) Chronic hypertrophic gastritis may be followed by (2) atrophic gastritis with dilatation. (3) Hypertrophic or atrophic cirrhosis of the liver. Orth says, "Most drinkers have no cirrhosis of the liver, but a fat liver, and many with liver cirrhosis are not drinkers of alcohol." II. *Vascular System.*—(1) The heart is usually enlarged and its muscle often thin, fatty, and friable. (2) The blood-vessels are frequently sclerosed, especially those arteries exposed to much strain. (3) The venules of the cheek and nose are often distended. III. *Central and Peripheral Nervous System.*—(1) The pia-arachnoid is thickened, with wasting of its convolutions. (2) The blood-vessels are thickened, tortuous, and may show miliary aneurisms. (3) The motor nerves of the muscles are sometimes altered (multiple neuritis). IV. *Genito-urinary Tract.*—(1) The kidneys are enlarged, cyanotic, and indurated. (2) The bladder is thickened and often shows signs of chronic cystitis. V. *Ductless Glands.*—Quervain¹ points out the destructive influence of alcohol on the thyroid gland, and accounts thereby for the spontaneous myxœdema sometimes seen in the children of alcoholics.

¹ *La semaine méd.*, 1905, vol. xxv, no. 44.

ALKALIES AND CAUSTIC SALTS.—Alkalies—potash, soda, and ammonia—act much the same as acids except that the involved areas are brown or black, due to changes in the blood, and are less brittle. The epithelium is shed in threads and there are ecchymotic folds of the mucosa. Capillary bronchitis is common, as the inhalation of ammonia causes intense congestion of the respiratory mucous membrane. Stricture of the œsophagus often results in patients who recover. In one of my cases cancer followed at the seat of stricture due to the accidental drinking of lye.

ANTIMONY.—Poisoning is usually due to tartar emetic. The mucous membrane from the mouth to the duodenum inclusive is usually inflamed, and often ulcerated and covered with stringy mucus. In chronic cases there is considerable emaciation; chemic tests will determine its true character. Klosowski employed antimony to murder three women; on exhumation their bodies were found to be preserved to a marked extent.

ARSENICAL POISONING.—This may be: (*a*) Acute. (*b*) Subacute. (*c*) Chronic. In acute arsenical poisoning there is generally a marked gastro-enteritis, which differs in severity according to the amount taken. The mucous membranes are intensely swollen, œdematous, and present small, emphysematous bullæ or diphtheritic exudation. Petechial eruptions may occur in both the stomach and intestines. The contents of the stomach are usually of a brownish color. In subacute arsenical poisoning or where large doses have been taken, patches varying in size from a dime to a silver dollar, consisting of an opaque, white, yellowish, or even violet coagulated lymph mixed with arsenous acid and firmly fixed to the mucous membrane, with signs of intense inflammation around them, may be found in the bowels. White spots of arsenic are sometimes discovered between the rugæ, and fatty degeneration of the intestinal epithelium and of the viscera is also present. Chronic arsenical poisoning is characterized by wide-spread fatty degeneration, affecting especially the heart, liver, spleen, and kidneys. Marked changes are also found in the voluntary muscles, which show wasting, fatty degeneration, and often cirrhosis. Trophic changes are common, such as overgrowth of hair and nails, both of which are harsh and brittle. In life the skin is harsh, dry, and frequently shows eruptions. Although arsenic is rapidly eliminated from the body, enough usually remains for purposes of identification. The urine should always be saved. The white material should be examined microscopically for the octahedral

crystals, and in England for soot and indigo, as the law there requires the retailing pharmacist to mix his arsenic previous to selling with one or the other of these substances. The cyanid of cacodyl, discovered by Cadet, appears to be one of the most poisonous compounds known. There are no characteristic lesions *post mortem*. It is a disputed question as to whether bodies keep a longer time after death in arsenical cases. The manifold ways in which arsenic may accidentally get into the system and thus cause death should always be remembered. From wall-paper it enters the system as dust and diethylarsin, due to the action of various moulds, such as the *Penicillium brevicaulis*. These organisms may, in turn, be used as the means of detecting arsenic by the odor evolved from the presence of minute traces. In England there were recently thousands of cases of arsenical poisoning, with many deaths, due to the drinking of beer made from glucose containing arsenic. The X-rays have been used to determine the presence of the crystals in an unopened stomach. Such a picture with the photomicrographs of portions used in making tests forms valuable evidence when produced in court during the giving of testimony. Gautier, a celebrated French chemist, claims, contrary to general belief, that arsenic is a normal weighable constituent of the thyroid gland. He also declares ¹ that one cubic kilometre of sea water contains three thousand kilogrammes of arsenic. The arsenic localizes especially in the ectodermic tissues and in the cells in the nature of nuclein and ferments. Rough-on-rats, which contains barium, and Paris green are favorite preparations with would-be suicides. In 1905 a number of valuable animals belonging to the New York Zoölogical Garden died from the effects of arsenical poisoning due to the eating of flies, an arsenical water having been freely used for the purpose of killing off these pests.

ATROPINE.—Fatal cases of atropine poisoning, either suicidal or homicidal, are rare, though accidental poisoning by the *Datura stramonium* is common. Death is caused by asphyxiation, the symptoms resembling those seen in heat-exhaustion. Careful search should be made in the stomach for any seeds, leaves, or berries.

BORIC ACID.—A crusade is now going on in the United States against the use of boric acid as a preservative for foodstuffs. In one of the cases tried in Philadelphia seven and a half grains of boric acid

¹ *Bull. de la soc. de chem. de Paris*, January 5, 1903.

were found in a quart of milk. Wiley has made some feeding experiments on a large scale and finds that the above amount cannot be taken for fifty days without the production in some cases of unfavorable results. Best¹ reports a fatal case of boric acid poisoning, and adds histories of three other cases from the literature on this subject.

CHLORAL HYDRATE.—Urine should always be reserved for chemic examination. Chloral is often taken with other drugs, as morphine, and after a debauch; this renders it difficult or even impossible to tell just what effect the chloral actually has had on the system. This is the drug which is so often used as "knock-out drops."

CHLOROFORM AND ETHER POISONING.—The saying of Tait, that the Coroner has to do with chloroform death, while the physician signs the death certificate in ether cases, is well known. Fright may have something to do with death in these cases. Signs of asphyxia are usually present and the characteristic odor is capable of determination. But although the anæsthetic may have been given, yet death may be due to other causes. It is much disputed how chloroform kills. If the heart be already weakened by fatty degeneration, it would seem as if death were due to a direct action upon this weakened organ. Otherwise it is due to paralysis of the central nervous system and direct action upon respiration. Idiosyncrasy would also seem to play an important part. Experimentally repeated inhalations of chloroform in dogs may produce hepatic cirrhosis.²

COCAINE POISONING.—At postmortem the heart is found in diastole and the nerve-centres are said to be congested. Cocaine should be tested for before making the diagnosis.

COPPER.—The lining walls of the stomach often have a bluish or greenish tinge. On the application of ammonia the coloration deepens into a darker shade of blue, or the green is converted into this color. Part of the toxic effect of the arsenite of copper is due to the copper. There is marked gastro-enteritis, with ulceration, necrosis of the mucosa, and at times perforation. Brouardel³ has written an interesting account of this form of poisoning, which was used formerly more frequently than it is now. Copper sulphate, when added to reservoirs in the proportion of 1 to 100,000, will rid the water of algæ. The

¹ *Jr. Amer. Med. Assoc.*, September 17, 1904, p. 805.

² HERTER and WILLIAMS, *Science*, November 17, 1905.

³ *La méd. mod.*, September 17, 1902, p. 305.

attempt to purify drinking water by adding 1 part to 1,000,000 of water must be considered a dangerous experiment, though cupric sulphate will kill typhoid bacilli in laboratory experiments when used in this strength. Zinc, tin, and barium salts may also cause death in an overdose.

ERGOT POISONING.—After death from ergot poisoning the arteries are found contracted and the abdominal viscera inflamed. In the chronic form the posterior columns of the cord are sclerosed and microscopic sections resemble those characteristic of locomotor ataxia. When given to chickens in sufficient quantities gangrene of the comb is produced.

FORMALDEHYD.—Bock¹ reports a case of poisoning by formalin in an imbecile twenty-six years of age. From one to three ounces of a four per cent. solution were taken. Death occurred thirty-two hours later. The stomach was necrotic, dark, tough, and leathery. Klüber,² Zorn,³ and Levison⁴ have also reported cases of poisoning by formalin. Formic acid will be found in the urine, the secretion of which may almost cease.

HYDROCYANIC ACID AND CYANID OF POTASSIUM POISONING.—The mucous membrane of the stomach is markedly and uniformly injected and congested. The odor of bitter almonds is detected at once on opening the abdomen. It should always be remembered that, if the post-mortem is not made for thirty-six hours after death, all the hydrocyanic acid may be converted into formic acid. The blood is dark and fluid and keeps for a long time without undergoing decomposition. There is formed a direct combination with the hæmoglobin (cyanmethæmoglobin), and death, when it ensues, comes on quickly, at times within several minutes; if the patient lives over an hour, recovery may be expected. Paralysis of the respiratory and circulatory systems occurs. (Ziegler.)

ILLUMINATING GAS AND CARBON MONOXID POISONING.—These two poisons are not quite alike in their action, though the poisonous properties of illuminating gas are largely due to the considerable amount of carbon monoxid which it contains, especially if of the variety known as "water gas." The body may appear quite life-like,

¹ *Fort Wayne Medical Journal Magazine*, July, 1899, p. 249.

² *Münch. med. Wchschr.*, October 9, 1900, p. 1416.

³ *Ibid.*, November 13, 1900, p. 1588.

⁴ *Jr. Amer. Med. Assoc.*, June 4, 1904, p. 1492.

with even a rosy hue upon the cheeks. After death the blood retains its bright cherry color for some time, especially in the brain, and when shaken forms a violet froth. All color reactions should be studied at once, before giving time for the oxygen of the air to act upon the blood. The skin and internal organs, as also the patches of post-mortem congestion, are bright red. The lungs are frequently congested, and afford a favorable place to detect the odor of illuminating gas. Carbon-monoxid hæmoglobin produces two absorption bands near *D* and *E* like oxyhæmoglobin, the latter, however, being reduced by the addition of the sulphid of ammonium. The blood should not be taken from the heart for this purpose, but from the smaller vessels in the muscles. It is well to remember that the spectroscopic test may even be secured several months after death in favorable circumstances. To detect a small quantity of carbon monoxid in the air of a room fresh normal blood is added to distilled water until the latter is faintly tinged; about five cubic centimetres are placed in a flask of some one hundred and fifty cubic centimetres' capacity and agitated several minutes in the suspected atmosphere; if the noxious gas be present, the liquid assumes a rose tint and gives the characteristic spectrum. Air is poisonous when it contains 0.02 per cent. of the gas. (Gruber.) In cases which live a day or so and then die bilateral softening may occur in the region of the inner capsule and the caudate and lenticular nuclei. The victim may die from a dose of some other poison taken with suicidal intent before turning on the gas.

IODIN POISONING.—In iodin poisoning the iodin is eliminated by the lungs as well as by the urine.

LEAD POISONING.—In acute lead poisoning there is marked gastroenteritis, and the bowels usually contain a large amount of blackish fluid. The kidneys show evidence of acute diffuse nephritis. In chronic lead poisoning the distinctive features are a marked fatty degeneration affecting the muscles, kidneys, spleen, and liver. There is often marked cirrhosis with atrophy of these organs. Arteriosclerosis with hypertrophy of the heart is also marked. Distinct gouty deposits are often found, particularly about the big toe. The brain is sometimes shrunken and dry, the blood-vessels being constricted; or these organs may be pale and extremely firm, or pale and œdematous, as in cases of uræmia. The small intestines may show areas of extreme contraction. For the detection of lead in urine and post-mortem specimens, the reader is referred to the *Lancet*, September 12, 1903, p. 746.

MERCURIAL POISONING.—The mucous membranes of the gastrointestinal tract, particularly the small intestine and colon, especially near the rectum, show extensive desquamation, with hyperæmia, ecchymoses, and grayish-white eschars. The bowel generally contains large quantities of a yellowish-brown or blood-stained liquid. The vagina may show gangrene or diphtheritic inflammation. The macroscopic appearances are those of dysentery if the patient survives several days. In some acute cases decalcification of the bones occurs, with a deposit of lime elsewhere in the body, especially in the kidneys. The number of mercurial salts is legion, many forming with albumin an insoluble albuminate of mercury. Chronic cases of poisoning occur, ulcerative stomatitis being one of the chief lesions. Sebillotte, in 1891, collected one hundred and forty-eight cases of poisoning from post-partum vaginal douches of bichlorid of mercury. He expressed his belief that the poison was not absorbed through the healthy mucous membrane, but through laceration of tissue due to the process of labor. Hamburger, however, has found that potassium iodid appeared in the urine in twenty-four hours when tampons of cotton saturated with this substance were placed in the healthy vagina, and potassium ferrocyanid or salicylic acid in three hours. H. C. Wood, Jr., reports a case of poisoning, exhibiting hæmaturia, resulting from the use of a douche containing 1 to 2000 of bichlorid of mercury.¹

METHYL ALCOHOL.—Blindness or impairment of vision may occur not only from the ingestion of wood alcohol, but also from inhalation of its fumes, as methyl alcohol seems to have a predilection for the retina and the optic nerve. A number of cases of fatal poisoning from this source have recently occurred throughout America. These have been tabulated by Buller, of Montreal, and Wood, of Chicago.²

NITROBENZOL POISONING.—Besides the odor of the artificial oil of bitter almonds, the blood and muscles are of a brownish color and the mucous membrane of the stomach is ecchymotic and injected. The body is cyanosed and of a leaden hue.

NUTMEG POISONING.—For a description of this rare but interesting form of poisoning, the reader is referred to Wallace's article in Vaughan's dedication volume of "Contributions to Medical Research." Grated nutmeg is used by some as an emmenagogue.

¹ *Amer. Med.*, December 27, 1902, p. 1006.

² *Jr. Amer. Med. Assoc.*, October 1, 8, 15, 22, and 29, 1904.

OPIUM POISONING.—In acute poisoning there is nothing to distinguish the condition of the brain from that in other cases of cerebral congestion. Extreme passive congestion of the bases of the lungs may take place, as in cerebral apoplexy (Osler). Cases of uncomplicated chronic poisoning are rare. The most important lesion is fatty degeneration of the heart. The liver may show similar changes. If laudanum has been used, the characteristic odor may be present. I know of no drug which is more apt to escape detection at the postmortem than morphine, as there are absolutely no characteristic lesions and chemic analyses are difficult and at times inaccurate. It seems strange that one of the most common and easily accessible poisons is thus so hard to detect. The pupillary reaction is of no value after death, and the clotting of blood in the right heart is by no means constant. The blood is usually darkened, and outside of the heart it is fluid. Many, if not all, of the chemic tests for morphine may be simulated by the effect of putrefactive bodies. Kippenberger's method is not considered reliable by Clift.¹ As morphine gives a beautiful color with formaldehyd, it is possible that the embalming of the body in a case of morphine poisoning might show the reaction and thus lead to the detection of the crime. Deléarde and Ricquiet insist on the importance of hydrolysis with hydrochloric acid to decompose a sulphonated morphine derivative formed in the body and of extracting the alkaloid with amylic alcohol.

PELLAGRA POISONING.—The lesions found are in the posterior columns and the crossed pyramidal tract. The cells in the anterior horn are deeply pigmented, and pigment is found in the internal organs and the skin. The brain presents general wasting; the ventricles are somewhat distended and contain an excess of fluid.

PHOSPHORUS POISONING.—In acute phosphorus poisoning the gastro-intestinal tract, especially in the stomach, shows an intense degree of inflammation. Hemorrhages are common and the stomach may contain grumous (coffee-ground) blood. The mucous membrane is the seat of numerous ecchymoses as well as more or less extensive necroses. The skin, the serous membranes, the muscles, and the adipose tissues all show numerous small hemorrhages. The blood is liquid and dark. The skin is jaundiced. The liver, in the early stages increased in size, soon—in from six to fourteen days—becomes small

¹*Jr. Amer. Med. Assoc.*, April 23, 1904.

(from one-half to one-third of the normal bulk), the capsule is wrinkled and shrunken, the color is pale yellowish, and on section the organ presents yellowish patches in the midst of which are scattered areas of deep congestion, giving an angiomaticous appearance to the organ; drops of fat are seen upon the knife. Hemorrhages may also be seen in the muscles, as of the thigh. The kidneys are large, their cortex pale, and the medullary portions congested. The epithelium often shows marked granular degeneration. As a rule, the spleen is not markedly altered. In chronic poisoning by phosphorus wide-spread fatty degeneration is the rule. In cases of workers in phosphorus having defective teeth, necrosis of the jaw is not uncommon. It is the yellow phosphorus that is poisonous, and not the red variety. Bug exterminators often contain phosphorus. The coating from the ends of matches is sometimes taken with suicidal intent.

PICROTOXIN.—Carel¹ gives the proceedings in three cases of homicidal poisoning by picrotoxin, derived from the cocculus indicus berries added to the liquor of half-drunken men for the purpose of robbery after the production of unconsciousness.

POTASSIUM CHLORATE POISONING.—The blood has the color and consistence of chocolate, the oxyhæmoglobin having been reduced to methæmoglobin. There is usually a hemorrhagic nephritis, especially of the glomeruli. Death may ensue in several hours.

PTOMAIN AND TOADSTOOL POISONING.—Such cases are of especial interest to the toxicologist, as the symptoms produced and the lesions found at the postmortem are similar to those caused by many alkaloidal and irritant poisons, and the possibility of the case under consideration in a trial being due to one or other of these substances is always suggested by the defence.

RICIN POISONING.—In dogs the eosinophile cells are increased in number. There is no marked positive degeneration of the liver, though the organ is congested and areas of necrosis are seen. In the kidneys the epithelial cells show degeneration.²

SILVER NITRATE POISONING.—I have been fortunate enough to see one case of this rare form of poisoning. The darkening of the necrosed mucous membrane on exposure to light was the chief diagnostic point. The child had an inspiration pneumonia.

¹ *Merck's Archives*, July, 1904.

² MÜLLER, *Ziegler's Beiträge*, vol. xxvii, p. 331.

SNAKE POISONING.—After death caused by cobra bite rigor mortis occurs as usual. The areolar tissue in the region of the bite is infiltrated with a pinkish fluid and the vessels are injected. The blood presents no demonstrable change. The veins of the pia mater are usually engorged, and the ventricles often contain turbid fluid. The lungs are generally congested and the lining of the bronchi injected. The appearance of the kidneys varies from normal to one of intense congestion. After death following the bite of an Australian snake the appearances are much the same as those just described. The blood may contain soft coagula, the lungs are sometimes the seat of hemorrhages, and the mucous membranes may be intensely congested and hemorrhagic. The blood-vessels of the central nervous system show engorgement. At autopsy, after the bite of a viperine snake, the region of the wound is seen to be the seat of intense cedema and extravasation of blood, and the underlying muscles are frequently disorganized and even diffluent from the latter cause. Hemorrhages may also be found in any of the organs and along the alimentary tract. The kidneys are acutely congested or hemorrhagic. The blood is fluid. Snake venom alone is not poisonous, but it takes a serum complement, like lecithin, to make it so. (Flexner and Noguchi.) Keyes¹ describes a method of preparing a pure crystalline compound of the toxin. The use of cryoscopy in this and other forms of poisoning may prove of value.

STRYCHNINE POISONING.—Rigor mortis is intense and persistent and the blood is dark and fluid as in asphyxia. Be sure to save the urine if any be present; a frog placed in it will have convulsions, even if but a small amount of strychnine be present. Marshall² reports the method of analysis used in a recent case with success.

TANNIN.—This substance, so useful as an antidote in various forms of poisoning, may itself produce violent diarrhoea and vomiting.

¹ *Berl. klin. Wchschr.*, 1903, nos. 42 and 43.

² *Amer. Med.*, June 18, 1904.

CHAPTER XXIX

THE PRUSSIAN REGULATIONS FOR THE PERFORMANCE OF AUTOPSIES IN MEDICOLEGAL CASES

THE Prussian regulations governing the performance of postmortems by the legally appointed officers of the Court are of great historic interest, as they bear the imprint of Virchow, and, though put in force February 13, 1875, are still observed throughout Prussia. These regulations also form the basis of similar statutes in other German states and in many countries throughout the world; indeed they are so well



FIG. 201.—Bronze medal of Rudolf Virchow; Virchow Jubilee, Berlin, 1892. (From one of the medals presented to the College of Physicians of Philadelphia, by S. Weir Mitchell, M. D. Reduced.)

defined that it is advisable, though one may chafe under their apparently unnecessary restrictions, to depart from them only in exceptional instances. This is especially the case if the one performing the autopsy is a beginner in medicolegal work.

I. GENERAL CONSIDERATIONS.

The Physicians making the Autopsy, and their Duties

§ 1. According to the present law, an examination of a corpse for medicolegal purposes may be made only in the presence of a magistrate by two practitioners, one of whom should be a state-appointed physician and the other a district surgeon. Upon those performing the autopsy devolve the duties of medicolegal experts. If doubt should arise in the technical performance of the autopsy, the physician or his deputy decides the question under consideration conditionally upon the right of the surgeon to state upon the protocol his dissenting opinion.

Substitutes

§ 2. The medical officers are permitted to appoint substitutes only when legitimately detained from the performance of their medicolegal duties. If possible, the deputy chosen is to be a physician who has passed his *pro physiatu* examination.

Time after Death at which the Post-mortem is to be performed

§ 3. As a rule, postmortems should not be performed until twenty-four hours after death; the mere inspection of a corpse, however, may be made earlier than this.

The Examination of Decomposed Bodies

§ 4. Generally, post-mortem examinations must not be neglected nor their performance refused by the legally appointed physicians because of the presence of decomposition, for even in a badly decomposed cadaver abnormalities and injuries to the bones may still be detected; many facts of value in the identification of a body may be ascertained, such as the color and appearance of the hair, the absence of limbs, etc.; and substances which have entered the body from without may be discovered, as well as pregnancy or poisoning proved. On the same grounds, when for one reason or another the advisability of disinterring a body is under consideration, the physicians are to approve of such exhumation without regard to the time which has elapsed since death.

Instruments

§ 5. The legally appointed physicians are to be careful to have the following instruments in readiness and in good condition: from four to six scalpels, of which the two smaller ones are to possess a straight and the two larger ones a rounded cutting edge; one razor; two strong cartilage-knives; two forceps; two double hooks; two pairs of scissors,—the stronger pair should have one blade pointed and the other rounded, while the smaller pair should possess one probe-pointed and one sharp-pointed blade; one enterotome; one injecting nozzle with stopcock; one coarse and two fine sounds; one saw; one chisel and one hammer; one costotome; six curved needles of different sizes; one pelvimeter; a one-metre rule divided into centimetres and millimetres; a measuring-glass divided into one hundred, fifty, and twenty-five cubic centimetres; one pair of scales capable of weighing up to ten pounds; one good magnifying-glass; blue and red litmus paper. The cutting instruments must be perfectly sharp. Those performing the postmortem are recommended to have ready for use a microscope with two objectives, so as to be able to magnify at least four hundred diameters, and the required instruments, glassware, and reagents necessary for the preparation of microscopic slides.

§ 6. A sufficiently large, well-lighted room is to be chosen for the autopsy, and all possible care is to be taken in the selection of a suitable place on which to lay the body and in the avoidance of all disturbing surroundings. Post-mortem examination by artificial light, except where postponement is impracticable, is not allowed; should it be done, the reason therefor must be expressly stated in the protocol (§ 27).

Place for the Autopsy and its Lighting

§ 7. If the body be frozen, it must be brought into a heated place and the autopsy postponed until the cadaver has sufficiently thawed; the employment of warm water or other warm articles to hasten the thawing process is forbidden.

Frozen Bodies

§ 8. If possible, when for any reason the body is moved, especially if transported from one place to another, there is to be no excessive pressure made upon any of the individual parts, nor any marked departure from the horizontal position of the organs in the larger cavities.

Transportation of Corpses

II. TECHNIC OF THE POSTMORTEM.

§ 9. Those performing the postmortem must hold steadfastly to the object in view, which is to make the investigation with accuracy and completeness. All important findings must be shown to the magistrate by the obducents before they are entered in the protocol.

Medicolegal Aspects of the Postmortem

§ 10. In those cases in which this appears to be necessary, the examiners are required, as early as feasible before the performance of the autopsy, to ask the magistrate for permission to visit the place where the body was found, and they are to ascertain the position in which the body was discovered and be given an opportunity to examine the clothing which the deceased wore at the time of death. As a rule, however, it is sufficient for them to await the solicitation of the magistrate to undertake these investigations. They are also obliged to ask for information from the magistrate in regard to any disclosures which might be of use to them in the performance of the autopsy or in helping them to make up their deductions therefrom.

Duties of the Obducents in regard to the Ascertainment of Special Circumstances connected with the Case under Investigation

§ 11. In cases in which a doubtful finding is to be quickly and definitely settled,—as, for example, the differentiation between blood and a fluid which is merely stained with hæmatin,—a microscopic examination is to be then and there undertaken. When circumstances render this impossible or when there are required difficult microscopic investigations which cannot be made at once,—as, for example, of certain tissues of the body,—portions of such tissue are to be preserved under legal protection and as quickly as possible thereafter to be thoroughly examined. It is to be distinctly stated in the report of such findings when the examinations were performed.

Microscopic Examinations

§ 12. The postmortem is divided into two main parts: A. External examination (inspection). B. Internal examination (section).

The Postmortem: its two main divisions

§ 13. In the external inspection of the body its appearance in general and that of its individual parts in particular are to be noted. In this general examination of the body the following points, in so far as possible, are to be brought out and recorded. 1. Sex; age;

External Examination

size; development; general condition of nutrition; any signs of previous illnesses,—*e.g.*, ulcers of the foot; special abnormalities,—*e.g.*, moles, scars, tattoo markings; supernumerary or absent limbs. 2. The signs of death and the changes that have already taken place from decomposition.

After removal by washing of any contaminations of the body in the way of blood, fæces, dirt, etc., record is to be made of the presence or absence of post-mortem rigidity; the general color of the skin of the corpse; the kind and degree of coloration and discoloration brought about by putrefaction; and the color, situation, and extent of any areas of hypostatic congestion, which are to be incised and then carefully examined and described, in order to prevent their being mistaken for extravasations of blood.

The following particulars are to be considered in the study of the individual parts. 1. In unidentified persons, the color and other appearances of the hair (head and beard), as well as the color of the eyes. 2. The possible presence of foreign substances in the normal openings of the head, the arrangement of the teeth, and the situation and appearance of the tongue. 3. An examination is next to be made of the neck, the breast, the abdomen, the back, the anus, the external genitalia, and finally of the limbs.

If an injury is found in any of these parts, its shape, situation, and direction with relation to fixed points of the body are to be described and the length and breadth of the injury given in the metric system. In solution of continuity of tissue, probing is, as a rule, to be avoided in the external inspection, because after the internal examination of the body and of the injured spot the extent of the injury becomes apparent. Should the obducents decide that the introduction of a sound is necessary, this procedure is to be done with great care, and special mention of the reason therefor is to be made in the protocol (§ 27). When wounds are present, a description of their borders and the adjacent tissues is to be given, and after such an examination and description of the lesions in their original condition the same are to be enlarged in order that the internal appearance of the borders and of the bottom may be disclosed. As to wounds and injuries which clearly did not conduce to, originate from, or have any connection with death,—for example, markings produced in the endeavor to restore life, gnawing by animals, and the like,—a summary description of the findings is sufficient.

Internal Examination;
General Considerations

§ 14. In the internal examination the three main cavities of the body—the cranial, the thoracic, and the abdominal—are to be opened. Opening of the vertebral column or of the individual joints is not to be omitted in cases where important findings might be secured thereby. When there is a definite suspicion as to the cause of death, the postmortem is to be commenced with that cavity in which the chief changes are suspected. Otherwise the head is to be examined first, the thorax next, and the abdominal cavity last.¹ The situation of the organs found in each of the above-named cavities is first to be determined, then the color and the appearance of the exposed surfaces. The presence is to be noted of any unusual contents, such as foreign bodies, gases, fluids, or clots, and in the last two cases measured and weighed, and finally each individual organ is to be examined externally and internally.

¹ As to autopsies on the new-born see §§ 23 and 24.

§ 15. When no injuries are present, the opening of the cranial cavity is accomplished by making an incision from one ear to the other directly over the skull, after which the skin-flaps are displaced forward and backward. (In case injuries are present, they should be as much as possible circumvented by the knife, thus giving rise to a different procedure.) As soon as the appearance of the soft parts and the surface of the bony cranium has been described, the latter is cut through with a saw by a circular incision, and the section, the inner table, and the other appearances of the calvarium are described. The external surface of the dura mater is next examined, the longitudinal sinus opened, and its contents estimated. The dura mater is then to be separated on one side and laid back, and the internal surface of the same described, as well as the appearance of the exposed pia mater. After this has been done on the opposite side, the brain is to be removed in as perfect a condition as possible, and the presence of abnormal contents in the skull is to be noted, and the appearance of the dura and pia mater at the base and sides of the skull and the condition of the large arteries are to be described. After the opening of the transverse sinuses (and, in case reason therefor exists, of the remaining sinuses), the size and shape of the brain are noted and an examination is made of its individual parts by means of a series of well-ordered incisions. Such parts include both cerebral hemispheres, the large ganglia (optic thalamus and corpus striatum), the corpora quadrigemina, the cerebellum, the pons Varolii, and the medulla oblongata, in the description of which are to be included especially the color, the fulness of the vessels, the consistency, and the structure. In addition, the tissue and the vessels of the choroid plexus are always to be described. The size and the contents of the different ventricles as well as the appearance and fulness of the different vascular plexuses in the individual sections of the brain are constantly to be kept in mind, and especial note is to be made of the presence of any clotted blood outside of the blood-vessels. The dura mater over the base of the skull and the sides is then to be removed and the condition of the bones in these regions described.

Cranial Cavity

§ 16. When it is required to open the internal portions of the face, to examine the parotid gland, or to inspect the auditory apparatus, the initial incision extending over the skull is continued behind the ear and down the neck, and the skin, for appearances' sake, is dissected away from beneath towards the part to be investigated. In this examination special attention is to be paid to the condition of the large arteries and veins.

Face, Parotid
Gland, and Ear

§ 17. The opening of the spinal column (§ 14) is usually made from behind, the skin and the subcutaneous fatty tissue being cut directly over the spinous processes and the musculature dissected away from the side of the latter and from the vertebral arches. During this examination hemorrhages, lacerations, and similar changes, especially fractures of bones, are to be carefully searched for. Then a chisel, or, if one is at hand, a vertebral saw (rhachiotome) is used for the purpose of separating the spinous processes with the adjacent portions of the arches throughout their entire extent. When they are removed, the external surface of the dura mater, which is now brought into view, is examined. It is next to be carefully opened by means of a longitudinal incision, and any abnormal contents, especially fluid or extravasated blood, are to be described, also the color, appearance, and similar characteristics of posterior portions of the pia mater, and by means of a gentle passage of the fingers over the spinal cord its degree of consistency is to be determined. Next, on both sides, by means of a

Spinal Column
and Cord

longitudinal incision the nerve-roots are cut through; then with one hand the lower end of the spinal cord is carefully grasped, and, after dividing the anterior attachments one after another, its upper end is finally drawn out of the occipital foramen. In all these proceedings special care should be taken not to make pressure on the spinal cord or to bend it. When the cord has been removed, the anterior surface of the pia mater is to be examined; next the external appearance of the cord as to size and color is to be described, and finally, by a considerable number of transverse incisions with a sharp and thin knife, the internal appearance of the spinal cord, both as to its white and its gray matter, is to be noted. Finally the dura mater of the vertebral bodies is to be removed, and they are to be examined in order to determine if there have been any hemorrhages, injuries, or changes in the bones or in the intervertebral discs.

Neck, Thoracic and
Abdominal Cavities;
General Considera-
tions

§ 18. The neck and the thoracic and abdominal cavities usually are opened by means of a single long incision from the chin to the pubic symphysis, passing to the left of the navel. Most commonly the incision in the abdomen is made deep enough to penetrate the abdominal cavity, care being taken to avoid injuring the organs contained therein. This is best begun by cutting a small nick in the peritoneum, at the same time observing whether any gas or fluid escapes. One finger is introduced into the opening and then another, the abdominal wall is elevated from the intestines, and the further opening of the peritoneum is made between the two fingers. The situation, the color, and other appearances of the intestines are to be immediately observed, as well as any abnormal contents within them, and the condition of the diaphragm is to be determined by palpation of its under surface.

The examination of the abdominal organs is to be proceeded with at this time only where a strong suspicion exists that the cause of death may be found within the abdomen (§ 14). As a general rule, the thorax is to be opened and inspected before any further scrutiny of the abdominal cavity is done.

Thoracic Cavity

§ 19. In opening the thoracic cavity the soft parts of the breast are dissected slightly beyond the junction of the osseous and cartilaginous portions of the ribs. Next with a strong knife the cartilages are incised a few millimetres within their attachment to the ribs, care being taken to avoid cutting the lungs or the heart. If the cartilages be ossified, the ribs are to be separated with a saw or a costotome somewhat beyond the cartilaginous junction. The attachments of both clavicles to the sternum are then separated by vertical semicircular sections, and the junction of the first rib, be it cartilaginous or ossified, is loosened with the knife or costotome, great care being taken to avoid injuring the vessels which lie beneath. The diaphragmatic attachments along the line of incision are severed close to the false cartilages and the ensiform process. The sternum is turned upward and the mediastinum is cut through, with careful avoidance of any injury to the pericardium or the large blood-vessels. When the sternum has been separated, the condition of the pleural cavity is to be determined, especially as to any abnormal contents, which are to be measured and their characteristics described; also the extent and the appearance of any portions of the lung which are in view. If any vessels have been injured in the removal of the breast-bone, they are to be tied or a sponge is to be placed beneath the bleeding points to catch the blood which if it were allowed to enter the pleura would later obscure the observation of the parts therein. The condition of the mediastinum and especially that of the thymus gland are to be noted, as well

as the appearance of the large blood-vessels lying outside of the pericardium, which are not yet incised. The pericardium is next to be opened and examined and the exterior of the heart inspected. Before the heart is incised or removed from the body its size, the filling of the coronary vessels and its individual cavities (auricles and ventricles), its color, and its consistency (*rigor mortis*) are to be estimated. While the organ is still in its natural position, the ventricles and auricles are to be separately opened and the contents of each chamber determined as to their amount, coagulation, and appearance, and the dimensions of the auriculoventricular openings are to be ascertained by the introduction of two fingers through the auricle. The heart is then to be removed from the body and the condition of the arterial vessels tested, first by filling them with water and next by incising their walls. Finally the color and exact appearance of the heart muscle are to be described. In every case wherein it is suspected that extensive changes—*e.g.*, fatty degeneration—have occurred in the muscular tissue a microscopic investigation is to be made. To this examination belongs that of the large vessels, with the single exception of the descending aorta, which is to be examined after the lungs have been excised. A minute inspection of the latter is not undertaken until they have been removed from the thoracic cavity. During this procedure great care is to be taken to avoid tearing or pressing upon the tissues. Should there be any extensive, especially old, adhesions, these are not to be broken down, but the attached pleura at this point is to be excised at the same time. When the lungs have been removed, their surface is again to be carefully examined for recent changes, so that nothing shall be overlooked,—for example, the commencement of inflammatory exudations; then the air contents, color, and consistency of the individual lobes are to be given. Finally large, smooth sections are to be made in order to determine the appearance of the cut surface and the air, blood, and fluid contents, as well as any solid contents of the air-vesicles, the condition of the bronchi and the pulmonary arteries, the latter being examined with special care to detect any obstructions, etc. For this purpose the air-passages and the large pulmonary vessels are to be opened with scissors and their finer ramifications followed out. When the suspicion arises that foreign materials are present in the air-passages or substances are therein found the nature of which cannot with certainty be determined by the naked eye, a microscopic examination is to be made.

§ 20. The examination of the neck may, according to the nature of the case, be made either before or after the opening of the Neck
thorax or the removal of the lungs. The obducents may also sever the larynx and the bronchus before the further inspection of the remaining parts when it seems to them especially desirable so to do, as is the case in drowning or hanging. As a rule, it is wise first to examine the large vessels and the nerve-trunks, then the larynx and trachea, by means of an anterior incision, and note their contents. If this observation should appear to be of especial importance, it is to be made before the removal of the lungs, which are at the same time to be carefully pressed upon to see if any fluid, etc., arises in the trachea. The larynx, the tongue, the velum palati, the pharynx, and the œsophagus are to be removed together; the individual parts are to be entirely opened and their contents and especially the mucosa thoroughly examined. At the same time the thyroid, the tonsils, the salivary glands, and the lymph glands of the neck are to be observed. In every case where injuries of the larynx or of the bronchus have been found or important changes therein are suspected, the air-passages are to be opened after their removal from the body and they are then to be examined from their posterior aspect. In cases of hanging or

in suspicious cases of strangulation the carotids are to be opened in order to ascertain whether or not their inner coats have been injured. This examination is to be undertaken while the vessels are still in their natural situation. Finally the condition of the cervical vertebræ and of the deep musculature is to be determined.

§ 21. The abdominal cavity and its viscera are now to be critically inspected in such order that the removal of one organ does not prevent the exact determination of its relations to another. Thus, the duodenum and the gall-ducts are to be examined before the scrutiny of the liver. As a rule, the following order of examination commends itself: 1. Omentum. 2. Spleen. 3. Kidneys and adrenals. 4. Bladder. 5. Organs of generation: in the male, prostate, seminal vesicles, testicles, and penis with the urethra; in the female, ovaries, Fallopian tubes, uterus, and vagina. 6. Rectum. 7. Duodenum and stomach. 8. Gall-ducts. 9. Liver. 10. Pancreas. 11. Mesentery. 12. Small intestine. 13. Large intestine. 14. The large blood-vessels in front of the vertebral column, whose condition as to blood contents is to be ascertained and noted.

Spleen In every case the spleen is examined in regard to its length, breadth, and thickness, not while held in the hand, but when placed on a solid surface and without pressure by the instrument used in measuring. It is to be divided throughout its entire length, more incisions being made in different directions if diseased areas are found.

Kidneys Each of the kidneys is to be removed after cutting vertically through the peritoneum externally and behind the ascending or descending colon, which is shoved back. The capsule is then incised longitudinally through its convex border and slowly peeled off, and the exposed surface of the kidney is examined in regard to size, form, color, condition of blood, and other appearances. Next a longitudinal incision is made through the entire kidney to its pelvis, and the cut surfaces are washed with water and described, in which description medullary and cortical substances, vessels, and parenchyma are to be distinguished.

Pelvic Organs The pelvic organs (bladder, rectum, and genitalia connected therewith) are removed preferably *en masse*, the bladder being opened and its contents examined while it is still in its natural situation. After their removal they are again inspected, the reproductive organs being examined and opened last. The slitting of the vagina is to precede that of the uterus. In puerperæ the venous and lymphatic vessels, both in the internal surface of the uterus and in its walls and adnexa, require special attention as to their width and contents.

Stomach and Duodenum When their external condition has been determined, the stomach and duodenum are with a pair of scissors opened in their natural situation, the duodenum on its anterior surface and the stomach along its greater curvature. After a careful inspection of their contents, the permeability and the presence of any matter in the opening of the gall-passages are determined and these parts are then removed for further examination.

Liver The liver is first described externally in its natural situation, and after its secretory ducts have been examined (as mentioned in the preceding paragraph) the gland is excised. Smooth incisions are now made through the entire length of the organ and its capacity for blood and the condition of the parenchyma determined. In the description a short account is always to be given of the general relations of the individual lobes, noting especially the condition of the inner and outer portions.




FIG. 202.—Method of carrying jars for a medicolegal postmortem. The jars on the right and left have the new form of clamp now in use. After cleansing, the jars, and the bag in which they are contained, are securely sealed.

The small and large intestines, after their individual portions have been examined externally as to dimensions, color, and other peculiarities worthy of mention, are removed together, their mesenteric attachments being severed with a knife close to the bowels, which are then opened with a pair of scissors at the place where the mesentery was attached. During these incisions the contents of the several parts are observed and described. Next the intestines are cleansed and the condition of the individual portions, especially of the small intestine, is inspected with special regard to the Peyer's patches, the solitary follicles, the villi, and the intestinal folds. At least in every case of inflammation of the peritoneum the appendix is to be carefully examined.

Small and Large
Intestines

§ 22. In those cases in which poisoning is suspected the internal examination is to begin with the abdominal cavity. Before anything else is done the external appearance of the upper abdominal viscera, their situation and extent, the filling of their vessels, and the presence of any odor are to be determined. In regard to the vessels, here as in other important organs, we are to ascertain whether we are dealing with arteries or veins, whether only the main trunks and their branches or the smaller ramifications also are filled to a given degree, and whether the extent of the vascular thinning is considerable or otherwise. Then to the portion of the œsophagus just above its entrance into the stomach and to the duodenum just below the entrance of the gall-duct double ligatures are to be applied and both parts incised between them. Next the stomach with the duodenum attached is carefully removed from the body and opened in the manner described in § 21. The contents are immediately examined as to their amount, consistency, color, composition, reaction, and odor, and placed in a clean porcelain or glass vessel. Then the mucosa is washed and its thickness, color, surface, and condition are determined, the state of the blood-vessels and the structure of the mucous membrane being particularly noted and each main portion separately described. Of especial importance is it to ascertain whether the blood which is present lies within the vessels or is exuded therefrom, whether it is fresh or changed by decomposition or by digestion, and whether in these conditions the neighboring tissues are permeated therewith. If such imbibition has occurred, it is to be noted whether it is found only upon the surface or in the tissue also, whether it is coagulated or not, etc. Finally it is of especial importance to decide, in the inspection of the surface, whether loss of substance, erosions, and ulcers are present. The question whether certain changes might not have resulted from natural processes of decomposition after death, especially from the action of the fermentative juices of the stomach, is always to be considered. After the completion of this examination, the stomach and duodenum are to be placed in the same vessel with the gastric contents (see above) and given to the magistrate for further investigation. An anatomic examination having been made of the œsophagus, it is tied high up in the neck, severed above the ligature, and placed in the same vessel. In those cases in which but a small amount of stomach contents is present the contents of the jejunum are also to be preserved. Finally other substances and portions of organs, as blood, urine, pieces of the liver and of the kidney, etc., are to be removed from the body and given to the magistrate for further examination. The urine is to be placed in a separate vessel, and the blood is to be preserved separately only in those cases where spectroscopic examination might disclose facts of interest. All of the remaining portions are to be placed together in a single receptacle. Each of these vessels is closed, sealed, and labelled. In every case where the macroscopic ex-

Cases of Poisoning

amination shows special alteration and swelling of the mucous membrane of the stomach, a microscopic examination thereof is to be made as soon as possible, especial attention being given to the condition of the peptic glands. Whenever suspicious bodies are found in the stomach contents, as portions of leaves or other parts of plants, remnants of animal food, etc., these also are to be viewed with a microscope. Where trichinosis is suspected, not only a microscopic examination of the contents of the stomach and of the upper portion of the small intestine is to be made, but portions of muscular tissue from the diaphragm, the neck, and the thorax are also to be laid aside for future study. (Fig. 202.)

The New-born ;
Determination of the
Maturity and Period
of Intra-uterine
Gestation

§ 23. In postmortems on the new-born, besides the points previously given, there are to be determined, first of all, the data upon which the maturity and the intra-uterine developmental period of the child depend. For these purposes consider the length and weight of the body, condition of the general coverings and of the umbilical cord, length and appearance of the hair of the head, size of the fontanel, longitudinal, transverse, and diagonal measurements of the head, appearance of the eyes (pupillary membrane), condition of the nasal and auricular cartilages, length and characteristics of the nails, transverse diameter of the shoulders and hips; in boys the condition of the testicles and the appearance of the scrotum, and in girls any peculiarities of the external genitalia. It still remains to be noted whether there be present, and if so to what extent, an ossifying centre in the inferior epiphysis of the femur. To determine this the patella is removed through a horizontal incision made just below it while the knee-joint is strongly flexed, and thin transverse sections are made continuously through the cartilage until the greatest transverse diameter of any centres of ossification which may there be present is found, which is then to be measured in millimetres. When from an examination of the offspring it seems to have been born before the thirtieth week, the postmortem may be discontinued unless a special request is given by the magistrate for its completion.

The Determination
as to whether or not
the Child has
breathed

§ 24. If it be determined that the child was born after the thirtieth week, the following data must be obtained in order to decide whether it breathed during or after birth. For this purpose the respiratory tests are to be applied in the following order: (a) Immediately after the opening of the abdominal cavity the condition of the diaphragm in relation to the corresponding ribs is to be determined. Hence in every case of examination of the new-born the abdominal cavity is to be opened first and afterwards the thoracic and cranial cavities.¹ (b) Before opening the thoracic cavity the trachea is to be once ligatured above the sternum. (c) The thoracic cavity is next to be opened and the extent and consequent situation of the lungs, the latter especially in regard to the pericardium, determined, and also the color and consistency. (d) The pericardium is to be incised and both its condition and the external appearance of the heart are to be described. (e) The individual cavities of the heart must be laid open, their contents noted, and other appearances determined. (f) The larynx and the portion of the trachea above the ligature are to be slit, and their contents as well as the appearance of their walls determined. (g) The trachea is to be cut through above the ligature and removed in connection with the other organs of the thorax. (h) After the removal of the thymus gland and

¹ But in no case shall section of the organs of the abdominal cavity be undertaken before the opening and examination of those of the thorax.

the heart, the lungs are to be tested as to whether or not they float in a large vessel filled with pure cold water. (*i*) The lower portion of the bronchus and its branches are to be opened and their contents specially examined. (*j*) Incisions are to be made into both lungs, the presence or absence of crepitation being carefully noted as well as the amount and appearance of any blood which may exude under slight pressure upon the cut surfaces. (*k*) The lungs are also to be incised under water in order to determine if any air-bubbles arise from the cut surfaces. (*l*) The lobes of both lungs are next to be cut apart, each lobe subdivided, and every separate portion tested as to its sinking or floating in water. (*m*) The œsophagus is to be opened and its condition ascertained. (*n*) Finally, in those cases where it is suspected that the pulmonary tissues may have been filled with the products of disease (hepatization) or with foreign bodies (vernix caseosa and meconium), so as not to permit of the entrance of air, the same are to be examined microscopically.

§ 25. Finally, it is the duty of the obducents to examine all organs not mentioned in these regulations in case injuries or other abnormalities are discovered. Further
Examinations

§ 26. The district surgeon, with the second physician acting as a consultant, is required, after the ending of the autopsy and as far as possible the removal of waste, to undertake the proper closure of those cavities of the body which have been opened. Closure of the Body

III. THE DRAWING UP OF THE PROTOCOL OF THE POSTMORTEM AND THE FINAL REPORT OF THE SAME.

§ 27. A post-mortem protocol is to be made by the magistrate, at the time and place of performing the autopsy, concerning all matters relating thereto. The medical officer must, therefore, be careful that the technical findings which have been determined at the examination are faithfully recorded in the protocol. In order to accomplish this, it is recommended to the magistrate that the description and findings of each individual organ be written down before another part is examined. The Post-mortem
Protocol

§ 28. The technical findings given in the post-mortem protocol by the medical officer must be stated clearly, definitely, and in such a manner as to be understood by one who is not a physician; for this purpose the use of foreign expressions is to be avoided except where these may be needed to make clear the description of the findings. The chief divisions, the external and internal examinations, are to be designated with capital letters (A and B). The findings for the openings in the cavities are to be given, in the order in which they were examined, with Roman numerals (I, II); but the organs in the thorax and abdominal cavity are to be entered under a single number. The descriptions of the organs of the thorax and abdominal cavity, named in § 18, are to be designated by the letters a and b. The results of the examination of each individual part are to be designated with Arabic numerals, such numbers running consecutively from the beginning to the end of the protocol. The record of the examination must be given in the protocol with special reference to the actual observations, and not in the form of mere statements of opinion,—as, for example, inflamed, gangrenous, healthy, normal, wound, ulcer, and the like. Arrangement and
Form of the Protocol

obducents have the option, however, in those cases in which it seems necessary for clearness, to add such observations, inclosed in parentheses. In every case a note must be made of the blood contents of each important part, and a short description thereof must be given, and not simply a name,—as considerable, moderate, middling amount, much reddened, rich in blood, poor in blood. Before any part is incised its size, form, color, and consistency are to be noted, in the order here named.

Provisional Opinion § 29. At the close of the postmortem the obducents are to give in the protocol their provisional opinion of the case, without stating their reasons therefor. If anything be known by means of which the diagnosis is influenced, in the way of previous history or the like, this must be briefly noted. Should the magistrate ask any special questions, the answers should be distinctly entered in the protocol, with the statement that they are given at his request. In every case the opinion as to the cause of death is to be stated, first with special reference to the facts bearing on the objective findings and then as to the question of criminal motive. If the cause of death is not determined, this fact must be recorded. It is never sufficient to say that death resulted from internal causes or from disease. The latter, whatever it is, must be specifically named. Special mention is to be made, with the reason therefor, in cases where further technical examinations are needed or where doubtful conditions exist.

Supplemental
Observations on
Instruments § 30. Should injuries be found on the body which were presumably the cause of death, and if suspicion be aroused that a specially discovered instrument might have inflicted such injuries, the obducents, at the request of the magistrate, are obliged to investigate and to express an opinion as to whether any and, if so, what injuries might have been caused by the instrument, and what conclusions from the situation and appearance of the wound are to be drawn as to the manner in which the one performing the act might have committed the deed, and also as to the strength with which it was performed. When definite weapons are not found, the obducents, as far as it is possible from the conditions present, are to give their opinion as to how the injuries were caused and especially as to what instruments might possibly have been used.

Post-mortem Report § 31. If the obducents be requested to present a report, this should be introduced without useless formalities by a condensed but exact review of the case, with the conclusion reached by them and the facts on which it is based. Then so much of the post-mortem protocol as they think necessary for the explanation of the case is to be given verbatim, with the number of the protocol. Any change made therein must be expressly stated. The style of the post-mortem report must be plain and concise, and the proof which led to the formation of the opinion therein expressed so set forth as to be understood by and convincing to one not a physician; for this purpose, the obducents are to use, as far as possible, German expressions and ordinarily accepted meanings. Especial attention to literary sources of knowledge is, as a rule, to be avoided. When as medical experts the obducents are asked certain questions by the magistrate, these are to be answered fully and as directly as possible, or, if this cannot be done, the reasons therefor are to be given.

Both obducents must sign their report, which must also bear the official seal of the district physician if he has taken part in the autopsy. When such a post-mortem account is requested, it must be delivered by the obducents within four weeks at the latest.

CHAPTER XXX

USUAL CAUSES OF DEATH: THEIR NOMENCLATURE, COMPLICATIONS, AND SYNONYMS

As morbidity and mortuary statistics are intimately associated the one with the other, uniformity in their nomenclature throughout the world is greatly to be desired. At the Eighth International Congress of Hygiene and Demography, held in Paris, August 18 to 21, 1900, a modification of the old Bertillon classification was adopted and called the "International System of Nomenclature of Diseases and Causes of Death."¹ It is here added but slightly altered in a few minor particulars as to the causes of death.

I. GENERAL DISEASES.

1. TYPHOID FEVER (Abdominal Typhus). *Include:* Dothienenteritis; mucous, continued, enteric, ataxic, or adynamic fever; abdominal typhus.—*Do not include:* Adynamia (179); ataxo-adynamia (179).—*Frequent complications:* Pneumonia; pulmonary congestion; intestinal perforation; peritonitis; intestinal hemorrhage; sloughing; albuminuria.
2. EXANTHEMATOUS TYPHUS.² *Include:* Petechial fever; petechial typhus.—*Do not include:* Abdominal typhus; typhus.
3. RELAPSING FEVER. *Include:* Recurrent fever; recurrent typhus.
4. INTERMITTENT FEVER AND MALARIAL CACHEXIA. *Include:* Paludal fever; pernicious fever; *accesso pernicioso*; remittent fever; malaria; ague; etc.
- 4a. MALARIAL CACHEXIA. *Include:* Paludism; pernicious cachexia, etc.
5. SMALLPOX. *Include:* Variola, varioloid.—*Do not include:* Varicella (19).—*Frequent complications:* Meningitis; endocarditis; suppuration; albuminuria.
6. MEASLES. *Include:* Eruption of measles; morbilli.—*Do not include:* Rubeola or German measles (19).—*Frequent complications:* Bronchitis; bronchopneumonia.
7. SCARLATINA. *Include:* Puerperal scarlatina; scarlatinous angina.—*Frequent complications:* Albuminuria; eclampsia; œdema of the glottis; hemorrhage; endocarditis; pericarditis; paralysis; convulsions; diphtheria.
8. WHOOPING COUGH (PERTUSSIS). *Frequent complications:* Bronchitis; spasms.
9. DIPHThERIA AND CROUP. *Include:* Diphtheritic, buffy, pseudomembranous, infectious, malignant, or toxic angina. Diphtheria under all its forms, especially diphtheria of wounds, cutaneous diphtheria; conjunctival diphtheria;

¹ Supplement to Public Health Reports, vol. xv, no. 49. Translated by Passed Assistant Surgeon H. D. GEDDINGS. WILLIAM A. KING, chief statistician of vital statistics of the United States Census, has added to this list the indefinite and unsatisfactory synonyms used for causes of death in the returns to the United States Census Office for 1890 and 1900. Washington, 1902.

² The word "typhus," without qualification, will be taken in the sense which is usual to it in each country,—viz., in the sense of "abdominal typhus" in German-speaking countries, or as "exanthematous typhus" in French-speaking ones.

- buccal diphtheria; pseudomembranous bronchitis; pseudomembranous laryngitis; malignant laryngitis; diphtheritic paralysis, etc.—*Do not include*: Stridulous croup (88); spasmodic croup (88); faise croup (88).—*Frequent complications*: Pneumonia; albuminuria; paralysis.
- 9a. DIPHTHERIA.
10. INFLUENZA. *Include*: Grippe; grippal pneumonia; grippal bronchitis; epizoötic; and grippal bronchopneumonia.
11. SWEATING OR MILIARY FEVER. *Include*: Sudor.
12. ASIATIC CHOLERA. *Include*: Indian cholera; cholera (when epidemic); epidemic cholera.
13. CHOLERA NOSTRAS.¹ *Include*: Sporadic cholera; cholérine; cholériform enteritis or diarrhœa; cholera (when not epidemic).—*Do not include*: Cholera infantum (105 or 106); antimonial cholera (175); hernial cholera (108).
14. DYSENTERY. *Include*: Cholériform dysentery; Chinese dysentery; dysentery of tropical countries.
- 14a. EPIDEMIC DYSENTERY.
15. BUBONIC PLAGUE (Plague or pest).
16. YELLOW FEVER. *Include*: Vomito negro; amarilla fever; black vomit.
17. LEPROSY. *Include*: Elephantiasis Græcorum.—*Do not include*: Elephantiasis Arabum (145d); Morvan's disease (63); syringomyelitis (63).
18. ERYSIPELAS. *Include*: All surgical erysipelas or medical erysipelas, without regard to seat; St. Anthony's fire.—It is disputed whether to classify gangrenous or phlegmonous erysipelas here or under 144.
19. OTHER EPIDEMIC AFFECTIONS.² *Include*: Mumps; rubeola; acrodynia; vari-cella; beriberi; and any other epidemic affections which may not be included in this nomenclature.—*Do not include*: Epidemic dysentery (14a); epidemic cerebrospinal meningitis (61).
20. PURULENT AND SEPTICÆMIC INFECTION.³ *Include*: Pyæmia; purulent absorption; putrid absorption; putrid infection; putrid fever; anatomic (dissection) wounds; streptococœmia.—*Do not include*: Puerperal septicæmia (137); infectious fever (55).
21. GLANDERS AND FARCY.
22. MALIGNANT PUSTULE. *Include*: Charbon; splenic fever. In France as 143.
23. RABIES. *Include*: Hydrophobia.—*Do not include*: Sitiophobia (68).
24. ACTINOMYCOSIS, TRICHINOSIS, ETC. *Include*: Dystoma hepaticum; cysticerci.—*Do not include*: Cyst or hydatid tumor of the liver (111) or of the lungs (99); intestinal parasites (107).
25. PELLAGRA.
26. TUBERCULOSIS OF THE LARYNX. *Include*: Tuberculous laryngitis; laryngeal phthisis.
27. TUBERCULOSIS OF THE LUNGS.⁴ *Include*: Pulmonary tuberculosis: pulmonary phthisis; phthisis (without qualification); phymia; phymatosis; pneumo-phymia; acute, galloping, or miliary phthisis or tuberculosis; pulmonary cavities; consumption; caseous pneumonia; tuberculous, bacillary, specific,

¹ The word "cholera morbus" will be taken in its ordinary signification in each country, as in the sense of "cholera nostras" in North America, and as "Asiatic cholera" in France and in other countries.

² In cases where epidemics arise, it will be necessary here to adopt a special provisional title.

³ When a female of childbearing age is returned as affected with "septicæmia," "sepsis," or any similar term, send the report back in order that the physician may state whether or not the disease was puerperal.

⁴ See observation on No. 93, relative to "apical pneumonia."

- granular, neoplastic, or heteroplastic bronchitis or pneumonia; bacillosis; tuberculous pleurisy; tuberculous hæmoptysis; tuberculosis (without qualification).—*Do not include*: Hæmoptysis (without qualification) (99); pulmonary hemorrhage (99); bronchorrhagia (without qualification) (99); apical pneumonia (93); laryngeal phthisis (26); pulmonary anthracosis (99).—*Frequent complications*: Hemorrhage; pneumonia; pleurisy; uncontrollable diarrhœa.
28. TUBERCULOSIS OF THE MENINGES. *Include*: Meningeal tuberculosis; tuberculous meningitis; granular, miliary, caseous, bacillary, specific, neoplastic or heteroplastic meningitis; tuberculous meningitis of spinal cord.—*Do not include*: Meningitis (without qualification), even for children of tender age (61).
29. ABDOMINAL TUBERCULOSIS. *Include*: Tuberculous, granular, bacillary, or specific peritonitis; peritoneal tuberculosis; tuberculous enteritis.
30. POTT'S DISEASE. *Include*: Vertebral caries; vertebral polyarthritis.—*Frequent complications*: Cold abscess, or abscess by congestion; paraplegia.
31. COLD ABSCESS (ABSCESS BY CONGESTION). *Include*: Ossifluent abscess.
32. WHITE SWELLING. *Include*: Fungous growths of joints; coxalgia; scapulargia; tuberculosis of joint.
33. OTHER TUBERCULOUS AFFECTIONS. *Include*: Tuberculosis of the skin, eye, bone, genital organs, etc.; tuberculous adenitis; lupus; esthiomene; bacillary abscess; tuberculous ulcer.—*Do not include*: Pott's disease (30).
34. GENERALIZED TUBERCULOSIS. *Include*: Tuberculosis showing itself simultaneously in any two or more organs. Often better placed under 27.
35. SCROFULA. (An unsatisfactory title.) *Include*: Struma; King's evil; lymphatism; scrofulides.—*Do not include*: Scrofulous or lymphatic keratitis and blepharitis (75).
36. SYPHILIS. Of which are recognized: (1) Primary, (2) secondary, (3) tertiary, (4) hereditary. These divisions are intended for mortuary statistics alone. *Include*: (1) Indurated or infecting chancre; chancre of the mouth or face; primary accident or infection; (2) Secondary manifestations—mucous plaques; syphilitic amygdalitis; angina or laryngitis; (3) Tertiary manifestations—specific manifestations; gummata; ulcerations; exostoses, etc. Osteocopic pains; all these diseases to be specified as "syphilitic."—*Do not include*: Soft, simple, or phagedenic chancre (36a).
- 36a. SOFT CHANCRE. *Include*: Chancroid; chancrelle; simple chancre; phagedenic chancre or bubo; bubo of soft chancre; venereal, virulent, or absorption buboes.—*Do not include*: Infecting or syphilitic chancre or bubo (36, 1); chancre of the mouth (36, 1); scrofulous bubo (35); suppurating bubo (144); plague bubo (15); bubo (without qualification) (144). (Morbidity statistics only.)
37. GONORRHEA (five years and over). *Include*: Blennorrhœa; ardor urinæ; urethritis; military drop; balanitis; balanorrhagia; balanoposthitis, vaginitis; gonorrhœal cystitis, orchitis, buboes, arthritis, rheumatism, or conjunctivitis of the adult; or gonorrhœal or blennorrhagic ophthalmia of the adult.—*Do not include*: Vaginismus (132); vaginalitis (126).—*Frequent complications*: Bubo; adenitis; cystitis; orchitis.
38. GONORRHŒAL AFFECTIONS OF THE CHILD.¹ *Include*: Blennorrhagic or gonorrhœal conjunctivitis of the child; gonorrhœal vulvitis, etc.

¹ This title takes account only of children under five years of age.

39. CANCER AND OTHER MALIGNANT TUMORS OF THE BUCCAL CAVITY. *Include:* Cancer of the mouth, lips, tongue, roof of the mouth, velum of palate, maxilla, jaw, parotid gland, and tonsil; sarcoma of soft palate; epithelioma, or carcinoma, or canceroid of these organs; smoker's cancer.
40. CANCER AND OTHER MALIGNANT TUMORS OF THE STOMACH AND LIVER.¹ *Include:* Cancer of the œsophagus; cancer of the cardia; cancer of the pylorus; carcinoma or scirrhus, or colloid or encephaloid tumor of these organs; gastrosarcoma; tumor of the stomach; scirrhus of liver or stomach; hepatic cancer.—*Do not include:* Hæmatemesis (104).
41. CANCER AND OTHER MALIGNANT TUMORS OF THE PERITONEUM, INTESTINES, AND RECTUM. *Include:* Cancer, carcinoma, scirrhus, encephaloid, canceroid, or epithelioma of the colon and anus; retroperitoneal sarcoma.
42. CANCER AND OTHER MALIGNANT TUMORS OF THE FEMALE GENITAL ORGANS. *Include:* Cancer of the uterus (womb), ovary, vagina, vulva; carcinoma, or encephaloid, or colloid tumor, or heteromorphous or neoplastic growth, or canceroid, or sarcoma, or epithelioma of these organs.
43. CANCER AND OTHER MALIGNANT TUMORS OF THE BREAST. *Include:* Carcinoma, or scirrhus, or encephaloid, or heteromorphous or neoplastic growth, or canceroid, or epithelioma of the breast or nipple.
44. CANCER AND OTHER MALIGNANT TUMORS OF THE SKIN. *Include:* Canceroid (without qualification); epithelioma or epitheliomatous tumor (without qualification); cancer of the ear, face, nose, or cervicofacial region; "nolime-tangere;" rodent ulcer.—*Do not include:* Esthiomene (33); lupus (33).
45. CANCER AND OTHER MALIGNANT TUMORS OF OTHER ORGANS, OR OF ORGANS NOT SPECIFIED. *Include:* Abdominal cancer; pelvic cancer; cancer of the lung, of the kidney, of the bladder, and of the prostate; cancerous goitre; thyrosarcoma; sarcohydrocele; cancer of the bone; osteosarcoma; cancerous or sarcomatous tumor of the neck; carcinoma, or scirrhus, or encephaloid, or cancerous ulcer, or malignant tumor, or sarcoma, or malignant fungus of these organs, or of other organs not specified; chimney sweeps' cancer; Lobstein's cancer; fungus hæmatodes; sarcoma of leg; lymphosarcoma, etc.—*Do not include:* Cancer of the œsophagus (40); cancer of the anus (41); cancer of the ovary, vagina, or vulva (42).
46. OTHER TUMORS (Tumors of the Female Genital Organs excepted). *Include:* Tumor (without qualification); abdominal tumor; intestinal tumor; vascular or erectile tumor; angioma; lymphoma; lymphadenoma; lymphatocele; adenoma; chondroma; osteoma; myoma; lipoma; wen; grub; sebaceous tumor; cystoma.—*Do not include:* Cancer and its synonyms (39-45); tumor of the stomach (40); stercoraceous tumor (108); tumor of the uterus (129); hydatid tumor (111); cyst of the ovary (131); aneurismal tumor (81); varicose tumor (83); polyp of the ear (76); polyp of the nasal or nasopharyngeal fossæ (87); uterine polyp (129); osteoma (146).
47. ACUTE ARTICULAR RHEUMATISM. *Include:* Rheumatic arthritis; rheumatic meningitis; abdominal or cerebral rheumatism; rheumatic vertigo; rheumatic endocarditis, pericarditis, pleurisy, peritonitis, etc.—*Do not include:* Organic heart disease of rheumatic origin (79); rheumatic iritis (75); arthritis deformans (48); gonorrhœal rheumatism (37 and 38).

¹ In countries where the words "organic lesion of the stomach" always signify "cancer of the stomach" classify these diagnoses under No. 40. In countries where, on the contrary, this is not always so, classify them under No. 104.

48. CHRONIC RHEUMATISM AND GOUT. *Include:* Arthritis deformans; articular rheumatism; Heberden's disease, podagra; rheumatic gout; rheumatism (unqualified).
49. SCURVY. *Include:* Scorbutus; Werlhoff's disease; Barlow's disease.
50. DIABETES. *Include:* Diabetes insipidus and mellitus; Hirschfeld's disease; diabetic gangrene and coma; glycosuria.—*Frequent complications:* Pneumonia; furunculosis; gangrene; cerebral hemorrhage and cerebral softening; tuberculosis.
51. EXOPHTHALMIC GOITRE. *Include:* Exophthalmia; Basedow's, Graves's, Parry's, Stokes's disease; exophthalmic cachexia.—*Frequent complications:* Hypertrophy of the heart; cachexia.
52. ADDISON'S DISEASE. *Include:* Adrenal disease.—*Freq. complic.:* Cachexia; ascites.
53. LEUKÆMIA. *Include:* Adenoleukæmia; leucocythæmia; Hodgkin's disease; pseudoleukæmia.—*Freq. complic.:* Hemorrhage; ascites; apoplexy; cachexia.
54. ANÆMIA; CHLOROSIS. The cause of the anæmia should always be given. *Include:* Pernicious anæmia.—*Do not include:* Cerebral anæmia (74b).
55. OTHER GENERAL DISEASES. *Include:* Auto-intoxication; infectious fever; virulent disease (without explanation); visceral steatosis; acromegalia; amyloid or generalized fatty degeneration; adiposis; obesity; polysarcia.
56. ALCOHOLISM, ACUTE OR CHRONIC. *Include:* Drunkenness; ethylism; alcoholic intoxication; alcoholic delirium; alcoholic dementia; delirium tremens; absinthism; absinthæmia; dipsomania; "mania-à-potu."—*Do not include:* Alcoholic cirrhosis (112); general alcoholic paralysis (67); atheroma (81); or any other disease attributable to alcohol; intoxication amblyopia (75).
57. SATURNISM. *Include:* Saturnine colic; lead colic; painter's colic; lead encephalopathia; lead paralysis; chronic lead poisoning; all conditions characterized as "saturnine."
58. OTHER TRADE OR OCCUPATION INTOXICATIONS. *Include:* Mercurial (hydrargyrisim); phosphorus, arsenical, or other intoxication, when special mention by the physician makes it clear that the intoxication is the result of a trade. Failing in this specific declaration, it should be classed in one of the conditions under 59.—*Do not include:* Alcoholism (56).
59. OTHER CHRONIC POISONINGS. *Include:* Morphinism; cocainism; chronic ergotism.—*Do not include:* Amblyopia from intoxication (75). Note the remark under 58.

II. DISEASES OF THE NERVOUS SYSTEM AND OF THE ORGANS OF SPECIAL SENSE.

60. ENCEPHALITIS. *Include:* Cerebral fever; phrenitis; poli-encephalitis.
61. SIMPLE MENINGITIS. *Include:* Meningitis (without qualification); meningoen- cephalitis; pachymeningitis.
- 61a. EPIDEMIC CEREBROSPINAL MENINGITIS. *Do not include:* Tuberculous meningitis (or other synonym) (28); rheumatic meningitis (47).
62. PROGRESSIVE LOCOMOTOR ATAXIA. *Include:* Duchenne's disease; posterior sclerosis; tabes dorsalis; cerebral ataxia; posterior spinal sclerosis; progressive ataxia; progressive spastic ataxia.
63. OTHER DISEASES OF THE SPINAL CORD. *Include:* Disease of the cord; sclerosis in plaques; symmetrical sclerosis; lateral sclerosis; sclerosis (without qualification); Charcot's disease; Morvan's disease; syringomyelitis; hemorrhage into the spinal cord; hæmatomyelitis; hæmatorrhachia; myelitis;

- medullary congestion; affections of the bulb; bulbar paralysis; spinal paralysis; paralysis agitans; trembling paralysis; ascending paralysis; essential paralysis of infancy; fatty or amyloid degeneration of the cord; Parkinson's disease; Friedreich's disease; medullary compression or compression of the cord; progressive muscular atrophy; fatty degeneration of muscle; atrophic muscular paralysis; amyotrophia; amyotrophic paralysis; atrophic paralysis; pseudohypertrophic paralysis, etc.
64. CEREBRAL CONGESTION AND HEMORRHAGE. *Include*: Apoplexy; cerebral apoplexy; meningeal apoplexy; serous apoplexy; cerebral atheroma; œdema of the brain; cerebral effusion; cerebellar hemorrhage; meningeal hemorrhage; cataplexia; apoplectic dementia; stroke (unqualified); clot on brain.—*Frequent complications*: Hemiplegia; paralysis.
65. CEREBRAL SOFTENING. *Do not include*: Senile dementia (154).—*Frequent complications*: Hemiplegia; paralysis; pulmonary congestion.
66. PARALYSIS WITHOUT SPECIFIED CAUSE. *Include*: Paralysis (without qualification); hemiplegia; facial paralysis; generalized paralysis (not insane or unqualified); palsy.—*Do not include*: Diphtheritic paralysis (9); atrophic muscular paralysis (63); general paralysis (67); paralytic cachexia (marasmus) (67); paralytic dementia (idiocy) (67); shaking (67) or trembling paralysis (63); bulbar paralysis (63); ascending paralysis (63); essential paralysis of infancy (63); labioglossolaryngeal paralysis (74b); paralysis of the velum palati (101); paralysis of the muscles of the eye (75).
67. GENERAL PARALYSIS. *Include*: Paralytic lunacy; paralytic dementia; paralytic cachexia; paralytic marasmus; diffuse meningo-encephalitis; diffuse peri-encephalitis.—*Do not include*: Generalized paralysis (not insane) (66).
68. OTHER FORMS OF MENTAL ALIENATION. *Include*: Dementia; lunacy; unsoundness of mind; hallucinations; mania; megalomania; monomania; delusions of persecution; melancholia; lypomania; nostalgia; insanity; nosophobia; necrophobia; sitiophobia; lycanthropy; homesickness; andromania; nymphomania; priapism; satyriasis; mental disease.—*Do not include*: Alcoholic dementia or delirium (56); delirium tremens (56); delirium (179); uræmic delirium (120); apoplectic dementia (64); paralytic dementia (67); choreic dementia (73); senile dementia (154); hysteria (74a).
69. EPILEPSY. *Include*: "Haut and petit mal;" disease of Hercules; fits; falling sickness.—*Do not include*: Epileptiform convulsions (70-71).
70. ECLAMPSIA (Non-puerperal).¹ *Include*: Epileptiform convulsions (of adults).—*Do not include*: Scarlatinous eclampsia (7); uræmic eclampsia (120); eclampsia of children under five years of age (71).
71. CONVULSIONS OF CHILDREN.² *Include*: Eclampsia of young children; contractures of children; spasms.—*Do not include*: Trismus nascentium (72).
72. TETANUS. *Include*: Opisthotonos; emprosthotonos; pleurosthotonos; trismus nascentium or neonatorum; lockjaw; idiopathic tetanus.
73. CHOREA. *Include*: Choreic dementia; Bergeron's disease; St. Vitus's dance.
74. HYSTERIA. *Include*: Hysterical anorexia; hysterical colic; all diseases classified as "hysterical." (Morbidity statistics alone.)
- 74a. NEURALGIA. *Include*: Tic dot lourenx; sciatica. (Morbidity statistics alone.)

¹ When a female of childbearing age is designated as having been stricken with "eclampsia," return the report to have the physician state whether or not the disease was puerperal.

² This title applies only to children under five years of age.

- 74b. OTHER DISEASES OF THE NERVOUS SYSTEM. *Include*: Cerebral compression; cerebral tumor; acquired hydrocephalus; neuroma; encephalopathia (without qualification); idiocy; imbecility; cretinism; gatism; amnesia; paramnesia; loss of speech; aphasia; nervous or cerebral accidents; cerebral anæmia; neurosis; tic; convulsive tic; contracture; anæsthesia (not due to external anæsthetic); neurasthenia; migraine; vertigo; somnambulism; catalepsy; boulimia; Landry's disease; symptomatic or Jacksonian epilepsy; athetosis; labioglossolaryngeal paralysis; amyloid or fatty degeneration of the nervous system, etc.—*Do not include*: Senile dementia, imbecility or senile gatism (154); syringomyelitis (63); myxœdema (89); congenital or undescribed hydrocephalus (150).
75. DISEASES OF THE EYE AND ITS ADNEXA. *Include*: Ophthalmia; foreign bodies; conjunctivitis (not including diphtheritic or gonorrhœal conjunctivitis); xerosis; pterygion; pinguecula; keratitis of every variety; staphylocoma; diseases of the cornea; arcus senilis; diseases of the sclerotic; diseases of the iris; iritis; diseases of the choroid; choroiditis; iridochoroiditis; sclerochoroiditis; glaucoma; diseases of the retina; retinitis; optic neuritis; amaurosis; amblyopia; amblyopia from intoxication; hemiopia; hemeralopia; nyctalopia; diseases of the lens; cataract; aphacia; parasites of the eye; ophthalmozoa; coloboma; strabismus; strabotomy; paralysis of the muscles of the eye; nystagmus; styes; chalazion; blepharitis; blepharoconjunctivitis; scrofulous blepharitis; blepharophimosis; blepharoplastia; ectropion; entropion; trichiasis; dacryoadenitis; diseases of the lachrymal gland and lachrymal sac; dacryocystitis; dacryolithiasis; dacryoma; lachrymal fistula; diseases and tumors of the orbit (undefined).—*Do not include*: Diphtheritic (9) or gonorrhœal (37-38) conjunctivitis; ocular cancer (45) or tuberculosis (33); exophthalmic goitre (51); exophthalmia (51). Many titles in 75 are never employed as causes of death.
- 75a. FOLLICULAR CONJUNCTIVITIS. (Morbidity statistics alone.)
- 75b. TRACHOMA. (Morbidity statistics alone.)
76. DISEASES OF THE EAR. *Include*: Otitis; otorrhœa; catarrh of the ear; hydrotitis; foreign body in the auditory canal; obstruction of the auditory canal; polyp of the ear; inflammation of the tympanum; "vertigo ab aure læso;" Ménière's disease, or vertigo; caries of the labyrinth (?); deafness; deaf-mutism.—*Do not include*: Mumps (19).

III. DISEASES OF THE CIRCULATORY APPARATUS.

77. PERICARDITIS. *Include*: Cardiopericarditis; hydropericarditis; hydropneumopericarditis; pericardial adhesions.—*Do not include*: Rheumatic pericarditis (47); endopericarditis (78); pleuropericarditis (94); pneumopericarditis (93).
78. ACUTE ENDOCARDITIS. *Include*: Endocarditis (without qualification); myocarditis, acute or without qualification; endopericarditis.—*Do not include*: Rheumatic endocarditis (47), or the other cardiac accidents which may supervene in the course of an attack of rheumatism.
79. ORGANIC DISEASES OF THE HEART. *Include*: Aortic, mitral, tricuspid, or cardiac affection or lesion; cardiac or valvular insufficiency or stenosis of the valves of the heart; cardiac cachexia; hypertrophy of the heart; dilatation of the heart; cardiectasis; steatosis of the heart; degeneration of the heart; cardiopathy; cardiosclerosis; cardiovascular sclerosis; cardiomalacia; cardiostenosis; labored heart; tachycardia; rupture of the heart; cardi-

- rhæxia; cardiac palpitation; asystole; cardiac asthma.—*Do not include:* Cardiac accidents (undetermined) (86); persistence or patency of the foramen of Botallo (150).—*Frequent complications:* Dropsy; bronchitis and pneumonia; albuminuria; embolism; thrombosis.
80. ANGINA PECTORIS. *Include:* Cardialgia; sternalgia; neuralgia of the heart.
81. AFFECTIONS OF THE ARTERIES, ATHEROMA, ANEURISM, ETC. *Include:* Arteritis; fatty degeneration of arteries; arteriosclerosis; atheroma of arteries; arteriectasis; aortic ectasis; Hodgson's disease; atresia of the pulmonary artery; aortitis; aneurismal tumor.—*Do not include:* Aortic affection (79).
82. EMBOLISM AND THROMBOSIS. *Include:* Thrombosis (without qualification); phlegmasia alba dolens (non-*puerperal*); embolic pneumonia.—*Do not include:* Embolism (*puerperal*) (140).
83. AFFECTIONS OF THE VEINS (Varices, Hemorrhoids, Phlebitis, etc.). *Include:* Pneumophlebitis; varicose ulcer; varicocele.—*Do not include:* *Puerperal* phlebitis (137); vascular or erectile tumor (46); angioma (46).
84. AFFECTIONS OF THE LYMPHATIC SYSTEM. *Include:* Angioleucitis; adenopathy; lymphangitis; adenitis.—*Do not include:* Suppurative adenitis (144); adenophlegmon (144); leukæmic adenitis (53); lymphatism (35); bubo (36a and 144); adenoma (46); lymphoma (46); lymphadenoma (46).
85. HEMORRHAGES. *Include:* Hemorrhage (without qualification); internal hemorrhage; hæmophilia; epistaxis; stomatorrhagia; cutaneous hemorrhage; purpura hæmorrhagica.—*Do not include:* Cerebral hemorrhage (64); cerebellar hemorrhage (64); meningeal hemorrhage (64); pulmonary hemorrhage (99); hæmoptysis (99); hæmatemesis (104); intestinal hemorrhage (109); hæmaturia (121); uterine hemorrhage (135 or 128, depending on whether it is or is not *puerperal*); metrorrhagia (128 or 135); umbilical hemorrhage (under three months) (152); traumatic hemorrhage (166).
86. OTHER AFFECTIONS OF THE CIRCULATORY APPARATUS. *Include:* Cardiac accidents (undetermined); angiectasis; angiectopia; affections of the great vessels; permanently slow pulse.—*Do not include:* Vascular nævus (150).

IV. DISEASES OF THE RESPIRATORY APPARATUS.

87. DISEASES OF THE NASAL FOSSÆ. *Include:* Coryza; cold; polypus of the nasal or nasopharyngeal fossa; ozæna; abscess of the nasal fossa; adenoid vegetations.—*Do not include:* Epistaxis (85); syphilitic coryza (36).
88. AFFECTIONS OF THE LARYNX. *Include:* Acute, chronic, erysipelatous, œdematous, phlegmonous, or stridulous laryngitis; aphonia; loss of voice; false croup; spasmodic croup; stridulous croup; œdema of the glottis; spasm of the glottis; polypus of the larynx; stricture of the larynx; laryngotomy.—*Do not include:* Tuberculous laryngitis (26); laryngeal tuberculosis (26); croup (9); diphtheritic laryngitis and its synonyms (9); foreign bodies in the larynx (176).
89. AFFECTIONS OF THE THYROID BODY. *Include:* Goitre; thyrocele; myxœdema; pachydermic cachexia.—*Do not include:* Exophthalmic goitre (51).
90. BRONCHITIS, ACUTE.¹ *Include:* Capillary bronchitis; tracheitis; tracheobronchitis; broncho-alveolitis.—*Do not include:* Bronchopneumonia (92); specific bronchitis or other synonym of pulmonary tuberculosis (see 27); fetid bronchitis (96); summer bronchitis (99).

¹ See note on No. 91.

91. BRONCHITIS, CHRONIC.¹ *Include:* Mucous bronchitis (pituitous); catarrh (without qualification); bronchial, pituitous, pulmonary, or suffocating catarrh; bronchorrhœa; dilatation of the bronchi; bronchiectasis.—*Do not include:* Fetid bronchitis (96); tuberculous bronchitis (27).
92. BRONCHOPNEUMONIA. *Include:* Catarrhal, deglutition, and aspiration pneumonia.—*Do not include:* Capillary bronchitis (90).
93. PNEUMONIA.² *Include:* Croupous pneumonia; fluxion of the lung; pleuropneumonia; pneumopleurisy; splenopneumonia; apical pneumonia; peripneumonia; pneumopericarditis; typhoid and alcoholic pneumonia.—*Do not include:* Caseous pneumonia (27); specific, bacillary, or any synonym of pulmonary tuberculosis (27); pulmonary congestion (95).
94. PLEURISY. *Include:* Pleuropericarditis; pleuritic or thoracic effusion; pneumothorax; hydropneumothorax; pyothorax; pleural vomica; pneumopyothorax; hæmothorax; thoracentesis; empyema; pleural adhesions.—*Do not include:* Pleurodynia (99).
95. PULMONARY CONGESTION AND PULMONARY APOPLEXY. *Include:* Œdema of the lungs; hypostatic pneumonia.
96. GANGRENE OF THE LUNG. *Include:* Fetid bronchitis; mortification of lung.
97. ASTHMA. *Do not include:* Cardiac asthma (79); suffocating catarrh (91); hay fever (99).
98. EMPHYSEMA OF THE LUNGS. *Include:* Emphysema (without qualification).—*Do not include:* Subcutaneous emphysema (145).
99. OTHER DISEASES OF THE RESPIRATORY APPARATUS (Phthisis excepted). *Include:* Tracheostenosis; pleurodynia; pneumopathy; hydatids of the lung; pulmonary calculus; abscess of the lung; pulmonary anthracosis; interstitial pneumonia; cirrhosis of the lung; secondary sclerosis; hay fever (summer bronchitis or catarrh). To be also included when their nature is not indicated: Organic lesion of the lung; pulmonary accidents; hæmoptysis; spitting of blood; pulmonary hemorrhage; pneumorrhagia; bronchorrhagia; tracheotomy.—*Do not include:* Cancer of the lung (45).

V. DISEASES OF THE DIGESTIVE APPARATUS.

100. AFFECTIONS OF THE MOUTH AND ITS ADNEXA. *Include:* Diseases of the gums; epulis; gingivitis; ulorrhagia; glossitis; diseases of the tongue (except cancer); parotid tumor; parotiditis; salivary fistula; ranula; thrush; diseases of the teeth; odontalgia; dental caries; staphylitis; staphyloplasty; staphylorrhaphy.—*Do not include:* Cancer of the lips or tongue (39); chancre of the mouth (36a); noma (142); mumps (19); gangrene of the mouth (142); diseases of the palate (36 or 146); fracture of the maxilla (164); necrosis of the maxilla (146); paralysis of the velum palati (101).
101. AFFECTIONS OF THE PHARYNX. *Include:* Angina or Ludwig's disease; anginas of all varieties (except diphtheritic angina and its symptoms; see Diphtheria, No. 9); amygdalitis; quinsy; abscess of the fauces, throat, or

¹ Return to the physician the reports given in as "bronchitis," in order that he may specify acute or chronic. When the physician fails thus to answer, classify under No. 90 all reports relating to children under five years of age, and under No. 91 all reports as to those of greater age.

² In countries where "apical pneumonia" is always synonymous with "phthisis," class this diagnosis under No. 27. In countries, on the contrary, where this is not constant, class under No. 93.

- retropharynx; paralysis of the velum palati; elongation of the uvula; pharyngitis; tonsillitis.—*Do not include*: Angina pectoris (80); cardiac angina (80); scarlatinal angina (7).
102. AFFECTIONS OF THE ŒSOPHAGUS. *Include*: Foreign bodies in the œsophagus; wound of the œsophagus; stricture of the œsophagus (except from cancer); spasm of the œsophagus; œsophagotomy.—*Do not include*: Cancer of the œsophagus (40); syphilitic stricture of the œsophagus (36).
103. ULCER OF THE STOMACH. *Include*: Round ulcer.—*Frequent complications*: Hæmatemesis; perforations of the stomach; peritonitis.
104. OTHER AFFECTIONS OF THE STOMACH (Cancer excepted).¹ *Include*: Dilatation of the stomach; paresis of the stomach; dyspepsia; aepsia; gastritis; gastrohepatitis; foreign body in the stomach; gastrotomy; perforation of the stomach (non-traumatic); gastralgia; "vertigo a stomacho læso;" catarrh of the stomach; indigestion. To be also included when their nature is not indicated: Gastrorrhagia; hæmatemesis; gastric hemorrhage.—*Do not include*: Gastro-enteritis (105 or 106, according to age).
105. DIARRHŒA AND ENTERITIS (under two years). *Include*: Gastro-enteritis or gastrocolitis of children; infantile enteritis; cholera infantum; athrepsia. This title only considers these ailments in children under two years.
- 105a. DIARRHŒA AND ENTERITIS, CHRONIC (under two years). *Include*: Athrepsia.
106. DIARRHŒA AND ENTERITIS (two years and over). *Include*: Gastro-enteritis or gastrocolitis of adults; enteritis of adults; diarrhœa of adults; lien-enteritis; intestinal ulcerations; colitis; intestinal colic; flatulent colic; inflammatory colic. *Do not include*: Tuberculous enteritis (29).
107. INTESTINAL PARASITES. *Include*: Helminthæ; oxyuri; tæniæ, of all kinds; solitary worm; ascaris lumbricoides; trematodes; trichocephalus; anchylostomes; colic from worms.
108. HERNIAS AND INTESTINAL OBSTRUCTIONS. *Include*: Internal strangulation; intestinal invagination; stercoral tumors; ileus; intestinal occlusion; volvulus; hernial colic; hernial gangrene. The following to be included when their nature is not specified: Merocele; sarco-epiplocele; sarco-epiplomphalitis; kelotomy; herniotomy; artificial anus; stercoraceous vomiting.—*Do not include*: Laparotomy (without other qualification) (46 and 179).—*Frequent complication*: Peritonitis.
109. OTHER AFFECTIONS OF THE INTESTINES. *Include*: Paralysis or paresis of the intestine; enteroptosis; constipation; stercoræmia; intestinal calculi; intestinal perforation; foreign bodies in the intestine or rectum; rectitis. Include also the following diseases when their nature is not indicated, and these operations when their cause is not specified: Enterotomy; artificial anus; enterorrhagia; intestinal hemorrhage; melæna; prolapse of the rectum; stricture of the rectum.—*Do not include*: Stercoral tumor (108); intestinal invagination and its synonyms (108); typhlitis and appendicitis (118); perityphlitis (118).
- 109a. DISEASES OF THE ANUS AND FECAL FISTULAS. *Include*: Proctitis; periproctitis; proctoceles; proctoptosis; fissure of the anus; abscess of the margin of the anus; fistula of the anus, either fecal or rectovaginal.—*Do not include*: Urinary fistulæ, even when these involve the rectum (124); artificial anus (108) (morbidity statistics alone); unnatural anus (108); imperforate anus (150). (For morbidity statistics alone.)

¹ See observation under No. 40 as to "organic lesion of the stomach."

110. ACUTE YELLOW ATROPHY OF THE LIVER. *Include:* Pernicious icterus; parenchymatous hepatitis; Weil's disease.—*Do not include:* Icterus (without qualification) (114); chronic icterus (114); icterus of the new-born (under three months) (151).
111. HYDATID TUMORS OF THE LIVER. *Include:* Hydatid cyst; hydatids (without qualification); echinococci.
112. CIRRHOSIS OF THE LIVER. *Include:* Cirrhosis (without qualification); alcoholic cirrhosis; interstitial cirrhosis; biliary cirrhosis: amyloid or fatty degeneration of the liver; slow atrophy of the liver: steatosis of the liver; alcoholic, interstitial, or chronic hepatitis.—*Do not include:* Organic lesion of the liver (114); hypertrophy of the liver (114).—*Frequent complications:* Dropsy; hemorrhage; pneumonia; tuberculosis.
113. BILIARY CALCULI. *Include:* Hepatic calculi; biliary lithiasis; hepatic colic.
114. OTHER AFFECTIONS OF THE LIVER. *Include:* Abscess of the liver; hepatitis; hepatitis, acute; angiocholitis; cholecystitis; hepatocystitis; choluria. To be also included when their precise nature is not indicated: Organic lesion of the liver; tumor of the liver; hypertrophy of the liver; acholia; cholemia; icterus (over three months); chronic icterus; jaundice; hepatic congestion.—*Do not include:* Acute yellow atrophy of the liver (110); icterus of the new-born (151).
115. AFFECTIONS OF THE SPLEEN. *Include:* Splenitis; splenopathia; megalosplenism; splenocele.—*Do not include:* The affections of the spleen due to leukemia (53) or malaria (4).
116. PERITONITIS, SIMPLE (Puerperal excepted).¹ *Include:* Peritonitis (without qualification); peritonitis, chronic; peritoneal adhesions; epiploitis; metroperitonitis, pelviperitonitis.—*Do not include:* Tuberculous peritonitis (29); cancer of the peritoneum (41); puerperal peritonitis (137); rheumatic peritonitis (47).
117. OTHER AFFECTIONS OF THE DIGESTIVE APPARATUS (Cancer and Tuberculosis excepted). *Include:* Diseases of the pancreas (cancer excepted).
118. APPENDICITIS AND ABSCESS OF THE ILIAC FOSSA. *Include:* Iliac phlegmon or abscess; typhlitis; perityphlitis; typhlocliditis; appendicitis.—*Do not include:* Pelvic (130) or periuterine abscess; pelvic suppuration (130).
- VI. DISEASES OF THE GENITO-URINARY APPARATUS AND ITS ADNEXA (NOT INCLUDING VENEREAL DISEASES).
119. NEPHRITIS, ACUTE. *Do not include:* Scarlatinous nephritis (7); chronic nephritis (120); tuberculous nephritis (33); nephritis of pregnancy (138).
120. BRIGHT'S DISEASE. *Include:* Chronic, albuminous, interstitial, or parenchymatous nephritis; albuminuria; amyloid or fatty degeneration of the kidney; amyloid kidney; steatosis of the kidney; renal sclerosis. To be included when their precise nature is not indicated: Uræmia; uræmic eclampsia; uræmic delirium; uræmic coma.—*Do not include:* Organic lesion of the kidney (121); puerperal uræmia (138); cardiac albuminuria (79).—*Frequent complications:* Anasarca; dropsy; convulsions; hemorrhages; cerebral apoplexy; pneumonia.

¹When a female of childbearing age is returned as having been stricken with "peritonitis," with out other explanation, the report should be returned in order that the physician may specify whether or not the condition was puerperal.

121. OTHER DISEASES OF THE KIDNEYS AND THEIR ADNEXA. *Include:* Pyelitis; anuria; renal congestion; renal ectopia; nephroptosis; floating, motile, or displaced kidney; movable kidney; renal cysts; polycystic kidney; hydro-nephrosis; hæmaturia; perinephritis; perinephritic and nephritic abscess; pyelonephritis; nephropyosis. To be also included when their nature is not specified: Organic lesion of the kidney; nephrorrhagia.
122. CALCULI OF THE URINARY TRACT. *Include:* Renal, ureteral, nephritic, vesical, or urinary calculus; nephritic colic; nephrolithiasis; gravel; stone; calculous affections; urinary lithiasis; lithotripsy; lithoclasty.—*Do not include:* Prostatic calculus (125).
123. DISEASES OF THE BLADDER. *Include:* Cystitis, acute or chronic vesical or ureteral catarrh; cystorrhagia; tumor of the bladder; cystocele; cystoptosis; foreign body in the bladder; cystotomy; retention of urine; dysuria; paralysis and section of bladder; vesical inertia; incontinence of urine; tenesmus of the bladder.—*Do not include:* Hæmaturia (121); urinary fistulæ, even when they involve the bladder (124); cystosarcoma (45).
124. DISEASES OF THE URETHRA. *Include:* Urinary abscess, etc.; ankylourethria; foreign bodies; urethrotomy; urinary fistula (urethral, urethrorectal, vesicorectal, or vesicometrorectal); urinary infiltration; urinary intoxication; urethralgia; urethrorrhagia; urinæmia; stricture of the urethra; urethrostenosis; urethroplasty; urethrorrhaphy; stricture (male).—*Do not include:* Ureteral catarrh (123); retention of urine (123).
125. DISEASES OF THE PROSTATE. *Include:* Hypertrophy of the prostate; prostatitis; abscess of the prostate; prostatic calculus.—*Do not include:* Cancer of the prostate (45); tuberculosis of the prostate (33).
126. NON-VENEREAL DISEASES OF THE GENITAL ORGANS OF THE MALE. *Include:* Phimosi; paraphimosi; amputation of the penis; seminal losses; spermatorrhœa; orchitis; epididymitis; funiculitis; hydrocele; hæmatocele of the testicle, cord, or scrotum; castration (in man); Malassez's disease.—*Do not include:* Cancer of the testicle (45); tuberculosis of the testicle (33); sarcohydrocele (45); syphilitic sarcocele (36); varicocele (83).
127. METRITIS (non-puerperal or unqualified). *Include:* Ulcer of the uterus; ulceration of the neck (of the womb); endometritis.
128. UTERINE HEMORRHAGE, NON-PUERPERAL. *Include:* Metrorrhagia; menorrhagia; tamponage of the vagina or uterus.
129. UTERINE TUMOR (not cancerous). *Include:* Fibroid tumor, or fibroid of body of the uterus; hysteromyoma; uterine polypus; fungous or fungoid tumors of the uterus; Huguier's disease.
130. OTHER DISEASES OF THE UTERUS. *Include:* Procidencia of uterus; uterine or vaginal catarrh; deviation, anteflexion, retroflexion, anteversion, falling or prolapse of the uterus; prolapse of the vagina; uterine prolongation; amenorrhœa; hypertrophy of the neck of the uterus; dysmenorrhœa; organic lesion of the uterus; hysterectomy; hysterotomy; metrotony; ablation of the uterus; abscess of the pelvis; periuterine or retro-uterine abscess or phlegmon; pelvic suppuration; leucorrhœa; fluor albus (whites; vaginal flow; white flux).—*Do not include:* Puerperal diseases (134 and 141); abscess of the iliac fossa (118).
131. CYSTS AND OTHER TUMORS OF THE OVARY. *Include:* Ovariectomy; castration (in the female). Dermoid cyst often classified better here than under 146.

132. OTHER DISEASES OF THE GENITAL ORGANS OF THE FEMALE. *Include:* Vaginitis; tumors of the vagina; ovaritis; salpingitis; salpinx; metrosalpingitis; hæmatosalpinx; pyosalpinx; abscess and tumors of the vulvovaginal glands; vulvitis; periuterine or retro-uterine hæmatocele.—*Do not include:* Urinary fistulæ (124); stercoral fistulæ (109a); even when they involve the genital organs. King makes a subheading of "Diseases of tubes."
133. NON-PUERPERAL DISEASES OF THE BREAST (Cancer excepted). *Include:* Mastitis; abscess of the breast (non-puerperal); cyst of the breast; cystic disease of Réclus; tumor of the breast (without qualification, or non-cancerous); amputation of the breast.—*Do not include:* Fistula of the breast (puerperal, or without qualification) (43); mammary cancer (43).

VII. THE PUERPERAL STATE.

REMARKS.—It often happens that physicians neglect to note the puerperal character of the disease; hence the following rule for the guidance of those whose duty it is to collect statistics. "Whenever a female of childbearing age is noted as dead from a disease which *may* be puerperal, the report should be returned to the reporter, in order that he may state explicitly whether or not the disease was puerperal." The following are these diseases: Peritonitis; pelviperitonitis; metropertonitis; septicæmia; hemorrhage; metrorrhagia; eclampsia; phlegmasia alba dolens; phlebitis; lymphangeitis; embolism; sudden death; abscess of the breast.

134. ACCIDENTS OF PREGNANCY. *Include:* Miscarriage (death of mother); abortion (death of mother); hemorrhage of pregnancy; incoercible vomiting; rupture of tubal pregnancy; ablation of the pregnant tube; difficulties and fatigues supervening in the course of pregnancy.
- 134a. LABOR, NORMAL. (Morbidity statistics only.)
135. PUERPERAL HEMORRHAGE. *Include:* Puerperal metrorrhagia; post-partum hemorrhage.
136. OTHER ACCIDENTS OF LABOR. *Include:* Dystocia; Cæsarean section; rupture of the uterus; metrorrhæxia; laceration or rupture of the perineum; perineorrhaphy; placenta prævia; malposition, retention, detachment, or apoplexy of the placenta; cephalotripsy; embryotomy (adult); symphyseotomy; version; application of forceps; uterine inversion.
137. PUERPERAL SEPTICÆMIA. *Include:* Puerperal fever; puerperal infection; puerperal endometritis; puerperal salpingitis; perimetrosalpingitis, or phlegmon of the broad ligament, or diffuse pelvic puerperal cellulitis; puerperal peritonitis, metropertonitis, phlebitis, lymphangeitis, or pyæmia.—*Do not include:* Septicæmia (without qualification) (20).
138. PUERPERAL ALBUMINURIA AND ECLAMPSIA. *Include:* Puerperal uræmia; nephritis of pregnancy; eclampsia of women in labor; epileptiform convulsions of women in labor; puerperal tetanus.
139. PHLEGMASIA ALBA DOLENS, PUERPERAL. *Do not include:* Phlegmasia alba dolens, non-puerperal (82).—*Frequent complications:* Gangrene; embolism.
140. OTHER PUERPERAL ACCIDENTS; SUDDEN DEATH. *Include:* Puerperal embolism; puerperal thrombus; sudden death in the puerperium; consequence of labor (without other explanation); subinvolution of uterus.—*Do not include:* Sudden death, non-puerperal (178); puerperal scarlatina (7).
141. PUERPERAL DISEASES OF THE BREAST. *Include:* Fissure of the nipple (puerperal); circumscribed abscess; abscess of the breast (puerperal); fistula of the breast (puerperal or without further indication).

VIII. DISEASES OF THE SKIN AND CELLULAR TISSUE.

142. GANGRENE. *Include*: Eschar; sphacelus; gangrene, dry; gangrene, senile; gangrene of the extremities; gangrene of the mouth; gangrene of the vulva, etc.; noma; Raynaud's disease.—*Do not include*: Gangrene of the lung (96); hernial gangrene (108); gangrenous erysipelas (18 or 144).
143. FURUNCLE (Carbuncle).¹ *Not included*: Biskra, Aleppo, or Medina button (145).
144. PHLEGMON; WARM ABSCESS. *Include*: Abscess (without qualification); phlegmonous tumor; adenophlegmon; suppurative adenitis; bubo (without qualification); suppurating bubo; diffuse phlegmon; phlegmonous or gangrenous erysipelas; panaris; whitlow; abscess of the mediastinum; vomica (without any modification).—*Do not include*: Bacillary abscess (33); abscess of the fauces, throat, or retropharynx (101); of the liver (114); of the iliac fossa (118); of the female pelvis (130); of the prostate (125); urinary (124); periuterine (130); of breast, non-puerperal (130); cold (31); by congestion (31); ossifluent (31); angioleucitis (84).
145. TINEA FAVUS. (Morbidity statistics alone.)
- 145a. TINEA TONSURANS, TRICHOPHYTON. *Include*: Tinea (without qualification). (Morbidity statistics alone.)
- 145b. PELADES. (Morbidity statistics alone.)
- 145c. ITCH. (Morbidity statistics alone.)
- 145d. OTHER DISEASES OF THE SKIN AND ITS ADNEXA. *Include*: Erythema; urticaria; prurigo; pityriasis; lichen; psoriasis; dermatitis; eczema; impetigo; aphtha; herpes; ecthyma; elephantiasis Arabum; pachydermatitis; polysarcia; scleroderma; keloids; fungoid mycosis; seborrhœa; trophoneuroses; zona; Wardrop's disease; Biskra, Aleppo, or Medina button; Pendjeh ulcer; Cochinchina ulcer; pemphigus; myiasis.—*Do not include*: Pachydermatous cachexia (89); elephantiasis Græcorum (17).

IX. DISEASES OF THE ORGANS OF LOCOMOTION.

146. AFFECTIONS OF THE BONES (Non-tuberculous). *Include*: Periostitis; periostosis; osteitis; osteoperiostitis; osteomyelitis; caries; necrosis; sequestrum; perforation of the palatine vault; necrosis of the maxilla (non-phosphoric or without qualification); exostosis (without qualification); osteoma; osseous tumor; cranial tumor; foreign bodies in the frontal or other sinuses; mastoiditis; abscess of the frontal or maxillary sinus; osteomalacia; softening of bone; rhachitis; scoliosis; lordosis; kyphosis.—*Do not include*: Caries of the petrous bone (76); dental caries (100); osteocopic pains (36); osteosarcoma (45); phosphorus necrosis (58).
147. ARTHRITIS AND OTHER DISEASES OF THE JOINTS (Tuberculosis and Rheumatism excepted). *Include*: Arthritis; polyarthritis (non-vertebral); hydrarthrosis; foreign bodies in joints; arthrodynia; arthroyposis; arthrophytis; ankylosis; arthralgia; arthrocele; genu valgum.—*Do not include*: Rheumatic arthritis (47).
148. AMPUTATION.² *Include*: Only those cases in which the lesion, the cause for amputation, is not specified.—*Do not include*: Amputation of the breast

¹ See No 22.

² Amputation, surgical operation, shock, and surgical shock, unqualified, are not sufficiently specific terms as causes of death.

(133); amputation of the penis (126).—*Frequent complications*: Septicæmia; erysipelas; tetanus; hemorrhage.

149. OTHER AFFECTIONS OF THE ORGANS OF LOCOMOTION. *Include*: Hygroma; perichondritis; disarticulation; tarsalgia; painful talipes valgus; retraction of the fingers or of the palmar aponeurosis; Dupuytren's disease; non-traumatic muscular rupture; muscular diastasis; myodiastasis; non-traumatic rupture of a tendon; diseases of tendons; tenophytes; tenosynovitis; tenotomy; tenorrhaphy; torticollis; lumbago; curvature.

X. MALFORMATIONS.

150. MALFORMATIONS (Stillbirths not included). *Include*: Malformation; monstrosity; anomaly; arrest of development; congenital hydrocephalus; hydrocephalus (without qualification); megalocephalus; hydrorrhachia; spina bifida; encephalocele; podencephalia; congenital eventration; omphalocele; exomphalos; ectopia; imperforate anus, etc.; harelip; cleft palate; anaspidias; hypospidias; cryptorchid; vascular nævus; polydactylia; syndactylia; congenital club-foot; talipes valgus, varus, or equinus, congenital; congenital deafness or blindness; persistence of the foramen of Botallo (foramen ovale).—*Do not include*: Coloboma (75); painful flat-foot (149); acquired hydrocephalus (74b); tuberculous hydrocephalus (28). King makes a separate subheading for hydrocephalus and cyanosis.

XI. EARLY INFANCY.

- 150a. THE NEW-BORN AND NURSINGS DEPARTING FROM HOSPITALS WITHOUT HAVING BEEN SICK. (Morbidity statistics alone.)
151. CONGENITAL DEBILITY, ICTERUS, AND SCLEREMA. *Include*: Premature birth (not stillborn); atrophy (infantile); icterus or hepatitis of the new-born; atelectasis of the lungs in the new-born; œdema of the new-born.
152. OTHER DISEASES OF EARLY INFANCY. *Include*: Umbilical hemorrhage; inflammation of the umbilicus; cyanosis of the new-born. (This title has reference to children not more than three months old.)
153. LACK OF CARE.

XII. OLD AGE.

154. SENILE DEBILITY. *Include*: Senility; old age; cachexia (of the old); senile exhaustion; senile dementia.—*Do not include*: Senile gangrene (142).

XIII. AFFECTIONS PRODUCED BY EXTERNAL CAUSES.

Among suicides there should only be classed those in whom suicide or attempted suicide is clearly demonstrated. In collective suicides there should only be counted those who have attained their majority. Minors ought to be regarded as the victims of assassination and placed under 176.

155. SUICIDE BY POISON. *Include*: Voluntary poisoning; voluntary absorption of sulphuric acid (or any other corrosive substance).—*Do not include*: Cocainism (59); morphinism (59).
156. SUICIDE BY ASPHYXIA. *Include*: Suicide by the vapor of charcoal.
157. SUICIDE BY HANGING OR STRANGULATION. *Include*: Legal executions.
158. SUICIDE BY DROWNING.

159. SUICIDE BY FIREARMS.
160. SUICIDE BY CUTTING INSTRUMENTS.
161. SUICIDE BY JUMPING FROM HIGH PLACES.
162. SUICIDE BY CRUSHING.
163. OTHER SUICIDES.
164. FRACTURES. *Include:* Separation of the epiphyses; fracture of the cranium.
165. SPRAINS. *Include:* Strains; ligament-stretching. (Morbidity statistics only.)
- 165a. LUXATIONS. *Include:* Subluxations; dislocations.
166. OTHER ACCIDENTAL TRAUMATISMS. *Include:* Stabs; contusion; bites (non-venomous, non-virulent); crushing; railroad accidents (suicide excepted); wounds by cutting instruments (suicide not demonstrated); accidental falls; concussion of the brain; perforation of the cranium; traumatic hemorrhage; traumatic fever; traumatic eventration; perforation of the abdomen or chest; all acute affections designated as "traumatic;" wounds by firearms. King subdivides into: accidental gunshot wounds; injuries by machinery; injuries in mines and quarries; railroad accidents and injuries; injuries by horses and vehicles; and other accidental traumatism.
167. BURNS AND SCALDS. *Include:* Burns and scalds from steam, petroleum, gasoline, boiling liquid, etc.—*Do not include:* Conflagration (174).
168. BURNS FROM CORROSIVE SUBSTANCES. *Include:* Burns by vitriol.
169. INSOLATION. *Include:* Sunstroke.
170. FREEZING. *Do not include:* Effects of cold (new-born) (153).
171. ELECTRIC SHOCK. *Include:* Death from lightning.
172. ACCIDENTAL SUBMERSION. *Include:* Drowning (non-suicidal).
173. PROSTRATION. *Include:* Fatigue. (Morbidity statistics alone.)
- 173a. INANITION. *Include:* Hunger; insufficient food (new-born excepted); misery.—*Do not include:* Lack of care (new-born) (153); lack of nutrition (new-born) (153); sitiophobia (68); hysterical anorexia (74a).
174. ABSORPTION OF DELETERIOUS GASES (Suicide excepted). *Include:* Asphyxia, accidental (pathologic asphyxia and suicidal asphyxia excepted); asphyxia by illuminating gas; asphyxia by stoves (fixed or portable); absorption of carbonic oxid; conflagration; absorption of ammonium sulphid; asphyxia by night-soil; absorption of chloroform; absorption of nitrous oxid.—*Do not include:* Asphyxia of the adult (without qualification) (179); asphyxia (under three months) (152).
175. OTHER ACUTE POISONINGS. *Include:* Every acute poisoning (suicide excepted); antimony cholera; acute ergotism; absorption of venom; bite of serpent; accidental absorption of sulphuric acid or other corrosive substances.—*Do not include:* Saturnism (57); hydrargyrisms, etc. (58 or 59), morphinism, chronic ergotism, etc. (59).
176. OTHER EXTERNAL VIOLENCE. *Include:* Accident (without other qualification); bad treatment (of a child); capital punishment; foreign body in the larynx; foreign body in the trachea. King subdivides into: Suffocation; injuries at birth; homicide; and other external violence.

XIV. ILL-DEFINED DISEASES.

The following titles will include only those conditions ill-defined by the physician, whether from lack of sufficient data, or because the disease was ill-defined, or because the physician was negligent in making a complete diagnosis.

- 177. DROPSY. *Include:* Anasarca; ascites; œdema of the extremities or generalized œdema; organic lesion (not defined).—*Do not include:* Œdema of the new-born (151); œdema of the glottis (88); œdema of the lungs (95); œdema of the brain (64).
- 178. SUDDEN DEATH. *Include:* Syncope (followed by death).—*Do not include:* Puerperal sudden death (140), or sudden death followed by an explanation, as "diabetic" (50) or "apoplectic" (64).
- 179. ILL-DEFINED OR UNSPECIFIED CAUSES OF DEATH. *Include:* Exhaustion or cachexia or debility (of adults); asthenia; adynamia; ataxo-adynamia; coma; asthenic, hectic, colliquative, synochal, gastric, bilious, or pituita fever; gastric involvement; fever of dentition; paralysis of the heart (in German "herzlahmung" or "herzschlag," in English "heart failure"); cyanotic asphyxia (without indicated cause, the new-born excepted); or any other insufficient diagnosis.—*Do not include:* Exhaustion, cachexia or debility of the old (154); fever, ataxo-adynamic (1), continued (1), summer, or hay (99); asphyxia by external cause (156 or 174); cyanosis of the new-born (152).
- 180. STILLBIRTHS. Stillbirths are not included among deaths, as a stillborn child is one born dead. Nevertheless, it is wise to have a separate heading for them, including under congenital debility (151) and unknown (179) cases where the child lived after birth and a cause of death cannot be assigned.

The following death certificate is used in duplicate in Pennsylvania.

RETURN OF A DEATH

IN THE CITY, TOWN, OR TOWNSHIP OF.....

Physician's Certificate

1. Full Name of Deceased,

2. Color, State if { Chinese, Japanese, Indian. }

3. Sex,

4. Single, Married, State if { Widow, Widower, Divorced. }

5. Age, { Years,
 Months,
 Days, } 6. Date of Death, { Year,
 Month,
 Day, }

(If age is less than one day, give hours.....) Duration,

7. Cause of Death, { Chief, Mos., Days,
 Contributing, Mos., Days, }

No Certificate will be accepted which is **MUTILATED, ILLEGIBLE, INACCURATE,** or any portion of which has been **ERASED, INTERLINED, CORRECTED,** or **ALTERED,** as all such changes impair its value as a Public Record.

This Certificate must not be issued for any other purpose than as a report to the Board of Health. Should the Physician issue a duplicate, it must be distinctly marked "Duplicate," and state why issued.

..... M. D.
 Residence,

The new record for Philadelphia for 1906 adds:

I HEREBY CERTIFY that I attended deceased from 190.... to 190...., that I last saw h... alive on 190...., and that death occurred on the date above at m.

Write plainly, and with ink; fill in every blank space.

CHAPTER XXXI

REFERENCES UPON POST-MORTEM TECHNIC

THE elaborate list of references pertaining to post-mortem technic and medicolegal autopsies, published in the second (1905) edition of this work, has been omitted in the present instance. The literature upon these subjects has, however, been revised to date, and the author will be glad to enter into correspondence with those desiring information in regard to this matter, or, indeed, upon any other subject coming within the scope of this book. Virchow's work, "*Die Sectionstechnik im Leichenhause des Charitè Krankenhauses*," 1874,—English translation by T. P. Smith, 1876,—has made a deep impress upon post-mortem technic, while Orth's *Compendium der pathologisch-anatomischen Diagnostik nebst Anleitung zur Ausführung von Obduktionen*, 1900, a new edition of which is now in the course of preparation, is the best work with which to study pathology at the post-mortem. Among other books in the German language which are to be recommended are those of Nauwerck, *Sectionstechnik*, Jena, 1904; Chiari, *Pathologisch-anatomische Sektionstechnik*, 1894; Busse, *Das Sektions-Protokoll*, 1903; and Graupner and Zimmermann, *Technik und Diagnostik am Sektionstisch*, 1899. In French, the works of Letulle, *La pratique des autopsies*, Paris, 1903; and Zilgien, *Manuel théorique et pratique des autopsies*, Paris, 1905, are the most recent and best. The more important works in English are Hektoen's *The Technic of Post-Mortem Examinations*, 1894; Blackburn's *Manual of Autopsies*, 1892; Kelynack's *Post-Mortem Handbook*, 1899; and Schmidt's *A Brief of Necroscopy*, 1902. Chapters upon the method of making autopsies are to be found in many books upon pathology, such as those of Coplin, Mallory and Wright, Delafield and Prudden, Hamilton, and Woodhead. Quain's *Dictionary of Medicine* and Wood's *Reference Handbook of the Medical Sciences* also give special articles upon this subject. Works upon medicolegal medicine, such as Witthaus and Becker, Peterson and Haines, and Draper, contain much information in regard to the proper performance of autopsies. The best reproductions of pathologic tissues are to be found in the *Pathologic Atlas* of Kast and Rumpel and the *Medicolegal Atlas* of Adolf Lesser.

INDEX

A

- Abbreviations used in weights and measures, 395
- Abdomen, embalming cadaver through, 302; enlargement of veins of, 70, 95; regional landmarks of (epigastric, hypogastric, right and left hypochondriac, right and left iliac, right and left lumbar, umbilical); striæ (*lineæ albicantes*) of, 70
- Abdominal cavity, bile in, 97; chyle in, 97; closure of, xx, p. 298, Figs. 175, 176; examination of organs of, 15, 17, vi, p. 89, 125, x, p. 172, 289, xxix, p. 484, Plate one, Figs. 55-57, 62, 71, 96-125, 164-166, 168; examination of organs of, in animals, 392, xxv, p. 407, Figs. 187-191, 198, 199; fluid in, 95; foreign bodies in, 30, 99; gas in, 94; gastric contents in, 98; removal of organs of, in one piece along with those of the thoracic cavity, 125, 289
- Abdominal pregnancy, see EXTRA-UTERINE PREGNANCY
- Abnormalities, see MALFORMATIONS and under the organs themselves
- Abomasum, Fig. 198
- Abortion, 70, 221, 294, 330, 334, 446, 466
- Abrachius (upper limbs absent, lower limbs well formed)
- Abrine, toxicology of, 463
- Abscess (amœbic, atheromatous, cold or chronic, embolic, miliary, pericæcal, perinephritic, perityphlitic, retropharyngeal, subdiaphragmatic, subphrenic, tropical, etc.), see anatomic name of part
- Absence, see the parts themselves
- Acacia solution, 370
- Acardia, 126
- Acarus folliculorum* (*Demodex folliculorum*), 358; *A. scabiei*, 358
- Accessory, see the organs and parts themselves
- Accident insurance, 52
- Accidents, 506; of pregnancy, 503
- Acervuloma of brain, 267
- Acervulus cerebri, see BRAIN SAND
- Acetanilid, toxicology of, 463, 465
- Acetic acid, toxicology of, 463, 469; uses of, 47, 369
- Acetone, 47, 233
- Achirus (without hands)
- Acholia (deficiency or absence of the secretion of bile)
- Achondroplasia, 258
- Achorion Schönleini*, Plate five
- Achromatopsia, 83
- Acid, see the acids themselves
- Acids, toxicology of, 468
- Acne, 42, 71
- Aconite, toxicology of, 463, 464
- Aconitine, toxicology of, 463, 464
- Acrania (partial or total absence of the cranium)
- Acrodynia, 388
- Acromegaly, 65, 79, 81, 107, 233, 240, 257
- Actinomyces*, 307
- Actinomycosis, 48, 72, 306, 327, 492
- Acute, see the diseases themselves
- Addison's disease, 33, 69, 134, 162, 191, 495
- Adenitis, 161, 332, 351
- Adenoids, 139, 156, 157, 158
- Adenoma (alveolar, cystic, fibrous, papillary, tubular; adenocarcinoma, adenocystoma, adenofibroma, adenomyoma, adenomyxoma, adenosarcoma), see the parts themselves
- Adipocere, 53, 57
- Adiposis dolorosa (Dercum's disease), 68
- Adnexa, uterine, diseases of, 496
- Adonis*, toxicology of, 466
- Adrenalin (the internal secretion of the adrenal glands, which may when introduced into animals in sufficient quantity cause atheroma and even aneurisms), 191
- Adrenals, accessory, 190; atrophy of, 191; cancer of, 191; *Coccidia* of, 366; cortical substance of, 15; cysts of, 191; diseases of, 33, 190; *Echinococcus* of, 191; examination of, 15, 17, 186, 187, 190, 295, 486, Fig. 192; examination of, in animals, 430; gliomata of, 191; hæmatoid degeneration of, 191; hæmatomata of, 191; hydronephromata of, 190; hypertrophy of, 191; intermediary substance of, 15; internal secretion of (see ADRENALIN), 191; measurements of, 190, 404; medulla of, 15; melanomata of, 191; nerves of, 15; of babe, anatomy of, 290; sarcoma of, 192; tuberculosis of, 191, 192; tumors of, 191; vessels of, 15; weight of, 394, 396, 404

- Ægagropilus (bezoar, hair ball, a concretion found in the alimentary tract, especially of ruminants)
- Aërobic organisms (those which require oxygen for growth)
- Æstivo-autumnal malaria, 364, 365
- Affection, see DISEASE
- African lethargy, see SLEEPING SICKNESS
- Agaricus bulbosus*, toxicology of, 465
- Age, apparent, 64; estimation of, 64, 481; real, 64
- Agglutination, 128, 132
- Ague, see MALARIA
- Ainhum (a disease of negroes, starting as a furrow in the toe, usually the little toe, with enlargement and destruction of the proximal ends)
- Air bubbles in blood, 134; emboli, 112; passages, foreign bodies in, 161
- Albinism, 69, 85
- Albuminuria, 334, 503
- Alcohol, toxicology of, 60, 68, 109, 130, 150, 154, 226, 229, 231, 232, 237, 261, 264, 278, 459, 460, 463, 465, 469, 495; uses of, 41, 42, 45, 47, 245, 250, 369
- Alcohol-lamp, 41, 42
- Aldehyd, formic, see FORMALDEHYD
- Aleppo boil (an Oriental furuncle, occurring especially on the face, and due to a specific bacillus)
- Algor mortis, 56
- Alienation, forms of, 496
- Alimentary tract, see parts and diseases themselves; measurements of, 402; weight of, 394, 402
- Alkalies, toxicology of, 202, 466, 470
- Alkaptonuria, 217, 234
- Allantoic cysts, 76
- Alopecia, 71
- Altmann's solution, 375
- Amanita phalloides*, 460, 466
- Amanuensis, duties of, at postmortem, 24, 489
- Amaurosis, 464
- American Anthropometric Society, 5; insurance standard of weight, 395
- Ammonia, aromatic spirit of, 47; test for, 55; to remove iodine stains, 302; toxicology of, 29, 465, 466, 470; use of, by injection, as a test for death, 55
- Amœba coli* (*A. dysenteria*), 229, 315, 364
- Amœbiasis, 130
- Ampulla of Vater, examination of, 199
- Amputation, complications of, 504; muscular twitching in limbs after, 54; of hand, in spreading gangrene, 52
- Amussat's hammer, 254
- Amyl nitrite, toxicology of, 31, 465, 467
- Amyloid concretions (bodies) occur in the prostate and in nervous tissue
- Amyloid degeneration, 143, 150, 209, 213, 337; reaction for, 206, 224; turpentine as a cause of, 460
- Amyotrophic lateral sclerosis, 257
- Anæmia (cytogenic, essential, idiopathic, von Jaksch's, parasitic, pernicious, primary, secondary, simple, splenic, symptomatic, etc.), 129, 130, 138, 139, 140, 324, 325, 331, 362, 495; definition of, 129; pernicious, 69, 81, 129, 130, 134, 135, 136, 199, 206
- Anaërobic organisms (those which do not grow in oxygen), 385, 386, 389
- Anæsthesia, fatal, 294
- Anasarca, 310
- Anastomosis, 153
- Anatomic wart, 51; treatment of, by X-rays, 52
- Anatomical Board, bodies for, 5
- Anatomy, comparative, 67; morbid, see the diseases, and the names of the diseases under the various organs; pathologic, 67; study of, at postmortems, 3
- Anchylostoma americanum*, 183; *A. caninum*, 183; *A. duodenale*, 129, 135, 362
- Anencephalus, 76
- Aneurism (anastomotic, arteriovenous, cavernous, cirroid, congenital, cylindrical, dissecting, false, fusiform, hernial, infective, miliary, mycotic, racemose, saccular, spurious, traction, traumatic, true, varicose, etc.), 82, 104, 105, 115, 144, 151, 152, 153, 154, 155, 259, 337, 497; electrolysis in treatment of, 154; of abdominal aorta, 154; of animals, 154; of aorta, 124; of bones, 288; of brain, 153; of carotid, 125; of cœliac axis, 154; of femoral artery, 153; of gluteal artery, 153; of heart, 112, 144, 150, 151; of hepatic artery, 154; of mesenteric artery, 154; of sinus of Valsalva, 146, 154; of splenic artery, 154; of thoracic aorta, 154, 199; of valves, 147; rupture of, 69, 106, 153, 200
- Aneurismal varix, 153
- Angina, Vincent's, 313
- Angina pectoris, 143, 497
- Angioma (arterial, cavernous, fissural, hypertrophic, lymphatic, plexiform, racemose, simple, varicose, and venous), 107; of bladder, 216; of kidneys, 214; of liver, 230; of ovaries, 219; of skin, 73; of spleen, 178
- Angiomalacia, 149
- Angioneurotic œdema, 71, 73
- Angiosarcoma of nasal passages, 156
- Angiosclerosis, 149
- Anguillula stercoralis*, 129
- Angular method of removing calvarium, 238, Figs. 129-137
- Anhydræmia, 129
- Anideus, 76

- Anilin colors, toxicology of, 463, 464, 467, 468
- Animal holder, 391, Fig. 184; parasites, pathogenic, 357; poisons, 460, 463, 478
- Animals, see APE, CAT, COW, DOG, GUINEA-PIG, HORSE, MOUSE, PIG, etc.; actinomycosis of, 407; aneurism in, 154; anthrax of, 407; arsenical poisoning of, 471; contagious diseases derived from domestic, 306, 407; hair-seams of, 409; inoculation of, 390, Figs. 185, 186; methods of killing, for post-mortem examinations, 408; post-mortem examination of, xxv, p. 407; removal of extremities of, 409; removal of hide of, 408, 430; taking temperature of, Fig. 183; value of necropsies upon, 407; weight of, 429
- Animation, suspended, 53
- Ankylosis, 81, 281; mistaken for post-mortem rigidity, 60
- Annotto, toxicology of, 464
- Anomalies, 3, 15, 235
- Anopheles claviger*, 364
- Anophelina*, 364
- Anonychia, acquired, 87
- Anthracois, 33, 109, 122, 168, 226
- Anthrax, 48, 72, 135, 203, 214, 293, 308, 407
- Anthropometric Society, American, 5
- Antifebrin, toxicology of, 467
- Antimony, toxicology of, 460, 462, 463, 464, 465, 470
- Antipyrin, toxicology of, 71, 463, 464, 467
- Antiseptic dressings, 45, 46, 47
- Antiserum test for diagnosing blood, 132, 396
- Antitoxin of diphtheria, 132; of glanders, see MALLEIN; of tetanus, 52
- Antrum of Highmore, 156, Figs. 173, 174
- Anuria, 468
- Anus, diseases of, 30, 79, 294, 336, 338, 339, 500; examination of, 15, 17, 420, 482
- Aorta, diseases of, 116, 124, 144, 147, 148, 150, 151, 154, 199, 208, 351; examination of, 15, 16, 17, 117, 120, 208, 485, Fig. 122; examination of, in animals, 413, 414, 415, 416, 417, 418, 430; measurements of, 124, 401; weight of, 394, 401
- Aortic valve, diseases of, 144, 149, 152; measurements of, 400, 401
- Aortitis, 152
- Aparathyroidism, 108
- Ape, syphilis of, 335
- Aphonia, 465
- Apnœa, 32
- Apodia, 80
- Apomorphine, toxicology of, 466
- Apoplexy (see also BRAIN, HEMORRHAGE OF, and LUNG, HEMORRHAGE OF), 56, 163, 189; mistaken for alcoholism, 32
- Appendices epiploicæ, diseases of, 99, 186
- Appendicitis (catarrhal, follicular, gangrenous, obliterative, parasitic, suppurative, tuberculous, typhoid, ulcerative, etc.), 134, 178, 183, 184, 185, 322, 347, 355, 501
- Appendix, ensiform, 105
- Appendix vermiformis, 183; actinomycosis of, 308; articles found in, 184; bacteriology of, 184; *Bilharzia* of, 184; cancer of, 185; catarrh of, 184; causing subdiaphragmatic abscess, 172; concretions in, 183; cysts of, 185; diseases of, see APPENDICITIS; duplication of, 183; enteroliths of, 184; examination of, 15, 100, 183, 487; foreign bodies in, 183; gangrene of, 184, 185; in hernia, 185; measurements of, 183, 402; mesentery of, 183; of babe, anatomy of, 290; opening of, 180; parasites in, 184; perforation of, 185; sarcoma of, 185; situation of, 30, 185; typhoid lesions of, 353; ulceration of, 185; Virchow's dictum concerning, 100; weight of, 402; worms in, 184
- Aphthæ, 78
- Apus (without a foot)
- Arachnoid, 16, 398
- Arecaline, toxicology of, 464, 465, 466
- Argyria (argyriasis), 69, 464
- Army, United States, autopsies in, 22
- Aromatic oils, toxicology of, 31; spirits of ammonia, use of, 47
- Arsenic as a normal constituent of the body, 47; detection of, in intestinal tract, by X-rays, 471; toxicology of, 32, 57, 72, 129, 178, 203, 212, 221, 264, 310, 450, 452, 459, 460, 461, 462, 463, 464, 465, 466, 468, 470; uses of, 302
- Arseniated hydrogen, toxicology of, 465, 467
- Arterial embalming, 302; varix, 152
- Arteries, diseases of, 118, 149, 152, 154, 268, 497; examination of, 15, 16, 17, 113, 116, 117, 122, 240, 242, 417, 486, 487
- Arterioliths, 152
- Arteriosclerosis, 142, 144, 149, 150, 153, 173, 337
- Arteritis obliterans (obliterative), 261
- Arthritis (acute, ankylosing, deformans, fibrinous, gonorrhœal, gouty, infective, multiple, neurogenous, obliterans (obliterative), pneumococcal, purulent, rheumatic, scarlatinal, serofibrinous, serous, spinal, syphilitic, toxic, tuberculous, ulcerative, uric, etc.), 139, 141, 151, 275, 277, 278, 280, 319, 324, 325, 329, 332, 350, 504
- Arthropathies, 259
- Ascaris* (*A. lumbricoides*, *A. megalocephala*, *A. mystax*), 129, 182, 361

- Ascites, 70, 75, 95, 96, 129, 133, 174, 227; chylous, 362
- Ascospore (a spore lying within a special spore-case or ascus), Plate five
- Asiatic cholera, see CHOLERA, ASIATIC
- Asomata, 76
- Asparagus, effect of, on urine, 466
- Asparagus rust, 432
- Aspergillus bronchialis*, 327; *A. fumigatus*, 166; *A. niger*, 166
- Asphyxia, 32, 113, 294, 505
- Assistants at postmortem, 6, 180
- Asthma, 130, 159, 498
- Atavism (congenital characteristics derived from remote ancestors)
- Ataxia, cerebellar, 261; Friedreich's, 257, 261; hereditary, 261; locomotor, 72, 73, 136, 258, 261, 265, 337, 473, 495
- Atelectasis, 121, 160, 162
- Ateleiosis (a form of dwarfism in which the development of the body is delayed or arrested, while in progeria, *q.v.*, it is accelerated), 258
- Atheroma, 70, 143, 149, 150, 208, 337, 497; of prostate, 222; of pulmonary artery, 161
- Atresia of blood-vessels of heart, 126; of uterus, 219
- Atrophy (acute yellow, of liver, brown, of heart and testicles, concentric, of heart, congenital, cyanotic, eccentric, of heart, granular, muscular, optic, progressive muscular, pseudohypertrophic muscular, red (Virchow's), senile, etc.), 27, 68, 80, 91, 106, 134, 143, 144, 207, 212, 219, 222, 223, 224, 229, 325, 468, 501
- Atropine, effect of, on pupil after death, 54; toxicology of, 7, 463, 468, 471
- Aurantia*, toxicology of, 464
- Auricular appendices, color of, 113; contraction of, 113; examination of, 117, 118, Figs. 79, 84, 85, 167; pulmonary veins of left, 118
- Auriculoventricular septa, 114, 117; valves, competency of, 116
- Author's method of fixing calvarium, 299; of precipitating lead in the gums, 465; of preparing frozen sections, 370; of removing brain in child, 291; of removing male genitalia without disfigurement, 196, Figs. 117-119; table of Coroner's cases, 450
- Auto-agglutination, 128
- Autoclave, 46
- Autodigestion, 98
- Autolytic ferments, 152
- Autopsia, 98
- Autopsy, see POSTMORTEM; first use of word, 2
- Avoirdupois weight, 394
- Axillary cellulitis, treatment of, 51
- Ayer Clinical Laboratory of the Pennsylvania Hospital, 11, 18, Fig. 4
- Azur II, 369
- Azygos veins, 17, 120, 208, 401, 418
- Azoospermia, 222
- B**
- Babes, measurements of, 395; postmortems on, xviii, p. 289; weight of, 395
- Bacillus, see also BACTERIUM and MICROORGANISMS; difference of, from bacterium, 385; resistant spores of, 308, 393
- Bacillus anthracis*, 308, 386; *B. coli commune*, see BACTERIUM COLI COMMUNE; *B. diphtheriæ* (see CORYNEBACTERIUM DIPHTHERIÆ); *B. icteroides*, 357, 388; *B. lepræ* (see MYCOBACTERIUM LEPRÆ); *B. mallei* (see CORYNEBACTERIUM MALLEI); *B. minutissimus sputi*, 388; *B. œdematis maligni*, 386; of Chantemesse, 314; of Friedländer, 327; of Lustgarten, 335; of Shiga, 314, 386; *B. pertussis*, 388; *B. pestis*, 325, 327; *B. pneumoniae*, 327, 332; *B. prodigiosus*, 91; *B. proteus*, 174; *B. smegmatis*, 335; *B. subtilis*, 307, 386; *B. tetani*, 340, 341, 386; *B. tussis convulsivæ*, 388; *B. X*, 357, 388
- Bactericidal properties of bone-marrow, 49
- Bacteriologic investigations, 41, 101, xxiii, p. 382
- Bacterium, see also BACILLUS and MICROORGANISMS; difference of, from bacillus, 385
- Bacterium aerogenes capsulatum*, 177, 229, 386; *B. coli commune*, 31, 327, 355, 386; *B. dysenteriæ*, 386; *B. enteritidis*, 386; *B. influenzae*, 321, 327, 386; *B. paratyphosum*, 386; *B. pestis*, 386; *B. pneumoniae*, 386; *B. proteum*, 386; *B. pyocyaneum*, 49, 386; *B. rhinoscleromatis*, 386; *B. septicæmiæ hæmorrhagicum*, 386; *B. typhi murium*, 386; *B. typhosum*, 327, 353, 386; *B. vulgare*, 386
- Bag, rubber, 42
- Balantidium coli*, 359
- Balls, graduated, 114
- Balsam of copaiba, toxicology of, 464
- Barium salts, toxicology of, 361, 466, 471, 473
- Barlow's disease, 140
- Bartholinian glands, 78
- Baryta, toxicology of, 466
- Basal ganglia, Fig. 149
- Base of skull, examination of, 244
- Basedow's disease, 108, 130, 162
- Basins, enamelled, 39
- Battery fluid, case of poisoning by, 9
- Beaded ribs of rachitis, 81
- Beale's Prussian blue, 380
- "Beaver-tailed" liver, 204
- Béclard's sign, 292, 445, 488, Fig. 172
- Bedbug (*Cimer*), 306, 358
- Bed-sores (decubitus), 72, 75
- von Behring's cure for tuberculosis, 343

- Belladonna, toxicology of, 463, 464, 466
 Bellows for inflating viscera, 41
 Benzaldehyd, toxicology of, 467
 Benzin, 47
 Benzokoll, toxicology of, 465
 Beriberi (dry, œdematous, and paralytic), 264, 310, 388
 Bertillon classification of causes of death, 32, xxx, p. 491; system of identification, 62
 Beta-oxybutyric acid in urine, 233
 Bezoar, see ÆGAGROPILUS
 Bichlorid of mercury, see MERCURY, BICHLORID OF
 Bichromates, toxicology of, 9, 465, 467, 470; uses of, 245, 252
 Bier's passive hyperæmia, 267
 Bigelow clamp, 38, Fig. 44
 Bile, 134, 224; examination of, 204, 224; Gmelin's test for, 134; in abdominal cavity, 97, 224; in blood, 134; in stomach, 200; specific gravity of, 224
 Bile ducts, diseases of, 224, 225, 226, 355; examination of, 15, 17, 198, 204, 223, Figs. 121, 122; examination of, in animals, 416, 426, 428, 430, Fig. 198
Bilharzia hæmatobia, see DISTOMA
 Biliary calculi, see GALL-STONES
 Bilirubin, 134, 211, 223
 Biliverdin, 294
 Binoxalates, toxicology of, 466, 468
 Biologic blood-(albumin)test, 132, 396; differential diagnosis, 132, 396
 Birds, post-mortem examination of, 429
 Bishop, mind-reader, postmortem on, 7
 Bismarck brown, toxicology of, 369, 464
 Bismuth, toxicology of, 465
 Bistoury, probe-pointed, 238
 Bisulphids, toxicology of, 264, 463
 Bisulphites, uses of, 47
 Black urine, causes of, 217
 Bladder (the urinary bladder is here referred to), abscess of, 215; absence of, 216; adenoma of, 216; angiomata of, 216; *Bilharzia hæmatobia* of, 217, 363; calcium carbonate stones of, 217; calcium diposphate stones of, 217; calcium oxalate stones of, 217; calcium triphosphate stones of, 217; calculi of, 217; carcinoma of, 49, 216; casts of, are sometimes found; *Cysticercus* of, 218; cystin stones of, 217; deformities of, 78; dermoids of, 216; dimensions of, 404; diphtheria of, 216; diseases of, 215, 502; distension of, 193; *Distoma hæmatobium* of, 217, 363; diverticula of, 216; double, 216; *Echinococci* of, 218, 360; *Eustrongylus gigas* of, 218; examination of, 15, 17, 193, 194, 195, 486, Figs. 107-114, 120, 164; examination of, in animals, 419, 430; extrophy of, 216; fibroma of, 216; *Filaria sanguinis hominis* of, 218; fis-
- Bladder (*continued*)
 tula of, 216; gangrene of, 216; hemorrhage in, 215; hernia of, 216; hypertrophy of, 33, 141, 216; inflammation of, see CYSTITIS; inversion of, 216; measurements of, 404; mucous membrane of, 215; myoma of, 216; necrosis of, 215; papilloma of, 216; parasites in, 217; *Pentastoma* of, 218; perforation of, 215; rigidity of, 59; rupture of, 216; sarcoma of, 216; traumatism of, 215, 216; thrombosis of, 215; tuberculosis of, 216, 348; tumors of, 216; weight of, 394, 404; xanthin stones of, 217
 Bladder, gall, see GALL-BLADDER
 Blank-books, post-mortem, 19
Blastomyces (yeasts), pathogenic, 72, 341
 Blastomycosis, 72
 Blebs, 72
 Bleeding, see HEMORRHAGE; use of word in court instead of "hemorrhage," 440
 Blisters on dead skin, 75, 464
 Blockley, see PHILADELPHIA HOSPITAL
 Blocks of wood as head-rests, 40; see also various figures, as 58, 126, 127
 Blood, viii, p. 126; abnormal constituents of, 134; acidity of, 128, 468; alkalinity of, 128; bacteriologic examination of, 113, 135, 382; bile in, 134; bilirubin crystals in, 134; blackish pigment in, 134; Bremer-Williamson reaction of diabetic, 226; Charcot-Leyden crystals in, 135; coagulation of, 127; color of, 28; cryoscopic index of, 127, 458; diseases of, viii, p. 126; effects of air on, 29; examination of, 29, 91, 126, 131, 369, 382, 460, 481, 482, 487; extravasation of, 139, 140, 141, 482; gas bubbles in, 134; glycogen in, 134; hamatoidin crystals in, 134; in carbon monoxid poisoning, 474; in chlorate poisoning, 128, 477; in cholera, 312; in diabetes, 226; in drowning, 458; in electric death, 454; in hydrocyanic acid poisoning, 473; in illuminating gas poisoning, 474; in longitudinal sinus, 241; in malaria, 134, 364; in nitrite poisoning, 128; in potassium cyanid poisoning, 461, 473; in putrefaction, 128; in scarlet fever, 331; in toadstool poisoning, 128; in typhus fever, 356; in yellow fever, 357; occult, in stools, 182; parasites of, 135, xxi, p. 306; poisons in, 429, xxviii, p. 468; specific gravity of, 127; spectroscopic examination of, 131, 460; spectroscopic test of, 474; staining of fluid by, 140; tumor cells in, 134
 Blood fluke, 363; plates (plaques), 128, 130, 135, 139, 140; pressure, 55, 149; serum, 41, 129, 133, 368; stains, 63, 131; tests, specific, 132, 396

- Blood-blisters caused by costotome, 37, Fig. 34
- Blood-color scale, 126, Plate three
- Blood-vessels, diseases of, 126, viii, p. 149, 261, 348; examination of, 16, 17, 483
- Blow-pipe, 38, 43
- Boards of Health, 4, 306, 382
- Boards to stand on while making post-mortem, 13
- Body, see *CADAVEE*
- Boils, 48, 234
- Bond's experiments, 33
- Bone, age of, how indicated, 68; aneurisms of, 288; angioma of, 287; ankylosis of, 60; atrophy of, 278; carcinoma of, 288; chloroma of, 288; chondroma of, 287; *Cysticerci* of, 288; cysts of, 287, 288; decalcification of, 376; diseases of, 62, xvii, p. 275, 323, 330, 504; dislocations of, 280; *Echinococci* of, 288; enostoses of, 287; examination of, 16, 236, 296; examination of, in animals, 430; exostoses of, 287; fibroma of, 287; fractures of, 280; hematoma of, 288; in lungs, 169; in muscles, 93; in tonsils, 158; inflammation of, 263; injuries to, 281; lipoma of, 287; marrow of, see *BONE MARROW*; measurements of, 65; myxoma of, 288; necrosis of, 262; osteoma of, 287; osteomyelitis of, 145, 236, 281, 323; osteophytes of, 287; parasites of, 287; sarcoma of, 288; supernumerary, of skull, 236; syphilis of, 336, 339, 340; tuberculosis of, 350; tumors of, 287; X-ray examination of, 275; weight of, of skeleton, 396
- Bone forceps (bone nippers). 37, 42, 254, 408; marrow, 16, 49, 130, 136, 137, 139, 281
- Bordeaux mixture of copper, 432
- Borders of organs, 27
- Boric acid, toxicology of, 471
- Bothriocephalus latus*, 129, 135, 360; *B. mansoni*, 361
- Bottle, iodoform-dusting, 42; wide-mouth, 40, 42
- Bovine tuberculosis, 48, 342
- Bowel, see *INTESTINE*
- Bow-leg, 81
- Box for post-mortem instruments, 34
- Brachial plexus, 106
- Brachycephalic skull, 397, 398
- Brain, abscess of, 261, 263, 322, 332; absence of, 260; acervuloma of, 267; actinomycosis of, 307; anemia of, 267; anthrax of, 310; aneurism of, 267, 268; blood-vessels of, 16; carcinoma of, 267; cerebroma of, 267; charts of, 26; cholesteatoma of, 267; congenital anomalies of, 260; congestion of, 267, 496; cortical lesions of, method of sectioning in, 250; *Cysticerci* of, 267, 359; Brain (*continued*)
cysts of, 267; diseases of, xv, p. 257, 321; *Echinococci* of, 267; embolisms of, 33, 147; encephalitis of, 33; endothelioma of, 267; examination of, 16, xiii p. 235, 291, 296, 483, Figs. 126-152; examination of, in animals, 420, 422, 427, 429, 430; fibroma of, 267; glioma of, 267; gumma of, 267; hardening of, 245, 251; hemorrhage of, 164, 255, 257, 261, 268, 452, 496; hyperæmia of, 268; hypertrophy of, 148; in diphtheria, 314; in malaria, 365; in poisoning, 461; in typhus fever, 356; incising of, 44; inflammation of, 262; injection of, 250; injuries of, 449; measurements of, 399; œdema of, 130; osteoma of, 267; osteophytes of, 277, 282, 287; peduncles of, 16; sarcoma of, 267; sawing of, 243, Fig. 138; scars of, 269; sclerosis of, 261, 265; sectioning of, 246; softening of, 261, 496; specific gravity of, 399; syphilis of, 267, 337; traumatism of, 261; tuberculosis of, 262, 267, 352; tumors of, 243, 261, 267; vascular changes in, 267; ventricles of, 16; volume of, 399; weight of, 243, 394, 396, 398
- Brain cavity, injecting embalming fluid into, 9; knife, 35, 408, 422, Figs. 17, 18; sand (acervulus cerebri), sand-like matter about the pineal gland and other parts of the brain; stem, weight of, 398
- Bran used in preservation of body, 301
- "Bread-and-butter" pleurisy, 109
- Break-bone fever, 312
- Breast, diseases of, 70, 72, 73, 91, 503; examination of, 15, 70, 91, 482
- Breastplate, 104, Fig. 70
- Breathing, see *RESPIRATION*
- Bremer-Williamson reaction of diabetic blood, 226
- Bright's disease, 73, 96, 157, 209, 451, 501
- Broad ligament, examination of, 15, 17
- Bromatotoxicism, 459
- Bromid, toxicology of, 463, 464
- Bromin for disinfecting wounds, 41, 42; toxicology of, 31, 461, 462, 465
- Bromoform, toxicology of, 31
- Bronchi, diseases of, 159, 160, 161, 163, 321, 334, 338, 351; examination of, 15, 17, 120, 122, 430, 485, 489, Fig. 89
- Bronchial glands, diseases of, 160, 309, 324, 345
- Bronchiectasis, 159, 160, 161
- Bronchiogenic cyst, 159
- Bronchitis (acute, atrophic, capillary, catarrhal, cheesy, chronic, croupous, fibrinous, gangrenous, hypertrophic, plastic, purulent, subacute, suppurative, tuberculous, etc.), 130, 159, 160, 161, 163, 307, 324, 355, 356, 498

- Bronchopneumonia, 160, 166, 234, 307, 314, 325, 356, 362, 499
 Bronzing of skin, 33, 69, 191, 464
 Brown atrophy of heart, 143; induration of lungs, 163
 Brunetti's chisels, 37, 256, Fig. 38
 Brush-burn, 71
 Brushes, hand, care of, 48
 Bubonic plague, see PLAGUE
 Bucket method of opening intestines, 181, Fig. 97
 Buffy angina, see DIPHTHERIA
 Buhl's disease (icterus neonatorum), 134
 Bulb for securing fluid for bacteriologic study, 383
 Bulbar paralysis, 257
- C**
- Cabbage club-foot, 433
 Cachexia, cancerous, 69; malarial, 491
 Cachexia strumipriva, 107
 Cacodyl, cyanid of, toxicology of, 471
 Cadaver, bacteriology of, 395; closure of, xx, p. 298, 489; cooling of, after death, 56; decomposition of, 57, 480; disin-terment of, 480; disposition of, by will, 5; embalming of, 9, 302, Figs. 179, 180; examination of, ii, p. 14, v, p. 53, 480, 481; fluorescence of, 444; frozen, 60, 302, 481; "found dead," 450; height of, 395; identification of, 61; inspection of, 14; lividity of, 14, 57, 58, 60; measurements of, 64, xxiv, p. 394; operations on, 3; pecuniary value of, 4; phosphorescence of, 444; preservation of, 290, xx, p. 298, Figs. 5-8, 179-182; putrefaction of, 481; restoration of, xx, p. 298; rigidity of, 60; right to dispose of, by will, 5; sewing up of, Figs. 175, 176; situation of, after death, determined by kind of clots, 128; specific gravity of, 395; surgical operations on, 3; sym-metry of, 61; temperature of, 14; thawing of, 305, 481; transportation of, 481; unidentified, 63; weight of, 11, 395; wounds of, produced by gnawing animals after death, 482
 Caisson disease, 259
 Calcicosis, 168
 Calcification, 143, 150, 152; in bladder, 217; in kidney, 211; in tuberculosis, 342; of appendices epiploicæ, 186; of arteries, 150; of cartilages, 103; of renal epithelium, 460; of valves, 145
 Calculi, biliary, see GALL-STONES; of blad-der, 217; of kidney, 210, 213, 214; of nose (rhinoliths), 156; of pancreas, 207, 232, 233; of prostate, 222; of salivary glands, 274; of ureters, 193, 215; of urinary tract, 502
 Calipers, graduated, 39
 Calomel, toxicology of, 163, 466
 Calvarium, angular method of opening, 238; circular method of opening, 236; clamps for holding, 38, Figs. 42-46; diseases of, xiii, p. 235, 339, 340; exam-ination of, 16, 236, 240, 483; examina-tion of, in animals, 421, 430, Figs. 192-197; French method of opening, 238 Fig. 133; restoration of, 299
 Calx chlorinata, 47
 Calyces, dilatation of, 214
 Campecia wood, toxicology of, 467
 Camphor, toxicology of, 31, 463
 Canal of Nuck, 101
 Cancer, see CARCINOMA
 Cancerum oris, 324
 Cannabinone, toxicology of, 463
Cannabis indica, toxicology of, 463
 Cannula, 9, 38
 Cantharides (cantharidate, cantharidin, cantharidinate), toxicology of, 210, 213, 215, 226, 460, 463, 464, 466, 467, 468
 Capsicum, toxicology of, 461
 Capsule of kidney, 189, 209, 210, 211, 212, 486, Figs. 103, 104; of liver, 206; of organs, 25, 27; of spleen, 227; Tenon's, 271
 Caput Medusæ, 155, 227
 Carbol-fuchsin, 41
 Carbon bisulphid, toxicology of, 264, 463, 467
 Carcass, see CADAVER
 Carcinoma (acinous, adenomatous, chim-ney sweepers', chorionotic, colloid, cylindrical, encephaloid, gelatinous, giant-celled, medullary, metastatic, primary, sarcomatous, scirrhus, second-ary, tubular, etc.), 68, 99, 106, 130, 146, 494, Plate four; cachexia of, 69; of adrenals, 191; of appendix, 185; of bones, 288; of brain, 267; of breast, 70, 494; of bronchi, 161; of buccal cavity, 494; of choroid, 85; of ciliary body, 85; of clitoris, 79; of female genital organs, 494; of gall-bladder, 49, 225; of heart, 148; of intestines, 183, 201, 494; of kidney, 214; of larynx, 158; of liver, 223, 225, 230, 494; of lung, 169, 201; of lymphatic glands, 201, 207; of lymph-vessels, 155; of mediastinum, 161; of mesentery, 97; of nasal passages, 156; of cesophagus, 124, 470; of omentum, 201; of ovaries, 219; of pancreas, 102, 201, 207, 233; of penis, 78; of pericardium, 110, 112; of peritoneum, 97, 173, 174, 201, 494; of pleura, 170, 201; of prostate, 222; of pylorus, 201; of ribs, 111; of rectum, 494; of skin, 73, 494; of spleen, 178, 201; of stomach, 199, 201, 494; of umbilicus, 76; of uterus, 219; of vag-ina, 221; of vulva, 78; protozoa of 388
 Carcinosis, miliary, 173

- Cardiac, see HEART
 Cardiome, 117, Figs. **31, 32**
 Cardol, toxicology of, 464
 Care of clothes removed from body, 62;
 of hands, iv, p. 45; of instruments, 34,
 44, 52; of rubber gloves, 46
 Caries, 85; of spine, 260; of teeth, 88
 Carnoy's fixing fluid, 367
 Carotid artery, aneurism of, 125; embo-
 lism of, 124; tearing of intima of, 124,
 486
 Carotid bodies, examination of, 15;
 tumors of, 125
 Cartilage, calcification of, 103; cricoid,
 108; cystic cavities of, 106; in tonsils,
 158; necrosis of, 142; xiphoid, 97
 Cartilage-knife, 103, 123, 480, Figs. **14-16**
 Caruncula minor, 199
 Cascarilla to remove odor at autopsy, 11
 Case, leather, for instruments, 42, Fig. **53**
 Castration, 130
 Casts of face, method of making, 305
 Cat, diseases of, 326, 429; postmortem
 on, 407, 408, 427
 Catarrh, 156, 157; adenoids in, 166
 Catheter, 38, 42
 Cattle, relapsing fever of, 329
 Causes of death, 447; in author's, 799
 Coroner's cases, 451; usual, Bertillon
 classification of, xxx, p. 491
 Caustics, toxicology of, 465; uses of, 55
 Cautery for bacteriologic work, 41, 42,
 389; for post-mortem wounds, 50
 Cavities, examination of, 31, 41
 Celloidin, uses of, 45, 376
 Cellulitis, 49, 52, 504; axillary, treat-
 ment of, 51
 Celluloid, strips of, for mounting spinal
 cord, 256
 Celosomia, 76
 Cephalonic skull, 398
Cercomonas intestinalis, 359
 Cerebellum, diseases of, 260; examina-
 tion of, 16, 243, 247, 483, Figs. **144-149**;
 weight of, 398
 Cerebral, see BRAIN
 Cerebroma, 267
 Cerebrospinal meningitis, 310, 326, 495
 Cerebrum, see BRAIN
 Cervix uteri, malignant neoplasms of, 221
Cestodes, 359
 Chain-hooks, 38, 43
 Chamois-skin, 42
 Chancre, Hunterian, or hard, 335; soft,
 336, 493
Chancre à distance, 335, 336
 Chancroid, 78, 338
 Charcot's joint, 92, 259
 Charcot-Leyden crystals, 135, 159
 Charts, outline, of position of organs and
 their lesions, 26
 Cheek, diseases of, 77, 341; sucking gland
 of, 75
 Cheiragra, 277
Cheiranthus, toxicology of, 466
 Chemic supplies, 41
Chenopodium, toxicology of, 467
 Chest, barrel-shaped appearance of, 159
 Chiara's raspatory, 38
 Chicken, gangrene of comb of, due to
 ergot, 473; relapsing fever of, 329
 "Chicken-fat" clots, 128
 Chicken-pox, see VARICELLA
 Chimney-sweepers' dermatitis (cancer), 72
 Chisels, 37, 42, 43, 245, 254, 408, 409, 423,
 480, Figs. **36-38**
 Chloasma, 71
 Chloral hydrate, toxicology of, 31, 463,
 464, 467, 472; uses of, 47
 Chlorates, toxicology of, 69, 128
 Chlorin, toxicology of, 31, 462; uses of,
 47
 Chloroform, toxicology of, 32, 84, 208,
 455, 463, 467, 472
 Chloroma, 288
 Chlorosis, 69, 130, 136, 151, 495; Egyp-
 tian, 362; of plants, 432
 Chlorphenol, odor of, 32
 Cholangitis, suppurative, 230
 Cholecystitis, acute infectious, 225
 Cholelithiasis, 226, 231
 Cholera, Asiatic, 48, 56, 58, 128, 129, 183,
 311, 359, 492
 Cholera infantum, 356; nostras, 492
 Cholesteatoma, 267
 Cholesterin, 151, 210, 265
 Chondritis, 279
 Chondroma, 70, 156, 169, 170, 287
 Chordæ tendineæ, 15, 117
 Chorea, 146, 259, 260, 261, 388, 496;
 canine, 260; chronic hereditary, 259;
 Huntington's, 259
 Choroid, tumors of, 85
 Choroid plexus, deposits of silver in, 247;
 examination of, 483
 Choroiditis, syphilitic, 336
 Chromates, toxicology of, 9, 464, 467
 Chromatolysis, 130
 Chromium, toxicology of, 460, 461, 465,
 495
 Chrysarobin, toxicology of, 464, 467
 Chrysoidin, toxicology of, 464
 Chyle, 179
 Chyle-duct, diseases of, 207; examina-
 tion of, 207
 Chylocysts of mesentery, 173
 Chylopericardium occurs
 Chylothorax, 170
 Chylous exudate, 97
 Cicutoxin, toxicology of, 463
 Ciliary body, tumors of, 85
Cimex lectularius, 358
 Cinchona bark, toxicology of, 464
 Circle of Willis, 269
 Circular method of removing brain, 236,
 Figs. **138, 139**

- Circulation, cessation of, as a sign of death, 54; diseases of, 136, 337, 497, 498
- Cirrhosis of liver, alcoholic, 226, 227; anthracotic, 227, 228; atrophic, 68, 70, 227; capsular, 226, 227; cyanotic, 227, 228; fatty, 226, 227; Hanot's hypertrophic, 128, 226; hypertrophic, 128, 226, 227; malarial, 227, 228; rhachitic, 227, 228; scarlatinal, 227, 228; syphilitic, 227, 228; tuberculous, 227, 228
- Cirrhosis of lung, 148
- Cirsoid aneurism, 152, 155
- Cladothrix*, 308
- Clamps for holding calvarium, 38, Figs. 42-46
- Classification, Bertillon, of diseases, xxx, p. 491; of poisons, 462
- Clavicle, examination of, 103, 104, 105, 106, 120, Figs. 64-66
- Claws, examination of, 430
- Clay modelling in the study of anatomy, 379
- Cleft palate, 123
- Clinical history, 61
- Clinocephalic skull, 398
- Clitoris, 79
- Cloacæ, 282
- Closure of body after postmortem, xx, p. 298
- Clothing as means of identification, 62; bullet-holes in, 63; examination of, 63, 481; preservation of, 62, 63; stains on, 63
- Clots, chicken-fat, 128; currant-jelly, 128; fibrinous, 128, 154; of pernicious anæmia distinguished from those of cancer, 136; red, 128
- Cloudy swelling, 372
- Club-foot, 283; cabbage, 433
- Club-hand, 283
- Coagulation of blood, 127
- Coagulation necrosis, 337
- Coagulum of heart, 128; post-mortem, 128
- Coal gas, toxicology of, 462
- Coal-dust in hands, 33; in liver, 228; in lungs, 33; in spleen, 134
- Coat, rubber, 47
- Cocaine, toxicology of, 455, 463, 464, 468, 472
- Coccidia*, 365
- Coccyx, 68, 267
- Cockroaches as cause of disease, 306
- Codeine, toxicology of, 464
- Cœliac axis, aneurism of, 154
- Cœliac plexus, diseases of, 192, 312; examination of, 192
- Coffee, burning of, to remove odor at post-mortem, 11
- Coffin used for post-mortem table, 10, Fig. 2
- Colchicine, toxicology of, 463, 464
- Colchicum, toxicology of, 461, 463
- Cold, death from, 455
- Cold abscess, 493
- Colitis, 185, 186, 529, 331
- Collapse, 463
- Collargol, 51
- Colloid degeneration, 92; of thyroid gland, 107, 161
- Coloboma, 84, 85
- Colocynthis, toxicology of, 465
- Colon, diseases of, 186; examination of, 17, 100; examination of, in animals, 411, 412, 413, 416, Fig. 189
- Color of eyes, 83; of fat in atrophy, 91; of fluid in abdominal cavity, 96; of hair, 86; of liver in acute yellow atrophy, 224; of lungs, 109; of muscle, 92; of organs, 28, 29; of skin, 69; of stomach after poisoning, 461
- Color index, 135; scale, post-mortem, 126; values by kromskop, 28
- Colors, anilin, toxicology of, 464
- Colostrum, 293
- Coma, 32, 134, 463
- Comedo, 358
- Comma bacillus* of Koch, 311
- Common bile duct, see DUCTUS CHOLEDOCHUS COMMUNIS
- Comparative anatomy, 67; postmortems, xxv, p. 407
- Compensation of physicians as experts, 438; for services, 437
- Compound fractures, 280
- Concretions, see CALCULI
- Condyloma, 338
- Cones, graduated, 39, 115, Fig. 50
- Congenital, see various organs; debility, 505; deformities, 76, 79, 80; dislocation of hip, 3, 76, 280
- Congestion, cyanotic, 58; hypostatic, 14, 58, 69, 164, 482; of brain, 496; of kidney, 210; of liver, 228; of lungs, 140, 148, 164, 499; post-mortem, 228
- Coniine, toxicology of, 464
- Conium, toxicology of, 461, 463
- Conjunctiva, 83
- Conjunctivitis, 83, 147, 314, 320, 322, 323, 324, 329, 351, 464, 497
- Consistency of organs, 29, 206
- Constipation, 182, 466
- Contagious diseases derived from domestic animals, 306, 407
- Continued fever, see TYPHOID FEVER
- Contour of organs, 25, 27
- Contracts between physician and patient, 437
- Contractures, 80
- Contrecoup*, 240, 449
- Convallaria*, toxicology of, 466
- Convulsions, see EPILEPSY
- Coplin brain-knife, 35, Fig. 17
- Copper, Bordeaux mixture of, 432; salts of, 465; toxicology of, 472
- Copper sulphate in treatment of actinomycosis, 307; purification of drinking water by, 472

- Cor villosum, 111
 Cord, see SPINAL CORD
 Cords, vocal, examination of, 157, 158
 Cornea, 84
 Cornell head-rest, 38, 235, Fig. 46
 Cornutine, toxicology of, 463, 465
 Coronary arteries, 116; diseases of, 118, 143, 144; examination of, 15, 113, 116, 117, 485
 Coronary veins, 113, 118, 485
 Coroner, 154; abolition of, 1; author's cases investigated for, 450; creation of, 1; duties of, 1, 33; office of, 1, 436; referring cases to, 4, 6
 Coroner's physician, 302
Coronilla, toxicology of, 466
 Corpora Arantii, 144; *C. cavernosa*, examination of, 196; *C. quadrigemina*, examination of, 483
 Corpse, see CADAVER
 Corpus callosum, 238, 242; *C. hæmorrhagicum*, 219; *C. luteum*, 218, 219; *C. spongiosum*, examination of, 196; *C. striatum*, examination of, 483
Corpus delicti, 64, 67, 440
 Corpuscles, red, agglutination of, in blood-serum, 129; diameter of, 132; elliptical human, 132; shapes of, 132
 Corrosive acids, toxicology of, 463, 465; alkalies, toxicology of, 463, 465, 466; metallic salts, toxicology of, 465; poisons, toxicology of, 465, 467
 "Corset-line," 204
 Cortex of kidney, 209, 210, 211, 212
Corynebacterium diphtheria, 327, 386; *C. mallei*, 318, 386; *C. tuberculosis*, 433; *C. xerosis*, 386
 Coryza, 156, 465
 Costochondral articulation, 90
 Costotome, 37, 38, 103, 104, 408, 480, 484, Figs. 33, 34
 Cotton, "flaming" of, in inoculation of culture tube, 388; uses of, 41, 383
 Court-plaster, liquid, 45
 Cover-slips, cleansing of, 384
 Cow, postmortem on, 407, 423; *Trypanosoma* of, 366
 Cowper's glands, removal of, 196
 Cow-pox, 388
 Coxalgia, 81, 351
 Coxitis, 208
 Cranial nerves, Fig. 140
 Craniopagus, 77
 Craniopriion, van Walsen's, 35
 Cranioschisis, 260
 Craniotabes, 81, 286, 340
 Cranium, dimensions of, 399; examination of, 238, 483; examination of, in animals, 420, 429, Figs. 192-197; restoration of, after removal of brain, 299, 300; sutures of, 67
 Credé's ointment, 51
 Crenation, 129
 Creolin, 42, 47; toxicology of, 463
 Creosote, toxicology of, 32, 467
 Crepitation of lungs, how elicited, 121, 489
 Cresol, toxicology of, 467
 Cretinism, 108, 260
 Crico-arytenoid joint, ankylosis of, 158
 Cricoid cartilages, 108; diseases of, 158
 Critical examination of organs of abdominal cavity, x, p. 172; of organs of thoracic cavity, vii, p. 103
 Crocein scarlet, 371
 Crop, examination of, 430
 Croton oil, toxicology of, 333, 464, 465, 466
 Croup, 491
 Croupous and catarrhal pneumonia, table showing difference between, 167
 Croupous bronchitis, 160; pneumonia, see PNEUMONIA
 Crura of diaphragm, severing of, 247
 Cruror, 128
 Crushing, suicide by, 506
 Cryoscopy of blood, 127, 458
 Crystalline lens, 85
 Crystals, Charcot-Leyden, 159; hæmatoidin, 134
 Csokor's method of removing thoracic and abdominal contents in animals, 416
 Cubebene, toxicology of, 464
 Culture-media, 41, 42, 382, 383, 385, 388
 Cultures ("smear," "stab," "stroke"), 389
 Cupping as a test of death, 55
 Curarine, toxicology of, 464, 467
 Curcas, oil of, toxicology of, 464
 Currant-jelly clot, 128
 Curschmann's spirals, 159
 Curvatures, lateral, 283
 Cutaneous horns, 72
 Cutis anserina, 75
 Cutting instruments, suicide by, 506
 Cyanid of cacodyl, toxicology of, 471; of potassium, toxicology of, 473
 Cyanmethæmoglobin, 473
 Cyanosis, 69, 138, 148, 465
 Cyanotic atrophy, 229; cirrhosis of liver, 227; induration, 147, 149, 206
 Cyclamin, toxicology of, 467
 Cyclocephalus, 76
 Cyst (see ALLANTOIC, DERMOID, ECHINOCCIC, HYDATID), 75, 155; of adrenals, 191; of bones, 287, 288; of brain, 267; of cartilage, 106; of Fallopian tubes, 218; of iris, 85; of joints, 287; of kidneys, 209, 210, 212; of nasal passages, 156; of ovary, 76, 219; of pancreas, 207; of prostate, 222; of retina, 85; of trachea, 159; of ureters, 215; of vagina, 221; sebaceous, 82
 Cystadenoma, 107, 161

- Cystic duct, examination of, 204, Fig. **121**; obliteration of, 225; obstruction of, 225
Cysticercus cellulosa, 359; of bladder, 218; of bone, 288; of brain, 267; of heart, 148; of kidney, 212; of lungs, 166; of pericardium, 111
 Cystin stones in bladder, 217; in kidney, 214
 Cystinuria, 466
 Cystitis, 214, 215, 216, 319, 355, 466
 Cystoma of ovaries, 219
 Cytisine, toxicology of, 463, 465, 466
 Cytogenic anæmia, 129
 Cytoglobin, 139
 Cytology, 263, 459
 Cytolysins, toxicology of, 463
 Cytolysis, 130
Cytorhynchus luis, 387; *C. variolæ*, 333
- D**
- Dactylitis, 339, 340
 Daltonism, 83
Datura stramonium, toxicology of, 460, 471
 Daylight, substitute for, at postmortem, 9
 Dead body, see **CADAVER**
 Dead-house (mortuary), 11, 13
 Death, Bertillon classification of the usual causes of, xxx, p. 491; duration of motility in spermatozoa after, 54; local, see **NECROSIS**; molar and molecular, 372; pathologic, 53; physiologic, 53; signs of, 14, 53, 482; sudden, 33, 54, 144, 294, 503, 507; tests of, 55; time after, to make postmortem, 7, 480; violent, 1, 442, 448
 Death certificate, form of, 507; mask, making of, 305; rattle, 54; stiffening (rigor mortis), 14, 30, 59, 311, 331, 334, 443
 Debility, 505
 Decalcification of tissues, 376
 Decapsulation of kidney, 3, 190
 Deciduoma malignum of uterus, 219
 Decomposition, 29, 30, 57, 61, 459, 482
 Deer, postmortem on, 409
 Deformities (acquired, asymmetrical, congenital, multiple, muscular, nervous, orthopædic, pathologic, single, symmetrical, etc.), 15, 76, 78, 80, 81, 82, 91, 124
 Degeneration, amyloid, 143, 150, 206, 224, 460; calcareous, 103, 143, 145, 150, 152, 211, 217, 460; colloid, 92, 107, 161, 355; fatty, 143, 144, 145, 147, 150, 212, 223, 225, 228, 229, 233, 234, 460, 484; glycogenic, 134, 206
 Dejerine's method of examining brain, 249, Figs. **149=151**
 Deleterious gases, absorption of, 506
 Delhi boil, 367
 Delirium, 257, 463
 Dementia, paralytic, 259, 337
Demoder folliculorum (*Acarus folliculorum*), 358
 Dengue, 312
 Dental engines used in sawing calvarium, 36
 Dentition, state of, in determining age, 67
 Deodorants, 41
 Dercum's disease, 68
 Dermatitis, 358; chimney-sweepers', 72; exfoliative, 71; Röntgen ray, 72
 Dermatitis herpetiformis, 72; venenata, 72
 Dermatomyositis, 72
 Dermoid cysts of bladder, 216; of lungs, 169; of mediastinum, 161; of ovary, 191, 219, 502; of testicles, 222; of uterus, 220
 Dermopathies, 259
 Development centre, 76
 Dextrocardia, 126
 Diabetes insipidus, 141; mellitus, 31, 73, 97, 127, 130, 134, 231, 232, 233, 234, 261, 341, 495
 Diabrosin, 142
 Diacetic acid in urine, 233
 Diagnosis, biologic differential, 132, 396; hypothetical, provisional, or tentative, 320, 440; pathologic, 24
 Diaphanous test, 54
 Diaphragm, diseases of, 99, 163, 207, 208; examination of, 15, 16, 17, 95, 207, 289, 484, 488, Figs. **67, 72, 122**; examination of, in animals, 410, 415, 417, 418, 426, 430
 Diarrhœa, 465, 500
 Diastasis, 280
 Diazo-reaction, 353
 Dicephalus, 77
 Differentiation, optic, 374
 Digestion, post-mortem, 98
 Digestive apparatus, diseases of, 499, 501
 Digitalis, toxicology of, 113, 147, 463, 466
 Dilatation of heart, 107, 119, 147; of lower rectum, 155; of lymph-vessels, 155; of pupils after death, 54, 56; of superficial abdominal vessels, 155
 Dimensions, see **MEASUREMENTS OF**, under the various organs and parts
 Diphtheria, 78, 90, 119, 129, 130, 132, 151, 156, 157, 160, 202, 216, 261, 264, 312, 313, 314, 324, 326, 491, 492; *Corynebacterium* of, 386, Plate five
 Diplegia, spastic, 266
Diplococcus, cultures of, 385; *D. crysipelatis*, 316; *D. intracellularis meningitidis*, 310, 386; *D. pneumoniae*, 166, 262, 327; *D. rheumaticus*, 330
 Diploë, 237, 240
 Diplopia, 464

- Diprosopus, 77
Diptera in stomach, 200
 Dipygus, 77; *D. parasiticus*, 77
 Directors, grooved and curved, 38, Fig. 41
 Dissection (division)
 Disease (see also the names of the various organs, Addison's, 33, 69, 134, 162, 191, 495; Barlow's, 140; Basedow's (Graves's), 108, 130, 162; Duchenne's, see ATAXIA, LOCOMOTOR; Duke's, 324; Friedreich's, 257; Gilford's, 258; Glennard's (splanchnoptosis, enteroptosis, or abdominal ptosis), 70, 173; Graves's (Basedow's), 108, 130, 162; Henoch's, 139; Hodgkin's, 130, 138, 173, 326; von Jaksch's, 138; Little's, 266; Osler's, 138; Paget's, of nipple, 70, 366; Parkinson's, 264; Raynaud's, 265; von Recklinghausen's, 267)
 Diseases, Bertillon classification of, 491; contagious, derived from domestic animals, 306, 407; contracted at postmortems, 48; diagnosed by agglutinative reaction, 128, 132; due to hæmatozoa, 364; due to micro-organisms, xxi, p. 306; due to parasites, xxi, p. 306; due to specific organisms or protozoa not yet isolated, 308; ill-defined, 506; of blood and blood-vessels, viii, p. 126; of bones, xvii, p. 275; of brain, xv, p. 257; of cord, xv, p. 257; of genito-urinary tract, xi, p. 209; of heart, viii, p. 126; of joints, xvii, p. 275; of liver and its ducts, xii, p. 223; of lymph-vessels, viii, p. 126; of nervous system, xv, p. 257; of pancreas and its ducts, xii, p. 223; of plants, xxvi, p. 432; of respiratory tract and accessory parts, ix, p. 156; of spinal cord, xv, p. 257
 Disinfection, 41, 47, 306, 392
 Disinfectants, 480
 Dislocations, 30, 76, 80
 Dissecting apron and sleeves, 42; forceps, 42, 43
Distoma, 135; *D. hamatobium*, 363; of bladder, 217, 363; of kidney, 212; of liver, 230; of lungs, 166; of ureters, 193, 215; *D. hepaticum*, 363; of alimentary tract, 363; of liver, 230; of peritoneum, 172; *D. lanceolatum* of liver, 230; *D. ophthalmobium*, 363; *D. pulmonale*, 166; *D. ringeri*, 363; *D. Westermanni* of lungs, 166
 Diverticula, Meckel's, 178, 180; of bladder, 216; of duodenum, 198; of œsophagus, 124, 198, 200; of stomach, 198
Doehmius duodenalis, see ANCHYLOSTOMA DUODENALE
 Dog, chorea of, 260; *Coccidia* of, 366; *Echinococcus* of, 360; postmortem on, 407, 408, 427, Figs. 199, 200; rabic, care of, 320; *Trypanosoma* of, 366, 367; uncinariasis of, 362
 Dolichocephalic skull, 397, 398
 Dose, lethal, 313
 Dothienteritis, see TYPHOID FEVER
 Dourine, 366
 Drains in dead-house, 11
 "Drill" bones, 93
 Dropsy (see also ASCITES), 137, 507
 Drowning, 75, 456, 485, 505
 Duchenne's disease, see ATAXIA LOCOMOTOR
 Ductus arteriosus Botalli, 17, 115, 126, 146, 148, 151, 290, 443, Fig. 167; *D. choledochus communis*, 15, 17, 198, 204, 226, 355, Figs. 121, 122
 Duke's fourth disease, 324
 "Dum-dum fever," 367
 Duodenum and its ducts, 198; diverticula of, 198; examination of, 15, 17, 198, 485, 486, 487, Figs. 121, 122; examination of, in animals, 413, 414, 416, 417, 426, 428, Fig. 189; measurements of, 402; pancreatic tissue in, 199; ulcers of, 178; weight of, 402
 Dupuytren's contracture, 283
 Dura mater, arteries of, 240; blood in, 241; examination of, 16, 240, 241, 255, 483, Figs. 133, 134; examination of, in animals, 421, 423; French method of opening, 239, Fig. 134; gummata of, 244; hemorrhage in, 241, 242, 244; hyperæmia of, 242; inflammation of, 244; sarcoma of, 230; tubercles of, 244; tumors in, 241, 244; veins of, 240
 Dura-tongs, 38, Fig. 39
 Dusts, irritating, toxicology of, 464
 Dwarfism, 65, 80, 258
 Dyscrasia, 97
 Dysentery, 128, 183, 185, 283, 314, 356, 492
 Dystrophia, 87
- E**
- Ear, diseases of, 77, 314, 340, 497; examination of, 15, 16, 245, xvi, p. 270, 430, 483, 488, Fig. 160
 Ecchymoses, 75, 83, 113, 142, 214
Echinococci, 75, 360; of adrenals, 191; of animals, 407; of appendix, 185; of bladder, 218; of bone, 288; of brain, 267; of diaphragm, 207; of heart, 148; of kidney, 212; of liver, 501; of lungs, 169; of pericardium, 111; of pleura, 170; of spleen, 178; of ureters, 215, 219
 Eclampsia, 224, 496, 507
 Ecthyma, 72
 Ectopia, 78, 126
 Ectopic pregnancy, see EXTRA-UTERINE PREGNANCY
 Ectromelus, 76
 Eczema, 71, 72, 73, 78, 142, 351, 358
 Egyptian chlorosis, 362; mummies, 1, 133
 Elasticity of organs, 30
 Elder pith, uses of, 368

- Electric contractility in body after death, 54; engine, 36, 236; fan, 11; light over post-mortem table, 12; òse, 41; shock, 75, 454, 506; treatment of aneurism, 154
- Electrocution, 7, 74, 454, 506
- Electrolysis, 105; aneurism treated by, 154
- Elephantiasis, 78, 155, 222, 227, 362
- Elephantiasis Arabum, see ELEPHANTIASIS
- Emaciation, 68, 139
- Embalming, 1, 302
- Emboli and embolism, 112, 115, 124, 144, 151, 152, 153, 154, 160, 163, 229, 285, 498; air, 112; fat, 163; of liver-cells, 224
- Embryos, fixation of, 380; measurements of, 397; method of determining age of, 397
- Emetine, toxicology of, 465
- Empysema of liver, 229; of lungs, 81, 105, 109, 148, 164, 165, 325, 499; of mediastinum, 106
- Empyema, 156, 169, 322, 329
- Encephalitis, 322, 495
- Enchondroma of ovaries, 219; of testicles, 222
- Encysted parasites, 100
- Endarteritis, 150, 151, 222, 269, 337
- Endocarditis (diphtheritic, fetal, fibrous, gonorrhœal, malignant, mycotic, rheumatic, septic, syphilitic, ulcerative, vegetative, verrucose, etc.), 48, 112, 139, 145, 146, 147, 151, 153, 202, 211, 220, 230, 314, 317, 320, 322, 325, 329, 330, 332, 334, 355, 356, 497
- Endocardium, diseases of, 144, 146, 332; examination of, 117
- Endocervicitis, 319
- Endocyma, 77
- Endometritis (atrophic, catarrhal, decidual, diphtheritic, fibrous, gangrenous, glandular, gonorrhœal, hypertrophic, interstitial, mycotic, purulent, syphilitic, tuberculous, ulcerative, villous, etc.), 220, 221
- Endophlebitis, Chiari's, 228; fibrous, 155
- Endothelioma of brain, 267; of lungs, 169; of lymph-vessels, 155; of ovaries, 219; of peritoneum, 172; of pleura, 170
- Endothelium, 152
- Engines, dental and trephining, 36
- Engorgement of lungs in pneumonia, 327
- Enlargement, see HYPERTROPHY
- Enostosis of bone, 287
- Ensiform appendix, 105
- Enteric fever, see TYPHOID FEVER
- Enteritis, 314, 362, 500
- Enteroliths, 183
- Enteroptosis, 70, 173
- Enterorrhagia, 142
- Enterotome, 37, 42, 43, 117, 408, 480, Figs. 31, 32
- Enzymes, toxicology of, 463
- Eosin and methylen blue stain, Jenner's, 369
- Eosinophiles, 130, 140, 362, 477
- Ephedrine, toxicology of, 464
- Epicardium, 113
- Epidemic affections, 492; cerebrospinal meningitis, 310, 326, 495; dysentery, 492
- Epididymis, 15, Figs. 117=119
- Epiglottis, 15, 17, 157, 338; examination of, 270
- Epilepsy, 260, 463, 496; cortical, 261; Jacksonian, 261
- Epilus, 258
- Epiphyses, condition of, in determining age, 67; fractures of, 141
- Epispadias, 78, 79
- Epistaxis, 142, 157
- Epithelial nephritis, 209
- Epithelioma, 72, 124, 156, 158, 221
- Equinia, see GLANDERS
- Equinum equiperdum, 366
- Erb's paralysis, 92
- Ergot, toxicology of, 463, 466, 473
- Ergotism, 73, 182, 460, 463, 465
- Erlicki's solution for fixing tissues, 375
- Eruptions, cutaneous, 71, 73
- Erysipelas, 49, 157, 178, 316, 326, 492
- Erythema, 71, 72, 73, 388
- Erythrocytes, 128, 129
- Erythromelalgia, 129, 150, 261
- Essential anæmias, 219
- Ether as a freezing agent, 370; toxicology of, 32, 264, 267, 463, 472
- Ethereal oils, 32, 467
- Ethyl chlorid, 41, 370
- Eustrongylus gigas*, 218
- Evisceration of cadaver, 17, 289, Fig. 94
- Exalgin, toxicology of, 465
- Examination, medicolegal, xxviii, p. 440; of abdominal cavity, vi, p. 89, x, p. 172; of animals, xxv, p. 407; of exterior of body, 53; of nasopharynx, eyes, and ears, xvi, p. 270; of new-born, xviii, p. 289; of plants, xxvi, p. 432; of skull and brain, xiii, p. 235; of thoracic cavity, vii, p. 103; order of, ii, p. 14; restricted, xix, p. 295
- Examiners, medical, 1
- Exanthematous typhus, see TYPHUS FEVER
- Excitomotor alkaloidal poisons, 463
- Exencephalus, 76
- Exhumation, 480
- Exophthalmic goitre, 83, 107, 162, 233, 495
- Exophthalmos, 272
- Exostosis, 142, 156, 287
- Expert, definition of, 438
- Expert testimony, 437, 438
- Exploratory punctures, 74
- Extrophy, 216
- Exterior of body, examination of, v, p. 53, 481

- Extrameningeal hemorrhage, 142
 Extra-uterine pregnancy, 101, 129, 218
 Extravasations, 142, 482
 Extremities of animal, removal of, 409
 Exudates, 31; chylous, 97; differentiation of, from transudates, 96; encapsulated peritonitic, at navel, 76; fibrinous, 111; hemorrhagic, 97; inflammatory, 96; milky, 97; suppurative, 97
 Eyes, diseases of, 33, 83, 85, 141, 230, 325, 340, 427, 430, 468, 497; examination of, 15, 16, 55, 83, xvi, p. 270, 297, 482, 488, Fig. 160
- F
- Face, examination of, 483
 Facial angle of Camper, 397
 Facies Hippocratica, 54
 Fæces, 182, 225, 412
 Fallopian tubes, diseases of, 218, 348; examination of, 17, 195, 486, Figs. 115, 116
 Falx, detachment of, 241
 Fan, electric, for ventilating, 11
 Farey, 318, 319, 492
 Fat, examination of, 68, 91, 113, 285, 396
 Fat embolism, 233, 285; necrosis, 99, 207, 231, 232
 Fatty degeneration, 143, 144, 145, 147, 150; of heart, 484; of kidney, 212; of liver, 223, 225, 228, 229; of marrow 281; of pancreas, 233, 234
 Fatty infiltration, 143, 144; of heart, 143; of liver, 206, 229; of pancreas, 232
 Favus of stomach, 203
 Fecal fistulae, 500
 Fehling's solution, 467
 Felon, 282, 355
 Female genital tract, diseases of, 218, 494; examination of, 193
 Femoral hernia, 101
 Ferments, autolytic, 152
 Fever, see the various fevers by name
 Fibrin, 151
 Fibroid heart, 119, 148
 Fibroma, Plate four; of bladder, 216; of bones, 287; of brain, 267; of breast, 70; of heart, 148; of intestines, 183; of kidney, 214; of larynx, 158; of liver, 230; of lungs, 169; of nasal passages, 156; of ovaries, 219; of peritoneum, 172; of pleura, 170; of prostate, 222; of testicles, 222; of tonsils, 158; of uterus, 219, 220; of vagina, 221
 Fibromyxoma in nasal passages, 156
 Fibrosis of aortic valves, 149; of heart, 144; productive, 155
 Ficker's test, 353
 Fig blight, 432
Filaria sanguinis hominis, 135, 155, 172, 212, 362
 Filicic acid, toxicology of, 463
- Finger, deformities of, 78
 Finger-cots, 40, 42, 47
 Finger-nails in syphilis, 336
 Finger-prints, 62
 Finger-stalls, 40, 42, 47
 Finsen light, 52
 Firearms, wounds by, 448, 506, Plate six
 Fish as cause of leprosy, 322; cancer of, 108
 Fish poisoning, 464
 Fissure, see FISTULA
 Fistula, bronchial, 159; cervical, 82; fecal, 500; tracheal, 159; tuberculous, 349; urethrorrectal, 79
 Fistula in ano, 347
 Fixation, choice of agents for, 371
 "Fixing" of "smear" preparation, 384
 Fixture, electric, gas, and water, 12, Figs. 12, 13
 Flax twine, 42
 Flaxseed poultices for post-mortem wounds, 51
 Flea (*Pulex*) as cause of disease, 306; as cause of plague, 325; common, 358; *Trypanosoma* of, 366
 Flemming's solution, 375
 Flies as cause of disease, 306
 Floating lobe of liver, 102
 Florence test, 459
 Fluid, ascitic, 95, 96, 109, 133, 368; embalming, 302; hydroceleic, 368; prevention of escape of, from large cavities, 41; removal of, from abdominal cavity, 95
 Flukes, 363
 Fluorescence, 444
 Fluorescin, 55
 Fly, Spanish, see CANTHARIDES; tsetse, 366
 Fœtus, absence of post-mortem rigidity in, 60; examination of, 289, 380; measurements of, 397; percentage of water in, 396; post-mortem expulsion of, 53
 Follicular conjunctivitis, 497
 Fontanels, examination of, 291, 398, 488
 Food, impurities of, 1
 Foot, ulcer of, 259, 482
 Foot-and-mouth disease, 317, 388, 407
 Foramen of Monro, opening of, 247; of Winslow, 204
 Foramen ovale, 118, 126
 Forceps, forms of, 38, 42, 43, 418, 480, Figs. 21, 40
 Foreign bodies in abdominal cavity, 99; in appendix, 184; of heart, 148; in larynx, 158; in stomach, 200; in uterus, 221
 Formad pocket-case, 42, Fig. 53; post-mortem record, 19
 Formalin (formaldehyd, formic aldehyd) toxicology of, 32, 463, 464, 473; uses of, 9, 27, 41, 42, 47, 69, 98, 245, 252, 302, 370, 377

- Formates, toxicology of, 467
 Formic acid, toxicology of, 467
 Fourth disease, Duke's, 324
 Fourth of July tetanus, 340
 Fractures, 30, 80, 81, 141, 163, 449, 506;
 compound, 280; of skull, 1, 236, 237,
 244; of vertebral column, 253, 483
 Fragilitas ossium, 258
 Fragmentation of heart, 143
 Framboesia, 317
 Freckles, 71
 French method of opening calvarium,
 238, Fig. 133; of opening dura, 239,
 Fig. 134
 Friedreich's ataxia, 257, 261; disease,
 257
 Fright, death from, 208, 472
 Frog, effect of strychnine on, 193
 Fropier's incision of spinal cord, 256
 Frozen bodies, 60, 302, 305, 481, 506;
 sections, 13, 370
 Fuchsin, toxicology of, 467
 Fungi, poisonous, toxicology of, 466
 Funnel-breast, 81
 Furuncle, 504
 Furunculosis, 72
- G**
- Gabbett's solution, 41
 Galactotoxismus, 460
 Gall-bladder, absence of, 226; bacterio-
 logic examination of, 205; cancer of,
 225; *Distoma hepaticum* of, 363; ex-
 amination of, 16, 101, 203, 204, 205,
 206, 426, Figs. 121, 122; inflammation
 of, 225; measurements of, 403
 Gall-ducts, examination of, 101, 486, 487;
 nematodes of, 361
 Gall-stones, 75, 101, 182, 200, 225, 226,
 229, 232, 501
 Galton's laws of inheritance, 3
 Gamboe, toxicology of, 463
 Ganglion, 287; cerebral, 16; cervical, 125;
 coeliac, 233; Gasserian, 297; semilunar,
 192; spinal (intervertebral), 320; Wris-
 berg's, 110, Fig. 74
 Ganglion cells, 136
 Gangrene, 49, 52, 71, 151, 234, 325, 355,
 504; carbolic acid causing, 468; of
 appendix, 184; of bladder, 216; of
 diabetics, 234; of extremities, 149; of
 intestines, 173; of legs, 332; of lungs, 31,
 159, 164, 165, 504; of lymph-glands,
 73; of mesentery, 173; of penis, 78;
 of tonsils, 158; of vagina, 221; senile, 150
Gangrène foudroyante, 177
 Gas, see EMPHYSEMA
 Gas fixtures over post-mortem table, 9,
 12, Figs. 12, 13
 Gases, deleterious, 462, 506
 Gas-forming organisms, 94
 Gasserian ganglion, examination of, 297
 Gastrectasis, 201
 Gastric contents, examination of, 41, 199,
 460; ulcer, 98, 199, 201, 500
 Gastritis (acute, alcoholic, atrophic, cat-
 arrhal, chronic, croupous, diphtheritic,
 glandular hypertrophic, mycotic,
 parenchymatous, suppurative, toxic,
 etc.), 136, 201, 202, 203, 362
Gastrophilus equi is frequently found in
 the stomach of the horse
 Gastroptosis, 70, 173
 Gastrorrhagia, 142
 Geese, relapsing fever of, 329
 Gelatin, uses of, 41, 379
 Gelatin of Wharton, 291
 Gelsemine, toxicology of, 463, 464
 General considerations, i, p. 1; paralysis of
 insane, 261
 Genitalia, diseases of, 136, 218, 222, 502,
 503; examination of, in animals, 405,
 409, 419, 430; female, examination of,
 15, 17, 193, 482, 486, 488, Figs. 106-
 114; male, examination of, 15, 17, 196,
 482, 485, 486, Figs. 117-119
 Genito-urinary tract, diseases of, xi, p.
 209, 347, 501
 Genu extrorsum, 81; G. valgum, 81, 282;
 G. varum, 81
 German measles, 331
 Gersuny's method, 3, 301
 Gestation, intra-uterine, period of, 444,
 487
 Giacomini's method of hardening brain,
 252
 Giant-cells, 342
 Giantism, 65
 Giemsa stain, 369
 van Gieson's stain, 369
 Gilford's disease, 258
 "Gill openings," 159
 Gilson's solution, 375
 Glacial acetic acid for detecting abra-
 sions of the hands previous to perform-
 ing postmortem, 45; for treating post-
 mortem wounds, 47, 50, 52
 Gland, mammary, see BREAST; parathy-
 roid, see PARATHYROID GLAND; pineal,
 see PINEAL GLAND; pituitary, see PITUI-
 TARY GLAND; sucking, 75; thymus, see
 THYMUS GLAND; thyroid, see THYROID
 GLAND
 Glanders, 48, 135, 156, 222, 318, 407, 492
 Glands, lymphatic, see LYMPHATIC
 GLANDS; mesenteric, in tuberculosis,
 100, 355
 Glandular fever, 319
 Glass balls, graduated, 39, Fig. 51; slides,
 41
 Glaucoma, 272
 Glioma of adrenals, 191; of brain, 267;
 of coccyx also occurs; of retina, 85
 Glisson's capsule, 206
 Globulin, 108, 133

Glomerulonephritis, 209
 Glossary index, 33, 508
Glossina palpalis, 366
 Glottis, œdema of, 465
 Gloves, rubber, 40, 42, 46, 47
 Glycogenic reaction of blood, 134, 206
 Glycosuria, 162, 233
 Gmelin's test for bile, 134
 Goat, meningitis of, 310; postmortem on, 407, 425
 Goitre, 83, 107, 108, 161, 162, 233, 260, 495
 Golgi's method, 369, 375
Gonococcus of Neisser, 135, 174, 221, 319, 385, 386, Plate five
 Gonorrhœa, 48, 78, 146, 156, 264, 283, 319, 326, 493
 "Goose-flesh" skin in drowning, 75
 Gout, 141, 145, 154, 276, 495
 Graduated cones, 39, Fig. 50
 Grains, 394
 Grammes, 394
 "Grand swipe," 125, Fig. 94
 Granular kidney, 209
 Granulations, Paechionian, 240, 241
 Granuloma of iris, 85; of lungs, 121
 Grape mildew, 432
 Graves's disease, see BASEDOW'S DISEASE
 Gray hair, cause of, 86
 Grippe, see INFLUENZA
 Gross specimens, preservation of, 6, 40, 41, 42, xxii, p. 368
 Growths, new, see the tumors themselves
 Guaiacol, toxicology of, 467
 Gudden's microtome, 250
 Guinea-pig, determination of rectal temperature of, 390, Fig. 183; how affected by X-rays, 222, 455; inoculation of, 390; postmortem on, 407, Fig. 187; *Trypanosoma* of, 367
 Gumma, 144, 336; of arteries, 152; of bone, 339; of brain, 267; of dura, 244; of kidney, 338; of liver, 228, 338; of lungs, 339; of respiratory tract, 338; of testicles, 338
 Gums, deposit of lead in, 465; diseases of, 465
 Gunshot wounds, 144, 444, Plate six
 Gutta-percha, liquid, 45, 47
 Gyrimus natator, toxicology of, 468

H

Hæmatemesis, 142
 Hæmathidrosis, 142
 Hæmatin, 269, 481
 Hæmatocele, 142, 221
 Hæmatoidin, 134, 211, 269
 Hæmatoma, 33, 142, 191, 210, 219, 288
 Hæmatoma polyposum, 219
 Hæmatometra, 142
 Hæmatomyelia, 261

Hæmatoporphyrin, 467
 Hæmatoporphyrinuria, 217
 Hæmatosalpinx, 218
 Hæmatoxilin, toxicology of, 467
 Hæmatozoa, 364
 Hæmaturia, 142, 217, 330
 Hæmochromatosis, 467
 Hæmoglobin, 126, 134, 135, 136, 137, 138, 139, 211; carbon-monoxid, 126, 474; reduced, 126; scale of, 126, Plate three
 Hæmoglobin spectra, 126
 Hæmoglobinuria, 211, 217
 Hæmolymp-nodes, 173, 176, 190, 417
 Hæmolysins, 463
 Hæmolysis, 60, 130
 Hæmopericardium, 110, 142
 Hæmophilia, 139, 143
 Hæmoptysis, 142, 163; parasitic, 363
 Hæmothorax, 142, 170
 Hair, care of, during postmortem, 235, Figs. 126-128; diseases of, 87, 336, 481; examination of, 15, 85, 86, 87, 445, 482, 488; growth of, after death, 86
 Hair-balls, 200
 Hairy heart, 111; tongue, 77
 Hallux valgus, 283
 Halsted's operation, 91
 Hamilton's method of hardening brain, 250
 Hammers, 37, 42, 43, 254, 408, 480, Figs. 21, 35
 Hand, amputation of, in spreading gangrene, 52; anointing of, at postmortem, 45, 46; care of, and treatment of post-mortem wounds of, iv, p. 45, 105, 242; condition of, before beginning autopsy, 45; disinfection of, 47
 Hand brushes, care of, 48
 Hand-bag for carrying instruments, 41
 Hanging, death by, 124, 456, 485, 505
 Hanging drop, 368
 Hangnails, 47
 Hanot's hypertrophic cirrhosis, 128
 Hardening of brain, advantages of, 245; of tissues, 371
 Harelip, 78
 Harke's method for examining nasopharynx, 270, Figs. 161, 162
 Hay fever, 157
 Head, actinomycosis of, 307; examination of, 16, 235, 482, 488; examination of, in animals, 420; measurements of, 397
 Head rests, 13, 40, Figs. 45, 46, 126, 127, etc.
 Headache, 257
 Health, Boards of, 1, 306, 382
 Heart, abnormalities of, 112, 115, 126; abscess of, 144, 145; actinomycosis of, 148; aneurism of, 110, 112, 144, 145, 150, 151; anthrax of, 309; asystolic,

Heart (*continued*)

- disease of, 173; atrophy of, 148, 149; carcinoma of, 148; chordæ tendineæ of, 15; circulation of lymph in, 113; coagula of, 128; color of, 112, 122; consistence of, 113; coronary arteries of, 15; *Cysticerci* of, 148; degenerations of, 143; dilatation of, 107, 119, 147, 159, 160; diseases of, viii, p. 126, 129, 130, 155, 497; double, 126; *Echinococci* of, 148; examination of, 15, 17, 112, 114, 115, 295, 485, 488, 489, Figs. **74-85, 164, 167**; examination of, in animals, 418, 419, 430; fatty degeneration of, 485; fibroid, 119; fibromata of, 148; foreign bodies in, 148; gummata of, 148; hemorrhage of, 224; hyaline degeneration of, 143; hypertrophy of, 107, 110, 112, 119, 142, 145, 147, 148, 150, 224; in asphyxiation, 113; in chlorosis, 136; in cholera, 312; in diabetes, 234; in digitalis poisoning, 113; in diphtheria, 145; in goitre, 162; in leucocythæmia, 137; in malaria, 365; in plague, 326; in pneumonia, 329; in poisoning, 461; in progressive pernicious anæmia, 135; in relapsing fever, 330; in rheumatism, 331; in scarlet fever, 332; in smallpox, 334; in typhoid fever, 355; in typhus fever, 356; in yellow fever, 357; incisions of, 114, 117, Figs. **76-85**; infiltrations of, 143, 145; leaflets of, 117; lipomata of, 148; lymphatics of, 15; lymphosarcomatosis of, 148; malformations of, 126; measurements of, 112, 400; military tubercles of, 148; muscle-fibres of, 143; myomalacia of, 148; myxomata of, 148; opening of, to discover air emboli, 112; papillary muscle of, 15; *Pentastomata* of, 148; plexus of, 15, 17, 110, 290, Fig. **74**; polypi of, 128, 148; rhabdomyoma of, 148; rigidity of, 113, 485; rudimentary, 126; rupture of, 144; sarcoma of, melanotic, 111; softening of, 146; suturing of, 3, 112; syphilis of, 144; thrombosis of, 128; trabeculæ of, 15; tuberculosis of, 144, 148, 348; tumors of, 148; ulcers of, 145; valves of, 15, 115; sclerosis of, 337; valvular lesions of, 210, 228, 331; volume of, 401; weighing of, 394; weight of, 118, 119, 396, 400; wounds of, 3, 112
- Heart muscle, color of, 119; consistence of, 119; fibres of, 143; fibrosis of, 337
- Heart-emboli, 308
- Heat-stroke, 7, 125, 455
- Heberden's nodosities, 277
- Height of body, 64, 65, 66, 395
- Hellebore, toxicology of, 466
- Helvella esculenta*, toxicology of, 465, 467
- Hemiatrophy, facial, 71
- Hemiplegia, 258, 261, 266
- Hemorrhage, 56, 93, 106, 111, 125, 130, 139, 140, 142, 153, 173, 203, 207, 215, 218, 220, 224, 231, 242, 244, 260, 261, 266, 268, 325, 452, 496, 498, 502, 503; per diapedesis, 142; per rhexin, 142; petechial, 203; post-partum, 142; punctate, 157; varieties of, 142
- Hemorrhagic infarct, 121, 122, 140, 142, 144, 151, 173, 177, 211
- Hemorrhoids (internal, external), 155, 215
- Henoch's purpura, 139
- Hepatic artery, 154, 204, Fig. **122**; duct, examination of, 205, Figs. **121, 122**; peritoneum, mechanical irritation of, 3
- Hepatitis, 228, 229, 338, 355
- Hepaticization, 327, 328, 489
- Hereditary ataxia, 261; chorea, 259
- Heredity, 3
- Hermann's solution, 375
- Hermaphrodite, 64
- Hernia, 15, 78, 82, 99, 101, 153, 500; of bladder, 216; of diaphragm, 99, 163, 207; of omentum, 172; of vagina, 221
- Herophilus, 1
- Herpes, 78, 259, 322
- Herpes zoster, 71, 261
- Hessee's method for test-tube culture, 389
- Heteralius, 77
- Heterotyphus, 77
- Hewson's preservative injection, 304
- Hexenmilch, 293
- Hey's saw, 35, Fig. **24**
- Hide of animal, removing of, 408, 428, 430
- Hip-joint, congenital dislocation of, 3, 76, 280
- Historical considerations, 1
- Hobnail liver, 206, 227
- Hodgkin's disease, 130, 138, 173, 326
- Hofmann's treatment of decomposed body, 57
- Hog, see Pig
- Homicide, 448
- Hone, 39, Fig. **21**
- Hoof, examination of, 430
- Hooks, double, 480
- Horns, examination of, 430
- Horse, death of, from electricity, 455; diseases of, 360; *Trypanosoma* of, 366; postmortems on, 407, 408, 409, 410, Figs. **189-193**
- Horse-flesh, specific blood-test for, 396
- Horseshoe kidney, 210
- Hour-glass contracture of stomach, 100
- Huntington's chorea, 259
- Hutchinson's teeth, 88, 339, 340
- Hyaline degeneration, 143, 150, 220
- Hydatids (see also *Echinococci*), 75, 360
- Hydræmia, 128, 129
- Hydrarthrosis, 276, 280
- Hydrocele, 78, 222, 459
- Hydrocephalus, 260, 261, 398

- Hydrochloric acid, toxicology of, 32, 469
- Hydrocyanic acid, toxicology of, 56, 57, 58, 128, 135, 189, 463, 467, 473
- Hydrofluoric acid, toxicology of, 462
- Hydromeningocele, 260
- Hydromyelia, 266
- Hydronephroma, 190
- Hydronephrosis, 193, 210
- Hydropericardium, 110
- Hydrophobia, see RABIES
- Hydrosalpinx, 218
- Hydrostatic test for pneumonia, 121, 122, 167, 419; for viability, 443, 489
- Hydrothorax, 170
- Hygroma, 287
- Hymen, 79
- Hyoid bone, fracture of, 81
- Hyoseyamine, toxicology of, 464, 465, 468
- Hyoscyamus*, toxicology of, 463, 464, 466
- Hyperæmia of brain, 242, 268; of liver, 228, 229; of lungs, 162; of spleen, 137
- Hyperinosis, 128
- Hypernephroma heterotopes of kidney, 215
- Hyperplasia, 137, 138
- Hypertrophy (see also the various organs), 27
- Hypnosis, 128
- Hypobromite solution, 47
- Hypodermic injections, 74; syringe for inoculation of animals, 390
- Hypogastric artery, Fig. 164
- Hypoplasia of aorta, 151; of cerebellum, 260; of circulatory and generative organs in chlorosis, 136; of uterus, 219
- Hypospadias, 78, 79
- Hypostasis, 113
- Hypostatic congestion of lungs, 58, 69, 164
- Hypothetic diagnosis, 440
- Hypsicephalic skull, 397
- Hysterectomy, vaginal, Figs. 106-114
- Hysteria, 257, 261, 496
- I
- Icard's test for presence of life, 55
- Ichthyosis, 72
- Ichthyotoxismus, 460
- Icterus, 57, 69, 130, 134, 183, 217, 227, 329, 365, 506
- Icterus neonatorum, 134
- Ictrogen, toxicology of, 465, 466, 467
- Identification of body, 61, 62
- Idiocy, 260
- I.-E. (immunity-unit) of German literature, 313
- Ileocæcal valve, 179, 182
- Iliac arteries, curvature of, 30; fossa, absence of, 501
- Illuminating gas for preserving the natural color of specimens, 378; toxicology of, 58, 264, 450, 473
- Imbibition, 60, 146, 487
- Immunity (an excellent series of articles appeared upon this subject in the 1905 numbers of the *Jr. of the Amer. Med. Assoc.*), 48, 50
- Immunity-unit, 313
- Impetigo, 72
- Inanition, 100, 460, 506
- Incense to remove odor, 42
- Incising heart, kidneys, etc., see EXAMINATION OF, under the names of the various organs
- Incubator, 41
- Index, altitudinal, 397; cephalic, 397; cryoscopic, 127
- Indican in urine, 217
- Indol, odor of, 32
- Induration, cyanotic, 147, 149; of liver, 206, 229; of skin, 73
- Infancy, early, diseases of, 505
- Infant, autopsies on, 443; new-born, autopsies on, xviii, p. 289
- Infanticide, 456
- Infantile paralysis, 262
- Infantilism, 258
- Infarets (air, anæmic, bilirubin, calcareous, fat, hemorrhagic, etc.), 121, 122, 140, 142, 144, 151, 152, 163, 164, 173, 177, 211, 213, 220
- Infection, post-mortem, 40, iv, p. 45; purulent, 492; septicæmic, 492; sources of, 33
- Infectious fevers, see the fevers themselves
- Inferior vena cava, 401, Fig. 122
- Infiltration, calcareous, 143; fatty, 143, 144, 206; hemorrhagic, 145
- Inflammation (catarrhal, croupous, diffuse, diphtheritic, phlegmonous, syphilitic, toxic, tuberculous, etc. The five cardinal symptoms of inflammation, heat, redness, pain, swelling, and interruption of continuity, may all be absent at postmortem, and yet inflammation may have existed at the time of death. Read Councilman's article in *Dennis's Surgery*, Adami's in *Allbutt's System of Medicine*, and Metchnikoff's comparative lectures on inflammation. Virchow's work on *Cellular Pathology* is of great historic value), 93, 213, 225, 244, 309
- Influenza, 130, 135, 156, 261, 264, 321, 326, 492
- Infusoria, parasitic, 359
- Infusorium balantidium coli*, 177
- Inguinal glands in plague, 326; hernia, 101
- Inheritance, laws of, 3
- Initial incision, 90, Figs. 58-62

- Injected specimens, 379
 Injecting fluid, 379, 380; syringe, 391, 480
 Injections, hypodermic, 74; of bodies, 302; Figs. **179, 180**; saline, 74
 Injuries, description of, 482; extent of, 30
 Innominate vein, care not to injure, 104
 Inoculated tubes, cultivation of, 389
 Inoculation of animals, intravenous, 391, Fig. **186**; intraperitoneal, 391, Fig. **185**; subcutaneous, 391, Figs. **184-186**
 Inoculum, preparation of, 389
 Inorganic chemic poisons, 462; irrespirable gases, 462; irritant poisons, 462
 Insane, general paralysis of, 261; malposition of organs in, 100
 Insanity, 257, 264; books of reference on, 264
 Insect galls, 432
 Insolation, 506
 Instruments, bacteriologic, 41, xxiii, p. 382; post-mortem, iii, p. 34; for animals, 407; in Army, 43; in Navy, 43; sterilization of, 34, 52
 Insurance in accident companies, 52
 Insurance standard of weight and height, 395
 Intercarotid bodies, 125
 Intercranial hemorrhage, 452
 Interments, premature, 53
 Intermittent fever, 491
 International system of nomenclature of diseases and causes of death, xxx, p. 491
 Interstitial nephritis, 62, 211; pancreatitis, 231; pneumonia, 166
 Intestines (see also COLON, RECTUM, DUODENUM, etc.), actinomycosis of, 308; adenoma of, 183; adhesions of, 178; bucket method of examining, 181, Fig. **97**; carcinoma of, 183, 201, 494; cleansing of, 180, 181; color of mucous membrane of, 181; diseases of, 181, 322, 500; *Echinococcus* of, 360; examination of, 15, 17, 46, 178, 179, 180, 484, 486, 487, 488, Plate one, Figs. **96-99, 164**; examination of, in animals, 408, 409, 413, 414, 416, 417, 428, 430; fibroma of, 183; gall-stones of, 182; gangrene of, 173; hemorrhage of, 142, 183; hernia of, see HERNIA; ileocaecal valve of, 179, 182; inflammation of, see PERITONITIS; lipoma of, 183; measurements of, 402; myoma of, 183; *Nematodes* of, 98, 361; obstructions of, 500; parasites of, 182, 500; perforation of, 213; polypi of, 181, 183; sand of, 183; sarcoma of, 183; serous covering of, 100; syphilis of, 337; tuberculosis of, 346; tumors of, 183, 494; tying of, 98, Fig. **96**; ulcers of, 140; weight of, 402
 Intima of carotids in strangulation, 124
 Intoxication, occupation, 495
 Intraperitoneal inoculation of animals, 391, Fig. **185**
 Intra-uterine gestation, determination of period of, 487
 Intravenous inoculation, 391, Fig. **186**
 Intraventricular septum, 114
 Intussusception (invagination), 101
 Iodin for staining of tissues, see LUGOL'S SOLUTION; toxicology of, 108, 461, 464, 465, 474
 Iodin index in determining presence of horse-flesh, 396
 Iodoform for post-mortem wounds, 51; toxicology of, 32, 463
 Iodoform celloidin solution, 42, 45
 Iodoform-dusting bottle, 42
 Iodothyrim, 108
 Ipecacuanha, toxicology of, 464
 Iris, 84, 85
 Iritis, 320, 322, 331, 336, 340
 Iron in liver, 136, 206; useful in axillary cellulitis, 51
 Irrespirable gases, organic and inorganic, 462, 463
 Irritant inorganic poisons, 462; organic poisons, 463
 Irritating dusts, toxicology of, 464; vapors, toxicology of, 464
 Ischiopagus, 77
 Islands of Langerhans, 232
 Itch, 504
 Itch-mite, 358
- J**
- von Jaksch's anæmia, 138
 Jalap, toxicology of, 466
 Jars, museum, 40, 42, 487, Fig. **202**
 Jaundice, see ICTERUS
 Jaw, actinomycosis of, 307
 Jejunum, peptic ulcer of, 182
 Jenner's stain, 369
 Jigger, 358
 Joints, diseases of, 80, 92, 141, xvii, p. 275, 279, 285, 287, 311, 336, 339, 350, 351, 353, 504; examination of, 16, 430, 482
 Jones, Admiral Paul, postmortem on, 62
 Jumping from high places, suicide by, 506
- K**
- Kairin, toxicology of, 467
 Kaiserling's method of preserving natural color of specimens, 377
 Kakke, 310
 "Kala-azar" of Assam, 367
 Karyokinesis, 218
 Keloid, 73
 Keratitis, 84, 336, 351
 Keratosis, 72

- Kidney (see also NEPHRITIS, BRIGHT'S DISEASE, etc.), abscesses of, 211, 213, 214, 220; absence of, 209; accessory, 209; adenocystoma of, 210; adrenal tissue in, 215; amyloid changes in, 209, 213; angioma of, 214; anthrax of, 310; atrophy of, 210; *Bilharzia hæmatobia* of, 212; bilirubin infarcts of, 211; blood-vessels of, 15; calcareous, 211; calculi of, 210, 214; cancer of, 214; capsule of, 15, 189, 209, 211; cicatricial bands of, 210; coalition, partial, of, 210; *Coccidia* in, 366; compensatory hypertrophy of, 211, 212; concretions in, 210; congenital defects of, 209, 210; congestion of, 160, 210; contracted, 209; cortex of, 15, 189, 212; cyst of, 210, 212; cystic, 209; *Cysticerci* of, 212; cystin stones of, 214; decapsulation of, 3, 190; degenerative changes in, 213; desquamation of, 213; diseases of, 129, 188, 209, 502; displacement of, by tumors, 212; *Distoma hæmatobium* of, 212; *Echinococci* of, 212, 360; embolism of, 147; examination, 194, 289, 295, 486, Figs. **100-104**, **166**; examination of, in animals, 393, 413, 414, 417, 419, 430, Fig. **191**; fatty changes in, 212; fibroma of, 214; *Filaria sanguinis hominis* of, 212; floating, 186; fluid in, 210; gouty, 211; granular, 189, 212; gumma of, 338; hæmatoma of, 210; horseshoe, 210; hypernephroma of, 215; hypertrophy of, 209, 212; in acute yellow atrophy, 244; in arteriosclerosis, 150; in cholera, 312; in cirrhosis of liver, 227; in diabetes insipidus, 141; in diphtheria, 314; in dysentery, 316; in erysipelas, 317; in Malta fever, 324; in pneumonia, 329; in relapsing fever, 330; in scarlet fever, 332; in smallpox, 334; in typhoid fever, 355; in yellow fever, 357; infarcts in, 211, 220; inflammation of, 212, 213; large white, 212; lipomata of, 214; liver-tissue in, 215; lobulation of, 210, 293, Fig. **166**; lymphadenoma of, 214; lymphoma of, 214; measurements of, 214, 403; medulla, 15, 189; method of distinguishing right and left, 188; movable, 212; myoma of, 214; myoma of, 214; necrosis of, 214; oxalate calculi of, 214; papilla of, 15; parasites in, 212; pelvis of, 15, 17; pelvis of, distension of, 210; *Pentastoma* of, 212; phosphate stones of, 214; pigmentary infarcts of, 213; poisons, effect of, on, 460; proliferation of, 213; pyramids of, 15; rhabdomyomata of, 214; right and left, distinguishing points between, 403; sarcoma of, 214; specific gravity of, 403; stones in, 214; *Strongylus gigas* of, 212; syphilis of,
- Kidney (*continued*)
 338; tuberculosis of, 214, 347; tumors of, 210, 214, 215; uric acid infarcts of, 189; vessels of, 187, 404; weight of, 394, 396, 403; xanthin stones of, 214
Klebs-Löffler bacillus, 160, 312, Plate five
 Knives, 34, 35, 42, 43, 44, 90, 408, 480, Figs. **14-20**; method of holding, 43, Fig. **54**, etc.
 Knock-knee, 81, 282
 "Knock-out drops," 472
 Koch controversy, 342
 Kolisko, postmortems by, 8, 435
 Kreotaxismus, 460
 Kromskop, 28
 Kyphosis, 108, 208, 257, 350
- L**
- Label, gummed, 42
 Labelling of tissues, 373, Fig. **202**
 Labia, diseases of, 155
 Labor, accidents of, 503; normal, 503; premature, 294
 Lacerations, 30
 Laking, 130
 Lamination of clots, 153
 Lamp, alcohol, 41, 42
 Landry's paralysis, 264
 Laparotomy wound, removal of organs by means of, 295
 Larcher's sign, 56
 Lardaceous degeneration, see AMYLOID DEGENERATION
 Large intestine, see INTESTINES
 Laryngitis, 157, 158, 324
 Larynx, diseases of, 157, 158, 257, 314, 321, 323, 334, 336, 355, 492, 498; examination of, 15, 17, 123, 485, 488; examination of, in animals, 418, 430
 Lateral curvature, 261; sinus, thrombosis of, 244, 332
 Lathyrism, 460
 Lavatories, 13
 Laveran's organism, 365
 Lead, toxicology of, 129, 150, 261, 262, 264, 452, 459, 460, 463, 464, 465, 466, 467, 474, 495
 Lecithin, 267
 Leiomyoma of uterus, 219
 Leishman-Donovan bodies, 367
 Lens, hand, 42, 480
 Leontiasis ossea, 258
 Leprosy, 69, 71, 72, 156, 222, 322, 323, 492
 Leptocephalic skull, 398
 Leptomeningitis, 154, 244, 262, 263
Leptothrix, 308
 Lesions, see diseases of the various organs, and the diseases themselves; multiple, 101
 Letulle's method of making autopsy, 17

- Leucin, 166, 223, 468
 Leucocytes, diameter of, 132
 Leucocythæmia, 31, 106, 127, 128, 130, 135, 136, 137, 138, 173, 175, 176, 177, 181, 214, 495
 Leucocytosis, 106, 130, 138, 139
 Leucoderma, 69
 Leucopenia, 130
 Leucoptasia, 337
 Leukæmia, see LEUCOCYTHÆMIA
 Lice, 68, 357, 366
 Lichen, 72
 Liebermeister grooves, 204
 Ligaments, examination of, in animals, 430; suspensory, of liver, 99
 Light for post-mortem examinations, 9, 12, 480; polarization of, 467
 Lightning, death by, 454
 Lindsay Johnson's mixture, 375
 Linæa albicantes, 70
 Lion-forceps, 38
 Lip, diseases of, 78, 339
 Lipæmia, 97, 130
 Lipoma, 70, 73, 75, 85, 148, 170, 183, 207, 214, 219, 287
 Liquefaction necrosis, 152
 Liquid court-plaster, 47
 Liquor antisepticus, 45
 Literature on postmortems (see also the second edition of this work, and the many foot-notes and references in the text of both editions), xxxi, p. 508
 Lithography and three-color printing, 28
 Lithopedion, 218
 Lithosis, 168
 Litmus paper, 41, 42, 480
 Litre, equivalents of, 395
 Little's disease, 266
 Liver (see also BILE DUCT, GALL-BLADDER, etc.), abscess of, 207, 223, 229, 315, 356; accessory lobes of, 102; acini of, 16; actinomycosis of, 308; adenocystoma of, 230; adenoma of, 230; adrenal tissue in, 215; albuminoid degeneration of, 224; amœbic abscess of, 207; amyloid degeneration of, 224; angioma of, 230; anthracosis of, 196, 226; anthrax of, 310; atrophy of, 106, 203, 211, 223, 224, 229, 468, 501; beaver-tailed, 204; blood-vessels of, 16; cancer of, 223, 230; capsule of, 16, 206; cirrhosis of, 97, 124, 177, 206, 226, 227, 232, 233, 365, 501; coal-dust in, 228; *Coccidia* of, 365; color of, 204, 224, 227; congestion of, 160, 228; consistency of, 206; cystic, 230; discoloration of, in ammonium hydrate poisoning, 29; diseases of, 129, 155, 210, xxi, p. 223, 321, 323, 501; *Distomum hematobium* of, 230; *D. hepaticum* of, 230, 363; *D. lanceolatum* of, 230; *Echinococci*
 Liver (*continued*)
 of, 230, 360, 501; emphysema of, 229; examination of, 16, 17, 101, 203, 204, 295, 486, Figs. 72, 75, 121, 122, 124, 125, 164; examination of, in animals, 393, 413, 414, 415, 417, 418, 428, 430; fatty degeneration of, 223, 225, 228, 229, 362; fatty infiltration of, 206, 229; fibroma of, 230; gumma of, 227, 228, 338; hemorrhage from, 224; hob-nailed, 206, 227; hyperæmia of, 228, 229; hypertrophic cirrhosis of, 227; hypertrophy of, 229; in cholera, 312; in diabetes mellitus, 234; in dysentery, 315; in erysipelas, 317; in Hodgkin's disease, 139; in leucocythæmia, 137; in Malta fever, 324; in measles, 324; in pneumonia, 329; in relapsing fever, 330; in smallpox, 334; in typhoid fever, 355; in yellow fever, 357; induration of, 229; infectious diseases of, 230; literature on diseases of, 223; lobulation of, 102, 206; measurements of, 402; melanosarcoma of, 33, 230; miliary tubercles of, 206; necrosis of, 224; nutmeg, 228; of babe, 290; parasites of, 230; passive congestion of, 228; *Pentastoma denticulatum* of, 230; poisons, effect of, on, 460; "porcelain," 102; *Psorospermia* of, 230; rachitic cirrhosis of, 228; rupture of, 33, 163, 223; sarcoma of, 230; situation of, 203; specific gravity of, 403; suspensory ligaments of, 99; syphilis of, 224, 227, 230, 335, 338, 340; tracings of, 204; traumatism of, 30, 228, 229; tuberculosis of, 206, 224, 230, 347, 349; tumors of, 125; volume of, 403; weight of, 394, 396, 402; "whisky and brandy," 227; yellow atrophy of, 106, 173, 357
 Liver-cells, emboli of, 224
 Liver-fluke, 363
 Liver-rot of sheep, 363
 Lividity, cadaveric, 57, 58, 60, 61, 69, 140
 Lobar pneumonia, see PNEUMONIA
 Lobeline, toxicology of, 464, 466
 Lobular pneumonia, see PNEUMONIA
 Lobulation, see KIDNEY, LIVER, etc.
 Locke's solution, 444
 Locomotion, diseases of organs of, 504
 Locomotor ataxia, see ATAXIA, LOCOMOTOR
 Loesch vs. Union Casualty and Surety Company, 5
 Löffler's alkaline methylen blue, 41
 Longitudinal sinus, 16, 128, 241, 483
 Lordosis, 208, 283
 Lorenz's operation, 3
 Luer's rhachiotome, 35, 254, 483, Fig. 26
 Lugol's solution, 41, 178, 224, 369
 Lumpy jaw, 306

- Lung, aberrant tissue of, 172; abscesses of, 162, 220, 355; actinomycosis of, 162, 307; adenoma of, 169; air embolism of, 163; alveoli of, 15; amyloid bodies of, 165; anæmia of, 163; anthracosis of, 109, 122, 168; anthrax of, 309; apoplexy of, 122, 163; atelectasis of, 121; blebs of, 121; bone in, 121, 169; brown induration of, 163, 164; calcified tubercles of, 121; cancer of, 169, 201; carnification of, 328; cavities of, 122; chondroma of, 169; cicatrices of, 121; circulatory disturbances of, 163; cirrhosis of, 148; *Coccidia* in, 366; collapse of, 162; color of, 109, 121, 122, 168, 169; congestion of, 148; consolidation of, 122, 148; crepitation of, 121; *Cysticercus cellulosæ* of, 166; dermoid cysts in, 169; differentiation of left from right, 121; diseases of (see PNEUMONIA, TUBERCULOSIS, etc.), ix, p. 156; *Distoma hæmatobium* of, 166; *Echinococcus* of, 360; embolism of, 147, 163; emphysema of, 109, 121, 164, 165, 499, Fig. 87; endothelioma of, 169; examination of, 15, 109, 120, 121, 122, 295, 484, 485, 489, Plate one, Figs. 72, 86-89, 94, 164; examination of, in animals, 393, 418, 430, Fig. 189; fat embolism of, 163; fibroid changes in, 328; fibroma of, 169; gangrene of, 31, 159, 164, 165, 355, 499; glands of, 318; gunma of, 339, 340; hemorrhage of, 121, 163, 345; hepatization of, 121, 327, 328, 345; hydrostatic test of, 121, 122, 167, 419, 443, 489; hypostatic congestion of, 164, 443; in cholera, 312; in diabetes mellitus, 234; in dysentery, 312; in pneumonia, 327; in relapsing fever, 330; infarcts of, 121, 122, 163, 164, 220; infectious granulomata of, 121; inflammation of, see PNEUMONIA; liquid in, 121; lobes of, 15, 120; lobules of, 15; measurements of, 401; melanosis of, 169; microscopic examination of scrapings of, 122; miliary tubercles of, 121; œdema of, 164; osseous formations in, 121, 169; osteoma of, 169; palpation of, 121; parasites in, 166; parenchyma of, 121; passive congestion of, 164; pigmentation of, 121; sarcoma of, 169; specific gravity of, 122, 402; *Strongylus* of, 166; syphilis of, 339, 340; thrombosis of, 163; traumatism of, 169; tuberculosis of, 121, 163, 168, 169, 217, 284, 325, 334, 339, 340, 492; tumors of, 121, 169; vesicular emphysema of, 165; vessels of, 15; viability of child determined by examination of, 443, 489; weight of, 121, 394, 396, 401
- Lupinotoxin, toxicology of, 465
 Lupus vulgaris, 72, 156, 352
 Luxations, 253, 506
- Lye, stricture due to, 124
 Lymph, circulation of, in heart, 113; collections of, mistaken for other lesions, 100
 Lymph stasis, 155; tumors, 155
 Lymphadenitis, 332
 Lymphadenoma, 138, 139, 214
 Lymphangiectasis, 362
 Lymphangitis, gangrenous, 73
 Lymphangioma, 123, 155
 Lymphangioma cysticum, 155
 Lymphatic glands, diseases of, 51, 138, 169, 201, 207, 314, 319, 329, 331, 351, 498; examination of, 15, 17, 393, 419, 430, 485
 Lymph-follicles, necrosis of, 353
 Lymph-glands, diseases of, 353
 Lymph-nodes, 16
 Lymphocytosis, 130, 231
 Lymphoid tissue, 138, 139
 Lymphoma, 158, 161, 214
 Lymphosarcoma, 138, 139, 148, 161
 Lymphotoxæmia, 294
 Lymph-vessels, 16, 155
 Lysol, 47, 463, 467
 Lyssa, see RABIES
- M
- Macrocytes, 135
 Macrocytosis, 129
 MacroGLOSSIA, 77, 155
 Macroscopic specimens, preservation of, 6, 40, 41, 42, xxii, p. 368
 Macrostoma, 77
 Macules, 71
 Madura foot, 308
 Magnesium oxid, toxicology of, 452
 Magnifying-glass, 39, 480
 Magnus's test for circulation, 55
Mal de cadéras, 366
 Malachite green, toxicology of, 464
 Malacia, 30
 Malaria, 71, 130, 134, 226, 261, 264, 326, 364, 365, 407, 491
 Male fern, toxicology of, 464
 Male genital tract, see GENITALIA, MALE
 Malformations, 30, 65, 76, 126, 156, 196, 505
 Malignant angina, see DIPHTHERIA; disease, see CANCER and SARCOMA, under the various organs; endocarditis, 139; œdema, 49, 393; pustule, 309, 492
 Mallein, 318
 Mallet, 42
 Mallory's stain, 376
 Malpractice, 437
 Malta fever, 128, 135, 323
 Mammary glands, diseases of, 91, 325, 352; examination of, 91, 293
 Mania, 130, 325
 Manometer, 55
 Marchi's method, 375
 Marine-Hospital Service, autopsies in, 23

- Marrow, 105, 130, 137, 281, 430
 Mask, death, making of, 305
 Masland's electric saw, 37, Fig. 27
 Massachusetts General Hospital, apparatus for transportation of bodies at, 11, Fig. 9
 Massage, stiff joints prevented by, 52
 Mastoid processes, examination of, 274
 Matrix of nails, suppuration of, 52
 Maturity, determination of, 444, 487
 Maxilla, alveolar compartments in, 445
 McKinley, President, postmortem on, 6
 Measles, 31, 71, 72, 130, 156, 157, 283, 324, 326, 388, 491
 Measles of pork, see *Trichina spiralis*
 Measurements (see also the various organs and parts), 38, xxiv, p. 394
 Measuring-glass, 39, 42, 480
 Meat, diseases of, 343
 Meat-axe, 408
 Meckel's diverticulum, 30, 178, 180, 355
 Meconium, 225, 293, 489
 Media, see CULTURE-MEDIA
 Mediastinitis, 106, 111, 161
 Mediastinum, diseases of, 106, 111, 112, 161; examination of, 15, 106, 485
 Medical examiners, 1
 Medicine, changes in urine after administration of, 466; practice of, compensation in, 437
 Medicolegal postmortem, difference of, from pathologic postmortem, 2, 440; form of report in, 440, 489; Prussian regulations for performance of, xxix, p. 479
 Medicolegal references, see second edition of this book; suggestions, xxviii, p. 436
 Mediterranean fever, 128, 135, 323
 Medulla oblongata, examination of, 16, 247, 483
 Medullary leukæmia, see LEUCOCYTHÆMIA
 Megaloblasts, 135
 Megalocytes, 135
 Melanæmia, 134
 Melanin, toxicology of, 467
 Melanoma of adrenals, 191
 Melanotic sarcoma, 107, 134, 169, 191, 217
 Melanuria, 467
 Melnikow-Raswedenkow fluid, 378
 Mendel's law (a law of heredity experimentally shown to exist by Mendel in 1865, and but recently rediscovered, according to which one-fourth of the characteristics will be like each parent and the other half will possess recessive attributes), 3
 Ménière's disease (aural vertigo)
 Meninges, examination of, 16
 Meningitis, 48, 49, 264, 269, 310, 311, 322, 325, 326, 329, 331, 332, 356, 493, 495
 Meningocele, 77
Meningococcus, 310
 Meningo-encephalitis, 33, 263, 352
 Menopause, 220
 Menorrhagia, 142
 Menstruation, vicarious, 142, 143
Mentha pulegium, toxicology of, 466
 Menthol, toxicology of, 467
 Mercaptan, 32
 Mercuric bichlorid soap, 47
 Mercury, toxicology of, 71, 221, 261, 264, 460, 462, 463, 464, 465, 467, 468, 475
 Mercury, bichlorid of, for dressings, 42; for fixing tissues, 373, 375; toxicology of, see MERCURY, TOXICOLOGY OF
 Mesarteritis, 151
 Mesenteric artery, aneurism of, 154, 173, 417; glands, 100, 355
 Mesentery, diseases of, 97, 172, 173, 183, 349; examination of, 15, 16, 17, 172, 486, Fig. 122; examination of, in animals, 412, 413, 414, 417, 426, 430, Fig. 191
 Mesocephalic skull, 397
 Mesorectum, examination of, in animals, 412, 414
 Metabolism, 135
 Metallic poison, postmortem on case of, 46
 Metals, acid salts of, toxicology of, 466
 Metapagus, 76
 Metastatic abscesses, 135, 145
 Meteorism in animals, 409
 Methæmoglobin, 128, 467
 Methæmoglobinæmia, 460
 Methyl alcohol, toxicology of, 32, 475
 Methyl chlorid, 41; as a freezing agent, 370
 Methylen blue, eosinate of, 369; Löffler's alkaline, 41; toxicology of, 467
 Methylen green, 369
 Metric system, 394, 482
 Metritis, 319, 502
 Metrorrhagia, 142
 Meynert's method of examining brain, 246, 248, Fig. 149
 Microcephaly, 260
 Microcephalic skull, 398
Micrococcus, 387; *M. albus*, 387; *M. cattarrhalis*, 327; *M. citreus*, 387; *M. gonorrhææ*, 386; *M. melitensis*, 323, 387
 Microcytes, 135
 Microcytosis, 129
 Microglossia, 77
 Micromegaly, 258
 Mieromyelia, 260
 Micro-organisms, Plate five; anaërobic, 385, 389; classification of, 385; cultures of, 389; diseases due to, xxi, p. 306; effect of, on urine, 466; found at postmortem, 395; in appendicitis, 184; in peritonitis, 174; odor due to, 31; pathogenic, 48, 389; study of, 24; uses of, 432; virulence of, 49, 50

- Microscope, 41, 368, 388, 481
 Microscopic examination at postmortem, 24, 41, 42, 368, 370, 481
 Microsomnia, 80
Microspironema, 335
 Microtome, freezing, 35, 41, 250
 Microtome knife for incising spinal cord, 255
 Middle ear, diseases of, 263, 314, 324, 332
 Miliaria, 72
 Miliary fever, 388, 492; tuberculosis, see TUBERCULOSIS, MILIARY
 Milk, abnormal color of, 91
 Milk spots, 111, 113
 Milky exudate, 97
 Mineral acids, toxicology of, 466
 Mirbane, toxicology of, 452
 Mitral orifice and valves, 118, 144, 147, 400
 Mnemonic for situation of valves and leaflets of heart, 118
 Moisture scale, 127, Plate three
 Moles, 69, 71, 482
 Mollities ossium, 284
 Molluscum contagiosum, 366; *M. fibrosum*, 73
 Monkey, trypanosomes of, 366
 Monsters, 76
 Morbidity statistics, 491
 Morbilli, see MEASLES
 Morgue, 10, 305
 Morphine, effect of, in accelerating death by electricity, 455; toxicology of, 455, 459, 460, 463, 464, 465, 466, 467
 Morphœa, 71, 73
 Mortopsy, see POSTMORTEM
 Mortuary room, 11, 13
 Morvin, 318
 Mosquitoes as disseminators of dengue, 407; of disease, 306; of malaria, 407; of yellow fever, 407
 Mother's mark, see NÆVUS
 Moulds, see HYPHOMYCELES
 Mouse, anthrax of, 393; as a cause of pneumonia, 327; effect of electricity on, 455; inoculation of, Fig. 184; malignant œdema of, 393; postmortem on, 407
 Mouth and its adnexa, diseases of, 77, 339, 341, 346, 499; examination of, 15, Figs. 90, 91, 173, 174
 Movable kidney, 212
Mucor mucedo, 166
 Mucous canals, ascending currents in, 33; fever, see TYPHOID FEVER; patch, 336, 338
 Müller's fluid, 42, 245, 250, 252, 375
 Multiple lesions, 101
 Mummification, 57
 Mumps, 283, 324, 326, 388
 Murder, first degree, medical expert in cases of, 462
 Murexid test, 217
 Muscular atrophy, central, 275; progressive, 257
 Muscarine, toxicology of, 464, 465, 466
 Muscles, diseases of, 43, 59, 60, 92, 93, 94, 123, 136, 147, 311, 319, 355, 356, 359, 362, 396; examination of, 16, 92; examination of, in animals, 430
 Museum jars, 40, 42, Fig. 202
 Mustard, 47; oil of, toxicology of, 464
 Mycetoma, 308
Mycobacterium lepræ, 322, 387; *M. tuberculosis*, 387, Plate five
 Myelitis, 215, 264
 Myelocytes, 130
 Myelocytosis, 130
 Myelogenous leukæmia, 130
 Myelomeningocele, 260
 Myelotome, Pick's, 35, 243, Fig. 20
 Myiasis, 359
 Myocarditis (fibroid, interstitial, parenchymatous, segmentary, etc.), 143, 144, 145, 148, 234, 308, 320, 329, 330, 332, 334
 Myocardium, examination of, 117
 Myofibroma of uterus, 219
 Myoma, 70, 158, 214, 216, 219, 220, Plate four
 Myomalacia cordis, 144, 146
 Myosarcoma of uterus, 219
 Myositis, 93
 Mytilotoxismus, 460
 Myxœdema, 73, 107, 108, 162
 Myxoma, 70, 156, 214, 222, 288, Plate four
- N**
- Nabothian cysts, 221
 Nævus, 71, 73, 152
 Nagana, 366
 Nails, 15, 52, 87, 488
 Narcotics, toxicology of, 466
 Nasal fossæ, diseases of, 142, 156, 157, 158, 311, 313, 318, 323, 339, 498; examination of, 15, 16, 245, 270, 297, 430, 488, Figs. 161, 162, 173, 174
 Nasopharynx, examination of, 270, Figs. 160-162
 Nauwerck's method of discovering seminal vesicles, 197, Fig. 120; of embalming, 303
 Navel, see UMBILICUS
 Navy, United States, autopsies in, 22
 Neck, diseases of, 75, 78, 80, 82, 307; examination of, 90, 482, 483, 485, Figs. 90, 91; examination of, in animals, 418
 van Neek's picture of Ruysch, the anatomist, Fig. 165
 Necropsy, see POSTMORTEM
 Necrosis (coagulation, colliquative, fat, liquefaction, molecular, etc.), 73, 85, 88, 99, 141, 147, 152, 207, 214, 215, 224, 233, 282, 357

Necrospemia, 222
 Needle, aneurism, 43; post-mortem, 40, 42, 43, 408, 480, Fig. 21
 Needles, tarnishing of, in living muscle, 55
 Negri bodies, 320, 451
 Negroes, bones of, 67; color of skin of, 69; malaria in, 364
Nematode, 361
 Neoplasm, see TUMOR
 Nephritis (acute, chronic, desquamative, diffuse, epithelial, fibrous, glomerular, interstitial, parenchymatous, subacute, tubular, vascular, etc.), 62, 110, 130, 140, 151, 189, 209, 210, 211, 212, 213, 234, 322, 323, 324, 330, 331, 332, 334, 338, 356, 357, 501
 Nephrolithiasis, see CALCULI, OF KIDNEY
Nerium, toxicology of, 466
 Nerves, diseases of, 56, 85, xv, p. 257, 310, 321, 337, 341, 497; examination of, 16, 242, Fig. 140
 Nettles, toxicology of, 464
 Neuralgia, 257, 324, 496
 Neurasthenia, 201, 257
 Neuritis, 259, 264, 310, 314, 388
 Neuroglia, 265
 Neuroma, amputation, 504
 Neurons, 257, 258
 Neuropathology, xv, p. 257
 Neuroretinitis, 233
 Neutral red, 369
 Neutrophilic whites, 135
 New-born departing from hospitals without having been sick, 505; determination of maturity of, 293, 443, 444, 488; evisceration of, 289; examination of, xviii, p. 289, Figs. 164-172; viability of, 293
 New growths, see TUMORS, under the names of the various organs and parts
 Nicotine, toxicology of, 32, 463, 464, 465, 466
 Nipple, infection of, 70; Paget's disease of, 70; supernumerary, 70; tuberculosis of, 352
 Nissl's staining method, 375
 Nitric acid, toxicology of, 461, 465, 469
 Nitrites, toxicology of, 128
 Nitrobenzol, toxicology of, 32, 135, 452, 465, 475
 Nitroglycerin, toxicology of, 465
 Noma, 313, 332
 Nomenclature of diseases and causes of death, international system of, xxx, p. 491
 Non-puerperal diseases of breast, 503
 Non-venereal diseases of genital organs of male, 502
 "Normal" as used in pathology, 24, 489
 Normoblasts, 135
 Nose, see NASAL FOSSÆ

Note-book, 42
 Notes, post-mortem, 24, 441, 481, 489
 Nothnagel's method, 246
 Nozzle, injecting, 480
 X-rays, 444
 Nuck, canal of, ovary in, 79, 219
 Nutmeg, toxicology of, 475
 Nutrition, 14, 68, 482
 Nux vomica, toxicology of, 468

O

Obducent (one who makes a medicolegal postmortem), 441, 489, 490
 Obduction, 2
 Obesity cordis, 143
 Obesity, 130, 396
 Objects used for comparison of size and shape, 27, 28, 431, Plate two
 Obstructions, intestinal, 500
 Occult blood, 182
 Ochronosis, 217, 234, 278
 Odontoma (tooth tumor)
 Odor of certain diseases, 31, 97, 487; of certain drugs, 31, 32, 466; of certain organisms, 31; post-mortem, removal of, 11, 47, 302
 Oedema, 31, 49, 62, 70, 71, 73, 91, 130, 137, 140, 157, 160, 164, 209, 213, 309, 362
 Oesophagus, abscess of, 200; cancer of, 124; dilatation of, 124; diphtheria of, 124, 314; diseases of, 321, 500; diverticula of, 124, 198, 200; epithelioma of, 124; examination of, 15, 16, 17, 122, 123, 124, 199, 200, 289, 468, 485, 487, 489, Figs. 90-94; examination of, in animals, 413, 415, 418, 426, 428, 430; longitudinal folds of, 200; measurements of, 200, 402; peptic ulcer of, 124; removal of, in one piece with tongue, trachea, and adjacent structures, and subsequent examination of, 122; rupture of aneurism into, 200; stenosis of, 337; syphilis of, 124, 337; thrush of, 124, 341; tuberculosis of, 124, 346, 351; tumors of, 124, 200; typhoid ulcer of, 124; ulcers of, 124, 200, 337; veins of, 124; weight of, 402
Oidium albicans, 341
 Oil, ethereal, of mustard, toxicology of, 466; of turpentine, toxicology of, 466
 Oiled silk, 42
 Ointment, carbolic acid, 45
 Oligæmia, 129, 176
 Oligocythæmia, 129
 Omentum, diseases of, 30, 172, 349, 366; examination of, 15, 17, 99, 172, 430, 486
 Omphalomesenteric duct, 99
 Omphalopagus, 77
 Omphalositic monsters, 76
 Onychia, 234

- Operating table, 9, 11, 12, Figs. 1-4, 11, 12
- Operation, Halsted's, 91; Lorenz's, 3
- Ophthalmia, 48, 330, 386
- Opium, toxicology of, 32, 84, 182, 463, 464, 466, 476
- Opsonin ("preparation for a meal"—that quality of a serum which makes a microbe more easily ingested by the phagocytes)
- Optic nerve, 85, 258, 311; thalamus, examination of, 483
- Optical differentiation, 374
- Oral cavity, examination of, 296; examination of, in animals, 418
- Orang-outang, intestinal infection from *Balantidium coli* in, 359
- Orbit, diseases of, 85; examination of, 245
- Orethritis, 322, 324, 325, 329, 338, 355
- Order of examination, ii, p. 14, 429, 486
- Organic acids, salts of, toxicology of, 466
- Organisms, see MICRO-ORGANISMS
- Organs (see also the organs themselves), general considerations concerning, 14, 25, 26, 27, 28, 29, 30, 102, 128
- Ornithodoros savignyi*, 358
- Orthocephalic skull, 397
- Orthognathous skull, 398
- Orth's fluid, 370, 375
- Os calcis, 293
- Öse, 41, 42, 389
- Osler's disease (chronic cyanosis), 138
- Osmic acid as a fixative, 369; odor of, 32
- Ossification, centres of, 79, 292
- Osteitis, 283, 284
- Osteitis deformans, 81, 258, 284
- Osteo-arthropathy, 284; hypertrophic pulmonary, 258
- Osteochondral line in syphilis, examination of, 292, Figs. 170, 171
- Osteogenesis imperfecta, 258
- Osteoma, 156, 169, 170, 222, 267, 287
- Osteomalacia, 30, 81, 130, 284
- Osteomyelitis, 145, 236, 281, 323
- Osteophytes, 277, 282, 287
- Osteoporosis, 278, 283, 351
- Osteosclerosis, 283
- Otitis media, 329, 351
- Otocephalus, 76
- Outline charts for recording the situation and extent of lesions, 26, Plate one
- Ovaritis, 319
- Ovary, abscess of, 218; absence of, 219; actinomycosis of, 308; adenoma of, 219; angioma of, 219; atrophy of, 219; calcifications of, 219; cancer of, 219; cystomata of, 76, 219, 502; dermoid cysts of, 191, 219; enchondroma of, 219; endothelioma of, 219; examination of, 15, 17, 219, 419, 486, Figs. 115, 116; fibroma of, 219; fibromyoma of, 219; hypertrophy of, 219; in canal of Nuck, 79, 219; in mumps, 219, 325; lobes of, 219; measurements of, 405; myoma of, 219; prolapsed, 219; psammocarcinoma of, 219; sarcoma of, 219; supernumerary, 219; transplantation of, 3; tuberculosis of, 219, 348; tumors of, 219, 502; weight of, 396, 405
- Oviducts, see FALLOPIAN TUBES
- Ox, accessory adrenals of, 190; diseases of, 360; *Tenia saginata* of, 360
- Oxalate stones of kidney, 214
- Oxalic acid, calculi of, 214; toxicology of, 459, 460, 461, 466, 467, 468, 469; use of, 47
- Oxamid, toxicology of, 466, 468
- Oxybutyric acid, toxicology of, 463
- Oxycephalic skull, 398
- Oxyhæmoglobin, 474
- Oryzias vermicularis*, 200, 361
- Oysters, poisoning by, 333
- Ozæna, 313, 332

P

- Pacchionian bodies (granulations), 16, 240, 241, 279
- Pachycephalic skull, 398
- Pachydermia laryngis, 158
- Pachymeningitis, 241, 244, 262, 264
- Paget's disease, 70, 366
- Pails used in autopsies, 41
- Palate, 15, 77, 123, 418, 430, 485, Fig. 91
- "Pale" as used in pathology, 28
- Palpation of organs, 29, 431
- Palsy, birth, 266
- Paludal fever, see MALARIA
- Panarium, 282
- Panarthritides, 275
- Pancreas, accessory, 199, 230; acini of, 16; anomalies of, 230; apoplexy of, 231; atrophy of, 233; blood-vessels of, 16; calculi in, 207; cancer of, 102, 207, 210, 233; cysts in, 207; degenerations of, 207; diseases of, 130, 207, xii, p. 230; examination of, 16, 17, 198, 207, 486, Figs. 121, 122; examination of, in animals, 413, 414, 415, 416, 426, 428, 430, Fig. 198; fat of, 16; fatty degeneration of, 233, 234; fatty infiltration of, 232; hemorrhages in, 207, 231; hyaline degeneration of, 232; lobulation of, 232; measurements of, 405; necrosis of, 233; pigmentation of, 232; specific gravity of, 405; syphilis of, 231, 232; tuberculosis of, 231; tumors of, 207; weight of, 394, 404
- Pancreatin, 369
- Pancreatitis (gangrenous, hemorrhagic, interaccinous, interstitial, syphilitic, etc.), 231, 232
- Panniculus adiposus, 91

- Papilloma, 124, 158, 161, 193, 216
 Papules, 72
 Paquelin thermocautery, 41
 Parabanic acid, toxicology of, 466
 Paracephalus, 76
 Paracolon infections, 181, 355
 Paraffin, injection of, to restore parts, 3, 301
 Paraffin method of preparing tissues for section, 320, 376
 Paraglobulin, 133
Paragonimus Westernmanii, 363
 Paraldehyd, toxicology of, 32, 496
 Paralysis, 464; atrophic spinal, 262; bulbar, 257; diver's, see CAISSON DISEASE; Erb's, 92; essential, of children, 262; facial, 81; general, of insane, 261; infantile, 262, 265; juvenile, 92; Landrey's, 264; pseudohypertrophic muscular, 92; spastic, 265, 266
 Paralysis agitans, 261, 264
 Paralytic dementia, 259
Paramecium coli, 359
 Paramidophenol, toxicology of, 467
 Paramyoclonus multiplex, 257
 Paraplegia, 81; ataxic, 261
 Paraplegia dolorosa, 267
 Parasites, see the parasites themselves, especially under the organs; diseases due to, 32, 77, 100, 129, xxi, p. 306, 357, 500
 Parasitic hæmoptysis, 363
 Paratyphoid fever, 128, 134, 135, 181, 356
 Parathyroid glands, 15, 107, 108
 Parchment-like spots, 75
 Purgative to remove post-mortem odor from hands, 47
 Parenchymatous myocarditis, 145; myositis, 93; nephritis, 212
 Parkinson's disease, 264
 Parotid gland, examination of, 483
 Parotitis, 274, 312, 324, 325, 339; cæliac or splanchnic, 274
 Parrot's nodes, 340
 Pasteur treatment, 320
 Patch, mucous, 336
 Pathogenic animal parasites, 357; bacteria, 48, xxi, p. 306, 386
 Pathologic diagnosis, 24, 67, 431
 Pathology, plant, xxvi, p. 432
 Patient and physician, relations of, 436, 437
 Pediculosis, 71
Pediculus capitis, 357; *P. corporis*, 357; *P. pubis*, 357; *P. vestimenti*, 357
 Peduncles of brain, 16
 Pelades, 504
 Peliosis rheumatica, 71
 Pellagra, 388, 460, 463, 468, 475, 492
 Pelvic cavity, examination of, 17, 486; organs, removal of, *en masse*, 17, 289, Fig. 94
 Pelvimeter, 42, 480
 Pelvis, exenteration of, in animals, 419; female, characteristics of, 67
 Pemphigus, 72, 339
Penicillium brevicaulis, 32, 471
 Penis, 15, 78, 196, 230, 409, 419, 420, 486, Figs. 117-119
 Pennsylvania Hospital, Ayer Clinical Laboratory of, 11, 18, Fig. 4
Pentastoma, 148; *P. constrictum*, 359; *P. denticulatum*, 178, 230; *P. tenioideus*, 359
 Pepper dust, toxicology of, 464
 Peptic ulcers of œsophagus, 124
 Perforating ulcer of foot, 259
 Periarthritis, 151, 154, 232
 Periostitis, 275
 Peribronchitis, 161
 Pericarditis (adhesive, fibrous, gonorrhœal, productive, rheumatic, suppurative, etc.), 106, 110, 111, 159, 161, 314, 320, 322, 329, 330, 332, 334, 355, 497
 Pericardium, adhesions of, 114; blood in, 110; cancer of, 110, 111; *Coccidia* in, 366; *Cysticerci* in, 111; *Echinococci* in, 111; examination of, 15, 17, 29, vii, p. 103, 190, 484, 485, 488, Figs. 72-75, 80, 164, 167; examination of, in animals, 418, 428, 430; exudate in, 110; fluid in, 110; foreign bodies in, 111; gas in, 111, 112; gummata in, 111; hemorrhage of, 111, 332; rupture of aneurism into, 154; sarcoma, melanotic, of, 111; *Trichina* in, 111; tuberculous of, 110, 111; villoid projections of, 111; wounds of, 112
 Perichondritis, 158
 Perihepatitis, 223
 Perinephric abscess, 213
 Periosteum, examination of, 16
 Periostitis, 85, 285, 355
 Peripheral nerves, diseases of, 323; examination of, 16, 256
 Periphlebitis, 206, 228, 229
 Perisplenitis, 227, 347
 Peristalsis, reversed, 182
 Perithelioma of carotid body, 125
 Peritoneal fluid, 109; specimen of, from inoculated animal, 393
 Peritoneum, 94; aberrant tissues in, 172; actinomycosis of, 172; cancer of, 97, 173, 201, 494; *Coccidia* in, 366; *Cysticerci* of, 359; cysts in, 172; *Distoma hepaticum* of, 172; endothelioma of, 172; examination of, 15, 172, 410, 430; fibroma of, 172; *Filaria* in, 172; lipoma of, 172; lung tissue in, 172; malignant tumors of, 494; mechanical irritation of, 3; tuberculosis of, 174, 349; tumors of, 172
 Peritonitis (adhesive, cancerous, diffuse, fibrinous, general, hemorrhagic, localized, proliferative, purulent, putrid,

- Peritonitis (*continued*)
 serofibrinous, serous, tuberculous, etc.),
 46, 48, 76, 97, 99, 146, 159, 172, 174, 175,
 178, 218, 228, 319, 329, 355, 501
- Permission to perform postmortem, 3, 4,
 6
- Pernicious anæmia, 69, 73, 81, 129, 130,
 134, 135, 136, 211
- Pertussis (whooping cough), 130, 157,
 325, 388, 491
- Petechiæ, 142
- Peyer's patches, 139, 180, 181, 312, 324,
 334, 353, 354, 417, 487
- Phalloides amanita*, 460, 466
- Pharyngitis, 331
- Pharynx, diseases of, 257, 314, 321, 338,
 355, 499; examination of, 15, 17, 123,
 430, 485
- Phenylendiamin, toxicology of, 452, 464
- Philadelphia Hospital, blank post-mor-
 tem record of, 20, 21
- Phlebotasia, 155
- Phlebitis, 154, 355
- Phleboliths, 152, 155
- Phlebosclerosis, 155
- Phlegmasia alba dolens, puerperal, 503
- Phlegmon, 504
- Phloridzin, toxicology of, 467
- Phosphates, deposits of, in pregnant
 women, 79
- Phosphatic calculi, 217
- Phosphorescence, 444
- Phosphorus, toxicology of, 32, 106, 129,
 143, 149, 173, 203, 215, 221, 223, 226,
 264, 452, 459, 460, 462, 463, 465, 466,
 467, 468, 476
- Photographs as means of identifying
 body, 62
- Photomicrographs, 369
- Phrenic nerves, 110
- Phthiogenic organism described by von
 Schrön, 342
- Phthisis, see TUBERCULOSIS
- Phthisis florida, 345
- Physician practising when intoxicated,
 437
- Physician and patient, relations of, 436,
 437
- Physician's certificate for return for a
 death, 507; responsibility in judicial
 hanging, 53
- Physostigmine, toxicology of, 463, 464,
 465, 466
- Pia mater, 16, 242, 243, 398, 483
- Pick's method of preserving the natural
 color of specimens, 378; myelotome, 35,
 243, Fig. 20
- Pirates and picric acid, toxicology of,
 456, 464, 466, 469; uses of, as a fixa-
 tive, 373
- Picrotoxin, toxicology of, 463, 477
- Pig, diseases of, 343, 359, 360; postmor-
 tem on, 408, 426
- Pigeon-breast (*pectus carinatum*), 81,
 105
- Pigmentation, 121, 134, 136, 144, 203
- Pilocarpine, toxicology of, 464, 465, 466,
 468
- Pineal gland, 16, 247, 394, 399
- Pins, 40
- "Pipe-stem" coronary artery, 113
- Pitres's method of examining brain, 246,
 248
- Pituitary body, 16, 242, 244, 257, 258,
 297, 394, 399, Fig. 139
- Pityriasis rosea, 71
- Placenta, 220, 294, 396
- Plagiocephalic skull, 398
- Plague, 48, 128, 325, 326, 492
- Plane, horizontal, of skull, 397
- Plants, pathology of, xxvi, p. 432, 444
- "Plaques choriales" of sheep, 79
- Plasmodium malariae*, 135, 364
- Platinum loop (ose), 41, 384
- Platycephalic skull, 397, 398
- Plethora, 129
- Pleura, diseases of, 109, 121, 155, 159,
 169, 170, 201, 329, 332, 349, 360; ex-
 amination of, 15, 109, 484; examina-
 tion of, in animals, 430
- Pleurisy ("bread-and-butter," diaphrag-
 matic, dry, encysted, gonorrhœal, hem-
 orrhagic, interlobular, purulent, rheu-
 matic, etc.), 49, 75, 81, 109, 161, 169,
 170, 171, 320, 322, 328, 330, 332, 355,
 499
- Pleuropneumonia, 204; of cattle, 166
- Plexus, brachial, 106
- Plumbism, see LEAD-POISONING
- Pneumatosis, 111
- Pneumococcus (Streptococcus lanceolatus)*,
 135, 327, 385, 387
- Pneumogastric nerves, 15, 17, 290
- Pneumomalacia, 165, 234
- Pneumomycosis, 166
- Pneumonia (alcoholic, aspiration, catar-
 rhal, croupous, fibrinous, hypostatic,
 interstitial, lobar, lobular, syphilitic,
 tuberculous, white, etc.), 62, 109, 111,
 122, 128, 130, 146, 154, 163, 166, 167,
 234, 261, 311, 312, 323, 324, 327,
 328, 330, 331, 332, 339, 340, 345, 355,
 499
- Pneumonitis, 327
- Pneumonoconiosis, 168
- Pneumopericardium, 111
- Pneumothorax, 90, 109, 111, 170, 325
- Pockets in bladder, 216
- Podagra, 277
- Podophyllotoxin, toxicology of, 466
- Poikilocytosis, 129, 135
- Poisoning, chronic, 495; collection of tis-
 sues from cases of, 46, 441, 487; con-
 tents of stomach in case of, 41;
 questions to be answered in cases of,
 461

Poisons, see also POISONING and TOXICOLOGY OF, under the names of the various poisons themselves; changes in urine after administration of, 466; classification of, 462; definition of, 459; "normal," 313; odor of, 31; suicide by, 505; symptoms observed after administration of, 463

Poley oil, toxicology of, 465

Poliomyelitis, 388; acute anterior, 262; chronic anterior, 257, 265

Polycythæmia, 129, 138

Polydactylism, 3

Polygnathus, 77

Polymelus, 77

Polypi, 99, 128, 148, 183, 203, 220

Polyserositis, 102, 223

Pons Varolii, examination of, 16, 247, 483, Figs. 143-149

"Porcelain" liver and spleen, 102, 223

Porencephalus (porencephaly), 260, 266

Pork, see PIG

Portal vessels, 16, 17, 154, 204, 205, 401, 413, Figs. 121, 122

Post, see POSTMORTEM

Posterior sclerosis, see ATAXIA, LOCOMOTOR

Postmortem (or post-mortem), see EXAMINATION OF, under the several entries, for the post-mortem examination of the various parts and organs and the various illustrations bearing upon this subject; Anatomical Boards and, 5; anatomy studied at, 3; Army and, 43; assistants at, 6; at hospital, 9, 11; at morgue, 9, 11; at place where carcass is found, 408; at private house, 9; at undertaker's, 9; bacteriologic, 392; blood-color scale for, 126, Plate three; Boards of Health and, 4; books for recording, 18, 19, 25; books on, xxxi, p. 508 (see also second edition of this work); cadaver improved in appearance by, 9, 290; care in making, 2; cause of death determined by, 2, 32, 447, xxx, p. 491; cleanliness at, 10; closure of body in, xx, p. 298; comparative, xxv, p. 407; compulsory, 4; consent for, 3, 290; contraction of infectious diseases at, 48; decomposed bodies and, 57, 480; defendant represented at, 462; definition of, 2; determination of viability of child by, 293, 443, 444, 488; disinfection after, 47; dress of operator at, 10, 408; electrocution and, 7, 74, 454, 506; examination of body before, v, p. 53; excitability of heart at, 444; exhumed, 462, 463; experimental, 392; final report of, 489; fœtus expelled from mother at, 53; frozen bodies and, 302, 305, 481; general considerations on, i, p. 1; guests at, 7; historical considerations of, 1; illumination at, 12, 481; immunity derived from constant inoculation at,

Postmortem (*continued*)

50; importance of, 2; in America, 1; in England, 1; in France, 17, Figs. 133, 134; in Germany, 8, xxix, p. 479; in Massachusetts, 1; in New York, 1, 5; in Pennsylvania, 1, 5; in poisoning, 442; in Vienna, 7; infections from, 48; instruments for, iii, p. 34, 407, 480; instruments for Army, 43; instruments for Navy, 43; insurance companies and, 4, 5; interns and, 4, 6, 30; interval to elapse before making, 7, 480; laboratory, upon animals, 407; law permitting, 5; legal aspects of, 1, 3, 4, 5, 6; light at, 9, 12, 481; literature on (see also second edition of this work), xxxi, p. 508; Marine-Hospital Service and, 23; medicolegal, 2, 7, 16, 46, 440; microscopic examinations at, 41, 42, 268, 370, 481; multiple, 462; Navy and, 22, 43; note-taking at, 23; nurse at, 7; objects of, 2; odor at, 11, 302; of Bishop, 7; of Brooks, Phillips, 5; of Jones, Admiral Paul, 62; of McKinley, 6; of Rameses II, 62; on animals, 392; on birds, 429; on calves, 423; on cats, 407, 408, 427; on children, xxviii, p. 289; on cows, 407; on dogs, 408, 427, Figs. 199, 200; on goats, 407, 425; on guinea-pigs, 407; on horses, 407, 408, 410, Figs. 189-193; on infants, 443; on lower animals, xxv, p. 407; on mice, 407; on new-born, xviii, 289; on plants, xxvi, p. 432; on rabbits, 407; on rats, 407; on ruminants, 423, Figs. 194-197; on sheep, 407, 425, 427, 429, Fig. 198; on snakes, 407; on swine, 408, 426; operations at, 3; order of examination at, ii, p. 14, xxv, 429, xxix, p. 481; permission to perform, 3, 4; per rectum, Figs. 106-114; per vaginam, Figs. 106-114; persons present at, 6; place at which made, 8, 408, 481; portable table for, 9, Fig. 1; preparation for, 9; protocol of, 489; Prussian regulations for the performance of medicolegal, xxix, p. 479; purpose of, 2; record books for, 19; record books for, on animals, 249; records of, ii, p. 14; references on (see also the second edition of this work), xxxi, p. 508; repetition of, 8; report of, 490; resident physicians making, 6; restricted, xix, p. 295; rheumatism from making, 13; room for, 11; rules for performing, 14; scales at, 11, 38; scheme for record of, in lower animals, 429; smoking at, 7; societies for promoting, 5; specimens secured from, 6; stool for instruments at, 13; study of anatomy at, 3; study of physiologic structures in, 3; substitute for daylight at, 9; substitutes in, 480; suggestions at, 8; surgical operations

- Postmortem (*continued*)
 at, 3; synonyms of, 2; table for, 9, 12, 40. Figs. **1, 3, 4, 10, 11**; teaching of technic at, xxvii, p. 434; teeth, removal of, at, 6; temperature of body at, 7; those present at, 6; time after death before making, 7, 480; time for performance of, 7, 480; time of completing, 8; to be made before the body is dressed, 9; toxicologic, 46, 442, 487; transportation of corpses for, 481; undertaker at, 4, 7, 9, 10; veterinary, 407
- Post-mortem lividity, see LIVIDITY, CADAVERIC; rigidity, 4, 6, 14, 30, 59, 311, 331, 334, 409, 444, 482; wounds, iv, p. 45
- Post-partum hemorrhage, 142
- Potassium, toxicology of, 452
- Potassium bichromate as a fixing fluid, 245, 252; toxicology of, 9, 465, 467, 470
- Potassium binoxalate, toxicology of, 466, 468
- Potassium cantharidate, toxicology of, 466, 468
- Potassium chlorate, toxicology of, 58, 69, 213, 465, 467, 477
- Potassium chromate, toxicology of, 461
- Potassium cyanid, toxicology of, 461, 463, 473
- Potassium iodid, toxicology of, 71
- Potassium permanganate, use of, 47
- Potato bug, distribution of, 432
- Pott's disease, 81, 99, 105, 186, 208, 253, 493
- Poultice, flaxseed, 51
- Poupart's ligament, 98
- Powder, talcum, 46
- Powder markings, 63, 449, Plate six
- Pregnancy (the German law accepts a duration of 302 days as the maximum. See also EXTRA-UTERINE PREGNANCY), 81, 130, 503
- Premature interments, 53
- Prepuce, examination of, in animals, 408, 430
- Preservation of body, xx, p. 298; of clothing, 63; of tissues for macroscopic and microscopic study, xxii, p. 368
- Priapism, 468
- Probes, 38
- Proctitis, 319
- Progeria (see also ATELEIOSIS), 258
- Prognathous skull, 398
- Prosopothoracopagus, 77
- Prostate, diseases of, 3, 215, 222, 319, 348, 502; examination of, 15, 17, 196, 406, 486
- Prostatitis, 319
- Prostration, 506
- Proteus, see BACTERIUM VULGARE
- Protocol of postmortem, 489
- Protozoa of smallpox, 333
- Provisional diagnosis, 440; opinion of obducent, 431, 489
- Prurigo, 72
- Pruritis, 73
- Prussian blue for injecting, 380; for testing presence of iron, 206
- Prussian regulations for medicolegal autopsies, xxix, p. 479
- Psammocarcinoma of ovary, 219
- Psammoma, see ACERVULOMA
- Pseudoarthrosis, 280
- Pseudencephalus, 76
- Pseudohypertrophic muscular atrophy, 207; paralysis, 92
- Pseudoleukæmia, 138
- Psilosis, 334
- Psittacosis, 128
- Psoas muscles, 16, 208, 413
- Psoriasis, 71, 72
- Psorospermiasis, 365
- Ptomaine poisoning, 463, 477
- Ptosis, 83, 464
- Puerperal diseases, 49, 73, 261, 264, 293, 326, 356, 503
- Pulex cheopsis*, 326, 358; *P. irritans*, 358; *P. penetrans*, 358
- Pulmonary vessels, diseases of, 136, 142, 163, 234, 499; examination of, 17, 114, 115, 117, 118, 122, 400, 485, Figs. **75, 80, 83, 88, 167**
- Pulse in poisoning, 466
- Puncture, fatal exploratory, 74; Quincke's lumbar, 3, 352
- Pupillary membrane, 445, 488
- Pupils, 54, 56, 84, 464
- Purpura, 71, 72, 73, 99, 139, 140, 142, 163, 322, 331, 355, 492, 503
- Pustule, 72, 308, 464; malignant, 309
- Putrefaction, 57, 128, 134, 356, 482
- Pyæmia, 49, 134, 135, 139, 145, 202, 229, 326, 329
- Pyelitis, 214, 319
- Pyelonephritis, 214, 355
- Pygopagus, 76
- Pylorus, 59, 199, 201, Fig. **122**
- Pyopneumothorax, 91
- Pyosalpinx, 218
- Pyosepticæmia, 229
- Pyothorax, 169
- Pyramidon, toxicology of, 467
- Pyrogallic acid, toxicology of, 463
- Pyrogallol, toxicology of, 465, 467

Q

- Question, medicolegal, 449
- Quillaja bark, toxicology of, 464
- Quincke's lumbar puncture, 3, 352
- Quinine, toxicology of, 71, 464, 467; use of, in cellulitis, 51
- Quinquaud's sign, 278

R

- Rabbit, *Coccidia* of, 366; inoculation of, 390, Figs. **185, 186**; postmortem on, 407, Fig. **188**
- Rabie tubercle, 321
- Rabies, 267, 320, 388, 407, 461, 492
- Race, determination of, 67
- Racemose aneurism, 152
- Racial characteristics, 64, 67
- Radio-activity, 443
- Ranunculus acris*, toxicology of, 464;
R. sceleratus, toxicology of, 464
- Rape, 63, 221, 459
- Raspatory, 38, 39, Fig. **48**
- Rat as disseminator of bubonic plague, 407; postmortem on, 407; *Trypanosoma* of, 367
- Ray-fungus, 306
- Raynaud's disease, 129, 265, 465
- Razor, 35, 480
- Reaction, agglutinative, 128; for diagnosis of human blood, 323
- Receptaculum chyli, examination of, 208
- von Recklinghausen's disease (hämochromatosis), 267
- Records, post-mortem, ii, p. 14
- Rectum, diseases of, 79, 155, 294, 494; examination of, 15, 17, 194, 195, 295, 338, 361, 486, 494; examination of, in animals, 412, 413, 416, 420, 426, 428, 430, Figs. **189, 198**
- Red, trypan, 367
- References to literature on postmortems (see also the second edition of this book), xxxi, p. 508
- Refrigerator box, 11, Figs. **5-8, 181, 182**
- Regional landmarks, 26, 509
- Regulations, Prussian, for performance of medicolegal postmortems, xxix, p. 497
- Regurgitation, tricuspid, 148
- Relapsing fever, 135, 283, 329, 491
- Renal, see KIDNEY
- Report, post-mortem, 490
- Reptiles, postmortems on, 407
- Resident physicians and postmortems, 4, 6, 30
- Resorcin-phthalein test, 55
- Respiration, absence of, in child, 487; tests for cessation of, 54
- Respiratory apparatus, diseases of, iv, p. 156, 321, 338, 344, 498, 499
- "Rest" bacillus, 344
- Restoration and preservation of body, xx, p. 298
- Restricted post-mortem examinations, xix, p. 295
- Retina, 85
- Retinitis, 336
- Retroperitoneal glands, examination of, 16
- Retropharyngeal abscess, 310, 314, 332
- Reversed peristalsis, 182
- Rhabdomyoma, 148, 214, 221, 222
- Rhabdonema intestinale*, 363
- Rhachioschisis, 260
- Rhachiotome, Luer's, 35, 254, 483
- Rhachipagus, 77
- Rhachitis, see RICKETS
- Rheumatism, 13, 71, 110, 146, 151, 283, 324, 330, 332, 388, 494, 495
- Rhinitis, 156, 157, 159
- Rhinoliths, 156
- Rhinoscleroma, 156
- Rhubarb root, toxicology of, 467
- Rhus toxicodendron*, toxicology of, 464
- Ribs, diseases of, 78, 81, 105, 111, 308; examination of, 105, Figs. **63-66**
- Rice bodies, 275, 287, 351
- "Rice-water" discharges in cholera, 311, 312
- Ricin, toxicology of, 463, 477
- Rickets, 80, 81, 105, 106, 141, 158, 163, 226, 283, 286
- "Rider's" bones, 93
- Rigidity, post-mortem (cadaveric), 14, 30, 59, 60, 311, 331, 334, 409, 443, 482, 485
- Rigor mortis, see RIGIDITY, POST-MORTEM
- Ring worm, 72
- Ripault's test, 56
- Robin's injecting fluid, 380
- Rocks, natural selection in, 432
- Rokitansky, 8, 15, 223
- Röntgen rays, see X-RAYS
- Rose rash, 388
- Rötheln, 156, 331
- Rougemont, Philip, 1
- Rough-on-rats, 471
- Round ligaments, examination of, 204
- Round worms, 361
- Rubber bag, 42; catheter, 42; coat, 47; finger-stalls, 47; gloves, 40, 42, 46, Figs. **97, 104, 123**; sheeting, 42
- Rubella, 331
- Rubeola, 324
- Rue, toxicology of, 466
- Ruler, 65
- Ruminants, postmortem on, 408, 423, Figs. **194-197**
- Rupia, 336
- Rupture of aneurism, 106, 153, 200; of bladder, 216; of diaphragm, 208; of Fallopian tubes, 218; of heart, 144; of liver, 223; of spleen, 176; of stomach, 107; of tubal pregnancy, 129; of uterus, 220
- Rustan, weight of brain of, 399
- Ruysch, van Neck's painting of, Fig. **165**

S

- Sabina, toxicology of, 466
- Sacrum, 68
- Sago spleen, 178
- St. Vitus's dance, see CHOREA
- Salicylic preparations, toxicology of, 464

- Saline injections, 74
 Salivary calculi, 274
 Salivary glands, diseases of, 274, 346;
 examination of, 15, 16, 402, 430, 485
 Salivation, 465
 Salmon, cancer of, 108
 Salol forming enteroliths, 183
 Salpingitis, 218, 319
 Salt water, drowning in, 458
 Salve, antiseptic, 45
 San José scale, 432
 Sand for filling in cavities, 41; false, in
 intestines, 183
 Sand-flea, 358
 Santonica seeds, toxicology of, 467
 Santonin, toxicology of, 463, 467
 Saponiferous substances, toxicology of, 467
 Saponine, toxicology of, 465
 Sapræmia, 135
 Saprophytes, 50
 Sarcinae, 387
 Sarcoma (adenocystic, alveolar, angio-,
 chondro-, fibro-, giant-celled, lympho-,
 melano-, medullary, myeloid, myxo-,
 osteo-, perithelial, round-celled, spindle-
 celled, teleangiectatic, tubular, etc.),
 70, 106, 154, 217, Plate four; of adrenals,
 192; of appendix, 185; of bladder, 216;
 of bone, 288; of brain, 267; of breast,
 70; of choroid, 85; of ciliary body, 85; of
 dura mater, 230; of eye, 33, 230; of
 heart, 111, 148; of intestines, 183; of
 iris, 85; of kidney, 214; of larynx, 158;
 of liver, 33, 230; of lungs, 169; of
 lymph-gland, 207; of mediastinum, 106;
 of nasal passages, 156; of neck, 153;
 of ovaries, 219; of penis, 230; of pericardium,
 111; of pituitary body, 258;
 of pleura, 170; of skin, 73, 230; of
 spleen, 178; of testicles, 222; of thyroid
 gland, 108; of tonsils, 158; of vagina,
 221
Sarcoptes scabiei, 358
 Satchel, contents of, for post-mortem
 work, 41
 Satterthwaite's clamp, 38, Fig. 42
 Saturnism, see LEAD, TOXICOLOGY OF
 Sausage poisoning, 464, 465
 Saw, 35, 36, 42, 43, 103, 254, 408, 480,
 Figs. 21-26, 163
 Sawdust in preservation of body, 41
 Scabies, 72
 Scalds, 454, 506
 Scale, 11, 38, 42, 480, Figs. 5, 6, 7, 8;
 moisture, 127, Plate three; post-mortem
 blood-color, 126, Plate three; Tallqvist's
 blood-color, 126
 Scalp, examination of, 16, 235
 Scapels, 35, 42, 43, 242, 368, 408, 480,
 Fig. 21
 Scar, 15, 73, 74, 228, 336, 481
 Scarletina (scarlet fever), 72, 93, 149, 156,
 202, 226, 283, 324, 331, 388, 466, 491
 Scharlach R, 380
Schistosoma Cattoi, 363; *S. hæmatobium*,
 364; *S. japonicum*, 363
 Schultze's clearing method, 380
 Schweinfurth green, toxicology of, 465
Scilla, toxicology of, 466
 Scissors, 37, 42, 43, 241, 243, 408, 480,
 Figs. 28-32
 Sclera, 84
 Sclerema, 505
 Scleroderma, 73, 313, 332
Scl'rose en plaques, 265
 Sclerosis, amyotrophic lateral, 257; dis-
 seminated, 324; gummatous, 337; multi-
 ple, 361; of arteries, 231, 232, 233; of
 brain, 265; of spinal cord, 265; pos-
 terior, see ATAXIA, LOCOMOTOR; primary
 lateral, 265
 Scolices, 360
 Scoliosis, 81, 208, 283
 Scopalamine, toxicology of, 464, 465, 466,
 468
 Scorpion, poison of, 463
 Scrapings, method of examining, 122,
 368
 Scrofula, 72, 326, 493
 Scrotum, diseases of, 78, 155; examina-
 tion of, 15, 419, Figs. 117-119; ex-
 amination of, in animals, 408, 409, 430,
 488
 Scurvy, 71, 72, 130, 140, 141, 163, 495
 Sealing-wax, 40, 42
 Seat-worms, 183, 361
 Sebaceous cysts, 82
 Seborrhœa, 72
 Secondary anæmia, 129
 Sectio anatomica, see POSTMORTEM; *S. ca-*
daveris, see POSTMORTEM
 Section, see POSTMORTEM
 Section-knife, 34, Figs. 14-16
 Sections, frozen, preparation of, 370;
 microscopic, preparation for, 320, 371
 Segmentation of heart, 143
 Selenium, toxicology of, 468
 Semen, 63, 133, 459
 Semilunar ganglia, 15, 192; valve, 126,
 144
 Seminal vesicles, examination of, 15, 196,
 197, 406, 486, Fig. 120
 Senile changes, 144, 149, 505
 Senna leaves, toxicology of, 467
 Sepsis and Septicæmia, 48, 49, 57, 119,
 135, 139, 145, 264, 326, 329, 492, 503
 Septum of heart, 114, 118, 126; of nose,
 156; of pancreas, 230
 Serous membranes, appearance of, 96,
 109
 Serum (antianthrax, antidiphtheritic, an-
 tiplague, antistreptococcic, antitetanus,
 etc.), 140
 Sewing up of body, 301, Figs. 175, 176
 Sex, 64, 67, 481
 Sheaths, diseases of, 286

- Sheep, diseases of, 360, 363; postmortem on, 407, 425, 427, Fig. 198
 Sheeting, rubber, 42
 Shiga, bacillus of, 314
 Shock, death due to, 32
 Siderosis, 168
 Sigmoid flexure, diseases of, 101, 173
 Signs of death, 53
 Silicosis, 168
 Silk, oiled, 42
 Silver nitrate, toxicology of, 247, 465, 477; uses of, 51, 71, 369
 Simple anemia, 129
 Singers' nodes, 158
 Sinus, longitudinal, 16; of Valsalva, aneurisms of, 146, 154
 Sinuses, accessory, exposure of, in animals, 423
 Sitotoxismus, 460
 Situs inversus, 126
 Size, how estimated, 27, 431, Plate two
 Skatol, odor of, 32
 Skeleton, 66, 396
 Skiagraphs, see X-RAYS
 Skin and its appendages, diseases of, 33, 45, 68, 69, 71, 72, 73, 75, 124, 130, 135, 137, 147, 230, 324, 330, 331, 333, 357, 366, 464, 504; examination of, 15, 70, 430
 Skin flap, Fig. 71
 Skull, diseases of, xiii, p. 235, 339, 340; examination of, xiii, p. 235, Figs. 126-140; fracture of, 1, 236, 244, 449; restoration of, 299, Figs. 177, 178; shapes of, 397
 Skulleap, see CALVARIUM
 Sleeping-sickness, 366
 Snee's method of fixing calvarium, 299, Fig. 177
 Slide, microscopic, 24, 384
 Slide-box, 385
 Small intestine, see INTESTINES
 Smallpox, 31, 33, 48, 56, 71, 72, 93, 156, 157, 283, 326, 333, 334, 388, 491
 "Smear" preparations, 383, 389
 Smegma bacillus, 348
 Smell, sense of, 257
 Smokeless powder, 449, Plate six
 Smoking, prohibition of, at postmortem, 7
 Snake, postmortem on, 407
 Snake venom, toxicology of, 57, 463, 478
 Soap, 42, 47
 Soapstone for rubber gloves, 40, 46
 Sodium acetate, uses of, 252
 Sodium bisulphite, 47
 Sodium chlorid, physiologic solution of, 368; use of, 252
 Sodium hydrate, toxicology of, 462, 470
 Sodium nitrite, toxicology of, 465, 467
 Sodium urate, 141
 Soft chancre, 493
 Softening of brain, 261, 263, 496
 Solanine, toxicology of, 467
Solanum pseudocapsicum, toxicology of, 461
 Somatic nutrition, 68
 Sounds, 480
 Spanish fly, see CANTHARIDES
 Specific gravity, method of determining, 27
 Specimens, preservation of, 6, 40, 41, 42, xxii, p. 368
 Spectroscope, pocket, 126
 Spermatic cord, diseases of, 155, 222; examination of, 15, 16, 44, 196, Figs. 117-120, 122
 Spermatozoa, 54, 133, 221, 459
 Sphenoccephalic skull, 398
 Spina bifida, 77, 266
 Spinal column, diseases of, 283, 310; examination of, 16, xiv, p. 253, 427, 483, Figs. 153-158, 169
 Spinal cord, diseases of, 136, 215, 255, 256, xv, p. 257, 258, 261, 262, 264, 267, 283, 310, 321, 332, 359, 495; examination of, 16, 243, xiv, p. 253, 254, 292, 483, Figs. 152-159, 169; examination of, in animals, 423, 430; hardening of, 255; measurements of, 400; nerves of, 16; weight of, 394, 400
 Spinal ganglia, examination of, 258, 341
 Spinal membranes, hemorrhage of, 269
 Spine, typhoid, 355
 Spirals, Curschmann's, 159
Spirochaeta Obermeieri, 135, 329, 387; *S. pallida*, 335, 387; *S. refringens*, 387
 Splanchnic nerves, 15
 Spleen, absence of, 176; accessory, 101; 176; actinomycosis of, 308; amyloid degeneration of, 178; angioma of, 178; anthracosis of, 169; anthrax of, 310; atrophy of, 175, 224; blood-vessels of, 15; cancer of, 178, 201; capsule of, 15; chronic capsulitis of, 227; coal-dust in, 176; *Coccidium* of, 366; color of, 176; congestion of, 160; diseases of, 175, 323, 501; *Echinococci* of, 31, 178; embolism of, 147; examination of, 15, 17, 175, 295, 486; examination of, in animals, 393, 413, 414, 415, 416, 417, 426, 430, Fig. 191; follicles of, 15; gumma of, 178; in acute yellow atrophy, 224; in Addison's disease, 191; in cholera, 312; in cirrhosis of liver, 227; in diabetes mellitus, 234; in dysentery, 316; in erysipelas, 317; in Hodgkin's disease, 139; in leprosy, 323; in leucoerythemia, 137; in malaria, 175, 365; in Malta fever, 323; in plague, 326, 327; in pneumonia, 329; in relapsing fever, 330; in scarlet fever, 332; in smallpox, 334; in typhoid fever, 353; infarcts of, 177; leukæmia of, 177; leucoerythemic, 137; measurements of, 404; of babe, anatomy of, 290; *Pentastomum denticulatum* of, 178; pulp of, 15; puncture of,

- Spleen (*continued*)
 367; rupture of, 137, 176, 330; sago, 178; sarcoma of, 178; softening of, 176; supernumerary, 100; syphilis of, 340; trabeculae of, 15; tuberculosis of, 177, 347, 349; tumors of, 130; typhoid, 355; volume of, 404; wandering, 176; weight of, 175, 394, 396, 404
- Splenic artery, aneurism of, 154, 176; tumor, 177
- Splenitis, 177
- Splenization, 137
- Splenomegalies, 367
- Spondylitis deformans, 277
- Spondylosis ("poker back," *spondylose rhizomclique*), reference on, 288
- Sponges, 10, 40, 42
- Spores, bacterial, longevity of, 308, 393
- Sporozoites, 364
- Spots, parchment-like, 75; Tardieu's, 113, 144
- Spotted fever, 264, 310
- Sprains, 506
- Spreads, preparation of, 384
- Sprue, 334
- Sputum, 159
- Squill, toxicology of, 463
- "Stab" cultures, 389; in making cultures of anaerobes, 389
- Stab-wounds, 106
- Stains on clothing, 63
- Staphylococcus*, 50, 174, 327, 330, 387
- Starvation, 129, 130, 456
- Status lymphaticus, 294
- Steatoma, 73
- Steel tape measure, 42
- Stegomyia fasciata*, 357
- Stenosis, 148, 151; of aorta, 147, 148; of blood-vessels of heart, 126; of bronchi, 160; of larynx, 109, 158; of mitral valve, 118, 144, 147; of pylorus, 201; of trachea, 109, 124; of ureters, 215; of uterus, 219
- Sterilized instruments, 34, 46, 52
- Sternum, diseases of, 105, 308; examination of, 103, 104, 105, 484, Figs. 58-61, 68-70
- Stillbirths, 507
- Stomach, abrasions of, 199; abscesses of, 202, 308; atony of walls of, 201; bile in, 200; cancer of, 199, 201; capacity of, 101; cicatrices of, 203; contents of, 41, 199, 460, 487; dilatation of, 201; *Diptera* in, 200; diseases of, 321, 322, 494, 500; diverticula of, 198; effect of poisons on, 461; epithelioma of, 201; examination of, 16, 17, 46, 100, 101, 199, 290, 295, 486, 487, Figs. 72, 75, 121-123, 164; examination of, in animals, 413, 414, 415, 416, 417, 426, 428, 430, Figs. 191, 198; foreign bodies in, 200; gall-stones in, 200; hour-glass contracture of, 100, 201; hemorrhage from.
- Stomach (*continued*)
 142, 199, 202, 203; in actinomycosis, 308; in anthrax, 203; in beriberi, 310; in cholera Asiatica, 312; in cirrhosis of liver, 227; in favus, 203; in progressive pernicious anæmia, 136; in relapsing fever, 330; in thrush, 203, 341; in tuberculosis, 346; infiltration of, 202; inflammation of, 202; injuries to, 202; measurements of, 100, 402; mucous membrane of, 16; muscularis of, 16; mucus of, 203; *Oxyuris vermicularis* of, 200; polypi of, 203; position of, in babe, 100; psychic secretion of, 182; rupture of, 101; submucosa of, 16; *Trichina spiralis* of, 361; ulcer of, 98, 199, 201, 500; weight of, 402
- Stomach pump, 39
- Stomatitis, 324
- Stomatitis aphthosa epizootica, 317
- Stone formations, see CALCULI
- Strabismus, 83
- Stramonium, toxicology of, 456, 464
- Strangulation, 124, 456, 486, 505
- Strangury, 468
- Streptococcus*, 50, 174, 316, 327, 333, 387
- Streptothrix*, 306, 308, 387
- Stricture, 33, 124, 193, 200, 201
- "Stroke" culture, 389
- Strongylus annatus*, 153; *S. duodenale*, see ANCHYLOSTOMA DUODENALE; *S. gigas*, 166, 212; *S. subtilis*, 363
- Strop, 39, Fig. 21
- Strophanthus*, toxicology of, 466
- Struma aneurysmatica, 162; *S. varicosa*, 162
- Strumpipriva, cachexia, 107
- Strychnine, toxicology of, 59, 60, 193, 461, 463, 468, 478
- Subclavian vein, 15
- Subcutaneous inoculation of animals, 391, Figs. 184-186
- Subdiaphragmatic abscesses, 172, 204
- Sublingual glands, 17
- Submaxillary glands, 402
- Submersion, accidental, death by, 506
- Subpericardial ecchymoses, 113; fat, 113
- Subphrenic abscesses, 172, 204
- Sucking gland, 75
- Sudan III, 371, 380
- Sudden death, 33, 503, 507
- Suffocation, 60, 109, 113, 145, 158, 456
- Suffusions, hemorrhagic, 142
- Suggillations, 142
- Suicide, 449, 505, 506
- Sulphid of ammonium, 41
- Sulphonal, toxicology of, 463, 467
- Sulphur balls, 306
- Sulphur dioxide, toxicology of, 462
- Sulphuretted hydrogen, odor of, 32
- Sulphuric acid, toxicology of, 32, 461, 462, 467, 468
- Summer diarrhœa of children, 315

- Sunstroke, 237, 456
 Superior vena cava, measurements of, 401
 Supernumerary, see ACCESSORY under the names of the various organs
 Supplies, bacteriologic, 41; chemic, 41; microscopic, 41
 Suppuration, 97, 135, 154
 Suprarenals, see ADRENALS
 Surgery, practice of, at postmortem, 3
 Surgical instruments left in abdominal cavity, 99
 Surra, 366
 Suspended animation, 53
 Suspensory ligament of liver, 99
 Sutures, cranial, 67
 Suturing of heart muscle, 112
 Sweat-glands, hemorrhage of, 142
 Sweating (miliary) fever, 492
 Swelling, cloudy, 324, 372
 Swine, see PIG
 Sydenham's chorea, see CHOREA
 Symbiosis, 231, 388
 Symelus, 76
 Sympathetics, 16, 33, 125, 324
 Symphysis menti, 123
 Symptomatic anaemia, 129
 Symptoms observed after the administration of the more common poisons, 463
 Syncephalus, 77
 Syncope, fatal, 32
 Syncytioma malignum, 219
 Syndesmosis, 280
 Synonyms of causes of death, xxx, p. 491; of "postmortem," 2
 Synostosis, 80, 236, 283
 Synovial membrane, diseases of, 139
 Syphilis, 48, 71, 72, 78, 81, 130, 145, 156, 261, 326, 327, 335, 493; congenital, 109, 130, 292, 339; in aneurism, 154; in locomotor ataxia, 258; of anus, 336, 338; of arteries, 152, 337; of bones, 275, 278, 336, 337, 339, 340; of brain, 285, 337; of bronchi, 338; of central nervous system, 337; of circulatory system, 337; of ears, 340; of eyes, 340; of fingers, 336; of gastro-intestinal tract, 337; of hair, 336; of heart, 148, 337; of intestines, 338; of joints, 278, 336, 339; of kidneys, 338; of larynx, 158, 336; of liver, 224, 226, 228, 230, 335, 338, 340; of lungs, 163, 339; of lymph-glands, 207; of lymph-vessels, 155, 207; of nasal passages, 156; of nervous system, 267, 337; of nose, 156, 339; of oesophagus, 337; of palate, 336; of pancreas, 231; of pericardium, 111; of periosteum, 336; of penis, 335; of pharynx, 338; of skin, 336, 337; of spinal cord, 337; of spleen, 175, 178, 340; of testis, 383; of tongue, 123, 335; of tonsils, 158, 336; of trachea, 124; of uterus, 220; of veins, 155; of vulva, 336; organisms of, 335, 369; rash of, 336
 Syringes, 38, 390
 Syringomyelia, 257, 261, 266
- T
- T incision, 273
 Tabes dorsalis, see ATAXIA, LOCOMOTOR; T. mesenterica, 351
 Table, postmortem, 11, 40, Figs. 3, 4, 10, 11; portable, 9, Fig. 1
 Table of approximate weights of internal organs, 396; of author's, 779 Coroner's cases, 451; of changes effected in urine by poisons, and medicines, 467; of coefficients for determining height from the length of long bones, 66; of differences between croupous and catarrhal pneumonia, 167; of differences between tuberculous and typhoid ulcers, 354; of poisons, 463; of symptoms observed in administration of poisons, 462, 463
Tænia bothriocephalus latus, 360; *T. cucumerina*, 361; *T. echinocephalus*, 360; *T. flavopunctata*, 360; *T. madagascariensis*, 361; *T. mediocanellata*, 182; *T. nana*, 183, 361; *T. pisiformis*, 361; *T. saginata*, 359, 361; *T. solium*, 359, 360
 Taguchi, weight of brain of, 399
 Tail, examination of, 420
 Taleum powder, 46
 Talipes calcaneus, 283; T. cavus, 283; T. equinus, 261, 283; T. planus, 283; T. valgus, 283; T. varus, 283
 Tallqvist's blood-color scale, 126
 Tannin, toxicology of, 478
 Tape measure, 38, 42, 65, Fig. 21
 Tape-worm, see *Tænia*
 Tar, toxicology of, 464
 Tattoo marks, 69, 482
 TC, 343
 "Tea" cigarettes, 452
 Teaching of post-mortem technic, xxvii, p. 434
 Technic, see EXAMINATION OF, under the various parts and organs
 Teeth, diseases of, 87, 88, 156, 293; examination of, 6, 15, 87, 482, Figs. 173, 174; examination of, in animals, 430; Hutchinson's, 88, 339, 340
 Tellurium, toxicology of, 32, 466, 468
 Temperature, fall of, after death, 56; of animals, how taken, 390, Fig. 183; rise of, after death, 7
 Tenaculum, 38
 Tendons, 16, 286, 430
 Tenosynovitis, 286
Terata anadidyma, 77; *T. anakatadidyma*, 77; *T. katadidyma*, 76
 Teratoma of pleura, 170
 Test, antiserum, 132, 396; Cattell's, 465; Gmelin's, 134; Icard's, 55; Magnus's, 55; Ripault's, 56; Widal's, 134, 181, 353, 354; Winslow's, 54

- Testicles, diseases of, 78, 222, 323, 325, 338, 348, 353, 366, 396, 405; examination of, 15, 17, 196, 419, 486, 488, Figs. **117-119**
- Testimony, expert, 437
- Testis, see TESTICLES
- Tests of death, 55
- Tetanus, 48, 52, 56, 59, 93, 128, 135, 340, 341, 496
- Tetanus neonatorum, 341
- Tetranol, toxicology of, 467
- TGL, 344
- Thawing of frozen bodies, 305, 481
- Thermocautery, Paquelin, 41
- Thigh, disease of, 155
- Thiosulphate of sodium, toxicology of, 466
- Thoracic and abdominal organs, removal of, in one piece, 125, Fig. **94**
- Thoracic aorta, aneurism of, 154
- Thoracic cavity, examination of, 44, vii, p. 103, 120, 208, 289, 401, 482, 484, Figs. **55, 72, 94, 164, 165, 167**; examination of, in animals, 410, 417, 418; injection of embalming fluid into, 103
- Thoracic duct, 15, 16, 17
- Thread, 40, 43; poisoning from, 452
- Thread-worms (*Oxyuris*), 361
- "Three color" printing, 28, Plate three
- Thrombo-arteritis, 151
- Thrombophlebitis, 124, 229
- Thrombosis, 100, 143, 151, 152, 154, 163, 244, 322, 498
- Thrombus, 33, 128, 129, 136, 144, 151, 152
- Throttling and hanging, differentiation of, 457
- Thrush, 124, 203, 220, 341
- Thuja*, toxicology of, 466
- Thymol, toxicology of, 467
- Thymus gland, diseases of, 107, 137, 162, 191, 257, 294; examination of, 15, 17, 443, 485, 488, Plate one, Figs. **72, 164**; measurements of, 107, 405; weight of, 106, 394, 396, 405
- Thyroglossal duct, 108, 120
- Thyroid gland, arsenic in, 471; dimensions of, 405; diseases of, 47, 74, 75, 108, 161, 162, 257, 260, 498; examination of, 15, 17, 107, 485; examination of, in animals, 418, 430; measurement of, 405; weight of, 394, 405
- Thyroiditis, 107
- Tibial nerves, removal of, 256
- Ticks, 306, 358
- Time after death before making autopsy, 7, 480; for body to skeletonize, 68; for weighing organs, 394
- Tin, toxicology of, 473
- Tinea favus*, 504; *T. sycosis*, 72; *T. tonsurans* (*Trichophyton*), 504
- Tissue, cellular, diseases of, 504
- Toadstools, toxicology of, 128, 460, 466, 477
- Toilet of hair, 235, Figs. **127, 128**
- Toluidin, toxicology of, 465
- Toluylendiamin, toxicology of, 467
- Tongue, diseases of, 77, 123, 307, 325, 341; examination of, 15, 17, 44, 122, 123, 482, 485, Figs. **90-93**; examination of, in animals, 430; hairy, 77
- Tonsils, diseases of, 158, 331, 336, 346; examination of, 15, 17, 123, 485
- Tophi, 82, 141
- Tourgenieff, weight of brain of, 399
- Tow for packing large cavities, 41
- Toxæmia, 329
- Toxicology, general considerations of, 459
- Toxin of diphtheria, 313; of pyæmia, 135; of tetanus, 463
- Toxon of diphtheria, 313
- Trabecule of heart, 15
- Trachea, diseases of, 109, 124, 159, 161, 163, 321, 334; examination of, 15, 17, 122, 123, 124, 289, 485, 488, Fig. **90**; examination of, in animals, 416, 418, 428, 430
- Trachoma (contagious granular lids, perhaps carried by flies), 497
- Trance, cases of, 53
- Transfusion, 129
- Transportation of tissues, 372
- Transudate, 31, 96, 133
- Transverse colon, 100
- Traumatism, 15, 72, 80, 81, 98, 99, 106, 153, 210, 212, 213, 228, 229, 506
- Treatment of post-mortem wounds, 50
- Trematodes*, 363
- Trephining, 73, 236
- Treponema pallidum*, 335, 369, 387, 388
- Trichina spiralis*, 94, 111, 129, 130, 207, 361, 369, 379, 429, 488, 492
- Trichomonas vaginalis*, 359
- Trichophyton tonsurans* (the fungus of herpes tonsurans), 504
- Trichostis vesicae*, 216
- Tricocephalus dispar*, 129, 362
- Tricuspid orifice, 117, 148, Fig. **167**
- Trigonocephalic skull, 398
- Trional, toxicology of, 463, 467
- Trocar, 38
- Tropacocaine, toxicology of, 468
- Trophic affections of skin, 73
- Trochocephalic skull, 398
- Tropical diseases, see Manson's work on this subject
- Trout, cancer of, 108
- Troy weight, 394
- Trypan red, 367
- Trypanosoma*, 135, 366; agglutination reaction of, 367; *T. Brucei*, 366; *T. disca*, 366; *T. Evansi*, 366; *T. gambiense*, 366; *T. Lewisi*, 366
- Trypanosomiasis of animals, 407
- Trypsin, 369
- Tsetse flies, 366
- Tubal pregnancy, see EXTRA-UTERINE PREGNANCY

- Tubercle bacillus, 341, 354, Plate five; finding of, in urine, 348
- Tubercle of Laennec, 342; rabic, 321
- Tuberculin, 52, 318, 344
- Tuberculosis, 48, 68, 70, 81, 99, 106, 111, 128, 130, 135, 146, 234, 245, 261, 322, 324, 341, 342, 343, 345, 346, 387, 451, 493; von Behring's treatment of, 343; bile in, 224; bovine, 48, 342, 343; microscopic appearance of, 342; miliary, 100, 148, 162, 344, 352; of adrenals, 191, 192; of alimentary tract, 346; of arteries, 152; of bladder, 348; of bone, 275, 278, 350; of brain, 267, 352; of dura, 244; of genito-urinary system, 347; of heart, 144, 148; of intestines, 354; of joints, 278, 350; of kidneys, 214, 347; of larynx, 158, 492; of liver, 224, 226, 230, 347, 349; of lungs, 163, 168, 169, 217, 283, 339, 344, 492; of lymph-glands, 155, 207, 351; of mammary gland, 352; of meninges, 493; of mesentery, 173; of nose, 156; of ovaries, 219; of oviducts, 218; of pancreas, 231, 232; of parotid glands, 274; of pericardium, 110, 111; of peritoneum, 174; of pia mater, 352; of pleura, 349; of prostate, 348; of respiratory tract, 344; of serous membranes, 349; of skin, 48, 52, 72; of spinal cord, 352; of spleen, 347, 349; of sternum, 105; of stomach, 346; of testicles, 222, 348; of thoracic duct, 208; of tonsils, 158; of trachea, 124; of ureters, 198, 348; of uterus, 220; of vein, 155
- Tuberculous wart, 48, 52
- Tumor (see also the names of the various forms of tumors, and of the parts and organs), 82, 87, 104, 105, 124, 130, 155, 218, 494, Plate four; cells of, in blood, 134; of adrenals, 191; of appendix, 185; arteries, 152; of bladder, 216; of bone, 287; of brain, 243, 267, 352; of breast, 70, 494; of carotid body, 125; of dura, 244; of eye, 85; of Fallopian tubes, 218; of female genital organs, 494; of gall-bladder, 206; of heart, 148; of intestines, 183; of joints, 287; of kidney, 212, 214, 215; of larynx, 158; of liver, 501; of lungs, 169; of lymph-glands, 139; of mediastinum, 112; of mesentery, 173; of muscles, 94; of nasal passages, 156; of neck, 75; of oesophagus, 124, 200; of ovary, 502; of pancreas, 207; of parathyroids, 108; of peritoneum, 172; of salivary glands, 274; of skin, 73, 494; of skull, 236; of spinal cord, 267; of spleen, 130; of stomach, 201; of testicles, 222; of thyroid, 108; of urethra, 79; of uterus, 219, 502; of vagina, 221; of veins, 155; of vulva, 78; polypoid, 99
- Tumor albus, 351
- Tunica vaginalis, hemorrhage in, 222
- Turbinates, absence of, 156
- Turmeric paper, 41
- Turpentine, removal of odor from hands by, 47; toxicology of, 32, 210, 212, 460
- TV, 343
- Twin pregnancy, history of, 294
- Twine, 40, 42, Fig. 52
- TX, 343
- Types of skull, 397
- Typhoid bacilli, 215, 222, Plate five; fever, 70, 93, 100, 119, 128, 129, 130, 135, 151, 157, 175, 178, 215, 222, 261, 264, 283, 353, 359, 491; spine, 355
- Typhus fever, 48, 130, 137, 139, 157, 175, 356, 388, 491
- Tyrosin, 68
- U
- Udder, examination of, 408, 409, 430
- Ulcer, 72; atheromatous, 150; diphtheritic, 78; of colon, 186; of cornea, 84; of duodenum, 178; of heart, 48, 145; of intestines, 182, 347; of larynx, 158; of oesophagus, 124, 200; of stomach, 98, 100, 500; of vagina, 221; syphilitic, 124; tuberculous, 100, 124, 347; tuberculous, how differing from typhoid, 354; typhoid, 100; typhoid, how differing from tuberculous, 354; typhoid, in Meckel's diverticulum, 355
- Ulcus molle, 336
- Ultraviolet microscope, 368, 388
- Umbilical cord, diseases of, 101, 143, 445; examination of, 291, 396, 445, 488, Figs. 164, 168
- Umbilicus, 15, 78, 216, 291, 408, 409, Figs. 164, 168
- Uncinaria Americana*, 362; *U. duodenalis*, 362
- Uncinariasis, 362
- Undertakers and postmortem, 4, 7, 9
- Undulant fever, 323
- Unguent, antiseptic, 46
- Unquatum Credé*, 51
- United States Army, autopsies in, 22; post-mortem instruments used in, 43
- United States Marine-Hospital Service, 306; autopsies in, 23
- United States Navy, autopsies in, 22; post-mortem instruments used in, 43
- Urachus, 78, 216, Fig. 164
- Uræmia, 31, 73, 127, 130, 134, 261, 451, 464
- Uranium, salts of, toxicology of, 467
- Urate, ammonium, 211, 217; sodium, 141, 211, 217, 293
- Urea, 130, 211, 217
- Ureter, abscess of, 193; absence of, 215; accidental tying of, 193; adhesions of, 193; calculus of, 193, 215; *Coccidia* in, 366; cysts of, 215; *Distoma hæmatobium* of, 193, 215; double, 193, 215; *Echinococcus* in, 215; epi-

Ureter (*continued*)

thelial cells of, 193; examination of, 15, 17, 187, 188, 193, 194, 195, Fig. 122; examination of, in animals, 414, 419, 430; hemorrhage of, 193; measurements of, 404; papillary fibroma of, 193; parasites in, 215; polyps of, 215; stenosis of, 215; stricture of, 193; tuberculosis of, 193, 348; twists of, 193, 210

Urethra, diseases of, 33, 79, 502; examination of, 15, 17, 404, 430, 486

Urethritis, 79, 319

Urethrorectal fistula, 79

Uric acid, 141, 142, 189, 211, 214, 217, 293

Urinary tract, diseases of, 142, 502

Urine, 141, 193, 217, 487; acetone in, 233; beta-oxybutyric acid in, 233; black, causes of, 217; diacetic acid in, 233; effect of poisons on, 466; frog test for strychnine in, 193; glucose in, 233; of new-born, study of, 293; securing of, for examination, 193, 393; sediments in, 217; specific gravity of, 233; tubercle bacilli in, 348; typhoid bacilli in, 353

Urinometer, 39

Urobilin, 224, 225, 467

Urobilinogen, 224

Uropygium, 429

Urticaria, 71, 73

Usual causes of death, nomenclature, complications, and synonyms of, xxx, p. 491

Utensils in postmortems on large domestic animals, 407

Uterus, adenoma of, 219; adenocystoma of, 219; amyloid degeneration of, 219; atresia of, 219; atrophy of, 219; bacteria in, 220; cancer of, 219; congenital abnormalities of, 219; deciduoma malignum of, 219; dermoid cysts of, 220; examination of, 15, 17, 195, 486, Fig. 107-116; examination of, in animals, 430; fibroma of, 219, 220; foreign bodies in, 221; hæmatoma polyposum of, 219; hemorrhages of, 142, 220, 502; hyaline degeneration of, 220; hydatiform moles of, 219; hypertrophy of, 219; hypoplasia of, 219; infantile, 219; leiomyoma of, 219; lipoma of, 219; measurements of, 406; myofibroma of, 219; myoma of, 219, 220; myosarcoma of, 219; rupture of, 220; stenosis of, 219; subseptus of, 219; thrush fungi in, 220; tuberculosis of, 220, 348; tumors of, 219, 502; weight of, 221, 394, 406

Uterus bicornis, 219; U. bicornis duplex, 219; U. bilocularis, 219; U. bipartitus, 219; U. cordiformis, 219; U. didelphys, 219; U. septus duplex, 219; U. unicornis, 219

V

Vaccination, 70; for smallpox, 333; for tetanus, 341

Vaccinia, 356

Vagabondism, 68

Vagina, diseases of, 221, 314, 334, 348; examination of, 15, 17, 46, 295, 486; examination of, in animals, 420, 430

Vaginitis, 319

Vagus, pressure on, 159

Valentine knife, 35, Fig. 19

Valsalva, sinus of, aneurism of, 146, 154

Valve, ileocaecal (Gerlach's), 180; of pulmonary artery, 117

Valves, cardiac, diseases of, 126, 146, 147, 228; competency of, 116; examination of, 15, 115, 144, 419, Figs. 76-85

Vapors of nitric acid, etc., inhaled, toxicology of, 465

Varicella (chicken-pox), 71, 72, 311, 356, 388

Varicocele, 78, 155

Varicose veins, 157

Variola, see SMALLPOX

Varioloid, see SMALLPOX

Varix, 154, 155, 222

Varnish, 45

Vasa deferentia, 17

Vaselin, 45, 46

Veins, azygos, 17, 208; coronary, 113, 118; diseases of, 136, 137, 154, 155, 498; examination of, 122, 256, 487; inflammation of, see PHLEBITIS; pulmonary, Fig. 80; œsophageal, 124; of Thebesius, 118; ovarian, 220; portal, 154; spermatic, 155; suppuration of, 154; thrombosis of, 154; traumatism causing diseases of, 154

Velum palati, 15, 17, 123, 418, 430, 485, Fig. 91

Vena cava, 15, 16, 17, 207, 208, 418; examination of, in animals, 413, 415, 418, 428, 430

Ventricles of brain, examination of, 16, 483

Ventricles of heart, diseases of, 113, 142, 144, 148; examination of, 15, 114, 117, 419, Figs. 81-85

Ventricular septum, 118

Veratrine, toxicology of, 461, 463

Veratrum viride, post-mortem rigidity in poisoning by, 59

Vermiform appendix, see APPENDIX VERMIFORMIS

Vernix caseosa, 489

Verruca, 73

Vertebrae, caries of, 308

Vertebral column, diseases and injuries of, 253, 283, 308, 355, 441; examination of, 16, 253, 482, 486, Figs. 154-158

Vertigo, 257

Vesiculæ seminales, 17, 348
 Veterinary postmortems, xxv, p. 407
 Viability of child, how determined, 293, 443, 444, 488
Vibrio cholerae, 388
 Vienna method of exenteration of animals, 416
 Vienna, postmortems at, 7, 15, 435
 Vincent's angina, 313
 Violence, external, forms of, 506
 Virchow, 8, 14, 23, 27, 43, Fig. 201
 Virchow's method of sectioning brain, 246, Figs. 141-147; red atrophy, 229
 Virulence of organisms, 49
 Vise, 38
 Vitiligo, 69, 71
 Vocal cords, 123, 124, 157, 158, 270, Fig. 93
 Volatile oils, effect of, on urine, 466
 Vulvulus of omentum, 172; of sigmoid, 101
 Vomica (cavity)
 Vomit, luminosity of, 465
 V-shaped incision, 118
 Vulva, diseases of, 78, 336; examination of, 17
 Vulvitis, 324
 Vulvovaginitis, 325

W

Wart, 48, 73, 78; anatomic, 51, 52; syphilitic, 336
 Warthin's autopsy-protocols, 19
 Water, distilled, 41; percentage of, in body, 396; use of, in cleansing parts, 10, 13, 29
 "Water gas," toxicology of, 473
 Waxy degeneration in typhoid fever, 92, 353
 Weigert's fibrin stain, 375
 Weights (see under the various organs and parts), 68, 138, 221, 243, xxiv, p. 394
 Wens, 73
 Wetherill's hæmoglobin scale, 126
 Wheat rust, 432
 Whetstone, 39, 42, Fig. 21
 Whip-worm, 362

Whitlows, 48
 Whooping-cough (pertussis), 130, 157, 325, 388, 491
 Widal test, 134, 181, 353, 354
 Williams case, 462
 Winkler vs. Hawkes, 6
 Winslow's test, 54
 Wire, platinum, 41
 Wire saw, 35, Fig. 163
 Wiring in cases of aneurism, 154
 Wirsung's canal, 199
 "Wish-bone," 429
 "Wooden tongue," 306
 Woodhead's method of examining ear, 272
 Worms, intestinal, 98
 Wound, 2, 15, 16, 41, 46, 48, 49, 50, 62, 63, 75, 111, 112, 146, 341, 481; bullet, Plate six
 Wound-infection, 52
 Wrisberg's ganglion, examination of, 290, Fig. 74

X

Xanthine, 214, 217
 Xanthoma, 73
 Xiphoid cartilage, 98
 Xiphopagus, 77
 X-rays, anatomic wart treated by, 52; cancer caused by, 455; determination of the existence of life by, 54; in determining arsenic in stomach, 471; legal aspects of, 455; sterility caused by, 222, 455; study of bone lesions by, 62, 275

Y

Y incision, 90
 Yaws, 317
 Yellow atrophy of liver, acute, 106, 173, 357
 Yellow fever, 48, 388, 407, 492

Z

Zenker's degeneration, 92, 355; fluid, 375
 Zinc chlorid for hardening brain, 252
 Zinc salts, toxicology of, 465, 473
 "Zuckerguss" liver and spleen, 102, 223









74-1572/38

University of Toronto
Library

DO NOT
REMOVE
THE
CARD
FROM
THIS
POCKET

Acme Library Card Pocket
Under Pat. "Ref. Index File"
Made by LIBRARY BUREAU

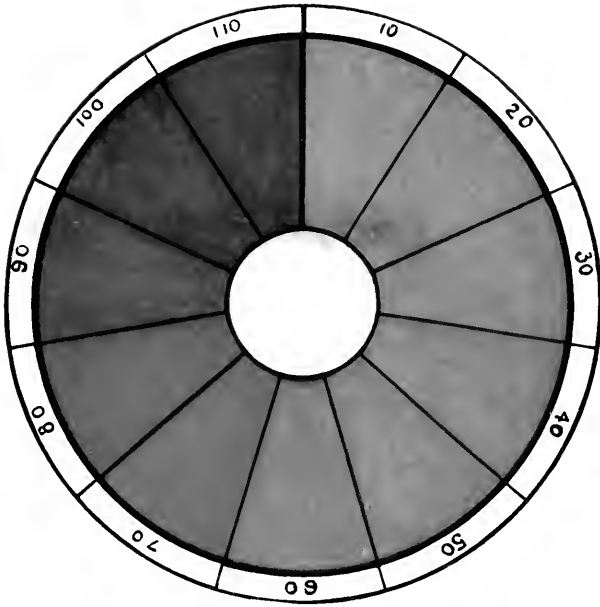
May 1 / 23
28.8.24.
6-7-31.

Beaverly St. 51 Howard Ave.
A.T. Campbell

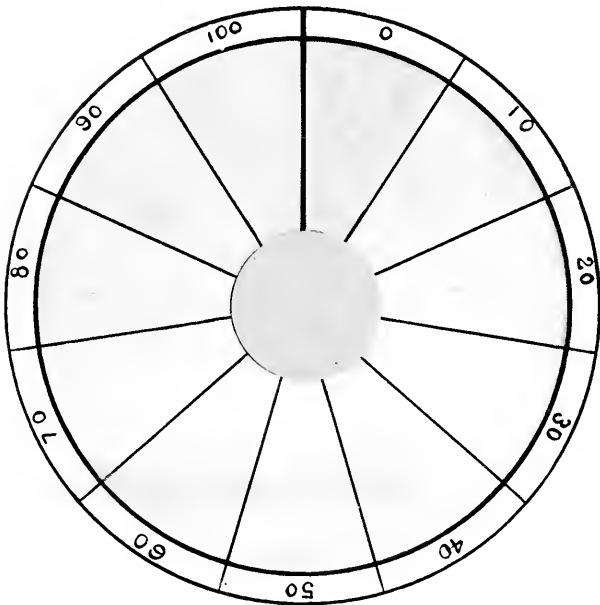
20

94-

PLATE III



POST-MORTEM BLOOD-COLOR SCALE.



MOISTURE SCALE.

